This is a digital copy of a book that was preserved for generations on library shelves before it was carefully scanned by Google as part of a project to make the world's books discoverable online.

It has survived long enough for the copyright to expire and the book to enter the public domain. A public domain book is one that was never subject to copyright or whose legal copyright term has expired. Whether a book is in the public domain may vary country to country. Public domain books are our gateways to the past, representing a wealth of history, culture and knowledge that's often difficult to discover.

Marks, notations and other marginalia present in the original volume will appear in this file - a reminder of this book's long journey from the publisher to a library and finally to you.

Usage guidelines

Google is proud to partner with libraries to digitize public domain materials and make them widely accessible. Public domain books belong to the public and we are merely their custodians. Nevertheless, this work is expensive, so in order to keep providing this resource, we have taken steps to prevent abuse by commercial parties, including placing technical restrictions on automated querying.

We also ask that you:

+ *Make non-commercial use of the files* We designed Google Book Search for use by individuals, and we request that you use these files for personal, non-commercial purposes.
+ *Refrain from automated querying* Do not send automated queries of any sort to Google's system: If you are conducting research on machine translation, optical character recognition or other areas where access to a large amount of text is helpful, please contact us. We encourage the use of public domain materials for these purposes and may be able to help.
+ *Maintain attribution* The Google "watermark" you see on each file is essential for informing people about this project and helping them find additional materials through Google Book Search. Please do not remove it.
+ *Keep it legal* Whatever your use, remember that you are responsible for ensuring that what you are doing is legal. Do not assume that just because we believe a book is in the public domain for users in the United States, that the work is also in the public domain for users in other countries. Whether a book is still in copyright varies from country to country, and we can't offer guidance on whether any specific use of any specific book is allowed. Please do not assume that a book's appearance in Google Book Search means it can be used in any manner anywhere in the world. Copyright infringement liability can be quite severe.

About Google Book Search

Google's mission is to organize the world's information and to make it universally accessible and useful. Google Book Search helps readers discover the world's books while helping authors and publishers reach new audiences. You can search through the full text of this book on the web at `http://books.google.com/`

LANE

MEDICAL LIBRARY

LEVI COOPER LANE FUND

A

TEXT-BOOK

OF

PATHOLOGY

BY

ALFRED STENGEL, M. D.

Professor of Clinical Medicine in the University of Pennsylvania; Physician to the Philadelphia Hospital; Physician to the Children's Hospital, Philadelphia, etc.

LANE LIBRARY

WITH 372 ILLUSTRATIONS

SECOND EDITION

PHILADELPHIA
W. B. SAUNDERS
925 WALNUT STREET
1899

Copyright, 1899,
By W. B. SAUNDERS.

ELECTROTYPED BY
WESTCOTT & THOMSON, PHILADA.

PRESS OF
W. B. SAUNDERS, PHILADA.

99

PREFACE TO THE SECOND EDITION.

As the sale of the first edition has made it necessary that another should be issued within a few months, the author has taken advantage of the opportunity to correct some verbal and typographical errors, but no revision has been attempted. The favorable reception accorded the first edition is an indication that the plan of the book has met with approval, and encourages the author in continuing the work upon the same lines, with such revision as may be necessary hereafter, should subsequent editions be called for.

43499

PREFACE.

In writing this book the author has tried to present the subject of Pathology in as practical a form as possible, and always from the point of view of the clinical pathologist. Considerable parts of the book were first prepared and used as the basis of demonstrations upon clinical pathology for students of medicine; prominence is therefore given to pathologic physiology, and discursiveness and citation of authorities are avoided.

Except in a few instances, discussion of methods of examination has been omitted, because it seemed unwise to increase the size of the book with matter that is appropriately presented in special works on technique. For similar reasons the author has decided to exclude the pathology of the skin and of the organs of special sense.

Controversial matter has been avoided as much as possible, excepting in certain parts of the sections on General Bacteriology and on Neuropathology, in which it seemed proper to discuss conflicting theories.

Full use has been made of works on pathology and of special monographs in English as well as in French and German.

The author is greatly indebted to Dr. Samuel S. Kneass and Dr. Alonzo E. Taylor for assistance in the sections on General Bacteriology and the Degenerations in Part I., and especially to Dr. Joseph Sailer, who prepared almost wholly the sections on Neuropathology. Acknowledgment is also due Mr. Thos. F. Dagney, of Mr. Saunders' editorial office, for his uniform courtesy and assistance in many ways, and Mr. R. W. Greene for the preparation of the Index.

CONTENTS.

PART I.—GENERAL PATHOLOGY.

CHAPTER I.

PAGE

THE ETIOLOGY OF DISEASE 18

Traumatism, 19.—Physical Conditions, 20.—Poisons, 23.—Bacteria and Parasites, 29.

CHAPTER II.

DISORDERS OF NUTRITION AND METABOLISM 31

Food, 31.—Diminished Supply of Food, 31.—Increased Supply of Food, 32.—Excessive Tissue-destruction, 33.—Acid-intoxication, 33.—Formation of Albumoses, 35.—Alloxin Bases and Uric Acid, 36.—Gout, 36.—Glycosuria, 37.—Diabetes, 38.—Fever, 41.

CHAPTER III.

DISTURBANCES OF THE CIRCULATION OF THE BLOOD 43

General Disturbances, 43.—Local Hyperemia, 46.—Local Anemia, 47.—Hemorrhage, 48.—Embolism, 51.—Infarction, 53.—Thrombosis, 55.—Edema, 59.

CHAPTER IV.

RETROGRESSIVE PROCESSES 62

Atrophy, 62.—The Degenerations, 64.—Cloudy Swelling, 64.—Fatty Infiltration, 66.—Fatty Degeneration, 68.—Amyloid Degeneration, 71.—Hyaline Degeneration, 74.—Mucoid Degeneration, 76.—Colloid Degeneration, 78.—Glycogenic Infiltration, 79.—Dropsical Infiltration, 80.—Cellular Necrosis, 97.—Abnormal Cell-division, 97.

CHAPTER V.

INFLAMMATION AND REGENERATION 98

Inflammation, 98.—Regeneration, 109.—Metaplasia, 113.

CHAPTER VI.

PROGRESSIVE TISSUE-CHANGES 113

Hypertrophy, 113.—Tumors, 115.—Fibroma, 120.—Myxoma, 124.—Lipoma, 125.—Xanthoma, 126.—Chondroma, 127.—Osteoma, 130.—Lymphangioma, 132.—Hemangioma, 132.—Lymphadenoma, 135.—

PAGE

Sarcoma, 145.—Spindle-celled Sarcoma, 141.—Round-celled Sarcoma, 142.—Angiosarcoma, 144.—Cylindroma, 145.—Melanosarcoma, 146.—Giant-celled Sarcoma, 147.—Mixed Tumors, 149.—Chloroma, 149.—Psammoma, 149.—Mycosis Fungoides, 149.—Endothelioma, 150.—Glioma, 151.—Neuroma, 154.—Leiomyoma, 154.—Rhabdomyoma, 157.—Papilloma, 157.—Adenoma, 159.—Carcinoma, 163.—Epithelioma, 171.—Glandular Carcinoma, 172.—Colloid Cancer, 174.—Syncytioma Malignum, 175.—Cysts, 176.—Teratoma, 179.

CHAPTER VII.

BACTERIA AND DISEASES DUE TO BACTERIA 181

Classification, 182.—Morphology, 183.—Demonstration, 186.—Biology, 188.—Functions and Products of Bacteria, 192.—Effects of Toxic Products of Bacteria, 196.—Immunity, 197.

Diseases due to Bacteria, 201.—Suppurative Diseases, 202.—Gonorrhea, 206.—Croupous Pneumonia, 207.—Other Forms of Pneumonia, 209.—Rhinoscleroma, 210.—Diphtheria, 211.—Typhoid fever, 214.—Bacillus Coli Communis, 218.—Cholera, 219.—Tuberculosis, 223.—Fowl-tuberculosis, 235.—Leprosy, 235.—Glanders, 239.—Malignant Edema, 240.—Anthrax, 242.—Infectious Emphysema, 244.—Tetanus, 246.—Actinomycosis, 247.—Mycetoma, 250.—Relapsing Fever, 251.—Influenza, 252.—Bubonic Plague, 253.—Syphilis, 254.—Soft Chancre, 259.—Yellow Fever, 260.—Measles, 261.—Scarlet Fever, 261.—Mumps, 261.—Whooping-cough, 261.—Typhus Fever, 262.—Rabies, 262.—Hemorrhagic Diseases, 262.—Rheumatism, 263.—Malta Fever, 264.—Beri-Beri, 265.

CHAPTER VIII.

ANIMAL PARASITES AND DISEASES CAUSED BY THEM 265

Protozoa, 265.—Amœba Coli, 265.—Other Amœbæ, 266.—Hematozoön Malariæ, 267.—Coccidium Oviforme, 269.—Animal Parasites and Carcinoma, 270.—Animal Parasites and Molluscum Contagiosum, 272.—Variola and Vaccinia, 273.—Varicella, 274.—Measles, Scarlet Fever, and other Diseases, 274.—Cercomonas Intestinalis, 274.—Trichomonas Intestinalis, 275.—Trichomonas Vaginalis, 275.—Other Forms of Trichomonas, 275.—Balantidium Coli, 276.—Megastoma Entericum, 276.

Cestodes, or **Tape-worms,** 277.—Tænia Solium, 279.—Tænia Saginata, 280.—Tænia Nana, 281.—Tænia Elliptica, 282.—Tænia Flavopunctata, 282.—Tænia Madagascariensis, 282.—Other Forms of Tænia, 282.—Bothriocephalus Latus, 285.—Bothriocephalus Cordatus, 286.—Bothriocephalus Cristatus, 286.—Bothriocephalus Liguloides, 286.

Nematodes, or **Round-worms,** 286.—Ascaris Lumbricoides, 286.—Ascaris Mystax, 287.—Ascaris Maritima, 287.—Oxyuris Vermicularis, 287.—Trichina Spiralis, 288.—Ankylostoma Duodenale, 289.—Anguillula Intestinalis and Rhabditis Stercoralis, 290.—Trichocephalus Dispar, 290.—Filaria Medinensis, 291.—Filaria Sanguinis Hominis, 291.—Other Forms of Filaria, 293.—Echinococcus Gigas, 293.—Eustrongylus Gigas, 293.—Strongylus Longevaginatus, 293.

Trematodes, or **Fluke-worms,** 293.—Distoma Hepaticum, 294.—

PAGE

Distoma Lanceolatum, 294.—**Distoma Hematobium**, 294.—**Distoma Pulmonale**, 296.—Other Fluke-worms, 296.

Annelids, 296.

Arthropodia, 296.—Pentastomum Denticulatum, 297.—Myiasis, 297.

PART II.—SPECIAL PATHOLOGY.

CHAPTER I.

DISEASES OF THE BLOOD 298

Anatomy, 298.—Blood-formation, 303.—Pathologic Changes in Red Corpuscles, 303.—Pathologic Changes in Leukocytes, 305.—Pathologic Changes in Plasma, 306.—Plethora, 306.—Oligemia, 307.—Hydremia and Anhydremia, 307.—Lipemia, 308.—Melanemia, 309.—Hemocytolysis and Hemoglobinemia, 309.—Polycythemia, 310.—Leukocytosis, 310.—Hypoleukocytosis, 312.—Anemia, 313.—Chlorosis, 315.—Progressive Pernicious Anemia, 317.—Leukemia, 319.—Hodgkin's Disease, 323.—Pseudoleukemia Infantum, 323.—Foreign Bodies and Parasites, 324.—Methods of Examining the Blood, 324.

CHAPTER II.

DISEASES OF THE LYMPHATIC TISSUES 326

Spleen, 326.—Abnormal Development and Situation, 327.—Circulatory Disturbances, 328.—Inflammation, 329.—Atrophy and Degeneration, 331.—Tumors and Parasites, 332.—Infectious Diseases, 333.

Lymphatic Glands, 334.—Atrophy, 334.—Hypertrophy, 334.—Degenerations, 334.—Inflammation, 336.—Infectious Diseases, 338.—Tumors, 341.

Bone-marrow, 343.—Degenerations, 343.—Atrophy, 344.—Hypertrophy, 344.—Inflammation, 344.—Infectious Diseases and Tumors, 345.

Thymus Gland, 345.

CHAPTER III.

DISEASES OF THE CIRCULATORY SYSTEM 346

Heart, 346.—Congenital Diseases and Deformities, 346.—Circulatory Disturbances, 350.—*Endocardium*, 352.—Endocarditis, 352.—Circulatory Disturbances, 359.—Degenerations, 359.—Inflammation, 364.—Hypoplasia and Atrophy, 370.—Hypertrophy and Dilatation, 371.—Aneurysm, 374.—Wounds and Rupture, 374.—Infectious Diseases, 375.—New Growths and Parasites, 375.—*Pericardium*, 375.—Circulatory Disturbances, 376.—Inflammation, 376.—Infectious Diseases, 380.—Tumors and Parasites, 380.—Pneumopericardium, 380.

Arteries, 381.—Congenital Defects, 381.—Hypertrophy, 381.—

PAGE

Atrophy, 381.—Degenerations, 382.—Inflammation, 383.—Infectious Diseases, 388.—Aneurysm, 388.

Veins, 395.—Circulatory Disturbances, 395.—Degenerations, 396.—Inflammation, 396.—Dilatation, 397.—Tumors, 398.—Infectious Diseases, 399.

Lymphatic Channels, 399.—Inflammation, 399.—Dilatation, 399.—Infectious Diseases, 400.—Tumors, 401.—Parasites, 401.

Thoracic Duct, 401.

CHAPTER IV.

DISEASES OF THE RESPIRATORY SYSTEM 402

Nasal Cavities, 402.—Congenital Abnormalities, 402.—Circulatory Disturbances, 402.—Inflammation, 402.—Infectious Diseases, 403.—Tumors, 403.—Parasites and Foreign Bodies, 404.

Larynx, 404.—Congenital Abnormalities, 404.—Circulatory Disturbances, 404.—Inflammations, 404.—Infectious Diseases, 406.—Tumors, 407.—Parasites and Foreign Bodies, 408.

Trachea, 408.—Malformations, 408.—Circulatory Disturbances, 408.—Inflammation, 408.—Infectious Diseases, 409.—Tumors, 409.

Bronchi, 409.—Congenital Malformations, 409.—Circulatory Disturbances, 409.—Inflammations, 409.—Stenosis and Obstruction, 412.—Dilatation, 412.—Infectious Diseases, 413.—Tumors, 413.—Parasites and Foreign Bodies, 413.

Lungs, 415.—Congenital Defects, 415.—Circulatory Disturbances, 415.—Hypertrophy and Atrophy, 419.—Emphysema, 419.—Atelectasis, 423.—Inflammation or Pneumonia, 425.—Gangrene, 442.—Tuberculosis, 443.—Syphilis, 454.—Glanders, 456.—Actinomycosis, 456.—Tumors, 457.—Parasites, 459.

Pleura, 460.—Circulatory Disturbances, 460.—Inflammation, 461.—Infectious Diseases, 465.—Tumors and Parasites, 465.

CHAPTER V.

DISEASES OF THE GASTRO-INTESTINAL TRACT 467

Mouth, 467.—Congenital Abnormalities, 467.—Circulatory Disturbances, 467.—Inflammation, 468.—Atrophy and Degeneration, 471.—Infectious Diseases, 471.—Tumors, 473.

Teeth, 474.

Pharynx and **Tonsils,** 475.—Circulatory Disturbances, 475.—Inflammations, 475.—Pressure-necrosis, 478.—Infectious Diseases, 479.—Tumors, 480.

Salivary Glands, 481.

Esophagus, 482.—Congenital Defects, 482.—Circulatory Disturbances, 482.—Inflammations, 482.—Stenosis, 483.—Dilatation, 483.—Perforation and Rupture, 484.—Infectious Diseases, 484.—Tumors, 484.

Stomach, 485.—Congenital Defects, 485.—Circulatory Disturbances, 485.—Inflammations, 486.—Peptic Ulcer, 489.—Atrophy and Degenerations, 491.—Alterations in Position and Size, 492.—Infectious Diseases, 493.—Tumors, 493.

Intestines, 497.—Abnormalities, 497.—Intestinal Obstruction, 500.—Prolapse of Rectum, 502.—Atrophy and Degeneration, 502.—Circu-

PAGE

latory Disturbances, 503.—Inflammation, 504.—Inflammation of Special Parts, 506.—Infectious Diseases, 510.—Tumors, 516.—Parasites, 519.—Intestinal Rupture and Foreign Bodies, 520.

Liver, 521.—Malformations and Changes of Position, 521.—Circulatory Disturbances, 522.—Atrophy and Degenerations, 524.—Inflammations, 529.—Hypertrophy, 534.—Rupture, 534.—Infectious Diseases, 543.—Tumors, 536.—Parasites, 539.

Biliary Ducts and **Gall-bladder,** 541.—Inflammations, 541.—Stenosis and Dilatation, 542.—Gall-stones, Cholelithiasis, 543.—Tumors, 544.—Jaundice, 544.

Pancreas, 546.—Congenital Abnormalities, 546—Circulatory Disturbances, 546.—Atrophy and Degenerations, 546.—Inflammations, 548.—Infectious Diseases, 549.—Tumors, 549.—Pancreatic Duct, 550.

Peritoneum, 551.—Congenital Abnormalities, 551.—Circulatory Disturbances, 551.—Inflammations, 553.—Tumors, 557.—Parasites, 558.

CHAPTER VI.

DISEASES OF THE DUCTLESS GLANDS 558

Thyroid Gland, 558.—Congenital Defects, 559.—Disturbances of Circulation, 559.—Inflammations, 559.—Struma or Goiter, 559.—Infectious Diseases, 562.—Tumors and Parasites, 562.—General Results of Thyroid Disease, 562.

Suprarenal Bodies, 564.—Congenital Anomalies, 564.—Degenerations, 565.—Infectious Diseases, 565.—Circulatory Disturbances, 566.—Inflammation, 566.—Tumors, 566.—General Effects of Suprarenal Diseases, 566.

CHAPTER VII.

DISEASES OF THE URINARY ORGANS 567

Kidneys, 567.—Congenital Anomalies, 567.—Changes of Position, 568.—Circulatory Disturbances, 568.—Inflammations, 570.—Atrophy and Hypertrophy, 585.—Degenerations, 586.—Concretions in the Uriniferous Tubules, 589.—Infectious Diseases, 590.—Tumors, 590.—Parasites, 594.

Pelvis of Kidney and **Ureter,** 595.—Congenital and Acquired Malformations, 595.—Calculus, 596.—Inflammation, 596.—Infectious Diseases, 597.—Tumors, 598.—Parasites, 598.

Urinary Bladder, 599.—Malformations, 599.—Changes of Position, 599.—Rupture, 600.—Circulatory Disturbances, 600.—Inflammation, 600.—Infectious Diseases, 602.—Calculi and Foreign Bodies, 603.—Tumors, 604.—Abnormal Conditions of the Urine, 606.—Chemical Changes and Sediments of Urine, 611.

Urethra, 614.—Congenital Abnormalities, 614.—Inflammations, 614.—Injuries, 617.—Infectious Diseases, 617.—Tumors, 618.

CHAPTER VIII.

DISEASES OF THE REPRODUCTIVE ORGANS 618

Uterus, 618.—Development and Anatomy, 618.—Congenital Abnormalities, 619.—Alterations of Position, 620.—Stenosis, Dilatation, and

PAGE

Rupture, 622.—Circulatory Disturbances, 623.—Inflammations, 624.—Infectious Diseases, 628.—Atrophy and Degenerations, 631.—Hypertrophy and Hyperplasia, 631.—Tumors, 632.—Parasites, 637.

Ovaries, 637.—Development and Anatomy, 637.—Congenital Abnormalities, 638.—Changes in Position, 638.—Circulatory Disturbances, 638.—Inflammation, 639.—Infectious Diseases, 639.—Tumors, 640.—Cysts of the Parovarium, 643.—Cysts of Kobelt, 644.

Fallopian Tubes, 644.—Congenital Abnormalities, 644.—Changes of Position, 644.—Stenosis, 645.—Dilatation, 645.—Circulatory Disturbances, 645.—Inflammations, 646.—Infectious Diseases, 648.—Tumors, 649.—Extra-uterine Pregnancy, 650.

Vagina, 652.—Prolapse of Vaginal Wall, 652.—Stenosis, 652.—Wounds and Fistulæ, 652.—Circulatory Disturbances, 653.—Inflammations, 653.—Infectious Diseases, 654.—Tumors, 654.

Decidua, Placenta, and **Fetal Membranes,** 654.—Anatomic Considerations, 654.—Abnormalities of Development, 655.—Circulatory Disturbances, 655.—Inflammation, 656.—Infectious Diseases, 657.—Hyperplasia, 657.

Vulva, 659.—Circulatory Disturbances, 659.—Inflammation, 659.—Infectious Diseases, 660.—Tumors, 660.

Penis and **Scrotum,** 661.—Congenital Abnormalities, 661.—Inflammation, 661.—Infectious Diseases, 662.—Tumors, 662.—Injuries, 663.

Testicles, 663.—Congenital Abnormalities, 663.—Atrophy and Hypertrophy, 663.—Degenerations, 664.—Circulatory Disturbances, 664.—Inflammation, 664.—Infectious Diseases, 667.—Tumors, 669.—Parasites, 671.

Prostate Gland, 671.—Inflammation, 671.—Atrophy and Degeneration, 672.—Concretions, 672.—Infectious Diseases, 672.—Hypertrophy and Tumors, 672.

Cowper's Glands, 675.

Seminal Vesicles, 675.

Mammary Glands, 676.—Congenital Abnormalities, 676.—Circulatory Disturbances, 676.—Inflammations, 677.—Atrophy and Hypertrophy, 678.—Degenerations, 678.—Infectious Diseases, 678.—Tumors, 679.

CHAPTER IX.

DISEASES OF THE BONES 682

Anatomy and Development, 682.—Rickets, 683.—Regeneration of Bone, 685.—Circulatory Disturbances, 688.—Inflammations, 688.—Hypoplasia and Atrophy, 692.—Degenerative Conditions, 692.—Infectious Diseases, 694.—Tumors, 698.

CHAPTER X.

DISEASES OF THE JOINTS 700

Luxation and Ankylosis, 700.—Distortion, 700.—Circulatory Disturbances, 700.—Inflammations, 701.—Infectious Diseases, 704.—Tendon-sheaths and Bursæ, 706.

CHAPTER XI.

PAGE

DISEASES OF THE VOLUNTARY MUSCLES 706

Hypertrophy, 706.—Circulatory Disturbances, 707.—Inflammations, 707.—Atrophy and Degenerations, 709.—Infectious Diseases, 712.—Tumors and Parasites, 712.

CHAPTER XII.

DISEASES OF THE BRAIN AND ITS MEMBRANES 713

Dura Mater, 713.—Circulatory Disturbances, 713.—Inflammations, 713.—Infectious Diseases, 714.—Tumors, 715.

The Pia and Arachnoid, 715.—Circulatory Disturbances, 715.—Inflammation, 716.—Infectious Diseases, 719.—Tumors, 721.

Brain, 723.—Development and Anatomy, 723.—Congenital Abnormalities, 727.—Post-mortem Degenerative Conditions, 732.—General Pathologic Anatomy of the Nervous System, 732.—The Blood-vessels, 743.—Circulatory Disturbances, 745.—Inflammation, 753.—Injuries of Central Nervous System, 760.—Choroid Plexus and Ventricles, 761.—Tumors, 768.—Pituitary Body or Hypophysis Cerebri, 771.

CHAPTER XIII.

DISEASES OF THE SPINAL CORD AND ITS MEMBRANES 775

Dura Mater, 775.—Fatty Infiltration, 775.—Hemorrhage, 775.—Tuberculosis, 775.—Syphilis, 776.

Pia and Arachnoid, 777.—Circulatory Disturbances, 777.—Degenerations, 777.—Inflammations, 777.—Infectious Diseases, 778.

Cord, 778.—Anatomy of the Cord, 778.—Congenital Abnormalities, 780.—Hydromyelia and Syringomyelia, 781.—Circulatory Disturbances, 785.—Inflammations, 787.—Primary Degenerations, 793.—Secondary Degenerations, 800.—Tumors, 802.

CHAPTER XIV.

DISEASES OF THE PERIPHERAL NERVOUS SYSTEM 802

Ganglia of the Cranial Nerves, 802.

The Nerves, 803.—Circulatory Disturbances, 803.—Atrophy and Degeneration, 803.—Inflammation, 806.—Infectious Diseases, 808.—Tumors, 809.

A TEXT-BOOK OF PATHOLOGY.

PART I.

GENERAL PATHOLOGY.

PATHOLOGY is the science that deals with disease in all its aspects. It includes the study of the causes, the manifestations, and the results of disease.

Three important subdivisions of the study of pathology are recognized, viz, *etiology*, or the study of the causes of disease; *morbid* or *pathologic anatomy*, the study of the structural changes in disease; and *morbid* or *pathologic physiology*, the study of disturbances of function. In the latter group is included *pathologic chemistry*, as morbid chemical action and its results are the outcome of disturbed function.

Pathology, or more especially pathologic anatomy, may be divided into *general* and *special* pathology. The former treats of pathologic processes irrespective of any individual part; the latter deals with the processes or changes in individual organs or parts.

Disease itself may be defined as abnormality in structure, in function, or in both combined. It is doubtful whether alteration of function can occur without some alteration in structure, but it frequently happens that functional disturbances are present though no structural alterations are discoverable even by the most precise methods of investigation.

The symptoms of disease are the expressions of abnormal functional activity, and are therefore properly discussed under the head of pathologic physiology; but they are so important from a practical standpoint, and form such an extensive subject of investigation, that they are usually considered apart from pathology, in special treatises dealing with diagnosis and the practice of medicine.

CHAPTER I.

THE ETIOLOGY OF DISEASE.

THE causes of disease may be classified as *predisposing* and *determining*. The former prepare the system or part by rendering it weaker and less resistant; the latter are the immediate or specific causes of disease.

Predisposing Causes.—The normal system is able to cope with the determining causes of disease to a certain point by its general vitality and regulative functions. Thus heat and cold may prove harmless if not too intense or prolonged. In the case of exposure to heat, the superficial capillaries become dilated, sweating increases, and there is increased heat dissipation from the surface at the same time that increased respiratory function occasions evaporation and loss of heat through the lungs. In the case of exposure to cold, increased muscular exercise leads to greater heat production, while contraction of the superficial blood-vessels restricts the elimination of heat. When, however, a certain point of intensity is reached in the case of heat, cold, or other causes of disease, the normal organism is unable to oppose sufficient resistance, and disease or injury results. The degree of resistance differs in different individuals, in different races, or people living under varying climatic conditions, etc. In some the degree of resistance may be so great that certain diseases are never contracted. The term *immunity* (*q. v.*) is applied to this state. In other persons there is a recognizable weakness of resistance in one direction or another which constitutes a definite *predisposition*. The latter may be either *hereditary* or *acquired*. Acquired predisposition results from previous disease, vices of living, and like causes.

Heredity as a predisposing factor in disease is probably less important than was formerly believed, but undoubtedly plays a part in many conditions. By hereditary predisposition is designated abnormal weakness of resistance transmitted from the mother or father to the offspring. There may be congenital weakness that is not definitely hereditary, as it is more or less accidental—that is, not the outcome of tendencies of the same kind (latent or active) in the parent. Heredity may be *direct* or *immediate*—that is, from the parent (himself or herself presenting the condition) to the offspring—or *remote*, as in cases in which the hereditary trait is *latent* in the parent. One or several generations may thus be free from certain diseases or tendencies which reappear in later generations. This return to conditions present in remote ancestors has been likened to *atavism* in the Darwinian sense. In some cases hereditary traits are conveyed from the male parent to the male children, or from the female parent to the female off-

spring; in other cases there is crossed transmission. A peculiar form of heredity is seen in hemophilia and some other diseases, which are transmitted through the female members of a family, who generally remain unaffected, to the male offspring. Hereditary traits sometimes predispose to a number of allied affections. This is particularly striking in the case of the neuropathic heredity, in which various forms of nervous disease may appear in members of an affected family.

Determining Causes.—Among the immediate or determining causes of disease are those which originate outside the body and those which are generated within the body. Among the former are included traumatism, heat, cold, and other physical agents, poisons, and living organisms, including bacteria and various animal parasites. The causes of disease originating within the body itself are less definitely known, but it has been found in chemical studies that various products of normal metabolism when accumulated in abnormal quantity, or products of disturbed metabolism, may occasion local or widespread disease of various sorts. This self-poisoning is designated auto-intoxication.

TRAUMATISM.

Traumatism, or mechanical injury, may be of various sorts, gradual or sudden, small or large; and the effects are dependent upon the form and severity of the injury. *Pressure* brought to bear upon a part leads to disturbances of the circulation and more or less direct injury of the cellular elements. When the pressure is gradual true atrophy of the part may occur, as in the case of the atrophic liver resulting from lacing. When the pressure is greater and the circulation is completely arrested more destructive change may result, such as necrosis or gangrene. This is seen in the necrotic atrophy of bone resulting from the pressure of aneurysms, or the gangrene of extremities resulting from ligation. Frequently, inflammatory reaction occurs in the surrounding tissues when traumatic injuries have been sustained. This is strikingly illustrated in all forms of wounds, and it is through the inflammation and subsequent regeneration of tissue that the areas of destruction are restored. In cases of injury by fine particles, as in powder-marks of the skin, or the surface injuries sustained by miners and metal-workers, or in individuals inhaling sharp particles like coal-dust, marble-dust, or steel-filings, small injuries of the tissues result. The foreign bodies may be subsequently discharged, leaving a focus of inflammation, or the inflammation may surround the particle imbedded in the tissue, and encapsulation by fibrous-tissue formation may occur. Large injuries in which the tissues are contused or broken may lead to extensive inflamma-

tion, in part the result of the direct injury to the tissues and in part the result of injury of the blood-vessels.

PHYSICAL CONDITIONS.

Heat.—High temperatures produce local or general results according to the mode of application and degree of heat.

Local excess of heat produces various lesions. Moderate excess leads to relaxation of the walls of the blood-vessels; with increasing grades of temperature there is in addition necrotic change in the cells of the part, and exudation of serum causes vesicle formation. Still higher grades of temperature produce immediate destruction, perhaps with charring, of large or small areas, while the surrounding tissues suffer from reactive inflammation and hyperemia. Extensive burns involving one-third or more of the surface of the body frequently cause death. In these cases it is likely that poisonous products are formed, either directly through tissue- and blood-destruction, or indirectly through disturbances of the functions of the skin or internal organs. The immediate manner of death is often in the form of shock; when the termination is more delayed various vascular, hemic, and tissue-disturbances may occur. Intravascular coagulation is not unusual, and is not improbably the result of the liberation into the blood of tissue-elements set free in the areas of local destruction, or to substances produced by direct destruction of the blood. The same substances may account for the existence of fever (ferment intoxication). The intravascular coagulation caused in this or other ways may induce venous stasis and localized hemorrhages. Focal necrosis or degeneration of the tissues of various organs, such as the liver, kidneys, or the mucous membranes, may be due to thrombotic occlusion of vessels, or to the direct influence of circulating poisons without thrombosis, or to both. Duodenal ulcer is a lesion often referred to as an occasional result of extensive burns. The blood itself may present evidence of disease in the form of degenerations of the corpuscles, in the reduction of their number and of the amount of coloring matter; while regenerative changes frequently present themselves some time later (nucleated red corpuscles). Changes in the urine may occur in cases of extensive burns in consequence of the tissue-destruction (hemoglobinuria, albumosuria).

Exposure to general high temperature varies in its effects according to the manner of exposure (as with dry air, steam, etc.). An animal exposed to a constant temperature somewhat above the usual surrounding temperature presents a slight increase of its body-heat, which is compensated for by increase in the respirations and pulse-rate. Much higher temperatures may cause death by coagulation of the tissues; notably, the muscular struct-

ure of the heart, or the respiratory muscles. Before this extreme is reached, however, it may be found that the consumption of the tissues of the body is greatly in excess, though the respiratory quotient is altered in favor of the amount of air inhaled. Continuous exposure to excessive heat frequently causes peculiar disturbances in man, known as heatstroke, sunstroke, or insolation and heat-exhaustion. In these conditions hyperemia and edema, or even inflammation of the meninges, may occur. These lesions are sometimes supposed to be the result of the direct effect of the heat; but there is reason to believe that they may be occasioned by poisonous substances produced within the body by disturbed metabolism, as a result of the heat.

Cold.—Exposure to extreme degrees of cold may cause results quite similar to those produced by heat. Exposure of the skin to liquefied air, solidified mercury, or other substances at excessively low temperatures produces vesiculation and necrosis of the tissues like those produced in burns.

Exposure of the body to greatly reduced but bearable temperatures of the surrounding atmosphere causes vascular disturbances followed by necrosis of the tissues and inflammatory changes. The parts so affected are the extremities or projections of the body, like the toes and fingers, nose and ears. The primary result of cold is vascular constriction and local anemia. These serve the purpose of preserving the body heat by preventing heat radiation; later the blood-vessels are paralyzed and extreme hyperemia results. Then cellular exudation and necrosis may occur. These changes are well seen in the condition termed *chilblain.* In prolonged exposure to cold there are a gradual reduction in the activity of the various organs and a gradual obtunding of the sensibility till the patient becomes comatose. The retention of excrementitious products of metabolism, or the formation of products of abnormal metabolism, may be important in causing this condition.

Exposure to cold plays an important part as a clinical cause of disease. Various forms of pharyngitis and coryza or bronchitis so frequently follow such exposure that the term "cold" is generally used. Other conditions, like rheumatism, pleurisy, pneumonia, and the like, bear a similar relation. It is now recognized that in most of these cases cold is merely a predisposing cause, the immediate cause being in many, if not all, cases specific micro-organisms. The mode of action of the exposure is uncertain; probably it causes a reduction in the resisting powers of the organism and thus favors the activity of bacteria. In some cases it may be that the cold alters the fluids of the body in such a way as to permit increased virulence of micro-organisms already present, or to promote their entrance into the system.

Increased Atmospheric Pressure.—Exposure to extreme

pressure of several atmospheres may occur among deep-sea divers, or in men working in caissons used in bridge building. But little disturbance may be caused at first, or for a long time; but on return of the workmen to the usual atmospheric conditions symptoms make their appearance (caisson disease). Among these symptoms are bleeding from the nasal or other mucous membranes, great depression, delirium, and paralytic conditions. Degenerations and vacuolations in the spinal cord have been discovered in some cases.

Decreased Atmospheric Pressure.—Effects of decreased pressure are seen in inhabitants of high altitudes and in persons ascending in balloons. Marked excitement of the vascular system, hemorrhages, vomiting, and similar symptoms are observed; in less marked cases a general excitement of the nervous system, sleeplessness, etc., occur. These symptoms have been attributed to lack of oxygen; to a certain extent they are probably mechanical and due directly to the reduced pressure on the exterior. Recent studies show that the blood contains greatly increased numbers of red corpuscles in a given volume, and the percentage of hemoglobin is correspondingly increased. This is probably due, to a large extent, to disturbance in the distribution of the corpuscles with stagnation in the peripheral vessels (see Diseases of the Blood).

Insufficiency of Respiratory Air.—A certain amount of air is necessary for the continuance of health or life. Insufficiency may be due to diseases which obstruct the air-passages or affect the pulmonary tissue itself, and to foreign bodies (solid bodies, water in drowning) within the air-passages. Changes in the atmosphere or gases taken into the lung may cause insufficiency in the supply of oxygen, notably in CO-poisoning, in which the foreign gas enters into firm combination with the hemoglobin of the blood and thus excludes oxygen.

Moderate decrease of the supply of air causes labored and rapid breathing, more or less cyanosis, depression, and stupor. This condition is termed *asphyxia*. Complete lack of air causes increase of these symptoms and death by *suffocation*. In these cases the blood is exceedingly dark and fluid, and hemorrhages may be found in various situations. The latter result from excessive blood-pressure during the death agony. Long-continued insufficiency of oxygen may directly or indirectly occasion degenerative diseases of the tissues.

It has often been asserted that anemia causes many of its symptoms and results because the blood is incapable of carrying sufficient oxygen in its reduced state. As a matter of fact, however, physiologic experiments have demonstrated that the respiratory exchange (inhalation of oxygen and exhalation of carbonic acid gas) is but little affected and is as frequently increased as decreased.

Electrical Influences.—Electrical discharges may cause burns or similar lesions of the surface, and frequently cause intense shock. Disturbances of the central nervous system of various sorts may occur immediately or some time after the exposure. Doubtless there are distinct organic changes in the nervous tissues, but these have not been determined. Gross injuries of organs, such as rupture and degenerative changes, may be occasioned.

POISONS.

Definition.—The term poison may be applied to substances which when introduced into the living organism disturb the structure or functional activity.

The Action of Poisons in General.—Gaseous poisons act mainly upon the respiratory mucous membranes with which they come in contact, or after absorption into the blood disorganize this fluid or lead to disturbances of the nervous system. Liquid poisons are generally absorbed through the gastro-intestinal mucous membrane, but may be received directly into the tissues by injection under the skin. They are rarely absorbed through the skin. Solid poisons must in all cases first be dissolved, and are then absorbed like the liquid poisons. They may by their strong attraction for water absorb the latter directly from the tissues, and by this process alone may bring about important changes.

The lesions due to a poison may be entirely local, as in the case of certain corrosives or caustics; in other cases the point of entrance is unaffected, the pathologic manifestations being entirely due to the changes in different parts of the body, or to nervous disturbances resulting from the circulation of the poison in the blood.

The fate of poisons after ingestion is very different in different cases. Some poisons circulate with the blood and are eliminated unchanged. Others may suffer chemical change within the stomach or other cavities of the body before absorption, and may be either completely neutralized, or may be converted into forms which are subsequently slowly absorbed. After absorption into the blood other chemical reactions may occur, and the poison may be more or less neutralized, the system then suffering either from the resulting compounds or from the changed conditions of the blood. Active destruction of the poison may occur in the blood or in the various organs. In these processes, however, the glandular organs may suffer seriously, various forms of degeneration or necrosis resulting.

The effect of poisons depends upon the dose as well as upon the nature of the substance, and also upon the individual. The repeated ingestion of certain poisons, such as arsenic or opium, may generate a considerable degree of immunity or tolerance.

Similar immunity may be characteristic of a given individual or of classes or species. Susceptibility to the action of poisons is further influenced by age and constitutional vigor. Children bear certain poisons better, comparatively speaking, than adults, while the reverse is true of other substances. Sometimes there are idiosyncrasies which lead to peculiar results not observed in the average individual. In consequence of this, substances ordinarily not toxic may be extremely injurious to certain persons.

Elimination.—The excretion of poisons may take place through the kidneys, lungs, the mucous membrane of the gastro-intestinal tract, or through the skin. In some instances a poison is almost completely eliminated in the excreta. In other cases it suffers complete change, and is not present at all in the excretions. The rate of elimination varies greatly, and is more or less dependent upon conditions of the system. Some poisons, as phosphorus and mercury, may be stored up within the body for a considerable period, subsequently suffering slow elimination.

Classification.—The number of substances which may act as poisons is very great, and the manifestations are of very different sorts. Classification of poisons is therefore difficult and not entirely satisfactory. We may crudely distinguish between gaseous, liquid, and solid poisons; between animal and vegetable, organic and inorganic, and the like; but these classifications have no scientific value.

From the point of view of the action of the poisons we may distinguish *corrosive poisons*, or those which have a local action; *organic* or *parenchyma-poisons*, or those which act less strongly at the point of application than upon the various organs to which they are conveyed through the blood; *blood-poisons*, or those which exercise their effects primarily upon the blood; and the *nerve-poisons*, or those which disturb the functional activity of the nervous system without producing definitely discoverable lesions.

Corrosive Poisons; Escharotics; Caustics.—Under this heading are included various acids, alkalies, and mineral poisons, such as sulphuric, nitric, oxalic, carbolic, and hydrofluoric acids, caustic potash or soda and ammonium, and gases like chlorin and bromin. Nitrate of silver, bichlorid of mercury, sulphate of copper, and other inorganic compounds have a similar action, and certain organic bodies, such as cantharidin and croton oil, belong to the same class.

All these poisons exercise a destructive effect upon the cells with which they come in contact, partly by abstraction of water and partly as a result of a coagulating power or similar action. The degree of injury depends upon the poison and the amount in contact with the tissues. There may be only a superficial injury of the outer layer of epithelial cells or extensive destruction. Reactive inflammation is almost always present. The affected

part may present slight areas of necrosis with reactive hyperemia and inflammation beneath and around them, or deep eschars, vesicles, or large bullæ. In the process of healing extensive scars may form, and these may be serious in their effects, as in the case of strictures of the esophagus.

Organic Poisons; Parenchyma-poisons.—This large group includes many metallic compounds that have a local corrosive or escharotic effect, but which may gain entrance to the blood and cause extensive organic lesions. It also includes poisons of vegetable origin and products of bacterial growth. In general these poisons have a similar action. The kidneys and the mucous membrane of the intestines are especially active in their elimination and suffer most seriously. Degenerations of the epithelial cells of various sorts are met with, such as nuclear degenerations, coagulation necrosis, fatty degeneration, and even calcification. The changes may be diffuse or may be scattered in small foci. In the latter case small areas of granular appearance, having a lighter color than the surrounding tissues, are seen; and on staining the cells are found to color poorly or not at all, the nuclei often showing this change first. Nuclear degenerations (fragmentation, hyperchromatosis, etc.) are observed, and in some instances marked fatty degeneration of the cells occurs. Around the foci of degeneration there is more or less round-cell infiltration (polymorphonuclear cells), and to a less degree the degenerated area itself is infiltrated. In cases in which diffuse change occurs there is equally diffuse round-cell infiltration. After the acute process has subsided hyperplasia of the connective tissues may occur and the affected part becomes more or less sclerotic or indurated. Regeneration of the parenchyma-cells is less apt to occur.

Some of the more important of the poisons of the group may now be separately considered.

Phosphorus is a poison of considerable activity in the yellow form; the red variety is inert. Workmen in match factories are the most frequent victims of this form of intoxication, but occasionally accidental poisoning by swallowing occurs. In the latter the manifestations are acute. The pathologic changes are catarrhal inflammation of the gastro-intestinal mucous membrane and more or less widespread fatty degeneration of various tissues and organs. The liver suffers most severely, being enlarged, light yellow or reddish in color, and friable or doughy. Microscopically the liver-cells are found extensively degenerated (fatty). Similar but less marked fatty degeneration is found in the renal tubules, gastro-intestinal epithelia, and heart-muscle, and in the intima of the blood-vessels. Extensive jaundice is frequent and numerous hemorrhages may occur. In the more chronic poisoning of match-makers the poison enters through the mouth and respiratory passages, being inspired as dust. Chronic catarrhal inflammation of

the respiratory tract may occur and a peculiar form of necrosis of the bones (see Bones) is met with.

Arsenic is poisonous in certain forms (white arsenic, arsenous acid) and inert in other forms (the sulphids). Acute poisoning occurs when toxic forms are swallowed in large doses; the chronic forms of poisoning result from gradual ingestion or the inhalation of dust containing arsenic. Cases of the latter sort occur when wall-paper, hangings, and the like, colored with arsenic-pigments, are used. The lesions in acute arsenic-poisoning resemble those produced by phosphorus. The gastro-intestinal inflammation is, however, more severe; while the fatty degeneration of the organs is less marked. In chronic arsenic-poisoning changes in the peripheral nerves (degeneration and inflammation) are most important. It is likely that focal or diffuse myelitis may likewise be caused by this poison. Chronic inflammations of the gastro-intestinal or respiratory mucous membranes are met with in some cases. Inflammatory lesions of the skin are frequent.

Lead.—Among the compounds leading to acute or subacute poisoning the chromate, the acetates, the carbonate, and oxid are most important. Chronic poisoning occurs in workmen in paint manufactories and among painters, and in persons drinking certain waters that have been conducted through lead pipes. Less rarely the use of cosmetics, dyestuffs, etc., containing lead causes chronic poisoning. In the acute forms of lead-poisoning moderate gastro-enteritis occurs. In the chronic form changes in the nervous system are most important. Peripheral neuritis is the most frequent lesion, but changes in the large ganglionic cells of the gray matter of the cord have sometimes been found. Diffuse sclerosis of the blood-vessels, interstitial nephritis, and the lesions of gout may be present. Atrophy and fatty degeneration of the muscle-fibers are less important lesions. A blue line on the gums at the junction with the teeth (due to deposit of sulphid of lead) is a lesion of clinical importance.

Mercury.—Poisoning with mercury may be acute, subacute, or chronic. The first is due especially to the corrosive chlorid and other mercuric salts; the second to calomel or small doses of those of the former group. Chronic poisoning occurs as a result of inhalation of fumes or dust containing mercury, and is seen in workmen in mirror manufactories. In the acute cases violent inflammatory and necrotic lesions of the gastro-intestinal tract are seen. Parenchymatous degeneration, fatty change, and even calcification of the renal epithelium may occur; and fatty degeneration in other organs may sometimes be met with. In subacute cases marked by ptyalism some change is doubtless present in the salivary glands, but the nature of this has not been determined.

Ergot.—Ergot is a poison capable of producing intense toxic results. It contains two important toxic principles, sphacelinic

acid and an alkaloid, cornutin. Acute poisoning sometimes results from overdosage; while chronic intoxication occurs from the use of affected grain, particularly in famine years. Widespread poisoning of communities has sometimes resulted. The lesions produced are not definite or uniform. Gastro-intestinal inflammation and erosion of the mucous membrane have been observed, but are not habitual; sclerotic change in the spinal cord has been found in a few cases. Gangrene is a frequent lesion, probably resulting from vascular obstruction due to contraction of the blood-vessels. Enlargement of the spleen has sometimes been noted.

Toxalbumins from Plants.—Certain vegetable bodies, like *ricin* derived from the castor bean and *abrin* derived from jequirity bean, are exceedingly toxic, acting in part as blood-poisons but also as parenchyma-poisons. Injected into animals these substances cause violent intoxication, and focal areas of necrosis in various situations, notably in the liver. In part these lesions result from vascular thrombosis; in part from direct action. The study of the action of these poisons is of particular interest from the resemblance of the lesions to those caused by certain bacteria and bacterial poisons.

Toxic Products of Bacteria.—In the growth and multiplication of various bacteria definite toxic substances are produced, and through the latter the lesions of infection are to a large extent produced. Such poisonous bodies may be generated in the growth of the bacteria outside of the body, as well as within the body. In the latter case the pathologic lesions at the point of infection may be the focus of origin of toxic substances which are then distributed throughout the body in the blood. This is eminently true of tetanus, and to a large degree of diphtheria. In other cases the bacteria themselves are transported to various parts of the body, and finding lodgement in the tissues set up changes by which their toxic products are evolved. The latter increase the local foci of pathologic change and then spread in the circulation and cause general intoxication. Further discussion of these poisons will be included under the individual bacteria.

The venom of serpents and of various insects contains toxic bodies, some of which are albuminous in nature. These vary in their action, being to some extent blood-poisons, but more particularly parenchyma-poisons. The lesions produced are local and general. Locally there are intense inflammatory reaction and edema around an area of cellular necrosis or destruction where the poison has come in immediate contact with the tissues. The blood seems to suffer great disorganization and corpuscular change. Petechial hemorrhage and foci of cellular necrosis occur in various organs; and edema of the lungs is frequently present. The action

of the venom of different animals varies in kind and intensity to a certain extent, but is in general of a similar type.

Blood-poisons.—Various liquid or gaseous substances are termed blood-poisons because of their especial action upon this liquid. The blood-poisons may be classified as (*a*) those which combine with the hemoglobin without changing the corpuscles; (*b*) those which alter the red corpuscles and the coloring matter; (*c*) those which affect the blood as well as the tissues generally; and (*d*) those which cause changes in the blood-plasma, increasing or decreasing the tendency to clotting.

(*a*) Among the poisons which act by entering into combination with the hemoglobin without changing the corpuscles, carbon monoxid, cyanogen, and hydrogen sulphid are important. In carbon-monoxid poisoning, which often results from inhalation of the fumes of charcoal burning with insufficient air, the blood has a light color and light petechial discolorations may be seen in various parts of the body. In cyanogen-poisoning the blood is similarly light in color; while in H_2S-poisoning the blood is often dark, sometimes quite black.

(*b*) Among the poisons which disorganize the blood-corpuscles and later the hemoglobin are a large number of chemical agents used in medical practice or in the arts, including potassium chlorate, nitroglycerin, anilin, nitrobenzol, various coal-tar derivatives, and arseniuretted hydrogen. Certain poisonous plants (toadstools) act similarly. These poisons lead to a reduction of the hemoglobin with generation of methemoglobin and at the same time destruction of the corpuscles themselves, with release of the hemoglobin into the serum. The altered condition of the blood often induces secondary changes, such as fatty degeneration and hemorrhages in various organs. The blood-corpuscles are found in variously degenerated conditions, showing microcytosis and poikilocytosis in particular. Nucleated red corpuscles may be present as in other conditions of blood-destruction with attempted regeneration.

(*c*) Among the poisons which disorganize the blood and at the same time cause changes in the parenchyma of organs, reference has been made to abrin and ricin. In addition to the organic changes, these substances cause certain alterations in the blood itself, increasing the coagulability and thus inducing thrombosis.

(*d*) Various substances introduced in sufficient quantity are capable of affecting the plasma of the blood or the corpuscles in such a way as to affect its coagulability. Calcium salts, carbonic acid gas, and fibrin-ferment are active in this way, but the last alone produces toxic results through this function. Ferment-intoxication may occur in consequence of various other intoxications, when corpuscular or tissue-destruction has liberated the ferment. Among the poisons which decrease coagulability peptone (albumose) is important.

Nerve-poisons.—This group contains a large number of substances capable of producing violent symptoms and even death without definite change in the tissues of the body. Recent investigations showing certain alterations in the finer structure of the nervous system in disease and in cases of intoxication suggest that histologic changes in the central neurons may be found to result from poisoning by these substances. Changes of this kind (thickening, contraction, or disappearance of dendrites, etc.) have been described in the gray matter of animals poisoned with alcohol and certain toxins of bacterial origin. It is not unlikely that similar changes will be found in other cases.

Among the nerve-poisons are alcohol, chloroform, ether, and various alkaloids like morphin, atropin, etc. In this same group might be included some of the poisons contained in the venom of serpents and other animals, but these frequently cause definite lesions in the blood or tissues of the body. Another group of poisons of similar action are those produced within the body by putrefactive action or in various foodstuffs before ingestion. Frequently cases have been observed in which all the members of a family or even large numbers of people have been poisoned by eating certain meats, sausages, ice-cream, and other foods. In some of these cases it has been found that the toxic element was a basic compound resembling the alkaloids in chemical structure. To these putrefactive compounds the name *ptomain* is given. One of these compounds, which occurs in cheese, and occasionally in milk, has been termed tyrotoxicon. Intoxications of this class must be distinguished from infections resulting from the use of food contaminated with micro-organisms. The symptoms may be so rapidly developed (absence of incubation period) and so immediately generalized that the distinction can be arrived at clinically, but the absolute diagnosis is made bacteriologically.

A considerable number of ptomains have been separated, including neurin, obtained from putrid flesh; muscarin and ethylendiamin, derived from decayed fish; mydalein, and mydatoxin. Some of these substances produce toxic results indistinguishable clinically from those produced by certain alkaloids. This fact has become one of great importance in medicolegal investigations.

BACTERIA AND PARASITES.

Bacteria are by far the most important causes of disease. The belief in a living cause or contagium vivum is by no means a recent acquisition, but the actual demonstration that diseases may be caused by minute living organisms has only recently been reached. The micro-organisms in question belong for the most part to the vegetable kingdom and constitute the lowest orders of

fungi. Their biologic characters and their relations to special diseases will be described in a subsequent chapter.

Etiologic Relationship of Bacteria to Disease.—It is difficult to prove the specific relation of bacteria to disease. Koch has laid down four important laws which must be conformed with before the etiologic importance of a bacterium is admitted. These are: (1) the bacterium must be found in the diseased person; (2) it must be cultivatable upon media outside the body; (3) pure cultures introduced into a healthy animal must produce the disease in the animal; and (4) the bacterium must be recoverable from the body of the animal. In a number of diseases micro-organisms have been proved to be the specific causes according to the requirements of Koch's rules. In other diseases it has not been possible to furnish absolute proof, though the presumptive evidence, furnished by constant occurrence of the bacteria, suggestive association with the lesions of the disease, absence of the bacteria in other diseases, etc., is sufficient to satisfy all but the most sceptical.

Classification of Diseases due to Bacteria.—The general term *infectious disease* is applied to all such as are caused by bacteria. In some cases the diseases are readily communicated from person to person, even though contact has not been immediate. These are termed *contagious diseases*, while the term *noncontagious* is given to those in which such ready transference is not observed. As a matter of fact, the distinction is artificial. Any infectious disease may be communicated from the diseased to the healthy if the germs or bacteria are transferred. In some diseases this transference readily occurs, even through the air and at considerable distances; in others actual contact is necessary; while in still others secretions or excretions of the diseased must be conveyed to the healthy. Contagiousness is therefore a matter of degree only.

Infectious diseases may at times spread in communities, affecting large numbers of people. Such a dissemination is termed *epidemic*, and the disease an *epidemic disease*. Other infections are constantly present in a locality; for such the terms *endemic* and *endemic disease* are used. Some endemic diseases are restricted to certain localities and seem in some measure dependent upon local conditions (of atmosphere, soil, etc.) for their continuance. These are called *miasmatic diseases*.

Infectious diseases are frequently described as *local* or *general*. Local infections are those that present specific pathologic change in a restricted area; the general organism suffers more or less in consequence. Examples of this are erysipelas and diphtheria. General infections are marked by an immediately generalized disease, as in typhoid fever. These terms, like others, are much less applicable at the present time than formerly. Among purely local

infections might be named the diseases of the skin due to vegetable micro-organisms.

Entrance of Micro-organisms into the Body.—Bacteria may be inhaled or swallowed, may enter through abrasions in the mucous membranes or skin, and may be transferred *in utero* from the maternal to the fetal blood. The mode of entrance in individual diseases depends upon the nature of the bacterium, its habitat, and surrounding conditions. Some may enter in but one way; others gain access in any of the different ways. Details regarding this subject will be given in the discussion of special infections.

Animal parasites of various kinds act as causes of disease. This group of diseases is termed the *parasitic diseases* or *invasion diseases.* In some instances the clinical course is similar to that of infectious diseases (malaria, dysentery, trichinosis); in other cases the manifestations bear little resemblance to infections.

CHAPTER II.

DISORDERS OF NUTRITION AND METABOLISM.

Food.—In the life of the organism certain substances are needed for the repair of tissues consumed in the wear and tear of life and to supply heat and other energy. Among these foods are proteids, carbohydrates, fats, inorganic salts, and water. A continuance of normal existence requires more or less definite proportions of the first three and at least a sufficiency of salts and water. The amount of food and the exact proportions vary somewhat in individual cases and under varying circumstances. Voit found that a laboring man under ordinary conditions requires 118 g. of proteid, 56 g. of fats, and 500 g. of carbohydrates. The proteids of the diet are necessary to restore tissue-waste, since the organism cannot build up proteids from simpler compounds. This consumes part of the nitrogenous foodstuffs. The rest, with the fats and carbohydrates, is mainly useful in contributing energy.

Diminished Supply of Food; Inanition; Starvation.—Either the want of food or disorder of the gastro-intestinal tract may lead to insufficient nourishment. This causes a loss of body weight, as the necessary heat-producing and energy-giving substances must be supplied to maintain life, and the tissues are consumed for this purpose. The carbohydrates (glycogen of liver and muscles) and fats suffer first and most profoundly, and unimportant parts are reduced before the vital structures are attacked. The subcutaneous and other adipose tissues and the muscles first waste, then the liver, bones, heart, etc.

The functions of various organs suffer greatly: the respirations and heart-action are weak, muscular exertions are reduced to a minimum, the endurance and nervous force decline, and finally death may occur from exhaustion or secondary affections consequent upon the disturbed nutrition (see Acid-intoxication). The blood in starvation preserves its corpuscular richness surprisingly, even after prolonged abstinence. This is doubtless due to loss or evaporation of liquid; the actual number of corpuscles probably suffers reduction.

Increased Supply of Food; Overfeeding.—The effect of this depends upon individual conditions, such as the amount of exercise, the surrounding temperature, and less easily demonstrable peculiarities of the individual. An excess of proteid food leads to increased excretion of the end-product of its metabolism—urea. A very small proportion may contribute to building up a reserve amount of albuminous tissue. Great excess of proteid eventually disturbs digestion and leads to its discharge with the feces.

The carbohydrates and fats are broken up in the body and excreted mainly as carbonic acid and water. An excess of these foods tends to cause increased deposition of reserve fat and glycogen, which may be called upon at subsequent times of need. This deposition is a normal or physiologic process and has the distinct purpose just indicated. Exceptionally in the condition called obesity the storing up of fat is inordinate and probably pathologic.

Obesity.—The origin of fat is still a subject of controversy among physiologists. According to the oldest view, the fat of the body is derived from that of the food, and the possibility of this has actually been demonstrated. Under ordinary circumstances, however, but little if any of the fat is so produced. Another school of physiologists maintained that the proteids of the food break up into a nitrogenous and a non-nitrogenous part, the former being finally excreted as urea and other substances or repairing the tissue-waste, the latter part contributing energy or forming fat. At the present time it must be admitted that though proteids may possibly form fat in this manner, the actual demonstration is still wanting. The main source of fat is certainly the carbohydrates of the food.

Causes of Obesity.—Excessive ingestion of food by persons having active digestion and leading sedentary lives may occasion unusual deposition of fat. It is difficult, however, to determine the limits between physiologic and pathologic fatness. In some cases patients assert that the amount of food has not been excessive, and this may be actually true. Obesity in such individuals is undoubtedly pathologic and due to some inherent abnormality of metabolism. A further proof of the existence of such a tendency is seen in certain families, in which excessive fatness is

common, even in childhood. The nature of this metabolic disorder is obscure. It has often been held that the power of oxidation is lacking, and, as a matter of course, the amount of oxygen consumed is deficient in comparison with the amount of food ingested. This must be true, or the fat could not accumulate; but it remains to be shown whether the diminished oxygen-consumption is the primary cause or only an incident in the disease.

Pathologic Anatomy.—The excessive adipose tissue in this disease is found in the skin and subcutaneous tissues, in the omentum and peritoneum, around the kidneys, heart, and mediastinal tissues, in the liver, and less commonly elsewhere. The amount varies from slight excess to monstrous deposits. Secondary changes in the organs (notably the heart-muscle) may be due to pressure or functional inactivity.

Associated Conditions.—Fatness is more or less closely related to certain other diseases of metabolism, such as diabetes and gout. Anemia is frequently present and has sometimes been regarded as a cause, operating by reducing oxidation. (Further discussion of this subject is included under Fatty Infiltration.)

Excessive Tissue-destruction.—This has been referred to in connection with inanition; but it may occur as a condition independent of the amount of food ingested. Among the conditions in which this is observed may be mentioned fever, infectious or of other forms; chronic infectious diseases, with or without fever; tumors, especially carcinoma; intoxications of various sorts; some cases of Graves' disease, etc. In all of these conditions the fats of the body may waste as in simple inanition; but there is an early and marked tendency to consumption of the more important proteid substances. This latter consumption may proceed along physiologic lines, or there may be distinctly pathologic modifications sometimes leading to serious results (see Acid-intoxication).

The nature of the metabolic disturbances in these cases is obscure, though it is likely that toxic substances of various sorts are the direct causes. This is most probable in the case of direct intoxications (phosphorus), but is also supported by other facts. In Graves' disease and carcinoma, as well as in fevers, there are doubtless poisonous substances in the blood, but whether these are the causes of the metabolic changes or not requires further study. The fact that thyroid extract is capable of causing excessive destruction of tissue in normal or obese persons is significant in this connection.

Acid-intoxication.—In the final metabolic transformation of proteids there are produced ammonium, urea, uric acid, kreatinin, and other nitrogenous substances. The formation of urea is still obscure in some particulars. It is certain that a large part is produced in the liver, and it is probable that some is formed in the muscles. The intermediate steps in the manufacture of urea

have not been definitely determined, but it is known that the liver is capable of converting ammonium salts directly into urea, and it is probable that ammonium is an important intermediate product of proteid transformation. An excess of acids in the body (either from introduction from without or production in the body) is in part neutralized by ammonium, and in consequence the urea of the urine decreases and the ammonium salts are increased. The quantity of such salts is therefore in a measure an indication of the condition which has been termed acid-intoxication. In part the neutralization of acids is effected by the fixed alkalies of the body, and thus occurs the reduced alkalinity of the blood and juices of the body.

Experimental acid-intoxication is easily produced in animals by feeding them with foods deprived of alkaline bases, or by direct administration of acid. In the former case the acids resulting from transformation of food and tissues must be neutralized by the alkalies of the body; in the latter case there is direct excess of acid. Such acid-intoxication is readily produced in herbivorous animals, as the amount of proteid food is small and in consequence but little ammonium is produced. Various nervous symptoms are observed. The animal breathes quickly, the pulse grows rapid, muscular weakness, ataxia, and tremor develop, and finally coma or collapse terminates the disease. The administration of alkalies may completely arrest the progress of the condition and full restoration may occur.

Acid-intoxication in Man.—Somewhat similar symptoms are seen in man in certain diseases in which increased elimination of ammonium with decrease of urea, decreased alkalinity of the blood, and the excretion in the urine of certain organic acids have been discovered. The assumption is warranted that these are cases of acid-intoxication.

Etiology.—Among the diseases in which this occurs are fever, diabetes, carcinoma, acute yellow atrophy of the liver, severe anemia, phosphorus-poisoning, advanced gastro-intestinal disease, and inanition. Sometimes no discoverable cause can be detected (cryptogenetic acid-intoxication).

In these conditions abnormal metabolism leads to excess of various acids, such as lactic, sarcolactic, sulphuric, phosphoric, diacetic, and β-oxybutyric acid. These in part combine with the fixed alkalies and with ammonium, and in part are excreted as such. Some, as sarcolactic acid, usually suffer decomposition in the body, and are therefore rarely met with in the urine.

The origin of the acids of the fatty acid series has been the subject of much controversy. Undoubtedly they may be derived from the non-nitrogenous part of proteids, and in most of the diseases above enumerated this is probably the case; but they may be formed from carbohydrates as well. The increase of diacetic

and β-oxybutyric acids in cases of diabetes when small amounts of carbohydrates are supplied, and their decrease when the carbohydrates are increased, point to the fact that destructive consumption of proteids is the important source, though it may not be the only or invariable source.

There is always reduction of oxidation in cases of acid-intoxication, but it is not known whether this is the primary disturbance, or whether it is but an accompaniment. Experimentally it has been shown by several observers that diminution in the supply of oxygen will lead to increase of these acids. They probably owe their presence to the failure of the normal oxidation which would reduce such bodies to simple excretory products. Other substances may result from the same tissue-destruction with insufficient oxidation. Among these are the amido-bodies, leucin and tyrosin, found in the urine in phosphorus-poisoning and acute yellow atrophy of the liver as well as in other conditions.

Symptoms.—The symptoms of acid-intoxication in man may be quite similar to those seen in experiments upon animals. Depression, stupor, and deep coma (coma carcinomatosum, diabeticum) are some of the more pronounced manifestations. The production of these may be direct or indirect. In diabetes it is generally held that the diacetic and oxybutyric acids are harmless, but that the acetone derived from them causes the violent symptoms. Aside from such direct action acid-intoxication may effect its results by lessening the alkalinity of the blood and abstracting fixed alkalies from the fluids of the body.

Formation of Albumoses.—In disturbed conditions of metabolism albumoses, and probably very rarely peptone, are formed.

The *causes* which lead to the presence of these substances in the blood and their excretion in the urine are numerous. Fever of all kinds may be attended by this condition, and it may occur in the course of suppurations, or other forms of tissue-destruction (acute yellow atrophy, phosphorus-poisoning). It is found in ulceration of the gastro-intestinal tract, and in some cases of new-growths. The occurrence of albumosuria in osteomalacia has long been recognized.

In all cases there is rapid tissue-destruction in which the albumins become hydrated, forming some variety or varieties of albumoses, and possibly in rare cases peptone. Formerly the term peptonuria was generally used to designate what is now called albumosuria. The presence of albumoses in the blood causes no well recognized results. It is known that they retard coagulability, and their ingestion often causes leukocytosis. It is very likely that they have other effects, but these are obscure.

The term peptone is now quite generally limited to the final hydration product according to the definition of Kühne. The peptone of Brücke includes certain bodies now recognized as albumoses.

Alloxin Bases and Uric Acid.—The investigations of recent years have shown that these substances are derived from the nuclein of cellular nuclei. The alloxin bases, xanthin, guanin, adenin, and hypoxanthin, are intermediary products which partially or largely become oxidized to uric acid. Normally the amount of uric acid is far in excess of that of the bases. Some of the uric acid may become further oxidized, with formation of urea. The great source of these products is cellular destruction, and especially that of the leukocytes. Abnormally large quantities are found in the urine in leukemia and in some cases of leukocytosis; and in a measure the substances furnish an indication of leukocytic destruction. The kind of diet may influence the amount of these bodies, according as it is rich or poor in cellular tissue. The attempt to establish a relationship between certain disorders (headaches, migraine, etc.) and increased production of alloxin bases has not as yet proved satisfactory.

A disease in some way dependent upon or associated with abnormal formation of uric acid and alloxin bases is gout.

Gout.—In its typical form gout is a paroxysmal disease marked by deposits of urates in the joints and other structures, and by coincident or consequent inflammatory disturbances. There are many varieties, however, of irregular gout in which the paroxysms may be partly or wholly wanting and in which the disease takes the form of a general systemic disorder, or of organic maladies of various sorts.

Etiology.—Gout is essentially a hereditary affection, the heredity not rarely being polymorphous. By this is meant that in certain families gout and other diseases, such as obesity, diabetes, and arterial sclerosis, may occur interchangeably. Gout usually develops in the later years of life, and among the contributing causes are the use of alcohol, overeating, sedentary life, and chronic lead-poisoning.

Pathologic Anatomy.—The conspicuous anatomic lesions are those of the joints, and consist of the deposit of urate of sodium in the cartilages and connective tissue, and secondary inflammatory changes. The latter may cause great distortion and fibrous overgrowth. Similar urate deposits may occur in the cartilages of the ear, eye, and nose, and in the subcutaneous connective tissue or elsewhere. These deposits, called the gouty *tophi*, may subsequently disappear by absorption or by discharging through the skin. Cirrhosis in various organs and tissues of the body frequently occurs in the course of gout. Among these the cirrhotic or gouty kidney is most important. Atheroma, cirrhosis of the liver, hypertrophy and fibroid change in the heart, and chronic valvular disease are also frequent.

Pathogenesis.—According to the older theory of gout, the disease is due to increased quantities of uric acid in the blood. Re-

cent investigations warrant a return to this view. The uric-acid excretion of the urine has been found to decrease markedly during a few days before an attack, and the assumption is warranted that the acid accumulates in the blood, and is then deposited in the tissues. Prior to the deposits local cellular necroses are believed by many to be necessary for the deposit, and these necroses have been attributed to the excessive amount of acid. Proof is wanting, however, to show that excessive quantities of uric acid are capable of causing such degenerations or necrosis. In some cases traumatism may play a part in localizing the gouty precipitations; in most cases, however, the cause is obscure.

The causes of the increased production of uric acid and the exact mechanism of this abnormal formation are still obscure. An old theory that diminished oxidation in the tissues is the immediate cause is no longer tenable; and a newer view which asserts that the accumulation is the result of failure of the renal function has not been established.

Glycosuria and Diabetes.—A certain amount of grape sugar occurs in the blood and urine of normal persons. The quantity in the blood varies from 0.1 to 0.2 per cent. Notable increase above these figures constitutes a pathologic condition, *glycemia*. Sometimes other forms of sugar, as levulose, occur in the blood and urine. When there is sufficient sugar in the urine to be discoverable by the ordinary tests the condition is pathologic, and is termed *glycosuria*. This may be transient and trivial in character, or a manifestation of a definite diseased condition called diabetes.

The disposition made of carbohydrates by the animal body is not definitely known in all particulars. It is certain, however, that these substances are deposited in the liver and in the muscles in the form of glycogen, that they form fats, and are in part consumed by oxidation. The deposit of glycogen is of the nature of a reserve store, the system thus being prepared for intervals of abstinence. The glycogen is gradually discharged from these tissues, and thus the quantity of sugar in the blood is maintained at a more or less constant level.

Alimentary glycosuria is a term applied to glycosuria occurring in healthy or diseased persons as a result of excess of carbohydrate food. It is easily produced by the administration of considerable quantities of milk-sugar, levulose, cane-sugar, or glucose. The drinking of beer seems to aid particularly in its development. The explanation of this condition seems a simple one. The organism is unable to store up or consume the amount of carbohydrates administered, and the excess is therefore discharged through the kidneys. The ease with which such glycosuria is developed differs in different individuals, and researches have been made to determine the conditions that favor its development. The

liver in particular has been suspected as the organ most likely inefficient in these cases, but thus far no definite facts have been learned; and the *rôle* of this organ has probably been exaggerated.

Experimental glycosuria, produced by administration of phloridzin, offers several puzzling facts for consideration. It shows that excess of glucose in the blood (*hyperglycemia*) is not a necessary condition for the occurrence of glycosuria. After administration of phloridzin, a glucoside which contains about 40 per cent. of sugar, there is no excess of sugar in the blood, but glucose appears in the urine, and indeed more than could have been produced by the entire quantity of phloridzin administered. This shows that there is abstraction of sugar from the reserve stores in the body. It is not unlikely that the renal cells play a part in the occurrence of this unusual excretion; and this fact, together with the disappearance of sugar from the urine in the late stages of some cases of diabetes, when renal disease has occurred, has suggested to some the possibility of *renal forms of glycosuria and diabetes.* This view, however, has not yet been established.

Clinical Causes of Glycosuria.—Glucose appears in the urine in many conditions, including various infectious diseases, various intoxications, and concussion, injury, or disease of the central nervous system, especially the floor of the fourth ventricle.

Diabetes is a disease in which polyuria and glycosuria are marked symptoms. It is not improbable that the term includes disorders of quite different sorts, but no differentiation of such is possible at the present time. A *mild* and a *severe* form are distinguished, and these present some striking differences, to which reference will be made below.

Etiology.—Diabetes is frequently a hereditary disease, occurring in families in which the same disease or obesity and gout have occurred. The Jews seem particularly liable to it. Overeating and sedentary life are causes of some importance, especially of the milder form. Sometimes abnormal conditions of the nervous system may be the underlying cause. Among these are functional depressions, as in cases of excessive grief; traumatic injuries with concussion of the brain; and local diseases at the base of the brain in the vicinity of the medulla. In some cases disease of the pancreas is the probable cause. Diabetes may occur in the young or after middle life, the milder cases more frequently occurring at the latter period.

Pathogenesis.—In the milder cases of diabetes the same explanation may be applicable as that given for glycosuria, viz., the liver and muscles do not store up the carbohydrates carried to them, and the excess of sugar is not burned up in the tissues. Hyperglycemia with consequent glycosuria results. In these cases the withdrawal of carbohydrate food or temporary abstinence from

all food causes the disappearance of the glycosuria. In severe cases this explanation is not entirely applicable, since the amount of glucose in the urine is often but little affected by abstinence from carbohydrate food or even by starvation. It is quite certain that in these severe cases the carbohydrate moiety of the proteids of the food or tissues furnishes the sugar excreted in the urine. In normal individuals and even in those suffering with mild diabetes the carbohydrates thus liberated by proteid decomposition are stored up as glycogen or fat, or burned up in the tissues. Glycosuria does not therefore occur, according to this view, which is held by many. Severe and mild diabetes differ only in degree—in one case the power to consume sugars is greatly deficient; in the other, only moderately so.

The nature of the metabolic disturbances that lead to this inability to dispose of carbohydrates is still very obscure. The old theory, that there is a lack of oxidating power, is disposed of by the experimental demonstration that oxidation may be normally active. The influence of the nervous system is undoubted. Reference may here be made to the occurrence of diabetes after puncture of certain parts of the brain (medulla). At one time this was thought to act through the vasomotor mechanism, congestion and disturbance of function of the liver being regarded as the important consequence of vasomotor derangement. At the present time the part played by the liver is considered less important. No plausible explanation of the *rôle* of the nervous system in the etiology of diabetes has been presented.

Older pathologic studies showed that diseases of the pancreas are frequently associated with diabetes; and recent experimental investigations emphasize this relationship. Removal of the pancreas in the lower animals causes diabetes. It has not, however, been shown in what way pancreatic disease or ablation acts, though Lepine and others believe that the pancreas elaborates a glucose-destroying (glycolytic) ferment, whose absence under the conditions named causes accumulation of sugars in the blood and consequent glycosuria. Unfortunately, this view is not confirmed by the experiments of others; and the theory is certainly not generally applicable, since diabetes may occur without discoverable disease of the pancreas.

Metabolism in Diabetes.—The essential facts are the inability of the body to consume carbohydrates for the production of energy. This leads, sooner or later, to destruction of the proteids of the body with increased excretion of urea. Emaciation may be prevented for a time by increased consumption of proteid food, but eventually occurs. In the destruction of the proteids of the food and tissues acids are formed in excess (phosphoric from the phosphorus, sulphuric from the sulphur, β-oxybutyric and diacetic from the non-nitrogenous part of the albumins), and the condition termed acid-

intoxication (see above) results. A consequence, and to some extent a measure, of this is the increased excretion of ammonium salts in the urine. The uric acid of the urine is but little increased in diabetes. Acetone, a derivative of β-oxybutyric and diacetic acids, and possibly (though not probably) these acids themselves, may occasion still further proteid destruction by direct toxic action. Acetone is certainly the important element in the production of diabetic coma.

Pathologic Anatomy.—Aside from the lesions already referred to as in some way related to the causation of the disease, there are found pathologic changes of various kinds that result from it. The lesions of gout (arteriosclerosis and cirrhotic kidneys) may be of the nature of mere concomitants, or may be direct results of diabetes. Renal diseases are of peculiar interest. Late in diabetes albuminuria frequently develops and interstitial nephritis may follow. When this occurs the glycosuria and other symptoms of diabetes sometimes subside. The explanation of this is obscure (see under Glycosuria). Changes in the liver (cirrhosis) have often been found, and have been regarded as causative in some cases. A peculiar form of diabetes with hepatic disease and general icteroid staining of the skin and other tissues has been described under the title *diabète bronzé*. Skin eruptions (eczema, furuncles, carbuncles) are frequent in certain forms of diabetes; and gangrene of the extremities is common. Pneumonia and pulmonary tuberculosis are among the frequent developments of late stages of the disease. Chronic endocarditis, neuritis, and cataract are comparatively rare lesions. The blood in diabetes is less alkaline than normal and contains an excess of solid matter, particularly when great polyuria has led to inspissation.

Oxaluria.—This term is, strictly speaking, applicable only to increase of oxalic acid in the urine, but is usually employed for cases in which crystals of oxalate of lime are found abundant in the urine. The normal maximum of oxalic acid is 20 mgr. for twenty-four hours. It has been sometimes held that oxaluria is a result of deficient oxidation of the carbohydrates or of the albumins of the body, but this theory has not been established. True oxaluria determined by chemical estimation of the total excretion of oxalic acid has been found in jaundice and in some cases of diabetes. The authors who have argued in favor of a specific disease marked by nervous symptoms and oxaluria based their observations on the presence of an excess of oxalate sediment, rather than on chemical examinations. Increased sediment occurs in certain instances of gout in which the oxalates alternate with uric acid or coexist with this.

Phosphaturia.—This term should be restricted to increased excretion of phosphoric acid, rather than to the presence of increased phosphate sediment in the urine. The latter may be due simply to want of acidity of the urine. The daily maximum of phosphoric acid with ordinary diet is from 3.5 to 4 g. The term phosphaturia might also be applied to cases in which no absolute excess of phosphoric acid is found, but in which this substance is relatively in excess when compared with the excretion of nitrogen. The

normal proportions are from 17 to 20 parts of phosphoric acid for 100 parts of nitrogen. Phosphaturia in the sense just described has been found in some cases of inanition. Decided increase in the phosphatic excretion, absolute as well as relative, occurs in some cases of diabetes; also in cases of tuberculosis and disease of the bones, such as ostitis and osteomyelitis. The term *diabetes phosphaticus* has been used by Teissier for phosphaturia in the sense of increased total excretion, and four varieties have been described: (*a*) cases with polyuria and marked nervous symptoms; (*b*) cases preceding or accompanying pulmonary diseases, especially tuberculosis; (*c*) cases in which phosphaturia alternates with or coexists with glycosuria; and (*d*) cases in which oxaluria, polyuria, and slight albuminuria are present and in which there is some relationship with gout.

The nature of the metabolic disturbances in phosphaturia are obscure. Sometimes the disorder of metabolism seems to be merely quantitative, in other cases doubtless qualitative.

FEVER.

Definition.—It is not easy to define this term accurately, though we may regard as fever a condition in which the temperature of the body is elevated above the normal (98.6° F.; 37° C.) and in which the tissue-metabolism is altered in the direction of increased consumption. There are cases in which the latter is insignificant or wanting, and there are other instances in which the temperature remains normal or subnormal under influences that ordinarily provoke fever. At the present time, however, elevation of temperature seems a necessary condition to the existence of fever.

Nature.—It is important, first, to consider the regulation of the temperature in health. In the normal individual heat is produced in the body by constant oxidation and other metabolic activities, and the excess is dissipated by radiation from the surface and the heating or evaporation of excreta. These processes of *heat-production* and *heat-dissipation* are regulated in an orderly manner under the influence of the nervous system. Special centers for the production, dissipation, and regulation of heat have been described by the physiologists, though their location and method of operation still remain in doubt. Whatever the exact mechanism may be found to be, it is quite certain that in some way the nervous system exercises a control over production and discharge of heat.

The excessive heat of fever may conceivably be due to excess of heat-production, diminution of the dissipation, to both of these conditions, or to increase of both with greater excess of production. In most instances of fever in man it appears that production and dissipation are both increased, though the latter is insufficient. The increased production results from increased oxidation and other metabolic processes. A study of the respiratory exchange of gases shows that oxygen is consumed in greater quantity than normally, and the quantity of CO_2 is correspondingly increased. The excess

may amount to as much as 20 per cent. Investigation of the excreta shows at the same time evidences of more or less rapid and extensive tissue-waste. The quantity of nitrogen eliminated is in excess of that consumed in the food; and wasting of the tissues results. The albuminous elements suffer particularly in the metabolic wasting, the decrease of fat being especially dependent on insufficiency of food.

Etiology.—The causes of fever doubtless vary greatly. Direct exposure to heat does not affect the temperature more than a fraction of a degree in healthy persons, unless the surrounding temperature is very great. Ordinarily the heat-regulating mechanism maintains a proper adjustment. Excessive heat may, however, bring on fever, as in the case of sunstroke. Here, it has been held that the heat leads to direct disturbances of the nervous-regulating apparatus; but recent investigations seem to show that there are first produced toxic substances which secondarily influence the heat-centers of the brain. In another class of cases still more direct disturbance of heat-regulation seems to occasion fever. Among these cases are the instances of fever in hysteria and other nervous diseases.

In the great majority of cases of fever it is quite certain that toxic substances are the cause of the febrile disturbances. These substances may be of quite different sorts. In the case of infections it is known that certain substances contained within the bacteria themselves may cause fever, and that products of the growth of the micro-organisms may have the same effect. The latter are probably bodies of albuminous nature. Other albuminous bodies resulting from normal or disturbed metabolism, independent of the action of bacteria, such as albumoses, peptone, tissue-fibrinogen, etc., may be equally potent; and various ferments, such as pepsin, fibrin-ferment, diastase, etc., are known to have the same power. These facts explain the multiplicity of causes capable of producing fever, as any chemical, mechanical, or bacterial injury of the tissues may liberate toxic substances, which in turn act upon the nervous system and occasion the phenomena of fever.

Pathologic Results.—Fever is accompanied by or leads to a variety of disorders. The appetite is lost, there is excessive thirst, emaciation is habitual, and the functions of the various organs are more or less disturbed. To a large extent these results are doubtless due to the presence of toxic substances in the blood and to other changes in this fluid. There is always a tendency to inspissation of the blood, the number of corpuscles being augmented (relatively) and the specific gravity increasing. This is not, however, invariably the case, as destruction of the solid matters of the blood may exceed the loss of liquid. The alkalinity of the blood is more or less reduced by the production of lactic acid or other acids in the tissue-destruction. There is little accurate knowledge

of the toxic substances in the blood. The original poisons that caused the fever may be toxic for the entire organism, and other poisons may be produced by the elevation of temperature and disturbed metabolism.

Definite morbid changes may occur in the various tissues of the body, notably the muscles, heart, liver, and kidneys. Among these changes are cloudy swelling, fatty degeneration, and coagulation-necrosis. It is unlikely that these changes are the direct result of the increased temperature. More probably they result from the action of toxic substances generated in the course of the fever.

Conservative Effects of Fever.—While fever occasions many disturbances and leads to various pathologic consequences, it is not improbable that there is a certain measure of usefulness in it. Some authors have called attention to the fact that rapid reduction of the temperature under the influence of antipyretics is often followed by harmful consequences. This does not necessarily prove the usefulness of the fever, as the antipyretics are all capable of harm in themselves. A more definite proof of the uses of fever is that obtained by subjecting infected animals to high temperatures or to febrile conditions, and studying the progress of the infection. Under these circumstances it has been found that the course of various infections, such as with the Diplococcus pneumoniæ, the bacillus of typhoid fever, and other organisms, is much milder and the consequences less serious than in animals not placed under the same conditions. These results agree very well with experiments with bacteria outside the animal body. For example, it is known that many of the bacteria are influenced unfavorably in their growth and virulence by excessive temperatures (104° to 107.6° F.; 40° to 42° C.). Whether in the body the temperature affects the micro-organisms directly or indirectly through the production of antitoxic substances, or in other ways, remains unsettled.

CHAPTER III.

DISTURBANCES OF THE CIRCULATION OF THE BLOOD.

GENERAL DISTURBANCES.

THE circulation of the blood is maintained by the rhythmic contractions of the auricles and ventricles of the heart, aided by the elasticity of the arteries; by the compression of the veins by

the muscles; and by the suction of the inspiratory movements of the chest.

General disturbances of the circulation result from lessened or excessive heart-power, from arterial disturbances, or from changes in the quantity or character of the blood. Muscular and respiratory weakness may be contributing causes.

Weak Heart.—There are a variety of heart-diseases that may lead to disordered circulation. The muscle itself may be weakened from overstrain, the fevers or other diseases, the action of poisons, or insufficient nourishment as in the anemias, or in narrowing of the coronary artery. The muscle may be soft and cloudy, fatty, or hardened by sclerotic changes. There may be no evident muscular disease, but functional weakness of the intracardiac ganglia. The valves or orifices of the heart may be diseased, and regurgitation or obstruction of the blood-flow results. Sometimes blood-clots form within the heart and similarly cause obstruction of the current. Finally, pericardial effusions or adhesions or tumors pressing upon the heart may seriously disturb its action.

The result of the weakened state of the heart must be the accumulation of blood in the venous system. The place of engorgement depends upon the part of the heart specially weakened. If the left ventricle fails, the blood backs into the left auricle and the lungs. As long as the right heart maintains its power the venous congestion goes no further; but when this fails repletion of the right auricle and of the systemic veins ensues. When the right heart is first at fault general venous congestion is an earlier manifestation. In all cases the arterial pressure falls and the blood-current is slowed, whereas the venous pressure is increased.

Hypostatic Congestion.—In cases of serious weakness of the heart, in which it is quite unable to maintain an active circulation, the blood tends by the force of gravity to sink to dependent parts. This condition is known as hypostatic congestion. It occurs very frequently in low fevers and quite commonly just before slow death resulting from any cause. Dilatation of the vessels from vasomotor paresis, general muscular weakness, and the failure of vigorous inspiratory efforts are secondary causes.

The blood accumulates in the skin of the back, especially about the buttocks. The skin is of a livid color, but is bloodless over the bony points; the tissues tend to become sodden from transudation of liquid from the blood-vessels. Sloughing and gangrene (bedsores) may result. Internally, hypostatic congestion affects the lungs particularly, and a form of pneumonia may follow.

Post-mortem lividity is allied to hypostatic congestion. After death the blood gravitates to the dependent parts and accumulates

especially in the veins, as the arteries contract as soon as the heart-action ceases. Sudden and complete failure of the heart leads to anemia of the brain and syncope, which may prove fatal if not instantly relieved.

Overaction of the heart is less frequent. Temporary overaction occasions increased activity of the circulation and elevation of blood-pressure, sometimes sufficient to cause hemorrhage. More prolonged overaction due to overwork, to excessive feeding, or to nervous stimulation, as in Graves's disease, causes hypertrophy of the left ventricle, and later of the whole organ. In consequence the circulation may be more or less permanently overactive.

Arterial Disorders.—Both organic and nervous disturbances are important. Of the *organic disturbances* the most frequent is sclerosis of the arteries, which offers a constant impediment to the arterial circulation. Hypertrophy of the heart overcomes the obstacle, but when the heart fails venous congestions and dropsy ensue. Sclerosis may also affect the veins, but much less commonly. Local diseases of the aorta, as congenital narrowing, compression by enlarged glands or tumors, aneurysms, and blood-clots may obstruct the flow of blood to the arteries, and thereby cause stagnation of the blood in the heart, lungs, and venous system.

Vasomotor disturbances are dependent upon the nervous system. Under the influence of certain diseases of the nervous system or of poisons (as carbonic acid gas in asphyxia) acting locally on the vessels or upon the vasomotor center in the brain, contraction of the smaller arterioles occurs; and in consequence the blood-pressure is greatly elevated, the heart is impeded, and venous congestion results. On the other hand, the arterioles may distend from vasomotor paresis, the blood-pressure falls, and unless the heart is active there is a tendency to hypostatic congestion.

Changes in the Blood.—Increase and decrease of the quantity of the blood are generally merely passing conditions to which the circulation readily adapts itself by dilatation or contraction of the vessels. Sudden losses of blood, if large, may be fatal by syncope. Smaller losses are soon repaired by absorption of water from the tissues and by regeneration of blood. Increases in the quantity of the blood by ingestion of liquids never disturb the circulation greatly. Rapid excretion soon reduces the quantity to the normal.

Changes in the character of the blood affect the circulation greatly. The accumulation of carbonic acid and probably other effete products of tissue-change impede the flow by exciting vasomotor contraction. This is probably brought about by the action of the poisons on the terminal nerve-filaments in the blood-vessels or directly on the walls of the vessels. This is the best explana-

tion of the increase of pressure in cases of Bright's disease without arteriosclerosis. The poisons in this case are the retained renal excreta.

LOCAL HYPEREMIA.

Local hyperemia is increase in the quantity of blood in a part of the body. This may be due to increase of the flow to that part, or to obstruction of the outflow. The former is called *active or arterial hyperemia* or *congestion;* the latter, *passive or venous hyperemia.*

Active hyperemia occurs in organs during periods of functional activity, the increased blood-supply here being due to increased demand for nutrition. Pathologically, active hyperemia is due to causes which lead to dilatation of the arteries of a certain part. This dilatation may be due to influences acting through the vasomotor nervous system or to local affections of the vessel-walls. The vasomotor nervous system may be affected at its center in the medulla or peripherally. The latter is seen when the sympathetic nerves, which contain vasoconstrictor fibers, are severed or compressed by tumors, the vessel-walls thereby becoming paralyzed (*neuroparalytic hyperemia*). On the other hand, the vasodilator fibers in the spinal nerves may be stimulated, as in certain cases of neuritis, with a similar result (*neurotonic hyperemia*). Direct injury to the vessel-walls by heat, traumatism, inflammation, drugs, or by the vascular fatigue following temporary stoppage of circulation, is a frequent cause.

Active hyperemia is spoken of as *collateral* when anemia in one part leads to overfilling of the vessels of an adjoining or even distant part.

The hyperemic area is bright red in color, the temperature is elevated, and there is slight swelling. After death the distended arteries and capillaries may contract and the part grows paler. Arterial hyperemia is one of the phenomena of beginning inflammation, and in any case if prolonged may terminate in inflammation. Functional activity is increased by moderate congestions.

Passive hyperemia is due to impediments to the outflow of the blood through the veins. This may be brought about by compression of veins by tumors, by thickening of their walls, or by thrombi within. Little disturbance results from obstruction of a small vein, because of the freedom of collateral circulation, provided the heart is active. In cases of weak heart-power, however, slight obstructions may determine local venous hyperemia, or by gravity alone the blood may sink to dependent parts. The latter constitutes hypostatic congestion (see page 44).

Areas the seat of passive hyperemia are dark red (*cyanosis*) and lowered in temperature. The veins are distended, and very soon

the watery elements of the blood transude and the part becomes edematous and swollen. In severe cases red blood-corpuscles escape by diapedesis. Later fatty degeneration results from the imperfect nutrition of the tissues; or even necrosis and gangrene may occur. In long-continued moderate passive hyperemia overgrowth of connective tissue and pigmentation of the tissue by broken-down blood-corpuscles is observed (brown induration).

FIG. 1.—Stasis of blood in the superficial vessels in a case of valvular disease and heart-failure (modified from Ziegler).

Complete stoppage of the circulation in a localized area is called *stasis* (Fig. 1). This may be an extreme grade of passive hyperemia. The blood-corpuscles accumulate in the small vessels (arteries, capillaries, and veins) and the plasma is slowly pressed out of the vessels or onward. There results a filling of the vessel with a homogeneous red material, which is composed of the red corpuscles so closely packed as to be indistinguishable. On relief of the stasis the corpuscles become free again. Stasis may also be produced by chemical agents which rapidly withdraw the plasma from the vessels, leaving the corpuscles unable to circulate; or similarly by rapid evaporation of the liquor sanguinis from internal structures (as the peritoneum) exposed to the air.

Passive congestion of any grade and stasis interfere with functional activity in two ways: by the reduction of nutrition of the cells and by the pressure exercised upon them by the accumulating blood and serum.

LOCAL ANEMIA.

Local anemia or ischemia is the condition in which a tissue contains less than its proper quantity of blood. This may be *direct* when it results from causes obstructing the flow into the arteries, or *collateral* when it is due to withdrawal of blood into hyperemic areas in other parts of the body. Of the causes acting directly, pressure is the most frequent. There may be general pressure upon an organ or localized area of the body, as in the application of elastic bandages; or pressure upon the vessels within the tissue itself, as in amyloid disease, the amyloid substance compressing the arteries and capillaries, or there may be direct compression of an artery by tumors. The circulation in an

artery may be impeded by sclerosis of the vessel-walls and by emboli or thrombi within the vessel. Local anemia of moderate or even severe grade may be due to nervous influences acting through the vasomotor system, as in the earlier manifestations of Raynaud's disease. Collateral anemia is well illustrated by the anemia of the brain occurring in animals in which the splanchnic nerves have been cut, with the consequent production of abdominal hyperemia. When ischemia is due to obstruction of a single vessel the circulation is generally soon restored by collateral anastomosis; the collateral vessels sometimes reach considerable dimensions (Fig. 2). When an artery which has few anastomoses and which soon splits up into capillaries is obstructed the phenomena of infarction (see page 53) ensue.

FIG. 2.—Anastomoses three months after ligation of the femoral artery of a dog (Porta).

An anemic area is pale, reduced in size and temperature, and functionally less active than normal. If the condition persists, fatty degeneration and necrosis result. When a severe local anemia is relieved it is apt to be followed by hyperemia of the same area, due to exhaustion or degenerative weakness of the vessel-walls.

HEMORRHAGE.

By hemorrhage is meant the escape of the several constituents of the blood from the blood-vessels. It is said to be *arterial*, *venous*, or *capillary* according to the vessel from which the flow of blood takes place, and *parenchymatous* when it comes from all of the vessels. Hemorrhage may occur either by diapedesis and extravasation through intact vessels (*hemorrhage per diapedesim*) or by actual rupture of a vessel (*hemorrhage per rhexin*). The former process is seen only in the capillaries and smaller veins; the latter occurs mainly in the arteries and veins.

Diapedesis and Emigration.—Under normal conditions a certain number of white corpuscles by virtue of their ameboid movements escape from the capillaries, and become wandering cells which move about in the tissues or are carried by the lymph-stream. This process is called *emigration*. There is at the same time some transudation of plasma, which, with the leukocytes, enters the lymphatic circulation. Under certain abnormal conditions the red corpuscles also pass through the vessel-wall and collect in the tissues. This is known as *diapedesis* (Fig. 3). It may be studied very readily under the microscope in the mesentery of a

living frog. It is noticed that the red corpuscles approach certain parts of the wall of the capillary or vein and become fixed; then a small projection appears outside the vessel, opposite the corpuscle, and as this increases the corpuscle within grows smaller, until the whole body has gradually passed through. Not rarely several

FIG. 3.—Diapedesis of the red blood-corpuscles through a capillary of a frog's tongue (after Thoma).

corpuscles pass through in one mass; as has been particularly noted by Thoma. Outside the vessel the corpuscle at once assumes its ordinary shape.

Diapedesis was first studied by Stricker and Cohnheim. Arnold, whose investigations are most important, first believed that the emergence of the red corpuscles takes place through orifices or stomata; but later recognized, as is now generally believed, that the supposed stomata are merely accumulations of intercellular substance in certain places between adjoining endothelial cells or at the junction of several cells. The active cause of the extrusion of the red corpuscles is the pressure of the blood.

The leukocytes emigrate from the vessel in exactly the same way as the red corpuscles, but mainly by their own ameboid movements. At the same time there is a more or less copious outflow of plasma.

Diapedesis is readily induced by mechanical compression of a vein, which elevates the blood-pressure; or it may follow elevation of blood-pressure from any other cause. On the other hand, with normal pressure increased permeability of the vessel-walls may occasion diapedesis. Such degenerative conditions of the vessels may be due to the action of poisons, to various infectious diseases, to moderate traumatism, or to temporary obstruction to the flow of blood into a certain area. Perhaps also altered states of the blood may play a part when both the vessels and pressure are normal. Hemorrhages by diapedesis are generally small and punctate (petechiæ), but may be quite large, as sometimes in the conjunctiva.

Causes of Hemorrhage.—The ordinary form of hemorrhage *per rhexin* may be due to traumatism, to diseases of the

vessels, to increase of the blood-pressure, and to certain vague nervous influences.

1. **Traumatic hemorrhage** may be due to direct laceration of a vessel or to contusions which merely weaken the vessel-wall and lead to subsequent rupture.

2. **Diseases of the blood-vessels** causing hemorrhage generally originate from causes within the vessel, and are due to such conditions as poisoning, infectious fevers, cachexias, or the anemias. Among the diseases of the vessels are fatty degeneration of the intima or media, atheroma, and miliary aneurysm. On the other hand, the outer coat may be eroded by surrounding disease and hemorrhage ensue (hemorrhage *per diabrosin*). This is seen in phthisical cavities in the lungs.

3. **Increase of blood-pressure** may be absolute or relative. The former occurs from emotional excitement, from hypertrophy of the heart, during paroxysms of whooping-cough, croup, and various convulsive disorders. In asphyxia there is decided increase of blood-pressure both from vasomotor contraction and from the violent muscular efforts. Relative increase of pressure occurs when the pressure external to the vessel is reduced, as in balloon ascension, or in the pleura in cases where during violent inspiratory efforts the air cannot enter the lungs, as in the fetus attempting to breathe during labor.

4. **Neuropathic Hemorrhage.**—The nervous system exercises a peculiar influence upon the vessels. In cases of apoplexy and epilepsy, of section of the spinal cord, and in other nervous conditions, spontaneous hemorrhages from the nose or stomach, or into the lungs, suprarenal bodies, and other organs, are not infrequent. In the same group also are to be reckoned the instances of vicarious hemorrhage due to suppression of the menses, and the remarkable cases of stigmatization. The last named is a condition in which under nervous exaltation or hysteria spontaneous hemorrhages occur from various parts of the body, especially from the parts wounded in the crucifixion.

5. **The Hemorrhagic Diathesis.**—Certain persons present an inherited tendency to bleed spontaneously or after very trivial injuries. Such persons are known as "bleeders," and the condition as *hemophilia*. The exact pathologic condition which occasions the hemorrhages is still uncertain. A hemorrhagic diathesis may also be developed as a result of various diseases, as typhus fever, anthrax, septicemia, or phosphorus-poisoning. The same is observed in the severe forms of anemia, like progressive pernicious anemia and leukemia. In these cases altered blood states and disease of the vessel-walls are doubtless the causes at work.

Classification of Hemorrhages.—Hemorrhage may occur on free surfaces or into the tissues. In the former case various names are applied to designate the locality, such as *epistaxis*, nose-

UNIVERSITY OF CALIFORNIA LIBRARY

bleed; *hemoptysis*, hemorrhage from the lungs; *hematemesis*, from the stomach; *enterorrhagia*, from the bowel; *metrorrhagia*, uterine hemorrhage between, and *menorrhagia* at, the menses.

Hemorrhages into the tissues take their names from the size and nature of the lesion. A hemorrhagic infiltration beneath a surface, as of the skin or mucous membrane, is called an *ecchymosis*, which if small and well defined is a *petechia*, but if large and diffuse, a *suggillation* or *suffusion*. A distinct accumulation of blood, constituting a veritable blood-tumor, is known as a *hematoma*. Infiltrations of a peculiar sort, involving localized portions of a tissue or organ, are known as *hemorrhagic infarcts* (*q. v.*).

Results of Hemorrhage.—A very large hemorrhage may lead to sudden death by cerebral anemia. More frequently the patient remains unconscious for a time and then slowly recovers. The hemorrhage ceases spontaneously by the diminution in heart-action, by clotting of the blood at the point of rupture, by retraction of the elastic vessels, and by pressure of the surrounding tissues. Blood extravasated in the tissues soon coagulates and subsequently undergoes disorganization, the red corpuscles breaking down into pigment-matter, which may be carried away or deposited at the seat of hemorrhage. The fluid elements may be completely absorbed, or, stained with coloring-matter, may remain as a cyst. A focus of hemorrhage may set up reactive inflammation and lead to encapsulation by new connective tissue. Sometimes hemorrhagic accumulations become inspissated and undergo calcification. Blood in the serous sacs does not readily coagulate, but mingles with the normal liquid secretion. It may be gradually absorbed or may undergo degenerative changes, especially when infected by micro-organisms. Large hemorrhages cause acute anemia; repeated small extravasations may lead to profound secondary anemia. (These conditions will be more fully discussed under Diseases of the Blood.)

EMBOLISM.

Embolism is the process in which foreign bodies of various kinds are carried in the blood and deposited in the smaller arteries or capillaries through which their size does not permit them to pass. The bodies deposited are called *emboli*.

Sources and Nature of Emboli.—The most common form of embolism is that in which portions of thrombi situated in the heart, the large veins of the extremities or pelvis, or on atheromatous patches in the aorta, are swept into the circulation and lodge in the smaller vessels. Softening of the original thrombus is generally the immediate cause. More rarely portions of a diseased heart-valve or of the intima of the heart or arteries, liver or placental cells, or parts of tumors, are carried in the circulation

and deposited as emboli. Disorganization of the blood may cause embolism of pigment-particles, as in malaria, or of small hyaline masses, as in burns and certain forms of poisoning. In cases of fracture of bones particles of fat may be dislodged from the marrow and enter the circulation, while in wounds of the large veins of the neck or elsewhere air-embolism is observed. Finally, masses of bacteria, scolices of echinococcus, and other parasites are a serious form of emboli.

Seats of Embolism.—The final place of lodgement of an embolus depends mainly on its source. Those derived from the general venous circulation are usually carried through the right heart to the lungs, where they occlude branches of the pulmonary artery. Emboli in the portal circulation may lodge in the liver, or pass through the liver to the heart and lungs. In cases of whooping-cough or other conditions attended with increased intrathoracic pressure emboli in the inferior vena cava may be carried in the direction opposite to the usual blood-current, and may be conveyed into the liver through the hepatic veins. This is known as *retrograde embolism.*

Emboli coming from the left heart or from the aorta are distributed in the general arterial circulation. They are most frequently found in the spleen, kidneys, and brain. Other organs or the peripheral vessels may likewise be affected, but the results of embolism are less marked in them and are frequently overlooked. Emboli from the veins may reach the general circulation in cases in which the foramen ovale or septum ventriculorum is perforated (*paradoxic embolism*), or by being broken up into smaller emboli in the lungs and thus passing through the pulmonary capillaries. The latter is not infrequent in cases of fat-embolism of the lungs.

Results of Embolism.—A large embolus may cause sudden death by occluding one of the main branches of the pulmonary artery, one of the coronary arteries, or a large cerebral vessel. If the vessel is not wholly occluded, secondary thrombosis may complete the obstruction and death may be slow; or in the case of less important vessels merely local anemia results. This may be relieved by establishment of collateral circulation or may cause more or less extensive necrosis if not relieved. The original embolus and the secondary thrombus may undergo softening or organization in the same manner as ordinary thrombi (*q. v.*).

The results of occlusion of smaller vessels by emboli depend on the nature of the embolus. They are either purely *mechanical* when the embolus is aseptic, or *septic* when the embolus is infectious. The important mechanical result of small emboli is the pathologic condition called *infarction.*

INFARCTION.

Infarcts occur in situations in which there are small arteries having only capillary or at most very slight arterial anastomosis with neighboring arteries. Such arteries were called *endarteries* by Cohnheim. They are found especially in the kidney, spleen, lungs, retina, base of the brain, and parts of the heart. When one of these is occluded by an embolus infarction occurs.

FIG. 4.—Anemic infarct of the kidney: the embolus, occluding a branch of the renal artery, is shown in the lower part of the picture (Perls).

Infarcts may be *hemorrhagic* or *anemic*. The former are dark red in color, situated in the peripheral part of the organ, and harder than the surrounding tissue. They are wedge-shaped, the base being outward toward the periphery of the organ. Infarcts may result sometimes from occlusion of a number of adjoining arterioles or capillaries, and in this case are irregular in outline. Anemic or white infarcts present the same general features, but are less elevated and are yellowish or grayish in color. They are frequently surrounded by a zone of congestion or hemorrhage (Fig. 4).

Formation of Infarcts.—The first effect of occlusion of an endartery by an embolus is stoppage of the circulation beyond the embolus. A wedge-shaped anemic area results. This may remain anemic and undergo coagulation-necrosis, with the formation of an *anemic* or *white infarct*. In other cases, however, the vessels of the occluded area, after a temporary period of anemia, become overfilled with blood, extravasation occurs, and an *hemorrhagic infarct* results. Various theories are offered to explain the persistence of anemia in the first case and the overfilling with blood in the second. In anemic infarcts the persistent anemia in some cases is due to thrombosis in the venules which receive the blood from the occluded endartery and in the anastomotic capillaries. At times rapid swelling of the parenchymatous cells of the organ compresses the capillaries and maintains the anemia. Some contend that white infarcts are frequently formed by rapid absorption and removal of the coloring-matter of the blood from hemorrhagic infarcts. In the latter the overfilling of the vessels results either from a backflow of blood from the veins (Cohnheim) or from free capillary-anastomosis. The latter would be especially apt to occur when the general or local blood-pressure was previously elevated, or when the lodgement of the embolus caused reflex contraction of the surrounding vessels, and thus overflow of blood into the occluded area through the capillary-anastomosis. The hyperemia

thus produced soon leads to extravasation of blood, because the vessels of the occluded areas rapidly undergo degenerative changes. Infarcts in the lungs are nearly always hemorrhagic; those in the kidneys and especially the spleen are frequently anemic.

Subsequent Changes.—In anemic infarcts coagulation-necrosis and caseation are the marked degenerative changes. The broken-down tissue is gradually absorbed and reactive inflammation and organization cause cicatrization. Not infrequently a small amount of calcareous matter is deposited, especially in infarcts of the lungs. In hemorrhagic infarcts the extravasated blood breaks up into pigment-matter and the tissues suffer degenerations similar to those seen in anemic infarcts. The final result in either case is generally a scar, which is pigmented in cases of hemorrhagic infarcts. More rarely infarcts undergo liquefaction and cyst-formation, especially in the brain. The infarct may become infected by micro-organisms after its formation and abscess may result, as in cases in which the embolus itself was an infectious one.

Infectious embolism occurs in cases of purulent softening of thrombi, in cases of local suppuration or necrosis, in ulcerative endocarditis, and the like. The first effect may be the formation of a hemorrhagic or anemic infarct; but the micro-organisms soon multiply and invade the tissues, causing suppurative or gangrenous processes. Metastatic abscesses are produced in this manner. Similar results follow when an infarct is secondarily infected. This is not infrequent in the lungs, where the air-passages furnish a ready path for the entrance of micro-organisms.

Dust-embolism.—Small particles of coal, iron, marble, or clay entering the lungs in respiration may penetrate the tissues, are largely taken up by phagocytic cells, and for the most part are carried to the bronchial lymphatic glands. If the latter are surcharged and soften, the dust-particles may gain access to the circulation through the efferent lymph-channels of the gland or by rupture of the gland into neighboring veins. More rarely dust-particles may enter the blood-vessels in the lungs, directly, by penetration. After their entrance into the blood they are deposited in the capillaries and substance of the liver, spleen, and bone-marrow, where they may remain permanently, either free or enclosed in fixed cells, or whence they may be removed by wandering cells. The final discharge occurs especially from the lungs, the tonsils, the lymphatic structures of the intestines, and from the liver in the bile.

Air-embolism.—Small quantities of air may occasion no serious disturbances; but when large quantities enter the veins the right heart is found full of frothy blood and the pulmonary arterioles are occluded by small bubbles. Sudden death in these cases is not unusual. Some recent experiments in dogs seem to cast doubt on the seriousness of air-embolism, but the matter is not yet settled.

Fat-embolism.—Sudden death may occur when a large number of the pulmonary vessels are obstructed by embolic oil-drops. When the process is less extensive little disturbance arises, as the oil is soon broken up into droplets and passes through the pulmonary capillaries, or it may be absorbed in the lungs.

Pulmonary infarcts may be due to embolic occlusion of the blood-vessels,

but also to obstruction of a bronchiole. Any kind of hemorrhagic extravasation in the lungs may assume a wedge-shape, because the area infiltrated is the wedge-shaped area included in the divisions of a terminal bronchiole. (For details, see the chapter on the Lungs.)

THROMBOSIS.

Thrombosis is the coagulation of blood within the blood-vessels or heart during life. At the very beginning of the process the formation is not a coagulum in the ordinary sense, but subsequently coagulation is the essential feature. After death clots form within the heart and vessels, as in blood removed from the body.

Causes.—The conditions favorable to thrombosis are alterations in the blood-current, changes in the vessel-walls, and alterations in the blood itself. For the most part two or all of these conditions are present in cases of thrombosis.

Alterations in the Blood-current.—Anything which slows the current, such as narrowing of the blood-vessels, weakness of the heart, or pressure upon the vessels, favors thrombosis. Complete arrest of the current in a part may lead to ordinary clotting, such as occurs post-mortem; but with careful precautions a vessel may be ligated at two points without the occurrence of clotting in the occluded portion—at least for a long time. Some change in the blood-vessel wall is generally necessary in addition. Thrombi due to slowing of the current are frequently seen in the heart, the vessels of the lower extremities, and in the sinuses of the brain in the course of exhausting fevers or other asthenic conditions. They are called *marantic thrombi.*

Changes in the vessel-walls play an important part. Atheroma, inflammatory or degenerative changes in the vessels of areas of inflammation or necrosis, ligation and other traumatic injuries, and diseases of the endocardium are all examples of conditions leading to thrombosis. Dilatation of the arteries (aneurysm) or veins (phlebectasia) or of the cavities of the heart act largely by slowing the current of blood or by producing irregular currents.

Alterations in the Blood.—Experimentally, thrombosis may be induced by injection into the circulation of extracts of the thymus gland, the suprarenal bodies, the testicles, and other organs. These extracts contain large quantities of the fibrin-ferment regarded by Schmidt as an essential factor in coagulation. Pathologically, it is probable that the tendency to thrombosis in typhoid fever, sepsis, and other diseases is due to increase of similar fibrin-forming factors in the blood. The name *fermentation-thrombosis* is applied in these cases.

According to Schmidt, coagulation is due to the reaction of fibrinogen (derived from the plasma) with fibrinoplastin under the influence of a fibrin-ferment (the two latter derived from the leukocytes). Fibrinoplastin is probably not essential (Hammarsten), while calcium salts are (Arthus and Pages).

Pathologic Anatomy.—The appearance and construction of thrombi depend upon the manner of formation.

When formed in consequence of almost complete stoppage of the circulation they are dark-colored, soft, *red clots*, similar in every way to post-mortem coagula; and under the microscope show fibrillar fibrin enclosing mainly red corpuscles.

Yellowish or white thrombi are formed slowly from actively circulating blood and are more consistent. Their composition will be understood from the mode of formation. In the normal circulation the red corpuscles and blood-plaques move in a column in the center of the stream, separated from the wall of the vessel by a plasmatic zone in which the leukocytes may be seen. When the circulation is slowed the plaques approach the vessel-wall and tend to adhere in small masses to any point of disease in the endothelium and also to each other. This has been termed *conglutination* of the blood-plaques. Gradually the mass grows and subsequently leukocytes are added. These set on foot true fibrin-formation or coagulation. White thrombi therefore consist of conglutinated plaques, leukocytes, and fibrin. They first appear as hyaline, viscid masses; but subsequently become granular from partial disintegration. If the circulation is alternately slow and more rapid, distinct layers are seen in the thrombus, first dark colored from admixture of red corpuscles, then lighter in hue. Such thrombi are called *stratified*. If the circulation is irregular from dilatation of the vessels or other causes, the light and dark areas of the thrombus may be more irregularly disposed.

The thrombus first formed is the *primary thrombus*. Subsequently it extends by additions (*secondary thrombus*) in the direction of the current of blood as far as the next collateral branch of the vein or artery, into which the thrombus frequently extends as a rounded prominence. In the case of the veins a new thrombus may start from such projection (Fig. 5), and eventually the clot

FIG. 5.—Thrombus in the femoral vein in a case of phlebitis (from a specimen in the Museum of the Philadelphia Hospital).

may extend as far as the heart. The thrombus may be *lateral*—that is, when it lies against the vessel-wall—or *obstructive*, when the lumen is completely obliterated. In the veins small thrombi are frequently formed in the valvular pouches in marantic subjects.

In the heart thrombi are especially common on diseased valves, in the auricular appendages, and in the intertrabecular spaces. They frequently appear as polypoid masses, and may be attached by slender pedicles. A curious form, called *ball thrombi*, is seen in the auricles. These are rounded clots wholly or almost wholly separated from the wall, and may occasion serious obstruction at the orifices of the heart.

Effects.—Frequently the collateral circulation is so quickly established that no untoward results are seen. When a large vein is obstructed venous congestion and dropsy may follow; obstruction of an artery causes local anemia, and subsequently, if the collateral circulation is not established, degenerations or necrosis. Thrombotic obstruction of small arteries may cause hemorrhagic infarction. Embolism and general pyemia result from softening of the thrombus.

Subsequent Changes.—After their formation all thrombi contract. In this way the red forms may become light colored by extrusion of the red corpuscles. In small vessels red thrombi often become light colored by removal of hemoglobin and a species of hyalin-transformation. These may have the appearances of white thrombi and are only distinguished by careful examination.

After the thrombus has contracted it may undergo various degenerative changes. Frequently the white corpuscles, plaques,

FIG. 6.—Thrombosis in cardiac chambers, showing cyst-like structure (Orth).

FIG. 7.—Branch of the brachial artery after amputation, showing vascularization of the thrombus, *Th* (Weber).

and fibrin are broken down into an emulsion by liquefaction-necrosis and fatty degeneration, and the red corpuscles converted into granular pigmented masses. These softened portions are swept into the circulation and occasion embolism. Frequently

this form of *simple softening* occurs in the center of large thrombi and gives rise to cyst-like formations (Fig. 6).

A more serious form of softening occurs when the thrombus is infected by micro-organisms. In this case true *purulent softening* takes place, and the wall of the blood-vessel shares largely in the suppurative processes. This form occurs especially in the thrombi blocking blood-vessels of suppurating or necrotic tissues. General pyemia and infectious embolism result.

FIG. 8.—Canalization of a thrombus (Karg and Schmorl).

A more favorable termination of a thrombus is *calcification.* This is most frequent in the clots in dilated veins, the calcareous thrombi being known as *phleboliths.* *Arterioliths* and *cardioliths* are rarely met with.

Organization of the thrombus may result from the irritation it occasions. New blood-vessels and proliferating connective-tissue cells spring from the vasa vasorum and lining membrane of the blood-vessel as well as from endothelial cells covering the thrombus, and penetrate the thrombus (Fig. 7). From these organization proceeds as elsewhere, and as it advances the thrombus itself is absorbed. Finally, the clot is fully replaced by connective tissue enclosing a small amount of blood-pigment or calcified remains of the thrombus. The blood-vessel may be converted into a solid fibrous cord, or may be distorted and narrowed by bands of connective tissue in the interior. Sometimes after partial vascularization of a thrombus small vessels running parallel with the lumen of the obstructed vessel become dilated and thus partly re-establish the channel. This is termed *canalization* of the thrombus (Fig. 8). In other cases canalization may begin as a process of simple softening.

EDEMA.

Definition.—The term edema is applied to a condition in which the liquid within the tissues is increased in quantity.

Etiology.—It is primarily necessary to understand the methods by which the liquids normally present in the tissues escape from the blood-vessels, their original source.

Several processes are concerned in this escape of fluid. In the first place, the pressure of the blood serves to cause a certain amount of *direct filtration*, just as liquid enclosed in tubes of permeable animal-membrane escapes when the pressure outside is less than within. In this process of direct filtration the state of the tissues themselves plays a part. If the normal elasticity of the tissues and degree of pressure of the liquid in the interstitial spaces are lowered, liquid escapes through the capillary-walls to equalize the pressure. A second process at work is that known as *diffusion* or *osmosis*. In this there is an exchange between the blood and the tissue-liquids, certain substances being taken into the blood in exchange for water and other constituents of the blood-plasma. The liquid thus discharged from the blood-vessels enters into the metabolic activity of the tissues to a greater or less degree, is somewhat altered in character, and the surplus is carried off in the lymphatic capillaries as *lymph*. Certain physiologists (Heidenhain *et al.*) believe that there is a farther and very important factor of a vital sort. This is described as an active secretory function of the endothelial cells of the capillaries and lymphatic spaces; so that, according to this view, lymph-formation is in a measure at least a direct secretion. This view is not generally accepted.

Briefly, then, lymph-formation may be described as the escape of water and other substances through a more or less permeable membrane, the capillary-walls, in consequence of direct filtration and osmosis. The quantity present in the tissues depends upon the quantity escaping from the blood-vessels and the amount carried away by the lymphatic circulation.

The causes of increased accumulation of liquid in the tissues may then be readily determined. Among these are (*a*) increase of blood-pressure, or (*b*) decrease of tissue-elasticity and pressure; (*c*) alterations of the blood rendering it more diffusible, or (*d*) of the liquids in the tissues increasing the osmotic power of these; (*e*) increased permeability of the walls of the blood-vessels; (*f*) obstruction to the flow in the lymphatic vessels. These causes will be considered separately with reference to certain well-known clinical types of edema.

(*a*) **Increased blood-pressure** always occasions increased escape of liquid from the vessels (transudation) and thus increased formation of lymph. In active hyperemia with excess of pressure the amount of liquid rarely becomes so great that the lymphatic vessels cannot carry it off, and edema does not therefore occur. In passive congestions, however, as in heart-disease, pressure upon veins, etc., the escape of liquid becomes more rapid and copious, and the lymphatic circulation is insufficient. Edema or dropsy results. In this process of direct filtration the transudate consists

mainly of the water and saline constituents of the plasma and to a relatively small degree of the albuminous constituents.

(*b*) **Decreased tissue-elasticity and pressure** is rarely a factor of prime importance, though it may be a contributing cause in many cases. In one class of cases termed œdema ex vacuo it is the principal cause. In these cases liquid escapes from the blood-vessels to fill a space left vacant by disease or atrophy of tissue-elements. This is frequently seen in the subarachnoid spaces of the brain and in other parts of the central nervous system.

(*c*) **Alterations of the blood,** though theoretically very important as direct causes, probably act indirectly. It has been found by experiment that artificial hydremia, even though combined with considerable increase of the bulk of blood, does not cause edema unless by some means the walls of the blood-vessels have been injured. It is probable, therefore, that the edema of anemic and marantic persons is similarly due to increased permeability of the vessels. This in itself might occasion edema, though the degree is probably greater as a consequence of the anemic state of the blood. The vascular disease itself is probably in some way (perhaps by the action of circulating toxic substances) brought about by the condition of the blood.

(*d*) **Alterations of the liquids of the tissues** may, conceivably, occasion increased diffusion of liquid, but practically little is known of the operation of this element. There are, however, certain cases in which disturbed metabolic activity of the tissues seems to alter the tissue liquids in such manner as to favor the development of dropsy.

(*e*) **Increased permeability of the capillary-walls** is of great importance and probably plays a part in every case of edema. Experimentally it is easy to prove that this factor alone may cause pathologic transudation. Applications of heat to a part or the introduction of poisons capable of causing disease of the walls of the blood-vessels may thus occasion edema. Clinically this factor is of importance in the edema of Bright's disease. Formerly the dropsies of renal disease were attributed to hydremia, but the experiments cited above show this factor to be insufficient. On the other hand, changes of the vascular system are known to occur in Bright's disease, and particularly in cases usually attended with marked edema (glomerulonephritis). Changes in the blood may, of course, contribute, as may also stasis due to cardiac weakness.

Disease of the capillary-walls is also an important cause of edema in and about areas of inflammation (inflammatory edema). In these cases the toxic products of inflammation doubtless attack the walls of the vessels and render them more porous. Such edema may occur only in the vicinity of an inflamed area, or may be quite widespread. Thus in some cases edema of the lungs and

other internal organs may be occasioned by bacterial toxins derived from a distant focus of infection.

Cases of hereditary edema have been described. These may owe their origin to a congenital excess of vascular permeability.

Finally, there are cases of edema in which the nervous system seems to exercise an influence. Among these are the dropsies attending cases of neuritis, neuralgia, or organic diseases of the cord. In these instances changes in the blood-vessels and perhaps in the tissue-elasticity may be important causes. An interesting form of this sort is that known as angioneurotic edema, in which local edema of various forms (often as giant-urticaria) makes its appearance under the influence of nervous irritations.

(*f*) **Obstruction of the lymphatic circulation** does not ordinarily occasion edema, because the collateral circulation is sufficient to carry away the lymph. When, however, larger trunks, especially the thoracic duct, or numerous smaller lymphatics are obstructed edema may result. This is observed in the chylous ascites due to obstructions of the thoracic duct and in the edema of elephantiasis.

Pathologic Anatomy.—Edema may take various forms according to its situation. In some cases it is localized, affecting a limited part of the body, as a single organ or member. In other cases it is widespread in the subcutaneous tissues and skin, when the term anasarca is applied. It may occur in the serous cavities in the form of serous transudates (hydrothorax, pleural effusion, hydropericardium, etc.).

The liquid itself varies in character according to the cause. In the pure transudates due to increased filtration the liquid is watery, low in specific gravity (below 1016), and comparatively poor in blood-corpuscles and albuminous constituents. In cases in which disease of the vessel-walls has played a large part in the causation, especially in the inflammatory edemas, the liquid is more dense and contains more corpuscles and albuminous bodies.

The transudate first occupies the lymph-spaces or interstices of the tissues, causing a more or less uniform swelling and bogginess. The tissue pits on pressure, and on section more or less abundant liquid exudes. The solid organs (kidneys, liver) are lighter in color, less dense, and more moist on section than normal; but the appearances of edema are here less characteristic than in the subcutaneous or submucous tissues, or in the softer organs like the lungs and brain.

Microscopically the tissue-elements are seen to be pushed apart by the transudate, and in some cases the cells themselves may be diseased (see Dropsical Infiltration).

Results of Edema.—The function of edematous parts is necessarily impaired. Sometimes serious consequences ensue, as in the case of edema of the epiglottis, the lungs, or the brain.

Secondary changes may occur in parts the seat of continued edema. Among these are various degenerations of the cells and a productive change in the connective tissues. The latter is well illustrated in the sclerotic change in the subcutaneous tissues of long-standing dropsy, elephantiasis, etc.

CHAPTER IV.

RETROGRESSIVE PROCESSES.

ATROPHY.

Definition.—Atrophy is a condition in which a tissue or organ undergoes a more or less uniform diminution, without definite disease of its constituent parts. A condition allied to atrophy is that termed *hypoplasia*, in which certain parts fail of their normal development. There may be entire absence of a part, and to this the term *aplasia* may be given. Hypoplasia is frequently seen in the vascular system, affecting the heart and great vessels conspicuously, but probably also all parts of the system. This occurs in some cases of chlorosis and in other conditions characterized by constitutional weakness or want of development, such as in those predisposed to tuberculosis.

Etiology.—The causes of atrophy may be varied. It occurs as a result of want of functional demand, as in the atrophies affecting palsied limbs; and sometimes as a result of disturbances of the trophic nervous system, as in diseases of the anterior horns of the spinal gray matter. In the latter instances lack of use is a contributing cause. In the involution processes of old age there is more or less general atrophy, which might be designated as physiologic. Similar normal or physiologic atrophy occurs in certain organs before the general manifestations of old age. Thus the atrophy of the thymus-gland in early childhood and of the genital organs at the menopause are instances of cessation of function, and consequent or concomitant atrophy of physiologic character. Atrophy may be more definitely pathologic, and the result of distinct causes, such as want of local or general nourishment by occlusion of the vessels, pressure, etc. In these cases the process may be purely atrophic, or there may be distinct degenerative disease of the cells with diminution of bulk.

Pathologic Anatomy.—Atrophy may be *simple* or *numerical*. In the former kind, to which the term true atrophy might also be applied, the individual cells decrease in size without manifest dis-

ease; in the latter the cells are reduced in number, and are usually first altered by some form of degenerative disease, so that the process is not, strictly speaking, true atrophy. The parenchyma of organs suffers first and most characteristically, the connective tissues remaining unaffected or even undergoing hyperplasia. In true atrophy the cells may present no definite alteration, excepting perhaps slightly increased pigmentation. This is sometimes due to the fact that the normal pigment of the cell does not suffer reduction as do the other constituents of the cell, but in other cases there is actual deposition of pigment (hematogenous). Cases of the latter kind are designated as *brown atrophy* (Fig. 9). This is seen most strikingly in the heart-muscle in advanced old age or in persons dead of some chronic cachectic disease. In some of the conditions generally described as atrophy the cells show degenerations of various forms, such as cloudy swelling, coagulation-necrosis, fatty degeneration with vacuolization, and other gross alterations of structure.

FIG. 9.—Brown atrophy of the heart-muscle.

Secondary degenerative changes may occur in the connective tissues after the parenchyma-cells have become atrophic. Thus, after the physiologic atrophy of the thymus-gland has occurred the connective tissues of the gland and of the surrounding parts become converted into fatty tissue. In other cases myxomatous change may be observed.

Organs which have undergone atrophy are often quite irregular on the surface from unequal involvement of the different constituents. The consistency may be little changed or may be greatly reduced, particularly when some form of cellular degeneration is present. On the other hand, the organ may be hard and tough from secondary hyperplasia of the connective tissue. The capsule is generally wrinkled from the shrinkage of its contents, and secondary thickening is not unusual, especially in the heart and spleen. The color of the organ, like that of the individual cells, often becomes darker than normal and may be decidedly changed in brown atrophy.

In cases of pressure-atrophy various distortions of the affected organ may be observed. These are particularly marked in the livers of women who have laced excessively. The right lobe of the organ often presents a deep groove or furrow corresponding with the lower border of the ribs, and each of the ribs with which the organ comes in contact may cause a depression.

Pathologic Physiology.—The function of an atrophic organ is necessarily impaired. In the atrophies of old age this may be of little consequence, as the functional demand grows less

and less. In premature atrophies general as well as local disturbances may occur. These disturbances vary with the varying functions of the organs, and will be separately discussed.

THE DEGENERATIONS.

The general term degeneration is applied to changes in the tissues by which their integrity is altered in the direction of lowered vitality. There may be a conversion of the protoplasm of the cell into substances abnormal to it either in kind or quantity. This is termed *degeneration* in a narrower sense. In a second class there are deposited in the cell, from the blood or other fluids of the body, substances abnormal to the cell in kind or quantity. The name *infiltration* is applied to these processes. In individual cases it is often difficult to distinguish between the two varieties.

CLOUDY SWELLING.

Definition.—Cloudy swelling, also termed albuminous infiltration and parenchymatous degeneration, may be defined as an edema of the cellular protoplasm, with alterations in the protoplasmic proteid and the production of opacity.

Etiology.—Cloudy swelling is an almost universal accompaniment of inflammations. Circulatory disturbances (anemia) were formerly supposed to be important, but are now considered to be of little significance. Fever *per se* can produce cloudy swelling, probably not so much the result of the simple degree of heat as of metabolic disturbances induced thereby. The most frequent cause of cloudy swelling is intoxication, either by bacterial toxins, as in the infectious and septic conditions, or by innumerable organic and inorganic substances. Cloudy swelling is also caused by nutritional disturbances; starvation of an organ will produce it as the first stage of atrophy; and, on the contrary, the cells may in other cases be so overloaded with nutritional substances as to become temporarily transformed into this condition, as in the glandular epithelium of the liver during active digestion. It is further known that excessive cellular activity may result in a cloudiness of the protoplasm, as in the kidney and in glands excited by nervous stimulation. These latter processes should be viewed as normal phenomena, analogous to the physiologic fatty degenerations.

Pathologic Anatomy.—The swollen cells present a fine opacity which under high powers is seen to be due to the presence of diffused refractile granules (Fig. 10). The normal protoplasmic granulations have disappeared; in muscle-fibers the striations are obscured or obliterated. Vacuolation may be seen in the late stages. The cell-wall becomes indistinct, so that the cells appear to have coalesced. The nuclei may be little altered. Generally the chromatin becomes diffusely stained; it may elect the acid-stains

or may refuse all staining. Marked nuclear degenerations are not seen in simple cloudy swelling, or at least very rarely. In late stages the entire cell may have lost its normal reactions to stain-

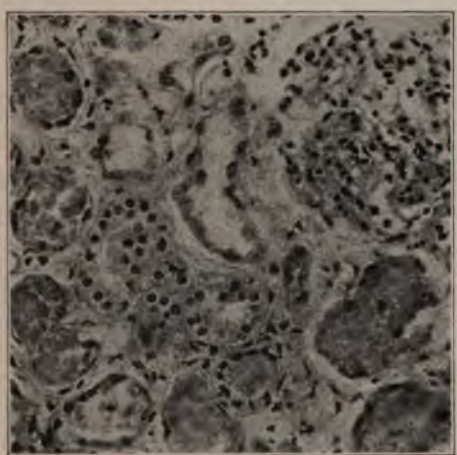

FIG. 10.—Cloudy swelling and necrosis of the epithelial cells of the renal tubules, due to sublimate-poisoning (Karg and Schmorl).

ing-reagents. The distinctive granules are not soluble in alcohol or ether, but are dissolved by acetic acid and alkalies.

The large glandular organs, the liver and kidneys, illustrate the condition exquisitely. The entire organ is symmetrically swollen; the general consistency perhaps a little decreased. On section the surface may be found a little moist and the parenchyma protrudes. The color is an opaque pallor, quite like the appearance of boiled flesh.

Seats.—The glandular epitheliæ (liver and kidney) and the muscle-fibers are the striking seats of this degeneration.

Pathologic Physiology.—The opacity seems to be due to a coagulation or precipitation of a part or all of the protoplasmic proteid. Some systematic writers have attempted to divide it into two groups: albuminous infiltration, in which the material has been deposited in the cell and then been precipitated; and albuminous degeneration, in which the inherent cellular proteid has been precipitated. It is doubtful whether this division is justified. The chemic relations are entirely obscure. It is as yet incomprehensible how bacterial toxins, themselves apparently proteids, can precipitate other and higher proteids. In the case of inorganic poisoning (metallic salts, acids) the process is more readily understood. The swelling is probably a simple edema, due, it may be inferred, to disturbed osmotic relations.

The function of organs is more or less profoundly disturbed by

this form of degeneration. Complete recovery is easy and frequent. If the causes persist, the cells pass into other degenerations, usually fatty metamorphosis.

FATTY INFILTRATION.

Definition.—Fatty infiltration is the deposition of fats derived from the circulation in cells and tissues which normally contain none, or the deposition of an excess of fats in cells and tissues which normally contain such.

Etiology.—Fatty infiltration may be physiologic or pathologic in its origin. In conditions of general obesity the regular consumption of excessive quantities of nourishment may lead to the most marked degrees of fatty infiltration; an inherited predisposition and lack of exercise acting as contributing causes. In rare instances it seems possible that with the normal physiologic diet persons of exceptional digestive power and living under conditions which restrict combustion may become affected with pathologic fatty infiltration. The condition may occur during pregnancy, and is frequent at the menopause. In a large class of cases an abnormal diet, or the presence in the diet of substances which tend to the formation of fats, such as alcohol, are responsible for the condition. It is doubtful whether poisons produce general fatty infiltration; they frequently, however, indirectly produce local or visceral infiltrations. In cachexiæ certain organs may become loaded with fats, as is sometimes seen in the liver in phthisis. In carcinoma the cells of the neoplasm may become infiltrated with fats. In organic diseases of the nervous system accompanied by extensive disintegration of myelin, in bone-diseases, and even following fractures of or operations on bones, the liberated fats are taken up by the circulation and deposited in susceptible localities. There is probably a rare fatty infiltration of senile origin, and also a type which appears at puberty. Of general diseases which may cause an undoubted general fatty infiltration chlorosis and diabetes may be mentioned. Fats may be deposited locally as substitution-tissue, as in the capsule about sclerosed kidneys, in the place of atrophied muscular fibers, in the bones, and about areas of local disease. The protective areas of fibrous tissue which wall off pathologic processes of various kinds may become extensively infiltrated.

Pathologic Anatomy.—Normal tissue plus fat describes the appearances. The fat may be diffuse, in localized areas, or in streaks along the planes of fibrous tissue. The appearances naturally vary with the tissue affected. Only rarely does the essential tissue of the part display disease. Microscopically the fat-drops are seen both within and without the cells. Without the cells they are most prominent along the fibrous strands, under the

endothelial membranes, about the lymph-channels, between the muscular fibrillæ, and to a marked extent just beneath the true skin, and indeed about all fasciæ. In the kidney the collections are between the tubules; in the liver, in the fibrous trabeculæ,

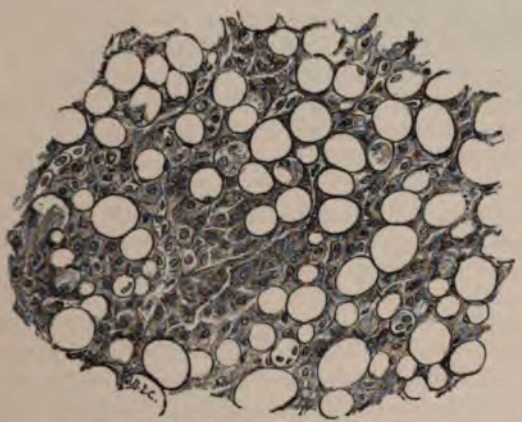

FIG. 11.—Fatty infiltration of the liver.

but especially in the hepatic cells; in the heart, underneath the serosa and between the bundles of fibers. Within the cells, and this is most marked in glandular epithelial cells, the fat is seen as distinct drops within the cell-wall. The fat-drops are always of considerable size, and soon run together, forming one drop, which pushes the protoplasm and nucleus against the cell-wall. The nuclei are usually normally distinct and well stained; the cell-protoplasm is clear and presents its normal granules; the cell-wall is intact, though often bulging to accommodate the excess of contents. In rare, prolonged, and extreme instances the bulk of the fat may be such as to interfere with the functions and nutrition of the cells, whose nuclei and protoplasm will then show pathologic alterations. Crystalline formations, as of margarin and cholesterin, and tiny balls of lecithin may be present, but are more often seen in fatty degenerations. The fat may be stained with osmic acid or sudan III.

Seats.—The favorite seats of fatty infiltration are the subcutaneous and subserous tissues, the mesenteries and omentum, along the fasciæ, between the muscles, about the kidneys, and in the liver and heart. The lungs and central nervous organs are rarely and only slightly affected.

Pathologic Physiology.—I have attempted to define this condition rigidly as an infiltration of fat into cells or tissues, distinct from formation of fat in them. Confessedly in individual cases the separation may be impossible; all doubtful cases are

probably degenerative. Infiltration arises whenever there is an abnormal quantity of fat in the circulation; the causes of this were pointed out in the etiology. Infiltration into imperfect or diseased cells may, however, occur with only normal quantities of circulating fats; this is probably the explanation of many of the local varieties. All cells and tissues are not of the same degree of susceptibility; when, therefore, isolated areas occur in unusual localities a pre-existing disease should be suspected. The mechanism of deposition is not well understood; it is perhaps effected by circulating cellular carriers.

Unless very extreme, fatty infiltration does not seriously embarrass the functions nor threaten the existence of tissues, and complete recovery and restitution are the rule. It may, however, lead to secondary degenerations, which, particularly in the heart, may be of serious consequence to the organ.

FATTY DEGENERATION.

Definition.—This is defined as a metamorphosis, the conversion of the cellular protoplasm into fat. The classic physiologic illustration is the fat-production in the secretion of milk. The nature of this process has not, however, been certainly determined. The majority of secreting cells do not die or show pathologic alterations; while for such cells as are cast off, as the colostrum-cells, it has not been shown that their fat was not an infiltration.

Etiology.—Fatty degenerations frequently follow upon cloudy swelling, and the causes detailed for the one apply also to the other. Of all agents, poisons are the most important. These may be metallic, as mercury, arsenic, lead, phosphorus—indeed most of the metals. Compounds which directly bind the hemoglobin or reduce it, or break up the red corpuscles, likewise produce it. Such are carbonic oxid, chlorates, pyrogallic acid, some coal-tar compounds, etc. Certain poisons, like chloroform, ether, iodoform, and the acids, seem to act directly on the cell-nutrition. In the case of most of these substances it seems to have been shown in more or less accurate chemical studies that the poison acts by disturbance of the gaseous cellular metabolism. More important as causative agents are the toxins of bacteria; these cause the majority of fatty metamorphoses. Their mode of action is not clear, and the analogy with the metallic poisons which naturally suggests itself has not been made out. In all anemias and cachexias fatty degeneration is common; it is rare in uncomplicated chlorosis. The degeneration in these cases was formerly regarded as due to suboxidation. Since, however, it has been shown that no suboxidation occurs in such chronic anemias, the degeneration may best be classed also as toxic. It seems possible, however, that extreme hemorrhage can produce fatty degeneration in this way. Metab-

olic diseases can also produce it, as is sometimes seen in diabetes. Fever can produce it, but the temperature must be high and prolonged.

Local fatty degenerations may be produced by local disturbances in nutrition, if not too sudden. This is seen in cases of congestion, thrombosis, embolism, atheroma, in tumors, and in tubercular and syphilitic deposits. The fatty changes of senility are probably of like origin. In the involution of tissues, as in the thymus, corpus luteum, uterus, etc., fatty degenerations are common. Trophic disturbances produce the degeneration, as is seen in the voluntary muscles. In many pathologic processes, as in caseation, liquefaction-necrosis, and the resolution of pneumonia, this metamorphosis plays an important *rôle*. In rare instances, as mentioned, fatty infiltration may pass into fatty degeneration. The transformation *en masse* of tissue into fat, as in fat-necrosis, should not be termed fatty degeneration.

Pathologic Anatomy.—Organs the subject of marked fatty degeneration are often somewhat increased in size: to this, however, there are many exceptions; a notable one is acute yellow atrophy of the liver. The consistency is usually lessened, though associated fibrosis may render the affected part abnormally dense. The specific gravity of the tissue is notably reduced. In the nervous system and in caseation and allied conditions liquefaction

FIG. 12.—Fatty degeneration of the epithelium of the renal tubules; stained with osmic acid (Simmonds).

may occur. The color in typical instances is a pale yellow; the existence and degree of congestion, pigmentation, or jaundice, will obviously alter the color. The areas of degeneration may be uni-

form or isolated. In the heart and liver particularly streaks or irregular areas may produce a mottled appearance. On section free fat may drip from the knife and cut surface; in other cases no fat-droplets can be seen macroscopically. In rare instances fat-crystals may be visible to the naked eye.

Microscopic Appearances.—The parenchyma-cells are first and most extensively affected, though the connective tissue may become involved. The cells are usually somewhat enlarged. The natural granules of the protoplasm disappear, and in their stead are fine dark granules, which usually stain black with osmic acid (Figs. 12, 13), and which are dissolved by alcohol, ether, etc., but not by acetic acid. A peculiar reaction of the granules is their staining with fuchsin (fuchsinophile granules). Usually the granules are very fine and only slightly refractile; they may, however, be large, and considerable droplets may appear or the entire cell become one large fat-drop, as in fatty infiltration. The nuclei in many cases of moderate degree show no changes; later in the process, however, the chromatin becomes diffused and refuses to stain and the nucleus may entirely disappear. Large hyalin balls may form inside the cells; these stain with acid-stains. The cell-membrane sooner or later breaks down, and the fatty contents and detritus fill the space. Cholesterin, lecithin, and fatty crystalline formations are often seen.

FIG. 13.—Fatty degeneration of the heart-muscle.

Seats.—Fatty degeneration occurs in nearly all tissues. The epithelial structures, especially the liver and kidneys, the heart-muscle, and the central nervous organs are the tissues most frequently affected. As before stated, interstitial as well as parenchymatous tissues may be involved. The cellular constituents of exudates and transudates are also liable to the change, and may present more or less the appearance of an emulsion.

Pathologic Physiology.—The manner of occurrence of fatty metamorphosis is as yet entirely obscure. If it were proved that fats can be formed out of proteids, this fact would warrant the simple explanation that in fatty degeneration the protoplasmic proteid is directly converted into fat. Certain evidence of this has, however, never been presented, and our reactions for fat are too unreliable to warrant deductions from simple microscopic studies. It has become apparent that the old and still largely accepted physiologic theory has never been demonstrated, even though it be true. No one has as yet produced fat in an animal fed on proteids entirely freed from fats and carbohydrates, and in the experiments with meats which contain both it has not been shown that any carbon-retention was unaccompanied by nitrogen-retention and that the carbon was retained in the form of fats or glycogen.

It is, of course, quite possible that the proteids may be directly converted into fat, and in recent experiments upon starving frogs poisoned with phosphorus this was apparently demonstrated; but even in these experiments it is likely that the glycogen of the liver was the source of the fat produced.

Unlike fatty infiltration, fatty degeneration tends to cell-death, as must in the nature of things be obvious, for it is an expression of cell-disease. Mild grades with the preservation of the nuclei undoubtedly admit of recovery; severe grades go on to necrobiosis. The function of the cells is, of course, disturbed. This may be in the direction of simple reduction of function or it may cause distinctly abnormal activity with pathologic metabolic products.

THE ALBUMINOID DEGENERATIONS.

The amyloid, hyaline, mucoid, and colloid degenerations represent proteid metamorphoses which are closely related. In typical instances they can be quite clearly differentiated from each other, and for the sake of clearness and convenience they will be separately described. It must be understood, however, that the products are closely related substances whose chemical characteristics and relations are not clear, and which cannot in many cases be distinguished.

AMYLOID DEGENERATION.

Definition.—This consists in the appearance in tissues of amyloid material; whether formed *in loco* or deposited is not quite clear. Amyloid seems to be a combination of chondratin-sulphuric acid with a proteid.

Etiology.—The common conditions under which amyloid degeneration arises are suppuration and ulceration. In tuberculosis, especially of the lungs and skeleton, and particularly in cases of mixed infection, and in syphilitic ulceration are found the conditions most favorable to its production. It occurs, however, in ulcerations of various sorts, in cutaneous ulcerations, in gastroenteritis, in connection with neoplasmic necrosis, in actinomycosis. Rarely it occurs under conditions of cachexia without suppuration, as in cancer, malaria, leukemia. In a few instances it occurs without any apparent cause.

Local amyloid formations are probably in no wise connected with the general condition and undoubtedly are often entirely physiologic.

Pathologic Anatomy.—In marked instances the organs are enlarged, and their specific gravity increased. On section the tissue is firm; the cut surface is smooth and neither contracts nor

extrudes. The consistency varies with the coexistence and degree of fibrosis, fatty degeneration, etc. The color of the organ is usually pale, but may obviously be altered by congestion, pigmentation, or fatty degeneration. The amyloid substance itself has a glistening, waxy, translucent appearance which is almost pathognomonic. This waxy appearance is not always uniform. Amyloid substance is more inelastic than any other degenerative material. Mild or even moderate degeneration may not present macroscopic appearances; in fact, apparently quite normal tissues may be highly amyloid microscopically. The special appearances in various organs will be described in the appropriate chapters.

Microscopic Appearances.—The favorite seats are the intima and media of the blood-vessels, the adventitia being rarely affected, the endothelium apparently never. The fixed connective tissues of the organs are the parts affected, the wandering cells and leukocytes being rarely involved. Muscle-cells are undoubtedly susceptible; but recent studies seem to show that glandular and lining epithe-

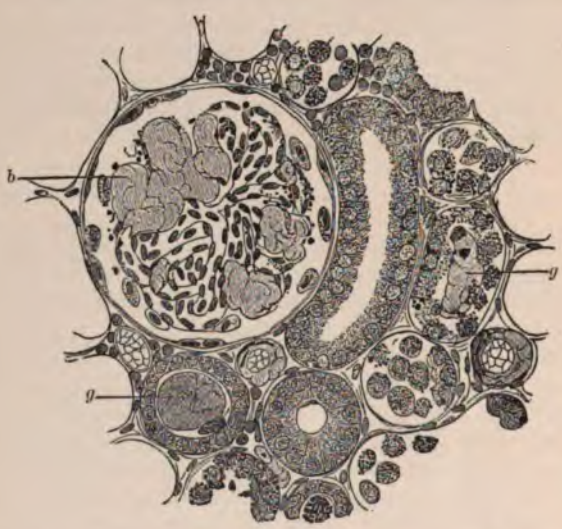

FIG. 14.—Amyloid degeneration of the kidney, showing amyloid substance in the walls of the blood-vessels of the glomerulus at *b*, and hyaline tube-casts in the renal tubules at *g* (Ziegler).

lium is never involved. Such cells may, and often do, show fatty or other degenerations or necrosis, but the presence of amyloid substance within their protoplasm has not been shown. The substance appears as irregular clumps or streaks in the interstitial tissues, often compressing the cells and blood-vessels. It presents

a glistening homogeneous appearance. The cells usually present evidences of atrophy and other degenerations. In the renal glomeruli and in the Malpighian corpuscles of the spleen the appearances are perhaps most distinctive. Without staining amyloid degeneration cannot always be distinguished from other degenerations; indeed, not always with staining reactions. The substance is highly resistant to bacterial decomposition and to digestion.

Reactions (see also below).—The gentian-violet reaction seems to be the most invariable. In sections of tissue fixed for microscopic study gentian-violet colors the normal tissues blue; the amyloid substance is a light pink or red. A mahogany-red reaction with Lugol's solution of iodin is quite constant, but fails in the isolated amyloid bodies. It is easily obtained in fresh specimens. The red color is changed to a blue by treating with sulphuric acid or chlorid of zinc.

Seats.—In the order of frequency amyloid degeneration affects the kidney, liver, and spleen, then the larger blood-vessels, the intestinal mucosa, the lymph-glands, the skeleton, the adrenal bodies, and the heart. It rarely affects the pulmonary mucosa, the bladder and genitalia, the thyroid body, the voluntary muscles, and, apart from the local amyloid bodies, the nervous system or the integument.

Local Amyloid Formations.—These occur in the nervous system, especially in advanced years and in scleroses, grouped about the blood-vessels, most marked in the posterior cord and in the brain; in the prostate gland; about inflammatory areas; in infarcts; in granulomata, especially syphilis; and in neoplasms. They present themselves as small round bodies which usually have a concentric arrangement resembling starch-granules. These do not usually present the typical amyloid reactions; often they react more like hyaline substance, and indeed the blood-vessels in their situation seem especially affected with hyaline change. The special appearances and reactions of the amyloid bodies of the nervous system will be described in connection with neuropathology.

Pathologic Physiology.—As stated, amyloid substance seems to be a combination of chondratin-sulphuric acid with a proteid. It is composed of hydrogen, nitrogen, carbon, and sulphur, and is insoluble in weak alkalies. Chondratinic acid is normally present in bones, cartilages, and elastic tissue. It seems to have been shown that an amyloid-like substance exists in the elastic coat of the blood-vessels—perhaps a different combination of chondratinic acid. Our present knowledge suggests that amyloid substance is not entirely abnormal, but rather an abnormal combination of normal substances. It seems to result from proteid alterations in connection with the pathologic processes already detailed. That bacterial influences are not necessary is suggested, though not proved, by the fact that amyloid change has been pro-

duced by long-continued aseptic suppuration induced by turpentine injections.

Amyloid substance cannot be removed, but does not of itself compromise life. It may become transformed into typical hyaline substance. Amyloid degeneration interferes with functional activity by pressure upon the parenchyma and by vascular disturbances. By its situation in the blood-vessels it may occasion thrombosis.

HYALINE DEGENERATION.

Definition.—This is a retrogressive process consisting in the appearance of a homogeneous proteid substance of obscure nature. It is closely allied to amyloid, mucoid, and colloid degeneration, and can certainly pass into each of them. The hyaline change of epithelium of older authors is now by general consent classed as a mucoid transformation.

Etiology.—Hyaline degeneration occurs under the following pathologic circumstances: in the muscles during infections and septic processes and following traumatism; in intoxications, as by lead; in interstitial hemorrhages and hematoma; in struma; in cicatrices; in the blood-vessels in old age, arteriosclerosis, or aneurysm; in all forms of arteritis, especially of the nervous system; in the endocardium and cardiac valves in all diseases affecting them; in the granulomata; in neoplasms, especially cylindromata and keloids; in the lungs in pneumonia; in the kidneys in nephritis; and in all conditions of coagulation-necrosis and fibrinous exudation, for in these processes hyaline degeneration seems to be a factor.

Pathologic Anatomy.—Hyaline change is not usually massive enough to be macroscopically appreciable. When so, the organ or tissue is enlarged, dense, and presents a pale, homogeneous, opaque appearance. Upon the mucous and serous membranes small collections may be readily seen, and may present either a pseudomembranous appearance or may appear as opaque plates upon or beneath the surface. Microscopically there are three chief sites: (*a*) In the blood-vessels, where the degeneration may appear in the endothelium, beneath it, between the coats and fibers of the vessel, or surrounding the vessel. The wall is thickened, the lumen is narrowed or obliterated; the endothelium may be in a state of proliferation. Perivascular hyaline change is well seen in certain tumors—cylindromata (Fig. 15). (*b*) In the interstitial tissues, as between the muscle-fibers, the hepatic cells, the renal tubules, in the reticulum of lymph-glands, in the retina, and in neoplasms and cicatrices. It may be uniform in distribution, but is more often irregularly clumped or may be in concentric whorls. (*c*) Within the cells. This condition is probably limited to meso-

dermic cells. It may be seen in muscle- and giant-cells, and in endothelium, leukocytes, or wandering cells to a less degree. Whether the epithelial cells take part in this transformation in the

FIG. 15.—Cylindroma, showing a number of blood-vessels whose walls have become converted into hyaline material.

coagulation-necrosis of mucous membranes and in the production of casts in nephritis has not been decided. It has not been possible in the intercellular or interstitial varieties to decide whether the substance was formed there or deposited there; in the vascular form, and especially in coagulation-necrosis and fibrinous exudations, it is more probable that it is formed *in loco*.

Unstained, the substance has a glistening, waxy appearance; it is less translucent than amyloid. Typically it evinces an affinity for the acid anilin-stains. It may or may not take the fibrin-stains; it often takes basic stains in a modified manner. In truth, the reactions of hyaline material are very uncertain and shifting, in many instances it can scarcely be distinguished from amyloid, and is then called a hyalo-amyloid change; in other instances it closely resembles mucin and the colloid substance. The cells of affected parts often show fatty degeneration or other alterations.

Seats.—The locations most often affected are the muscles, especially the recti, the mucous membranes, the liver, kidneys, and adrenal bodies, the cardiovascular system, the nervous system, the serous membranes, and the retina and choroid coats of the eye. The other locations are suggested in the discussion of the etiology.

Pathologic Physiology.—Von Recklinghausen believed it to

be a coagulation of normal proteid upon the death of the cells; this explanation is, however, insufficient. It appears more likely either that it consists of proteid modified *in loco* by disturbed action of cells, or that it is a deposition by cellular carriers of insoluble material formed elsewhere. The exact nature of the transformation is entirely obscure; it cannot be held analogous to the coagulation of proteids by heat; nor to the precipitation by metals or salts, since in these events the proteids are not usually rendered permanently insoluble in water and are in other ways clearly different. Hyaline material can undoubtedly be reconverted, absorbed, and removed. Its presence rarely compromises the parenchymatous structures to an extreme degree. It may be converted into the other albuminoid degenerations, and may undergo caseation and also calcareous infiltration.

MUCOID DEGENERATION.

Definition.—Theoretically this is the conversion of cellular protoplasm into mucin. Mucin is a glycoproteid, which contains no phosphorus, and which by virtue of its carbohydrate moiety reduces cupric sulphate in alkaline solution. It is quite insoluble in water, but has itself a marked capacity for taking up water. It is very soluble in alkaline solutions, but is precipitated by saturation with most neutral salts. It is precipitated by acetic acid in solutions poor in salts; also by heat, alcohol, and many of the metals. It does not dialyze. The secretions from different classes of epithelium differ notably among themselves, and the pathologic mucins differ still more.

Etiology.—Mucoid transformation should be distinguished from hypersecretion of mucin. Hypersecretion is a common result of inflammation or irritation of all sorts; it is seen in the pulmonary, gastro-intestinal and urinary mucous membranes, in the glands of Cowper, the gall-bladder, the salivary glands, in the antrum of Highmore, in the lachrymal glands, and in the testicles. The product of the epithelium of the urinary tract and gall-bladder, usually called mucin, is more often nucleo-albumin. Mucoid degeneration in the strict sense occurs most frequently in mesoblastic tissues, the abnormal substance lying between the cells. It is in some way connected with inflammatory processes, as, apart from its occurrence in tumors, it is found only in tissues the seat of inflammation. Any of the connective tissues of the body may be affected. Widespread myxomatous degeneration of the subcutaneous tissues may be seen in myxedema. In some cases of myxedema, scleroderma, and the other pachydermic affections, mucin has been extracted from the skin; other attempts in similar cases have failed. Neoplasms comprise the third group of mucoid phenomena. The transformation occurs in sarcomata, carcinomata, fibro-

mata, lipomata, chondromata, and especially in the myxomata, where mucin is the essential element, while in the other growths it is an accidental and occasional transformation. In the epithelial tumors the epithelial cells themselves may be affected.

Pathologic Anatomy.—The gross appearances may consist in nothing but the appearance of the mucin. Upon catarrhal mucous membranes is a coat of thick, tenacious mucus, with or without congestion or other changes. In localities where the mucin becomes pent up it swells markedly, dilates the chambers, flattens the epithelium (which may then atrophy), and later becomes converted into a simple albuminous fluid. Such a process is seen in the antrum of Highmore, in Cowper's glands, in the salivary glands, etc.; in these cases the appearances are those of a cyst. In mucoid degenerations in the connective tissues the appearances are often not characteristic of mucin; the tissues are soft and elastic and tear easily. In tumors cysts are usually formed along with general mucoid infiltration. In cystic ovarian neoplasms the production is often massive, and the substance is often peculiar in refusing precipitation by acetic acid, and has therefore been termed pseudomucin. In myxomata the substance is usually much more dense.

Microscopic Appearances.—In catarrhal mucous membranes the goblet-cells are seen in excessive quantity. Only in extreme instances is the process accompanied by the death of the cell. The cells are much swollen, and the distal end is especially bulged out with its drop of mucin. There is usually a submucous inflammatory reaction, and pus-cells containing mucoid material may be seen (Fig. 16). In the connective tissues it is seen that the mucin lies between the cells and that the ground-substance has disappeared—*i. e.*, been converted into mucus. The cells very rarely present mucous change, but are often degenerated in other ways. In tumors the change occurs everywhere, in and between the cells and in the form of cysts, whose walls may or may not present a cellular lining. The blood-vessels are rarely affected. In all situations mast-cells may be seen, often abundantly.

FIG. 16.—Myxomatous degeneration of a sarcoma, showing stellate cells separated by mucoid intercellular material (Karg and Schmorl).

Mucin is best fixed with corrosive sublimate. As a rule, it elects basic stains. It stains only moderately with hematoxylin, but very well with methylene-blue and indeed with most of the basic anilin-stains. Thionin and tuloidin-blue are the best stains,

giving it a purple-red color. These staining reactions are not entirely distinctive, and it is often impossible to differentiate mucoid from colloid material, and even from hyaline and amyloid material.

Seats.—Of normal epithelial tissues the mucosa of the respiratory and gastro-intestinal tracts, the salivary glands, and the uterus are most often affected; any epithelium may, however, be involved. The connective tissues have been sufficiently considered. Of neoplasms, ovarian cysts, abdominal carcinomata, and mesoblastic tumors anywhere are most liable.

Pathologic Physiology.—Since the deposition of mucin seems to be excluded, the only explanation is to assume the conversion of other proteids into mucin. The causes and *modus operandi* are not clear; the fact, however, that in the cysts the mucin may be reduced to simple albumin, shows the possibility of such transformations.

Unless the disease is very prolonged, the affected mucous membranes may recover. The connective-tissue forms do not of themselves threaten the life of the tissue; and the deposit is often removed by reabsorption. In neoplasms the degeneration seems an evidence of cell-death.

COLLOID DEGENERATION.

Definition.—This consists in the abnormal appearance of a substance whose prototype is the colloid material of the thyroid gland. It is not precipitated by acetic acid nor alcohol, does not take up water avidly, and is therefore quite like the pseudomucin already noted.

Etiology.—It occurs in goiters and in thyroid neoplasms, in the hypophysis cerebri, in the kidneys (some cases of congenital cysts), and the adrenal bodies, in the prostate and seminal vesicles, in the atrophic gastric mucosa, in cysts of the lips and larynx, and in the cervix uteri. Colloid transformation in neoplasms apart from the thyroid body is very rare. Colloid may arise from or become converted into mucoid material, and stands very close to the hyaline substance.

Pathologic Anatomy.—Affected organs may be enlarged, and may be hard or quite soft. On section the colloid areas appear as yellowish-brown translucent bodies; rarely they are arranged in large clumps. They may be macroscopically invisible, or, on the contrary, may form large cystic collections with thin, flattened walls. Colloid degeneration may be accompanied by serous transudation, due probably to vascular disturbances. The serous transudation seems to dissolve the colloid material, so that finally the cysts are converted into compartments filled with a chocolate-colored fluid containing pus, blood, and crystals of cholesterin, sodium chlorid, and calcium oxalate (Fig. 17).

Microscopically the material is found in the glandular acini, in the cells, and in the connective tissues. There are often signs of pressure, and, probably from the same cause, the areas are anemic and have a poor vascular distribution. The arrangement is

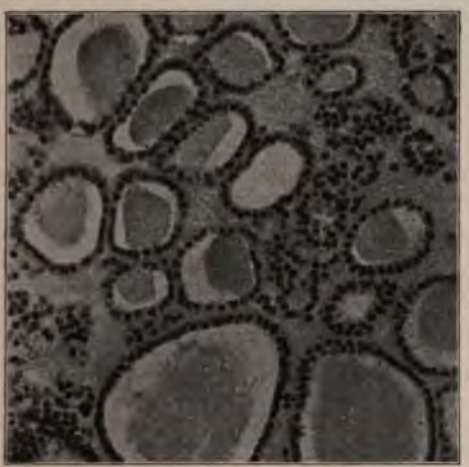

FIG. 17.—Colloid degeneration of the thyroid gland, showing masses of colloid matter in the gland acini (Karg and Schmorl).

usually in balls or scrolls, homogeneous as a rule, but often with concentric or radiating lines. The areas often intercommunicate, and extensions may be traced into the adjacent tissues. The cells usually show degenerative changes, and inflammatory reactions are often present. Crystals of calcium oxalate are common. Acid stains are usually elected, as in hyaline degeneration. The indefiniteness of the reactions may make it impossible to exclude hyaline and mucoid changes.

Pathologic Physiology.—This is obscure, but seems to be analogous to that of mucoid change. The substance is undoubtedly produced *in loco*.

Colloid is a grave degeneration, usually connected with marked cellular disturbances. The substance may become hyaline or mucoid, or may be reduced to a simple or purulent transudation.

GLYCOGENIC INFILTRATION.

Definition.—This condition consists in the presence of glycogen in cells which normally contain none, or the presence of an excess in cells which normally contain it, as in the liver, cartilage, muscles, leukocytes, in the embryo in all tissues, and in the uterus. The attempt has been made to separate glycogenic infiltration from a glycogenic degeneration, but the conversion of protoplasmic proteid into glycogen has never been demonstrated.

Etiology.—The condition is not infrequent. It is seen in the tissues in diabetes, especially in the kidneys, muscles, liver, and circulating leukocytes. It occurs in neoplasms, especially in malignant growths of mesoblastic origin, being rare in most carcinomata. In leukocytosis of different varieties the cells may contain an excess, and granules of the glycogen may float free in the plasma. In purulent collections and in inflammatory areas the cells may be markedly infiltrated. The infectious granulomata, however, seem exempt. The amylaceous bodies of the prostate are closely allied to glycogen.

Pathologic Anatomy.—Tissues rich in glycogen may present a hyaline appearance; usually there are no macroscopic alterations. Microscopically the material is generally found within the cells; it may, however, be in the intercellular substance, and may be free in the plasma of blood or the fluid of exudates. It is commonly deposited as round balls, which may be concentrically striated. In fresh tissues it is soluble in water, but loses its solubility after fixation by alcohol, etc.

Glycogen is stained brown by iodin, but the brown is not turned blue on the application of sulphuric acid. Ptyalin or amylopsin converts it into sugar, with the loss of the color-reaction.

The **pathologic physiology** is obscure. In diabetes it is simply an expression of the general hyperglycemia. In neoplasms and suppurations the collections are probably depositions.

DROPSICAL INFILTRATION.

By dropsical infiltration is meant *edema of the cells*, the presence in cells of an excess of plasma. This does not always occur

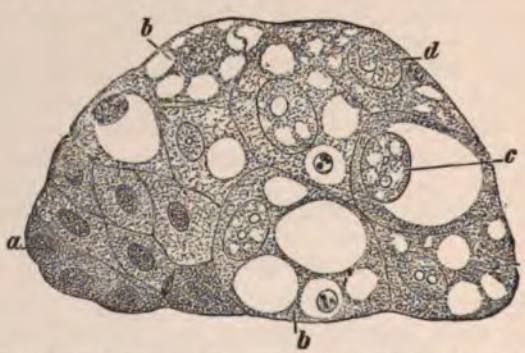

FIG. 18.—Dropsical infiltration of the epithelial cells of a carcinoma of the breast: *a*, ordinary epithelial cells; *b*, dropsical cells; *c*, dropsical nuclei; *d*, enlarged nucleoli (Ziegler).

in general dropsy, the fluid being between the cells and often compressing them to a marked degree. In other instances the

cells take up the fluid. In burns and pemphigus and in other skin-lesions connected with vesiculation, and in various inflammations of organs, edema of the cells occurs. It is also a part of the degeneration termed cloudy swelling.

The cells are enlarged, often to an extreme degree, and they may even burst. The protoplasm sooner or later becomes cloudy and often presents degenerative changes—fatty metamorphosis in particular. Vacuolation is frequently observed (Fig. 18).

The condition is probably a purely physical phenomenon in the dropsies. In the cutaneous lesions other factors are operative.

CALCIFICATION.

Definition.—Calcification consists in the abnormal deposition in tissues of earthy salts. The phosphates and carbonates of calcium are the chief salts concerned; the oxalates, however, are usually present, and the corresponding magnesium salts may be mixed with them. The best physiologic examples are the senile change in the vascular apparatus and the formation of the brain-sand (acervulus cerebri). Impregnation of the skeletal tissues is usually accomplished as a physiologic condition through the activities of special cells; this is an essential element in ossification.

Etiology.—The deposition generally occurs in diseased tissues, especially in those the seat of vascular disorders. Local necrosis or fibrosis antedates intercellular calcification, and the process may be accompanied by atrophy and absorption of certain cellular elements. In neoplasms the abnormal cellular conditions obviously predispose; but here, too, the vascular relations are of notable importance. Hyaline and fatty degenerations often precede or accompany it. In rare instances no local predispositions can be determined. Cases of this kind occur in old age, and for these it is inferred that owing to increased lime-resorption from the skeleton the system is saturated to the point of precipitation. Similar supersaturation of the blood with calcareous matter may occur in cases of extensive disease of bones, and may lead to widespread deposition.

Pathologic Anatomy.—Early in the process no macroscopic signs are apparent. On microscopic examination the salts are seen as fine granules scattered through the intercellular substance. Cellular infiltration, however, is not uncommon, and in such instances the cells show more or less extensive nuclear and protoplasmic degenerations. By the coalescence of the granules larger, irregular spherical bodies may be formed. These usually have a concentric arrangement (psammoma bodies). Definite crystals are rare, but may be seen. The next adjacent tissue may present an opaque appearance. In certain localities, especially the blood-vessels and serous membranes, calcareous plates are formed. The depositions

may attain a surprising size, especially in the vessels and in neoplasms. The macroscopic color is usually white, grayish, or yellow; accidental pigments may, however, produce discolorations. On staining the deposition takes up both carmine and hematoxylin, but exhibits no elective attraction for the anilin dyes. The salts are dissolved by acids, best by hydrochloric acid; in the case of carbonates, with evolution of carbonic acid gas. Many organic and inorganic acids are employed in the decalcification of tissues for purposes of microscopic study. Fibrosis, cellular necroses, and degenerations can be demonstrated in the tissues by suitable methods.

Seats.—It is in the cardiovascular system that the condition is of the most importance. It occurs often as a simple senile change, usually connected with an atrophy of the elastic tissues of the vessel-walls, hyaline degeneration of the connective tissue, and general fibrosis. It is almost invariably an accompaniment of sclerotic endocarditis and arteriosclerosis. In the endocardium the valves are most frequently affected; of the vessels, the aorta, the coronary arteries, and the cerebral vessels. The process is, however, often universal, and the splanchnic vessels and radial arteries seem very susceptible. It affects chiefly the intima and media. In the pericardium the deposition is uncommon without the previous occurrence of pericarditis; in adherent pericardium the heart may be literally enclosed in a calcified sac. In the myocardium calcification is usually interfibrillar, but may involve the fibers. Large collections may occur in the pituitary body, the meninges, and in the ventricular plexuses. It is common in the joints, uncommon in the pleura, rare in the peritoneum. In the muscles local formations are not rare, and usually occur at the seat of previous injury or irritation. In the lungs and liver it is not unusual in and around foci of necrosis due to various causes (tuberculosis, parasites, etc.). Cicatricial tissue often becomes calcified. In the walls of cysts, in the biliary and urinary bladders, in the limiting wall of old abscesses and hematomata, in thromboses, and even in cutaneous scars calcification is a common incident. In the kidneys infarcts of these salts may be formed. The neoplasms most subject are the avascular tumors; uterine fibromata, fibromata in general, dermoid cysts, goiters, scirrhous carcinomata, and tumors of the pituitary bodies. The special term psammoma (*q. v.*) is applied to certain calcified neoplasms. It may, however, occur in the most vascular sarcomata. Lithopedia are the calcified fetuses of extra-uterine pregnancy. Apart from neoplasms, the most striking intracellular depositions are seen in the ganglion-cells in areas of softening and in the renal cells following certain metallic poisonings (mercury). It is interesting to note that the intestinal epithelium, which normally secretes the larger part of the lime-salts discharged from the body, is rarely infiltrated by them.

Pathologic Physiology.—Various views are held to explain the depositions. An excess of the salts in the blood or tissue-liquids must be rare. On the one hand, it has been assumed that the soluble are converted into insoluble salts, and, on the other hand, that the tissues have become less solvent for the salts. Probably the best established view is that the salts are precipitated as insoluble combinations with proteids.

Calcareous deposits are probably never removed, but once formed remain permanently. There is no doubt that they influence the adjacent tissues to degenerations.

OSSIFICATION.

Ossification implies the deposition of lime-salts and other changes through the agency of osteoblastic cells. It occurs in cartilages, and in tumors connected with the bones, cartilages, and periosteum. The salts are more regularly deposited and are usually in masses between the cells. An accurate differentiation from calcification can in some instances be made only by the detection of osteoblasts after decalcification of the material.

URATIC INFILTRATION.

Deposits of urate of sodium in the cartilages and fibrous tissues of joints and in various other situations occur in the course of gout (see Disturbances of Metabolism and Diseases of Joints).

PIGMENTATION.

According to the origin and variety of the pigments, pigmentations may be divided into four groups : 1, those in which the pigments are derived from external sources ; 2, those derived from the hemoglobin ; 3, those derived from the bile ; 4, those derived from cellular activity within the organism.

Pigmentation from the Exterior.

Of the first group, those caused by entrance of foreign bodies through the air-passages are the most important. The condition now generally termed **pneumonokoniosis** is commonly a disease of occupation. Coal, iron, and stone are the most frequent foreign substances inhaled. Vegetable particles, as grain-dust and textile fibers, and animal hairs and furs are not uncommonly the cause of such pigmentations. Corresponding to the agent, there are such terms as anthracosis (coal-dust pigmentation), siderosis (iron), calcicosis (stone), etc. (Fig. 19). Inhaled substances probably do not reach the alveoli, but are caught by the bronchial cellular cilia. In part they are coughed up or otherwise cast off with the bronchial secretions ; in part they penetrate the bronchial walls or are

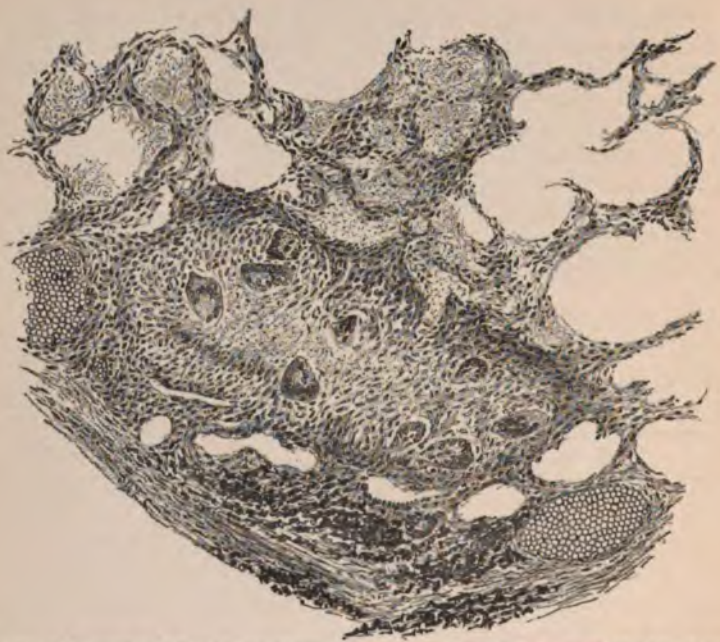

FIG. 19.—Tuberculosis of the lung, showing anthracotic pigmentations in the lower part.

carried by phagocytic cells into the submucosa (Fig. 20). They may become deposited in the latter situation, or may be carried in

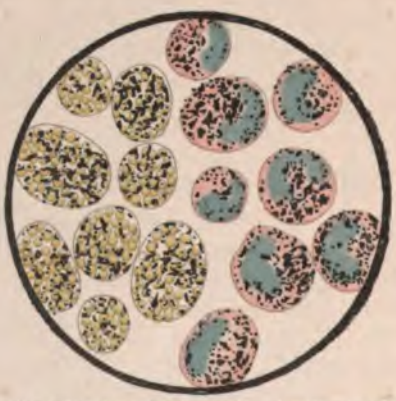

FIG. 20.—Phagocytic cells of the bronchial secretion (sputum) containing black particles of dust and carbon; the cells on the right are stained with methylene-blue (Jakob).

the lymphatic circulation to the peribronchial and mediastinal glands, the fibrous tissue of the lung, or the subpleural tissues. In rare instances the pigment finally reaches the general circulation,

following which it is deposited largely in the spleen, liver, intestinal mucosa, and kidneys. In these cases the mucous membranes from the lips downward may be more or less pigmented.

Pigmentation through the alimentary tract is best illustrated by **argyria** following the excessive ingestion of soluble salts of silver. The depositions seem to consist of a reduced form of a silver albuminate. In the skin the pigment lies directly under the epithelial layer, between the cells, and in the intercellular tissue and lymph-spaces. The gastric and intestinal walls are deeply affected. The liver and kidneys are usually involved; in the former the deposition is periportal, in the latter the glomeruli and the corticomedullary boundary contain the pigment; in both the cells are free. Among the rarer sites are the choroid plexus, the various glands of the body, and the walls of the blood-vessels.

Pigmentation by cutaneous absorption apart from tattooing is problematical; it has been alleged to occur in workers in copper.

Hematogenous Pigmentation.

This concerns the deposition of pigments derived from the hemoglobin, of which there are two groups, the siderous and the non-siderous. The chief siderous pigment is hemosiderin, which has, however, many modifications; the non-siderous pigments are derivatives of hematin—hematoidin, hemofuscin, melanin, etc. In the course of time the siderous pigments may lose their iron. Probably all formation and further elaboration of these pigments are the result of specific cellular activities. Two groups of hematogenous pigmentations may be distinguished, (1) those in which the hemolytic agents act in the circulating blood or the associated organs, and (2) those in which the reductions occur in local tissues.

(1) To the first group belong the general hemolyses. In pernicious anemia and leukemia, in malaria, in severe cachexias, in occasional infectious and septic processes, in poisonings (as by pyrogallic acid, chlorates, arseniuretted hydrogen, by some mollusks, by pyridin and tuluylendiamin, etc.), the hemoglobin is set free in the circulation. It is promptly excreted by the kidneys, and to a limited extent by the intestines; much is converted into bile in the liver, some little passing into the bile unchanged. A certain amount is reduced by the tissues (apparently by the liver) to the two before-mentioned series of pigments, which are then carried in the lymphatic and vascular circulation and by means of cellular carriers and deposited in various places. As time passes, these pigments seem to become reduced, the iron being excreted by the intestine and the remainder by the kidneys as urobilin. In the liver the depositions are largely in the periphery of the lobule; in the spleen, in the regions of the follicles; in the kidney the most marked collections are in and about the glomeruli and the tubules.

In all tissues the depositions are both intercellular and intracellular; the cells may either take up pigment or have it deposited in them.

A peculiar form of hematogenous pigmentation is that seen in the gastro-intestinal tract and other abdominal organs of drunkards. In other instances the presence of siderous pigments in the intestine is to be viewed as a process of excretion, since the greater mass of iron is eliminated through the bowels.

The appearance of organs with marked pigmentation varies with the variety and stage. A rusty-red color is the usual early appearance; later a brown, then a greenish color may be produced, and finally a dark blackish-brown. The association of jaundice, which is common, alters appearances very much.

(2) The two chief causes of *local pigmentation* are thrombosis and interstitial hemorrhage and coagulation. The pigmentations seen in the indurations resulting from prolonged venous stagnations and congestions are probably of analogous origin. Under these circumstances the hemoglobin is diffused from the blood-cells, and a portion passes directly into the plasmatic circulation and is carried away to be eliminated; soon, however, the area becomes walled off and the two sets of pigments are then formed within. The siderous pigments are most frequently seen in small lesions and at the periphery of large ecchymoses; the hematoidin series is most prevalent within the cystic contents. The pigments change in color (the color-changes in a bruise are due to this), and finally become a brownish amorphous powder, which in turn disappears. Phagocytic cells take up all forms of the pigments (Fig. 21), and

FIG. 21.—Phagocytic cells of the sputum containing blood-pigment, from a case of cardiac congestion of the lungs (Jakob).

carry them to various parts of the body, especially to the liver, hematopoietic organs, intestines, and glands; the depositions in them are known as *pigment-metastases*.

The distinctive reactions of the various pigments are not well known. Of hematin and hemin it is known that they are insoluble in water, alcohol, and ether; slightly soluble in weak acetic and mineral acids; easily soluble in chloroform and in weak alkalies, from which solution they are precipitated on the addition of lime- or baryta-water. Hematoidin differs from these in being somewhat soluble in ether, but insoluble in weak acetic acid, and gives with strong nitric acid the spectral play of colors. Apart from the iron reactions little is known of hemosiderin. The iron is best demonstrated by its conversion into the sulphid by means of ammonium sulphid, or by the Prussian-blue reaction with weak hydrochloric acid and potassium ferrocyanid.

Microscopically hematogenous pigment presents three chief appearances: small needles, rhombic crystals, and amorphous masses or fine balls clumped together (Fig. 22). The first two

FIG. 22.—Hematoidin-crystals from an old hemorrhagic focus (Jakob).

forms are very rarely seen within cells, the last form commonly. The colors vary from a pink-red to a deep rubin, from pale yellow-green to a deep brown or absolute black.

Hepatogenous Pigmentation.

Pigmentations derived from the bile are due to bilirubin (isomeric with hematoidin) and its oxidation-product, biliverdin. As will be elsewhere explained in detail, all jaundice is now held to be of hepatic origin; so far as known, only the hepatic and renal cells can produce bilirubin from hematin.

The deposition of these pigments may be either in solution in the tissues, in granular precipitations, or in crystals (needles and rhombic plates). The cerebral substance alone seems never, except in the new-born, to be pigmented. The liver, skin, mucous membranes, the endarterium and other serous membranes, and the

glandular and fatty tissues are especially susceptible. The color is first yellow and gradually deepens to a deep olive, the urine presenting similar transitions. The lachrymal and salivary glands, the mammæ, and the intestinal mucosa seem to be able to keep the pigment from passing out with their secretions. The ocular fluids are colored.

The pigment in solution saturates the tissues. The granular pigments, yellow, brown, or greenish in color, may be seen in the cells or in the interstitial tissues; the crystals, yellow or red in color, are usually extracellular. The pigment displays the spectral play of colors on contact with strong nitric acid, and is turned green by weak tincture of iodin.

A special form of deposition is the bilirubin-infarcts in the urinary tubules. These are seen in severe jaundice of the new-born, but may occur in deep icterus of adults, as in acute yellow atrophy.

Metabolic Pigmentation.

The pigmentation derived from cellular activity may be properly termed metabolic. We know isolated facts about the different forms, but there is little systematic fundamental knowledge. Two facts, however, seem clear: that these pigments are formed by migratory and resident pigment-building cells, which with leukocytes and plasma-cells accomplish their transportation and deposition; and that hemoglobin is in some way or other the raw material for their manufacture, with, perhaps, the exception of some pigments in melanosarcoma, which seem derived from proteids.

The manifestations may be local or general. Among the former are the pigmentations of nevi and moles, of pregnancy, of the corpus luteum, freckles, some scars, certain skin-diseases, as chloasma and xanthelasma, of the lesions secondary to some cutaneous parasites, etc. A special local type is that seen in tumors, notably in melanosarcomata. Lipomata and sarcomata (chloromata) may be analogously affected.

Among the general pigmentations are those of Addison's disease, of certain severe anemias and cachexias; of some cases of diabetes (*diabète bronzé*); tuberculosis of the peritoneum, intestines, and retroperitoneal glands; of abdominal neoplasms, and of senility. The cases associated with abdominal lesions are held to be connected with disturbances of the adrenal bodies or of the splanchnic sympathetic system, which has been considered to have control of pigment-formations.

The metabolic pigments are very varied, and a detailed discussion of them here would be unprofitable. They may have a high percentage of sulphur, and may or may not contain iron. They are commonly deposited in and between the cells as granules, but

may be crystalline. They do not give a play of colors with nitric acid, and have varying solubility.

NECROSIS.

Definition.—Necrosis may be defined as the death of tissues. The death of individual cells is termed *necrobiosis;* death of tissue *en masse*, usually accompanied by putrefactive changes, constitutes *gangrene.*

Etiology.—All classes of cellular death may be brought under four etiologic groups: 1, those due to nutritional and circulatory disturbances; 2, those due to trophic disturbances; 3, those due to poisons—animal, vegetable, bacterial, and inorganic; and, 4, those due to traumatism, employing the term in its broadest sense. It has been attempted, without success in our opinion, to class the trophic necroses as identical with those due to circulatory and nutritional disturbances; similarly the poisons and traumatism have been considered as acting only through the circulatory and nutritional paths, but it seems evident that in the light of our present knowledge the four groups are to a greater or less degree distinct.

The various causes do not produce constant types of necrosis, but occasion one form in some cases, another in other cases. Prominent among these varying circumstances are the native health of the tissues and their vital resistance, the circulatory relations of the part involved, the activity and duration of the causal agents, the age of the subject, the presence of other diseases, the temperature of the tissues, etc. It will therefore be better first to consider collectively the causes of necrosis, and subsequently detail the varieties of it. There can be no doubt, however, that in the direct forms of necrosis the results are to a marked extent individual to the agent; for example, cells killed by the action of acids, alkalies, and metallic salts present appearances quite characteristic of each.

Circulatory Derangements.—The circulatory disturbances include many conditions. Acute and chronic ischemia, however produced—by embolism, thrombosis, arteriosclerosis and atheroma, by extra-arterial pressure, cardiac weakness, or by arterial spasm, as in Raynaud's disease, and perhaps in ergotism—are important conditions. Venous stagnations are responsible for many instances. Actual stasis is a rare cause, being mechanical obstructions and such poisonings as produce coagulations. Heat and cold act partly by circulatory disturbances. Among the general disorders of circulation and nutrition may be mentioned the anemias, the cachexias, senility, and certain metabolic diseases, such as diabetes. In these conditions there is much probability that poisoning by metabolic products plays an important part.

Trophic Derangements.—Forms of necrosis due to trophic disturbances are well illustrated by bedsores (decubitus), myelitic cystitis, the ulcerations seen in trigeminal neuritis, and the arthropathies. These forms of cell-death cannot be brought under the circulatory, toxic, or traumatic classification. They can be explained only by the assumption that the biologic mechanism of the cell is disturbed, and that in consequence death occurs.

Intoxications.—The group due to poisons is very extensive and the particular subdivisions numerous. The toxins of bacteria furnish many direct examples; and indirectly many forms which seem circulatory or traumatic are not really so, since these factors only lower the resistance of tissues, which then become susceptible to bacterial infection. Experimentally the most exquisite forms of cell-degenerations and necrosis can be produced by the injection of toxins or analogous substances like ricin and abrin. The alkaloids possess marked power in the production of necrosis. Acids, alkalies, metallic salts, and innumerable other chemical substances may produce direct necrosis by immediate action, or indirect necrosis by the preliminary production of degenerations. The same substances often cause both circulatory and mechanical disturbances, which augment their direct effects. Heat and cold act like chemicals; heat alters the properties of proteids; cold affects the fluids rather than the protoplasmic substances; both also induce marked circulatory disturbances.

Mechanical Agents.—The mechanical causes of necrosis are many and varied. Pressure *per se* may cause the death of cells, but is often aided by the circulatory disturbances which it occasions. That tension causes necrosis is an old surgical truth, well illustrated by the results of collections of exudates below the periosteum and by the results of strangulations. The pressure of calculi, concretions, enteroliths, and exostoses may cause important necrotic processes. Circulatory disturbances often are a very active factor—indeed, many forms of traumatism act solely through them.

Inflammation, whatever its original inception, may become so extreme as to lead to necrosis. Necrosis, on the other hand, often leads to inflammation, the dead cells constituting veritable irritants.

All forms of necrosis are accompanied to a greater or less extent by the various degenerations. In particular the cellular alterations are constantly present, and constitute the evidences of morbific action. (Reference will be made below to the cellular changes.)

There are several general forms of necrosis which, however produced, have a sufficiently distinct character to warrant separate descriptions. They are coagulation-necrosis, liquefaction-necrosis, caseation, fat-necrosis, hemolysis, and gangrene.

COAGULATION-NECROSIS.

Definition.—This is defined as that form of death of tissue in which the proteid suffers a change similar to or identical with coagulation. It is seen only in those tissues which are rich in proteids. The process is partly at least a species of fibrin-formation, and is allied to hyaline degeneration.

Etiology.—The causes of this condition are those above detailed for necrosis in general. Circulatory disturbances, except thrombosis or infarctions, play a minor *rôle* here. Chemical irritants and high temperatures frequently produce it. Bacterial poisons are very prone to produce it, especially those elaborated by the pyogenic bacteria, the tubercle bacillus, and the Bacillus diphtheriæ. About every abscess is found more or less coagulation-necrosis; it is one of the early changes in tubercles, and the fundamental element in the production of pseudomembranes. All exudates and transudates are liable to coagulation.

The serous and mucous membranes are most susceptible; next the muscular tissues (often the myocardium).

Pathologic Anatomy.—The tissue has a glazed, opaque, waxy appearance, and is firmer and paler than normal. In later stages the color becomes gray and the tissue inclines to soften. Microscopically it is seen that there is an exudate which has been

Fig. 23.—Obstruction of a branch of the renal artery with micro-organisms: necrosis of the tissue around the artery, and round-cell infiltration of the neighboring tissue (Thoma).

fixed in the tissues; the fibrin is seen (with suitable stains) in granules and fibrils with the homogeneous exudate closely packed about it. The cells soon lose their election for stains (Fig. 23). Early in the process the nuclei may stain faintly and present a

homogeneous appearance; later the cell disintegrates completely. In muscles the striations disappear; and in the cardiac muscle the intercellular cement-substance seems to be dissolved, for the cells often lie separated and present vacuolation and fragmentation. Pus, leukocytes, and red blood-cells in the affected areas all suffer the fate of the fixed tissue. The blood-vessels at the margin of the area are seen to be thrombosed. In the kidneys the tubules may contain firm casts.

Morbid Physiology.—Many chemicals cause coagulation by direct action. In the larger number of instances, however, it must be assumed that the fibrinogenetic substances which bring about the coagulation of the proteids are derived from the necrobiotic cells in the area or are carried thither by the lymphatic

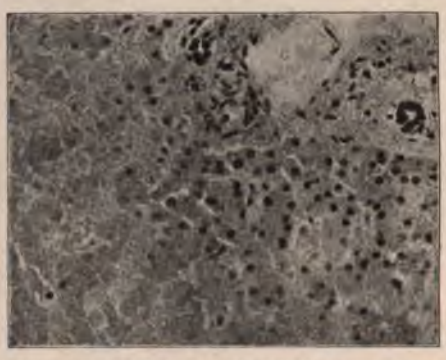

FIG. 24.—Coagulation-necrosis of the hepatic cells in a case of puerperal eclampsia (Karg and Schmorl).

cells. There is considerable evidence that bacterial products may act fibrinogenetically (Fig. 24).

An area of coagulation may be cast off by the process of ulceration, may undergo liquefaction, caseation, or suppuration, may be encysted, and apparently may be dissolved and reabsorbed. The area of disease may finally be converted into scar-tissue by secondary regeneration. More or less complete loss of function results from this form of necrosis.

LIQUEFACTION-NECROSIS.

Definition.—This change consists in the death of tissue with colliquation. It may be divided into primary and secondary forms. Secondary liquefaction-necrosis is the form in which other varieties of necrosis or degeneration are followed by liquefaction. Thus, areas of coagulation-necrosis, cheesy necrosis, and of inflammation, gangrenous tissue, and tumors may become liquefied.

Among the special forms may be mentioned vesicle-formation

and the softening of caseous tuberculous lesions. A very frequent seat of liquefaction-necrosis is the central nervous system, where the conditions are unfavorable to coagulation, so that liquefaction here follows pathologic conditions which would elsewhere produce coagulation. Circulatory disturbances, traumatism, and intoxications all cause softening in the central nervous system; the peripheral nerves are much less susceptible.

Pathologic Anatomy.—In the early stages the tissue is softer than normal and very rich in juices. Later, when the solution of the fibrillar tissues is advanced, the area becomes filled with a liquid of greater or less consistency, depending upon the tissue involved. The cells in the area are seen in all stages of degeneration; later, nothing but detritus is visible. In some instances, instead of becoming more and more fluid, the exudate undergoes coagulation. The color may be white, from the presence of an emulsion of fats; yellow, from fats and pigments; red and brown, from the presence of blood-pigment; and deeply colored when jaundice is associated.

The process consists in the infiltration of fluid into tissues and the more or less complete solution of the tissue-elements in it. It has been compared to the alterations of proteids by digestion—a reasonable deduction, since enzymes are often elaborated in the processes which give rise to liquefaction. In other respects the process resembles the solution in distilled water of proteids precipitated by salt solutions.

Areas of liquefaction may discharge their contents, may coagulate, may be reabsorbed, encysted, or in uncommon instances organized.

Fig. 25.—Tuberculosis of the suprarenal capsule, showing caseation of the tuberculous areas (modified from Kast and Rumpel).

CASEATION.

Caseation is the crude name applied to a complex process whose product has a cheese-like appearance (Fig. 25).

The condition is most frequently seen in connection with tuberculosis, although it is found in the other granulomata, and also in other pathologic processes. The preliminary *conditio sine qua non* of caseation is coagulation-necrosis.

The early tubercle, before the occurrence of softening, has an appearance like that of cheese, but is less homogeneous and more granular (Fig. 26). A form of caseation quite similar in appearance occurs in

pneumonia, in tumors, and especially in syphilis. Soft caseation is usually coagulation-necrosis advanced to liquefaction, together with fatty metamorphosis, so that the appearances are those of soft, creamy cheese. The liquefaction-necrosis of the central nervous system may present similar appearances.

Microscopically, the tissues in caseation show no cells preserving their staining-reactions; everything is converted into débris. Around the affected area is usually found a zone of coagulation, of inflammation, or both.

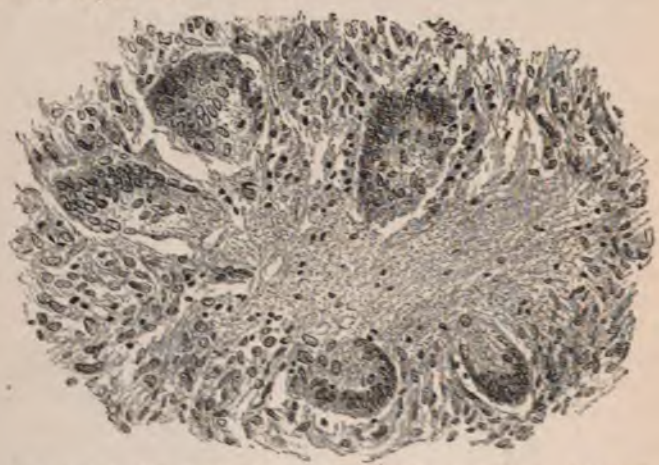

FIG. 26.—Large tubercle of the lung, showing cheesy necrosis in the center.

Tissues that have undergone caseation may be cast off, reabsorbed, or encysted; resolution is not possible. Calcification is a frequent termination.

FAT-NECROSIS.

This term is now used to designate a peculiar type of necrosis to which the fatty tissues are subject, and is distinct from ordinary fatty metamorphosis. In human beings it is seen almost exclusively in the abdomen, abdominal walls, and subperitoneal fat. In nearly all instances it appears in connection with pancreatic disease—cysts, tumors, obstruction to the duct, and the various forms of acute pancreatitis. In rare instances the pancreas has not seemed especially diseased. In one case I have seen of hypertrophic cirrhosis of the liver the omentum was affected, while the pancreas showed nothing but a moderate degree of fibrosis.

The affected areas are white in color, usually not larger than a pea; they may be soft or quite gritty. Inflammatory reaction may or may not surround them. On microscopic examination crystals of the fatty acids may be seen together with more abundant crystals of a combination of lime with the fatty acids. This

combination, it appears, is not a primary feature in the necrosis, suggesting that the fatty acids are first set free and then unite with lime-salts. In experimental work by Hildebrand and Flexner it seems to have been shown that the typical condition may be the result of direct action of the fat-splitting ferment of the pancreatic secretion. It is certain, however, that in some cases of pancreatic cysts containing steapsin no fat-necrosis has occurred. Bacteria have been supposed by some to be the essential agents causing the change, but this has not been demonstrated.

HEMOLYSIS.

Hemolysis, or blood-destruction, is a term limited to the red cells, and indicates destruction of the cell with dispersion of its hemoglobin. (The causes and other features are described under Pigmentations and Diseases of the Blood.)

GANGRENE.

Definition.—Gangrene, formerly defined as the death of tissue *en masse*, is perhaps best defined as the putrefaction of areas of necrosis. It may be *primary*, when a particular bacterium produces a gangrenous inflammation as its direct result, as in malignant edema; or *secondary*, when saprophytic bacteria decompose an area already necrosed from other causes. It may be *dry* or *moist*, according to the location and supply of fluids. It may furthermore be *circumscribed*, *progressive*, or *metastatic*.

Primary gangrene constitutes a specific affection, or rather a number of specific affections. Malignant edema, infectious emphysema, and some forms of anthrax may be included in this group. In these conditions there is violent infective inflammation with practically immediate gangrene of the affected parts.

Secondary gangrene is more common, and the appearances are very varied. The essential condition is putrefaction of a necrosed area.

Dry gangrene is usually due to vascular disturbances. As a result of arterial obstruction it is seen in the extremities in senility, and following arterial embolism or thrombosis of whatsoever nature if the collateral circulation be insufficient to nourish the part. Freezing may produce a dry form of gangrene, the vessels being blocked by thrombosis. Ergotism causes dry gangrene as a rule; the same may be said of Raynaud's disease. Finally, dry gangrene may result from the moist form when putrefaction is slow and evaporation of the fluids occurs. The putrefactive processes in the dry type are not marked, and may cease entirely. Dry gangrene is generally circumscribed, and the end-result of a typical case is mummification. The color is usually dark, finally black; early it may be yellow or brown; rarely, the tissues are very pale. There is little toxic absorption in these cases.

Moist gangrene presents numerous varieties. It is rarely produced by arterial occlusion, but is the usual result of extensive venous occlusion. Internal emboli, as in the pulmonary arteries or veins or mesenteric arteries, not infrequently cause gangrene of this form. It also occurs in the lungs as a result of inspirational or other pneumonias, abscess, neoplasms, bronchiectasis, and in diabetes. It is seen as a result of traumatism and pressure in severe contusions (especially with vascular injuries), in intussusception and strangulation of the bowel; as a result of torsion in movable kidneys, spleens, or tumors. It is frequent in the obstructed or strangulated vermiform appendix. Extensive moist gangrene of the extremities or other parts is not rare in connection with diabetes. The mucous membranes may become gangrenous as a result of various infections. A particular form is noma of the mouth and genitalia. It is seen as a rare condition in certain skin-diseases; and is not unusual in severe trophic lesions, as decubitus, cystitis, mal perforant, etc.

In moist gangrene the consistency of the part becomes progressively softer. There may be local or widespread emphysema. The color is usually dark brown, due to disorganized blood-pigment; the skin commonly becomes black, and is covered with blebs. About the area there may be a zone of coagulation-necrosis with vascular thrombosis; or a zone of inflammatory reaction which will produce a line of demarcation. In some cases, especially the diabetic, neither of these zones is formed.

The cells first succumb. The protoplasm and nuclei exhibit various evidences of degeneration, the nuclei disappearing and the cells becoming converted into granular detritus. Fat and the myelin-sheaths of nerve-fibers are reduced to free fat and fatty crystals. The muscle-cells lose their striations and become fragmented; the axis-cylinders of nerves fibrillate. Hemorrhages into the area are common, due either to erosion of vessels and expulsion of their thrombi by the pressure of the blood-current, or to a genuine hemorrhagic condition the result of toxemia. Connective tissue and elastic fibers resist longer than the cells, but finally become liquefied. The affected area contains crystals of pigment, fatty acids, cholesterin, leucin, tyrosin, phosphates, and carbonates. Ammonia, the fatty acids, indol and skatol, amins, sulphuretted hydrogen, carbonic acid, and other gases, usually of pronounced odor, are formed. There is more or less toxic absorption from these areas.

But two things can happen to an area of gangrene; it may progress and cause the death of the individual, or may become circumscribed. In dry gangrene and in the vascular forms of moist gangrene limitation is the rule; the other moist forms tend to be progressive. In the circumscribed form a line of demarcation is formed by inflammatory reaction, and the mass is finally cast off

as a *sphacelus* or slough if the area be superficial, or encysted if the area be internal. The latter cases may be followed by reabsorption of the contents and calcification of the sac.

GENERAL PATHOLOGY OF CELLULAR NECROSIS.

The cell as an individual element is liable to pathologic processes of various kinds that merit brief consideration, apart from definite forms of tissue-degeneration and necrosis.

Etiology.—The causes of cellular degeneration and necrosis are numerous, including mechanical, thermal, electrical, chemical, and vital (trophic) influences of various kinds. It is easy to demonstrate the influence of some of these causes in the unicellular organisms such as amebæ, and the changes thus produced may also be seen under proper conditions in the cells of the animal body.

Pathologic Anatomy.—The cell as a whole may show various forms of distortion, or internal change. Increased irritability and mobility of the protoplasm cause the projection of pseudopodia, and these may be separated from the body of the cell as rounded particles more or less resembling the original cell. This is easily demonstrable in red blood-corpuscles subjected to heat. Sometimes particles of the substances are discharged from the cell and vacuolations (expulsion-vacuoles) result. Certain influences, like cold, and metallic salts or other poisons, cause a reduced mobility and general contraction of the cell. Granular precipitation may at the same time occur within the protoplasm. In other cases solution of parts of the cellular protoplasm occurs, and vacuoles of varying size are thus produced.

Similar changes have been discovered in the nuclei of the cells, but certain special forms of nuclear change require special mention.

Nuclear solution or *hypochromatosis* may occur as a process of gradual fading or disappearance. The nucleus becomes more and more pallid, and finally is indistinguishable.

Karyorrhexis is a form of nuclear fragmentation in which the chromatin of the nucleus becomes broken up into small particles.

Hyperchromatosis is a degenerated condition of the nucleus, involving the nuclear membrane in particular. The body of the nucleus becomes pale and finally quite colorless, while the periphery is much more apparent and thickened. With the further destruction of the nucleus and cell the pigment-particles arranged around the periphery of the nucleus may become scattered through the cell.

Pyknosis is the name used to designate degeneration of the cell and nucleus in which the protoplasmic substance of these structures becomes more dense and their size correspondingly decreased. The cells become darker and frequently densely granular. When the nucleus is affected this contraction may leave a vacant zone about it, so that the nucleus apparently lies within a vacuole.

ABNORMAL CELL-DIVISION.

In addition to these diseases of the cell and its nucleus there are certain disorders of cell-multiplication that may be here described. Karyokinesis, instead of being a regular process of division of the nucleus into two daughter-nuclei, may proceed irregularly. Sometimes the process is *asymmetric*—*i. e.*, does not lead to equal division; in other cases it is *multipolar*, several instead of two daughter-nuclei resulting. Other less definite irregularities are sometimes observed, and some have held that cell-division may occur by a process of mixed karyokinesis and amitosis. It is important to recognize that some of the forms of nuclear degeneration (karyorrhexis; hyperchromatosis) may be mistaken for normal or abnormal karyokinesis.

CHAPTER V.

INFLAMMATION AND REGENERATION.

INFLAMMATION.

Definition.—By this name are designated the vascular, exudative, degenerative, and regenerative changes which occur in the living tissues as a result of irritation by chemical, mechanical, or thermal agents. No short definition contains the essence, for inflammation is by no means a simple process. It varies with the varying anatomical conditions or the vitality of the tissue involved, and with the intensity or nature of the irritant. Galen and his followers defined it by giving the cardinal symptoms: heat (*calor*), redness (*rubor*), pain (*dolor*), and swelling (*tumor*). To these may be added altered function (*functio læsa*).

Historical.—The earliest conceptions of inflammation were those of a specific entity. Subsequently various theories were offered in explanation of the several phenomena or symptoms. First, the blood-vessels were supposed to be influenced through the nervous system (*vascular theories*). Next, it was taught that the inflammatory irritant excites proliferative changes in the tissues (thus giving rise to round cells), and that this stimulation of the cellular activity invites more blood to the part (hence the hyperemia). This was the *cellular and attraction theory* of Virchow. Others, notably Cohnheim, described the emigration of leukocytes from the blood-vessels, and held this to be the essential feature of inflammation. This emigration was first described by Dutrochet (1824), Waller (1842), and Stricker; but Cohnheim was the first to systematize the *emigration theory*. According to Virchow, the first step is a formative stimulation of the cells; according to Cohnheim, degeneration of the vessels leading to emigration; according to Weigert, at least in many cases, the first step is necrosis of the parenchymatous cells. At the present day inflammation is generally regarded as purely reactive in nature, the irritation causing sometimes one and sometimes another primary lesion.

Phenomena in Inflammation.—These may be well studied in the mesentery or tongue of a frog. When the mesentery is exposed and spread under a microscope the first visible effect is a very temporary contraction of the arteries, which may disappear before the examination can be made. It is followed by dilatation of the arteries, and then of the capillaries and veins. The blood-current is first more rapid than normal, then slower, and may finally stop entirely (stasis), especially in the capillaries in the center of the inflamed area. Notable changes are seen in the circulating corpuscles. As the current becomes slower the leukocytes in the plasmatic zone increase in number and stick to the vessel-walls in a continuous row. In the capillaries clumps of leukocytes frequently alternate with masses of red corpuscles, or of red and white corpuscles in their customary proportion. Next, it may be observed that the leukocytes are passing through the walls of the

capillaries and veins and spreading in the outside tissues. At the same time a certain number of red corpuscles are passed through the capillary walls, and altered plasma escapes and infiltrates the tissues. In the connective tissues outside the vessels proliferative changes take place, leading to karyokinesis and formation of round cells resembling the emigrated leukocytes (Fig. 27). In struct-

FIG. 27.—Inflammation of the mesentery, showing overfilling of the blood-vessels, with emigration of leukocytes and diapedesis of red corpuscles (Ziegler).

ures in which there are parenchymatous (archiblastic) cells the latter undergo various degenerative changes, such as cloudy swelling, mucous degeneration, fatty degeneration, or even necrosis. Less frequently proliferation of the parenchymatous cells takes place. Every case of inflammation does not present all of these phenomena, nor is the subsequent fate of the exudate and altered cells always the same.

The phenomena must now be separately considered.

1. Changes in the Vessels.—The first effect of irritation may be momentary contraction of the arteries; but this is rarely observed. Usually the arteries dilate at once, and dilatation of the capillaries and veins promptly follows. The cause of this dilatation was formerly looked for in the nervous system, but it is more probably to be found in some degeneration of the vessel-walls. The microscope does not reveal this, but some of the phenomena connected with exudation and the circulation of the blood show that the cause must be in the vessel-walls.

2. Exudation.—The blood-current is at first more rapid, then slower, than normal. The former is due to dilatation of the arteries; the latter doubtless to some change in the walls of the blood-vessel increasing the friction. Mere dilatation of the vessels could not affect the current in this way. As the current grows slower the leukocytes in the plasmatic zone of the blood-stream increase in number and cling to the wall of the vessel. This is

purely a mechanical result of the slower rate of the blood-current. Finally, the leukocytes pass through the vessel-walls between the endothelial cells and collect on the outside of the blood-vessel, whence they more slowly migrate through the tissues (Fig. 27). This emigration of leukocytes occurs to a moderate degree normally, but is abnormal in degree in inflammation. Cohnheim ascribed it to disease of the vessels—increased permeability—the leukocytes being purely passive. Later observation indicates that the chief *rôle* in this excessive emigration must be assigned to the stimulated ameboid movements of the leukocytes. Degeneration of the vessel-walls, especially swelling and softening of the cement-substance between the endothelial cells, and the pressure of the blood, aid; but only to a minor extent. The cause of this active ameboid motion and tendency to emigration has recently been found to be an attractive force peculiar to the causes of inflammation. Pfeffer found that certain substances manifest strong attractive power for motile bacteria and various spores of plants. This has been termed *positive chemotaxis*. A repellant influence is peculiar to other substances, such as the toxins of bacteria, and to this the term *negative chemotaxis* has been applied. The irritant substances which cause inflammation are probably positively chemotactic in action; and in cases where mechanical injury causes inflammation such substances first result from mechanical destruction of cells and then occasion the subsequent phenomena of inflammation. In other inflammations the irritant causing the disorder may itself contain the positively chemotactic substance (see under Suppurative Inflammation). The microscopic appearance of the tissues after emigration of the leukocytes is characteristic. The capillaries are dilated and obscured by a mantel of exuded white corpuscles, and

FIG. 28.—Acute appendicitis, with extensive round-cell infiltration of all of the coats of the appendix.

the tissue around is infiltrated with migratory leukocytes. This appearance is called *round-cell infiltration* or *inflammatory infiltration* (Fig. 28). The round cells are mostly leukocytes, but some are new-formed connective-tissue cells, as will be subsequently described.

Coincidently with leukocytic emigration there is exudation of more or less altered blood-plasma. This is richer in albumin and more coagulable than dropsical fluid, which is a further indication that the blood-vessels are more permeable in inflammation than in health or mere congestion.

Finally, a certain number of red corpuscles escape from the capillaries by diapedesis. This is a purely passive process as far as the red corpuscles are concerned, being due to pressure of the blood. It is particularly marked when stasis has occurred. Accidental hemorrhage by rhexis may add to the blood in an exudate, but is not truly exudative.

3. Degenerative Changes in the Tissues.—The action of the irritants which excite inflammation sooner or later affects the tissues and causes degeneration or death. The first effect may fall upon the blood-vessel walls or upon the tissues. Weigert, Neumann, and others hold that the "primary effect" in inflammation is generally or always this tissue-degeneration, which excites secondary proliferation. This is certainly the case at times; and the discovery that tissue-degeneration leads to the formation of substances positively chemotactic in action would indicate the manner in which inflammation is brought about in these cases. The degenerative changes may be merely physiologic (some form of altered functional activity), or there may be structural alterations, such as cloudy swelling, liquefaction, fatty change, coagulation- or other forms of necrosis. The nature of the degeneration depends largely upon the severity of the irritation. Very powerful irritants cause necrosis at once, and not inflammation. It is the irritants which disorder, but do not entirely destroy, cells that are especially apt to excite inflammation.

4. Proliferative Changes.—Sooner or later in an inflamed area there are evidences of cellular proliferation, which occasions the appearance in the tissue of round cells closely resembling the outwandered leukocytes. They differ, however, in being somewhat larger, in having a larger and paler nucleus which is rounded or oval, and in their exhibiting evidences of karyokinesis. These cells are derived from pre-existing connective-tissue cells. Recently it has been claimed that they are in part redevelopments of cellular remnants which had almost or quite lost their cellular character, such as fibrillar protoplasmic prolongations of connective tissue. These are the "slumbering cells" of Grawitz. Virchow held the proliferative changes to be the essential feature in inflammation, and believed that all round cells have

this origin; Cohnheim denied the occurrence of proliferation, and ascribed to emigration the essential *rôle*. Later, it was held that the proliferative changes are not in reality a part of inflammation, but rather regenerative and for the purpose of repairing the tissue-injuries after inflammation (Fig. 29). At the present time we

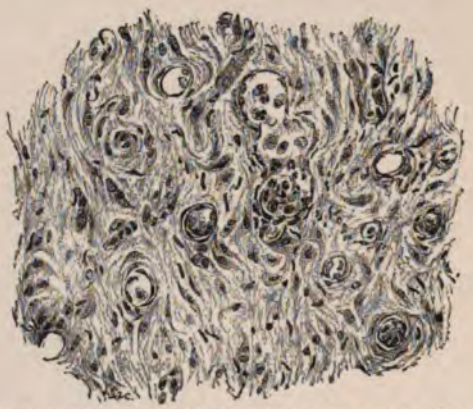

FIG. 29.—New blood-vessels and fibroblastic cells in a beginning adhesion of the pericardial layers.

must regard as factors in inflammation both emigration and proliferation, whether the latter in any individual case is due to direct stimulation of the cells, or is secondary to destructive changes, or is merely the result of increase of nutrition from the inflammatory congestion. It is conjectured by some that under chemotactic influences the cell-contents of fixed cells are incited to movements terminating in karyokinesis, just as the whole cell is influenced in the case of movable cells. Proliferative changes also occur in the parenchymatous cells, but in that case they are more strictly regenerative in nature.

Etiology.—Irritation by mechanical, chemical, thermal, or infectious agents causes inflammation when it is severe enough to disturb the vitality of the tissue and not sufficient to cause necrosis at once. When the irritant is brought to bear upon the tissues directly there is probably, first, cell-degeneration, followed by vascular disturbances and emigration. When the irritant acts through the blood, vascular disorders probably, as a rule, precede the tissue-changes. Micro-organisms may act by first destroying the cells, or may by their own death liberate from their substance some poison (protein) which is chemotactic. Disturbances of circulation, innervation, or metabolism may so alter cellular processes as to occasion the production of irritating and chemotactic products.

Special Forms of Inflammation.—The nature of the exu-

date and its subsequent changes lead to a variety of forms of inflammation. Other varieties depend on the activity and duration of the process.

(*a*) **Edematous or serous inflammation** is characterized by a copious exudation of fluid with comparatively little cellular matter, as in edema of the larynx, serous effusions in the serous sacs, etc. The fluid differs from dropsical fluid in containing more albumin and fibrin-factors.

(*b*) **Fibrinous Inflammation.**—The plasmatic exudate may clot at once and form a fibrinous membrane on free surfaces or a network within the tissues; this is termed fibrinous inflammation. Inflammations of the serous membranes are nearly always more or less fibrinous. Croupous pneumonia furnishes another example.

(*c*) **Diphtheritic inflammation** differs from the last in having associated with the coagulation of the exudate coagulation-necrosis of the cells of the part inflamed. Diphtheritic inflammation occurs especially in the pharynx and larynx, where it occasions pseudomembranes (Fig. 30). This is most frequently due to the

FIG. 30.—Pseudomembranous inflammation of the uvula: *a*, masses of micrococci; *b*, necrotic cells; *c*, round-cell infiltration; *d*, fibrin-network (Ziegler).

specific cause of the disease called diphtheria; but diphtheritic inflammation may result from a variety of severe irritations, such as bacteria, superheated steam, and chemical irritants. The diphtheritic membrane consists of a network of fibrin or of homogeneous or granular fibrin-masses enclosing degenerated epithelial cells and emigrated leukocytes. Sometimes it is quite superficial, involving only the surface-layer of epithelium; at other times the whole depth of the mucous membrane is implicated. The former are sometimes called croupous and the latter diphtheritic false membranes. These terms, however, are ill-defined and objectionable.

(*d*) **Suppurative inflammation** is characterized by unusual abundance of emigrated leukocytes and by the tendency to liquefaction. Bacteria are most frequently the cause; but it has been shown experimentally that croton oil, calomel, turpentine, and other substances are capable of producing suppuration. Of the bacteria, the commonest are the so-called pyogenic staphylococci and streptococci; but numerous forms, not essentially pyogenic, may occasionally prove so. Such are the bacillus of typhoid fever, the gonococcus, the Bacillus coli, and others. Recent studies ascribe to chemotaxis the important *rôle* in the action of bacteria in inflammation and suppuration. Either the products of the bacteria or substances derived from their own protoplasm (bacterioprotein—Buchner) exercise a powerful chemotactic influence, and thus occasion the massing of emigrated leukocytes (Fig. 31). The same or similar substances further

FIG. 31.—Embolic abscess in the myocardium, showing accumulation of large numbers of leukocytes (Karg and Schmorl).

prevent fibrin-formation or cause a solution of fibrin already formed, and thus the exudate liquefies and forms pus. This consists of a liquid part, the *liquor puris*, a modified blood-plasma, which differs from ordinary plasma in being less coagulable and containing notable quantities of albumose (peptone), and a corpuscular part, consisting chiefly of multinuclear leukocytes more or less degenerated. Some proliferated connective-tissue cells or wandering cells may be added from the neighboring tissue, but these are very few in number.

The entrance of bacteria of suppuration into the body may take place directly through wounds, or somewhat indirectly through small abrasions in the various mucous membranes. Some local injury may serve to determine the suppurative inflammation at a given place.

Abscess.—When this occurs in the substance of a tissue or organ the lesion is called an *abscess*. This consists of a collection of pus, which usually presents a creamy yellow color, but may be variously altered in odor or color by subsequent changes. Around the abscess the tissues present the proliferative changes described as part of inflammation. There are numerous round cells, differing from emigrated leukocytes and showing karyokinetic figures in the nuclei, and there are new blood-vessels and beginning organization. This restraining-wall of granulation-tissue was formerly regarded as a pus-producing membrane, and therefore called the *pyogenic membrane*. Abscesses, especially such as are due to bacteria, tend to soften the surrounding tissues in the direction of least resistance, and thus to break on the surface, discharging their contents by sinuous tracts or *sinuses*. Sometimes the pus of an abscess becomes inspissated by absorption of the liquid part and the residue undergoes various degenerative changes, such as mucous, fatty, or calcareous. At the same time the surrounding membrane advances to complete organization, and thus encapsulates the abscess.

Ulcer.—Suppurative inflammation with erosion of areas of the skin or mucous surfaces occasions *ulcers*. These have the same histologic construction as the wall of an abscess, the base of the ulcer being the same as the pyogenic membrane. In it may be seen small red points or granulations, which consist of loops of capillary blood-vessels surrounded by round cells. (The histology of granulation-tissue is more minutely described under Regeneration.)

The appearance and pathologic course of ulcers vary widely. Sometimes rapid destruction of the tissues causes large and spreading ulcers, called *phagedenic*. Others extend in one direction while healing in other parts, and are called *serpiginous*. The granulations may be too rapid in growth, forming red fungous masses which fill up the ulcer. In other cases the ulcer remains dry and *indolent*, showing little tendency to heal.

In suppurative inflammation of mucous membranes without ulceration the emigrated leukocytes reach the surface between the epithelial cells, some of which are loosened and cast off together with an excessive excretion of mucus (Fig. 32). The result of these processes is a *mucopurulent catarrh*.

Suppurative inflammation of serous membranes leads to collections of pus in the serous sacs. Unlike other tissues, there is usually considerable fibrin-formation combined with the purulent exudation in these situations.

(*e*) **Productive Inflammation; Chronic Inflammation.**—In this form the proliferative changes predominate over exudation and degeneration. This may be due to the extent of the primary tissue-injury or to the nature of the cause. Whether the regenerative processes are always reactive and consequent upon primary

destruction, or may be stimulated directly by the irritant, is unsettled. This form of inflammation is often called *interstitial* when occurring in the substance of organs, and is distinguished from *parenchymatous* inflammation, in which the parenchymatous or proper cells of the organ are said to be involved. Strictly speak-

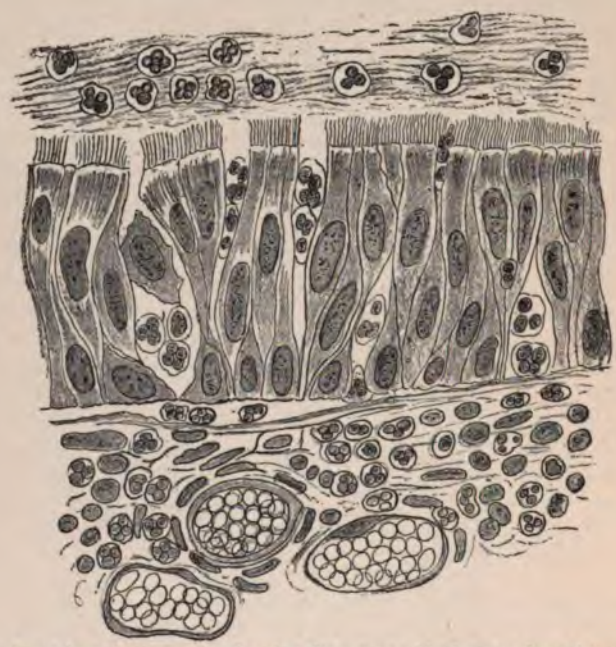

FIG. 32.—Acute bronchial catarrh, showing the escape of leukocytes from the submucous tissue between the epithelial lining cells (Thoma).

ing, this distinction is ill-founded, but the terms are convenient to distinguish cases in which parenchymatous degeneration is prominent from those in which proliferation and new formation of connective tissue are the more striking features.

Repair of Wounds.—Productive inflammation is well illustrated in the healing of wounds. If the lips of a clean, incised wound are drawn together at once and kept closely apposed, rapid healing occurs, which is called *healing by immediate union.* In these cases a microscopic examination shows slight exudation from the surfaces of the wound and proliferated connective-tissue cells. The epithelial continuity is restored by proliferation of the old epithelial cells. Should apposition be less immediate or less accurate, the amount of exudation is greater. If the wounded surfaces are examined twenty-four hours after the injury, they are found red and swollen and soon they become glazed in appearance. The

microscopic features here are the same as in the case of healing by immediate union, excepting the amount of exudation is greater. Healing proceeds in the same way but more slowly, and is called *healing by first intention.* In neither case is there great congestion. If the wound be irritated by foreign bodies or kept exposed, there will be seen on the surfaces, after two or three days, small red elevations, known as *granulations,* which consist of loops of new-formed capillaries covered by emigrated and new-formed round cells, and sometimes (after longer intervals of time) giant-cells (Fig. 33). The surface may be covered with pus. The proliferated round cells gradually elongate and form new fibrous tissue (see Regeneration), which afterward contracts, forming *cicatrices* or *scars.* The epithelial continuity is re-established by multiplication of the old epithelial cells at the edges of the wound. This form of healing is called *healing by second intention* or *healing by granulations.*

FIG. 33.—Loops of blood-vessels in granulation-tissue (Thiersch).

The formation of adhesions following inflammation of the serous surfaces occurs in much the same

FIG. 34.—Adhesive pericarditis, showing fibrin-deposit, with new blood-vessels extending upward into it (Perls).

way as wounds heal. The primary exudation is largely fibrinous and causes agglutination of neighboring surfaces. Subsequently

the proliferated connective-tissue cells penetrate this fibrinous exudate, as do newly-formed blood-vessels (Fig. 34). Thus a union of vascular channels is effected between the adjacent inflamed surfaces and organization follows.

Precisely similar changes occur in the tissues surrounding a foreign body, as a piece of sponge, or around a portion of dead tissue. In these cases the exudative and proliferated cells tend to penetrate into the foreign mass, as occurs also in the organization of thrombi. There is also in these cases a greater tendency to the formation of giant-cells (by division of nuclei without division of the cell-body) than in ordinary granulations. If the foreign mass can be softened and absorbed, this gradually occurs, and later merely a scar will indicate the location; if it cannot be absorbed, connective tissue encloses or encapsulates it.

General Fibrosis.—A tendency to widespread productive inflammation is noted in certain individuals. This affects the blood-vessels especially (general arteriocapillary fibrosis, general angiosclerosis), and also the liver (cirrhosis of the liver), the kidneys (interstitial nephritis), and other organs (Fig. 35). The cause of these changes is supposed to be some general intoxication—alcoholic, gouty, syphilitic, or the like.

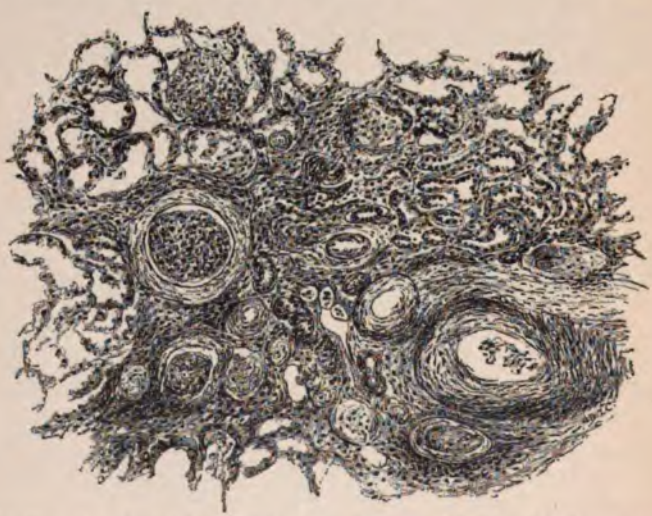

FIG. 35.—Chronic interstitial nephritis: great increase of connective tissue around the glomeruli, renal tubules, and blood-vessels; from a case of arteriocapillary fibrosis.

Productive inflammation may affect other tissues than the fibrous connective tissues. Reference has already been made to epithelial proliferation in the healing of wounds. Similar epithelial processes of greater activity or duration may lead to warty growths of the skin or polypoid outgrowths on the mucous membranes. In pharyngeal catarrhs considerable proliferation of the adenoid tis-

sues is not unusual. So also thickening of cartilages, bones, or the periosteum is not an unusual result of inflammation of these structures.

(*f*) **Hemorrhagic Inflammation.**—More or less diapedesis of red corpuscles generally occurs in inflammation; but sometimes the irritating cause falls with such peculiar force on the blood-vessels, or the general condition of the patient (cancer, tuberculosis, hemophilia, scurvy) is so unsatisfactory that the exudate is unusually rich in red corpuscles. These are always serious inflammations, and are to be distinguished from ordinary inflammations in which accidental hemorrhage occurs.

(*g*) **Necrotic or gangrenous inflammations** likewise depend for their occurrence upon the severity of the irritation or the state of the general system.

Resolution after Inflammation.—In cases of trivial exudation the emigrated leukocytes may re-enter the blood-current or may escape through the lymphatics. The liquid exudate is similarly disposed of; while the proliferated connective-tissue cells (if there be any proliferation) remain *in loco* or become wandering cells. When the exudate is more abundant the liquid elements may be removed in the same way, but the cells first undergo degenerative softening and are reduced to the form of an emulsion, which is gradually absorbed. The degenerated parenchyma in inflammation may recover if the degeneration is not severe, or may be softened and removed. Phagocytic cells often play a prominent part in the removal of broken-down cellular remains, pigment-masses, and the like.

The reparative changes in inflammation may be so slight as to lead to no discoverable lesion for some time after the process is completed; but where large damage has been done there is apt to be a permanent scar or some other productive lesion.

REGENERATION.

Definition.—The term regeneration is applied to the formation of new cells or tissues to take the place of those destroyed. Regeneration may be physiologic or pathologic. The former is that which occurs in the normal life of the organism and by which the cellular wear and tear is counterbalanced. Pathologic regeneration is the more massive and often atypical reconstruction that follows disease or injuries.

Etiology.—The cause or mechanism by which normal regeneration is brought about is more or less obscure. The cells have an inherent tendency to multiply, and this goes on to a certain point at which the normal development is complete. This limit is probably maintained by some restraining influence, but the nature of this is unknown. In the skin and mucous membranes, where

physiologic regeneration is most active, new cells are constantly produced and the older cast off. In what manner the balance is so maintained that production and destruction keep their equal pace is as yet matter only for speculation. The idea of action and reaction occurs naturally to the mind, and it seems probable that the reproductive processes are dependent in some way upon the loss of substance. In some cases the normal restraining influence seems to be deficient and giant-growth results. In all forms of normal or physiologic regeneration the reconstructed cells are exactly like the pre-existing cells, and the status of the tissue is unaffected. In highly-specialized cells, such as those of the nervous system, regeneration seems to be intracellular—that is, the cells are constantly rejuvenated by supplies of nutriment rather than reproduced *in toto*.

In pathologic regeneration there seems to be abnormal stimulation of the reproduction of cells as well as a reduced restraint. It is not improbable that various toxic substances have the power of stimulating the formative process, though this has not been actually demonstrated. In all cases in which regeneration follows mechanical, thermal, or toxic causes there is, first, destruction of cells, and following this regeneration. In such cases the relief from the accustomed pressure may serve as a withdrawal of restraint, but at the same time there is doubtless augmented formative energy. The latter may result from the same agency as that which caused the primary cell-destruction, or it may be due to the influence of formative irritants derived from the dying and dead cells. The demonstration that micro-organisms are able to produce substances having a strong attractive or repellant influence upon leukocytes gives some warrant to the belief that similar substances are at work in the regenerative changes that accompany bacterial diseases. In the case of tissue-destruction due to other causes similar products possibly play a part.

Pathologic Anatomy.—In the normal regeneration of cells the process is one of gradual *cell-multiplication* without marked changes of any sort. Pathologic regeneration may be equally simple, but more often there are complicated changes in the pre-existing tissues and new formation of blood-vessels preceding or accompanying the regeneration. The vascular regeneration is a necessary preliminary, having the purpose of supplying abundant nutriment to the tissues undergoing proliferation.

Cell-multiplication occurs in two ways, the direct and the indirect. The former method is one of simple cleavage, by which the cell is divided into two or more parts. This mode of division is unusual. The common method is called *indirect segmentation*, *karyokinesis*, or *karyomitosis*. In this method complicated changes begin in the nucleus and finally lead to division of the cell into two or rarely into several parts. It is unnecessary to refer to the

histologic stages in detail, but in a general way we may describe the process as follows: (1) the nucleus of the cell enlarges and the chromation-fibers become thicker and less closely woven than normally; (2) U-shaped loops of chromatin-fibers arrange themselves around a central clear space or *polar field* to form a *mother-wreath;* (3) these loops then undergo longitudinal cleavage and the separated parts move one to one pole and the other to the opposite pole of the cell, forming *daughter-stars*, which eventually become coarse and then fine skeins of new nuclei; (4) the protoplasm of the cell finally divides and the process becomes complete.

Pathologic Regeneration.—In the reconstruction of areas of destruction of surface-epithelium (mucous membranes, skin) the process of cell-multiplication, as above described, occurs in the epithelial cells under and around the area of destruction, and eventually the surface is fully restored. The same form of regeneration may occur in other surface-cells, as those of serous membranes, and also in the substance of organs or solid tissues when the cellular damage is slight. In cases of more extensive destruction the connective tissues play an active part and the restoration is atypical, the new-formed tissue containing a greater amount of connective tissue than the pre-existing tissue. In the case of highly specialized tissues, such as the gray matter of the brain or cord, the regeneration is confined to the connective tissues. In massive regeneration or regeneration of specialized tissues, then, the principal changes are those affecting the connective tissues.

Regeneration of Fibrous Connective Tissues.—It is difficult to draw a line between the process of inflammation and regeneration. In the latter process there is always some congestion and cellular infiltration (emigration of leukocytes); later, multiplication of the fixed connective-tissue cells and new formation of blood-vessels occur.

The multiplication of connective-tissue cells may be more or less abundant. The old connective-tissue cells swell and the nuclei divide by karyokinesis, new cells of rounded outline and with rather pale nuclei resulting. At the same time the cells of the capillary blood-vessels become swollen and here and there budding processes are sent outward (Fig. 36). These may unite with similar processes from an adjacent or the same capillary and then undergo central vacuolization, which proceeds along the loop, converting it into a channel with here and there new-formed nuclei within the protoplasmic wall. The latter finally becomes differentiated into definite endothelial plates and the new capillary is completed. Around these capillary loops lie the emigrated leukocytes, and especially the new-formed connective-tissue cells. The latter are the *formative cells* of the regenerating tissue. In the case of fibrillar connective tissues they are called *fibroblasts* (Fig. 37); in the case of cartilage, *chondroblasts;* in the case of bone, *osteo-*

blasts. The process is practically the same in the different connective tissues, the differentiation occurring secondarily. The formative cells become larger and more or less elongated, and the formation of intercellular substance then follows. In the case of fibrillar connective tissue the cells elongate considerably, and by segmentation of their extremities in part contribute to the formation of the intercellular fibrils. The rest of the fibrils are formed by cleavage of the homogeneous in-

FIG. 36.—Formation of new blood-vessels, as seen in the tail of a tadpole (Arnold).

FIG. 37.—Fibroblasts forming fibrous tissue (Ziegler).

tercellular substance in which the cells are at first embedded. This intercellular substance, in part at least, is doubtless a product of cellular activity.

When the processes of regeneration have reached this stage the new-formed tissue consists of an abundance of round and elongated cells, with a small amount of fibrillar intercellular substance. Subsequently the latter increases in amount and by contraction further adds to its density. During this late stage the number of cells becomes less considerable, and eventually there may be only here and there a cell embedded in dense bands of fibrils. Nearly always, however, there is greater cellular richness in new-formed connective tissues than in the normal tissues of the same kind.

Regeneration of other Connective Tissues.—The reconstruction of cartilage and bone may occur by primary formation of ordinary connective tissue and subsequent transformation. This is especially the case when the regeneration springs from the periosteum or from membranous connective tissues. In other cases, however, the regenerative processes produce cartilage and bone directly. In the regeneration of fatty tissue there is first formed an ordinary connective tissue, and subsequently the fatty deposit occurs within the cells.

Regeneration of Parenchymatous Tissue.—When connective-

tissue regeneration follows lesions of the parenchymatous organs the cellular elements of the latter are reproduced in some measure at the same time that connective-tissue hyperplasia is taking place. The degree of restoration of the normal structure on the one hand or of formation of connective tissue on the other hand depends upon the intensity of the original cause of destruction and the extent of the injury. In glandular organs reproduction of acini may occur to a considerable extent, but these are usually atypical in character. In some cases this atypical glandular formation may become pronounced, and an adenomatous structure may result. (For further details regarding this, see Adenoma.)

Regeneration may occur in practically all of the tissues of the body, though in a varying degree. It has not been shown, however, that the large nerve-cells are capable of proliferation, though the occurrence of such cells in certain tumors suggests the possibility.

METAPLASIA.

Metaplasia is the term applied to the transformation of one form of tissue into another without the intervention of a stage of regeneration by cellular multiplication. In many instances the change consists of a transformation of the intercellular substance, as, for example, when ordinary connective tissue is converted into myxomatous tissue, or fibrillar connective tissues are altered to cartilaginous or even bony tissue. The cells themselves suffer secondary changes. In other cases of metaplasia the cells may be primarily altered, as when ordinary connective tissue is changed to fatty tissue.

CHAPTER VI.

PROGRESSIVE TISSUE-CHANGES.

THIS term may be used to designate pathologic conditions in which there is a decided tendency to formation of new tissue.

HYPERTROPHY.

Definition.—The term hypertrophy is applied to a pathologic condition in which a certain part increases beyond the normal size, without marked alterations from the normal structure. The term hypertrophy is frequently used loosely to designate enlargements of various kinds in which but one tissue of an organ is increased, or in which there is deposit of abnormal exudate. Such instances are not, strictly speaking, cases of hypertrophy.

Etiology.—The causes of hypertrophy are quite numerous. In some cases there is a distinct increase of functional demand brought about in some way or other, as in the hypertrophy of the muscles of athletes; in the hypertrophy of a kidney after disease or removal of its fellow; or in the hypertrophy of a limb after injury to the opposite limb. The direct increased demand for work occasions the hypertrophy. Sometimes there appears to be a special tendency to hypertrophy, as is evidenced by the occurrence of congenital or hereditary giant growth. Most of these, however, are instances of peculiar and abnormal development, rather than of hypertrophy, the latter being a condition developed pathologically in parts previously well formed. Disturbances of the nervous system may play a part in the development of some hypertrophies, but these influences are obscure. Continued congestion undoubtedly stimulates tissue-growth, but this element is the means whereby hypertrophy is effected rather than the original cause.

Pathologic Anatomy.—Parts the seat of genuine hypertrophy are uniformly increased in size. This is well seen in the condition termed giant growth, or gigantism, in which the bony framework and other tissues may be uniformly affected, the individual being of excessive size. Sometimes local giant growth of the skeleton and external tissue is observed; as in the case of one member or a single finger. This has often been found in corresponding members on the two sides of the body. In certain cases termed hypertrophy, in which this designation is more or less justified, lack of uniformity in the increase of the organ or part affected causes irregular increase in size.

Histologically, hypertrophy may be *simple* or *true hypertrophy*, and *numerical* (hyperplasia). In the former there is increase in the size of the individual cells; in the latter the cells increase in number, though the individuals are not excessive in size, and indeed often smaller than the normal cells. In the hypertrophy of the uterus during pregnancy and of the heart-muscle in compensatory enlargement, simple hypertrophy predominates. Hyperplasia is very commonly a factor in hypertrophy of any kind, but may be so strictly limited to one tissue of an organ, notably the connective tissue, that the term hypertrophy is in no way applicable. Between these extremes there are all grades of cases, in many of which it is difficult to determine whether the designation hypertrophy is applicable or not. In some cases the clinical designation *hypertrophic enlargement* is used, though the condition is strictly one of hyperplasia of the connective tissue, with a tendency rather to atrophy than hypertrophy of the proper substance of the organ. Instances of this are hypertrophic cirrhosis of the liver, some cases of hypertrophy of the heart-muscle, etc.

Pathologic Physiology.—Hypertrophy results from an

increased demand upon an organ or member, and leads to increased functional capacity. Thus in the case of a diseased kidney the opposite kidney may be capable of compensating for the deficiency; in the case of laborers the enlarged muscles may meet every demand made upon them. There are occasional instances of more or less genuine hypertrophy, resulting from diseased conditions, in which the excessive functional capacity causes marked disturbances, as, for example, in case of enlargement of the thyroid gland.

TUMORS.

Synonyms.—New-growth, Neoplasm, Pseudoplasm.

Definition.—In its broadest etymologic significance the term tumor designates an abnormal swelling in any part of the body. This definition, however, is not applicable to tumors in the ordinary sense. Inflammatory growths and collections, such as abscesses, hyperplastic deposits, and the like, are excluded. Pathologists, however, have always found it difficult to construct an accurate definition for tumors or to draw sharp lines of separation between them and the inflammatory or infectious swellings that occur in various diseased conditions. An attempt to establish an ultimate boundary-line is evidenced by the term *autonomous new-growths* applied by Thoma. This name is used to designate the supposed spontaneous origin of new-growths and their independence of ordinary causes, such as are recognized in the production of inflammatory outgrowths and the like. It cannot be said, however, that tumors are causeless, and in the discussion of the etiology we shall have occasion to refer to certain definite factors known to aid in their production. It is true, however, that the growth of tumors is practically always out of proportion to the amount of local irritation or to the severity of other factors that may be conceived as playing some part in the etiology; and in the great majority of cases the causes, whatever they may be, are obscure or unknown. A negative definition perhaps best suits for the delimitation of this term tumor. Thus we may exclude from the category of tumors all swellings in which some sufficient cause is discoverable, and include the apparently causeless growths among the true tumors.

Etiology.—A great number of theories have been entertained to explain the causation of tumors.

Among the older writers there was a disposition to attribute the occurrence of tumors to a *constitutional dyscrasia*, or a diseased state of the fluids of the body. This explanation, however, is based entirely upon speculation, and is most unsatisfactory in that the original dyscrasia is as difficult to explain as the tumor supposed to result from it.

Recently a number of more elaborate theories have been constructed that resemble this older one, in ascribing the growths to some form of disturbance of vital activity and of cell-proliferation, without explaining the cause of such disturbance. For example, we may refer to the theory that tumors result from a retrograde change in vital properties of certain cells, so that they tend toward the original properties of the sperm-cells and multiply in a purposeless and indeterminate manner. Another theory would explain the occurrence of new growths somewhat upon the basis of infection, assuming instead of an exogenous infection with micro-organisms an endogenous infection. The author of this theory explains that in consequence of some thermic, chemical, or other irritation certain cells may become, so to speak, infectious, assuming the *rôle* of a sperm-cell and stimulating the adjacent cells to abnormal multiplication. Such theories, however, are entirely speculative, and leave the etiology as little settled as before.

Virchow strongly advocated the theory of *external irritation*, and was able to cite numerous examples of tumors that had arisen in consequence of more or less definite causes. Thus in cases of carcinoma of the breast, in the epithelioma occurring on the lips in pipe-smokers, and in the epithelioma of chimney-sweeps, there is at times a definite history of unusual irritation, and the relation of cause and effect seems easily traceable. It must be admitted, however, that there is some further underlying cause which renders one individual liable to tumor-growth, while another is not thus predisposed, and though it is probable that some tumors owe their origin to irritation as the exciting-cause, all cases cannot be thus explained.

Cohnheim advanced the interesting theory that *defective development* lies at the basis of tumor-formation. According to his theory, there are frequently small errors of development leading to the inclusion or misplacement of portions of the original blastoderm in the midst of tissues derived from a different layer of the embryo. These inclusions or *embryonic rests* are independent of the function of the part in which they lie, and are assumed to be liable to subsequent sprouting with the consequent formation of tumors. There is evidence that this theory contains a certain measure of truth, and some tumors, as, for example, certain ovarian growths, tumors of the parotid region, and others, seem to originate in this way. The theory, however, is not by any means universally applicable.

Recently an *infectious character* has been ascribed to malignant and benign growths, and there is no doubt that in certain respects tumors resemble infectious processes of definitely ascertained kinds. Their effect upon the general health and their tendency to metastasis are very significant facts. Notwithstanding this, however, the proof of the infectious nature of tumors remains to

be furnished. In the case of certain sarcomata (lymphosarcoma) it seems possible that bacteria are the immediate factors. In carcinomata and other epithelial new-growths, as well as in sarcoma, certain forms of intracellular animal parasites have been described, though the nature of these bodies remains still in doubt; and recently the theory is gaining ground that blastomycetes are active in the production of tumors. Upon the whole, though it must be admitted that the infectious nature of tumors is probable, the actual proof still remains wanting. In experiments upon animals it has been possible in a few cases to demonstrate inoculability. The significance of this fact, however, must not be overestimated, and it certainly cannot be assumed without further proof that this evidences the infectious nature of the growths.

Predisposing Conditions.—Whatever may eventually prove to be the immediate cause of tumors, it is certain that predisposing causes are often of great importance. The occurrence of certain forms of tumors in persons of advanced age and the occurrence of tumors in other persons whose vitality has been reduced by disease give evidence that a constitutional predisposition is sometimes requisite for the formation of the new-growth. The nature of this vital defect has sometimes been speculated upon, and retrograde vital metamorphosis of the cells or other like changes have been assumed to occur. These theories, however, are purely speculative. In some cases there is evidence of a family predisposition, and heredity was formerly regarded as of great importance. While this element cannot be entirely denied, it has certainly been overestimated.

The Structure of Tumors.—In their histologic structure tumors do not differ absolutely from healthy tissues. In all cases they conform more or less with the structure of some one or more tissues. The cells composing tumors invariably represent some one or several types of normal cells, though they may differ in being larger or smaller than the normal cells, or in being of embryonal or undeveloped character. In the arrangement of the cells, however, there is a notable difference, and tumors may be described as being atypical proliferations as far as their organic or tissue arrangement is concerned. The orderly disposition of cells and stroma or intercellular substance seen in the normal tissues and organs is wanting, particularly in the tumors in which organic arrangement is simulated. There may be in some cases entirely typical glandular acini, but the relation of these to each other and the absence of regularly disposed excretory ducts render the tissue as a whole atypical.

The structure of tumors is always closely related to that of the tissue from which it springs, a primary tumor invariably growing in a part in which there is some tissue at least of the type

simulated by the tumor, and it is from this tissue doubtless that the tumor takes its origin. A connective-tissue growth invariably springs from a part in which connective tissue of some form has pre-existed, and epithelial growths from a part in which there has been epithelium. Metaplasia, or the transformation of one variety of tissue into another variety, with the production of a tumor, does not occur. This statement, though applicable also to secondary tumors, is sometimes difficult of demonstration from the fact that the secondary growths may take origin from cells transported to the seat of growth from a primary tumor, though not normally found in the part in which the secondary tumor has arisen. The occasional discovery of a primary tumor in a locality in which the form of tissue composing the tumor does not occur may be explained upon the assumption (based on some actual demonstrations) that embryonic rests had been deposited in the seat of tumor by faulty development.

The Shape of Tumors.—This depends to a large extent upon their manner of growth, their situation, and the influence of surrounding parts. We may distinguish, first of all, between *circumscribed* and *infiltrating* growths. The former may be of various shapes, but are distinguished by their sharp delimitation and often by the existence of a distinct capsule; the latter are indeterminate, and the extent to which they involve the healthy tissues cannot be accurately determined. Circumscribed tumors usually grow centrally or in an expansive manner, the new cells being produced in the interior and gradually pushing the older parts outward toward the surrounding tissues. The infiltrating growths are eccentric in development, and may result from a gradual extension of parts of the periphery of the original growth or by the development of secondary nodules in the neighborhood which become confluent with the original mass. Of the circumscribed growths we may distinguish small nodules of spherical or ovoidal form buried in the substance of the tissue or projecting from some surface as more or less hemispherical elevations. These may be large or small, and the terms *miliary*, *tubercular*, *nodular*, and the like are employed to designate the individual grades. When a tumor projects from the surface in such a manner that the projecting part is larger than the part between the projection and the surface of the body or the organ involved, the term *fungiform* or *fungoid* tumor may be applied, while in the cases in which the new growth is attached by a more or less narrow pedicle the name *polyp* or *polypoid tumor* is applicable. Wart-like growths are known as *verrucose* or *papillary* tumors, and those in which a distinct cauliflower-form is developed are called *dendritic*.

The Number of Tumors.—*Primary tumors* are usually solitary at their onset, though examples of multiple primary growths, such as carcinoma involving both breasts simultaneously,

or simultaneous appearance of carcinomata or sarcomata in different parts of the mucous membrane or elsewhere, may be observed. In these cases it is often likely that there was a single tumor at the very onset, with secondary growths originating before the primary growth had reached any considerable magnitude. Primary benign tumors are usually solitary, but sometimes may be found in considerable number, and there may be enormous numbers scattered in various parts of the body. Thus in cases of multiple enchondromata or multiple fibromata the number may from the first be very great.

Secondary tumors are usually multiple. In most cases the number of nodules found post-mortem or during life is considerable, and sometimes they are so numerous that large portions of the body may be literally studded with new-growths. This is seen very well in the secondary sarcomatous or carcinomatous nodules involving the peritoneum and the other serous surfaces, in which cases the degree of involvement is simulated only by that seen in miliary tuberculosis.

Pathologic Physiology.—In most cases tumors take no part in the functional life of the part in which they occur or of the individual. What influence they may bear to the general metabolism is as yet practically unknown. Cases, however, are recorded in which large lipomatous or other tumors have been found to suffer practically no change, while the individual in whom they occurred was undergoing progressive emaciation from lack of nutrition. That there is a certain amount of function in some cases is shown by the fact that biliary pigment is detected in the cells in certain carcinomatous tumors of the liver or abortive milk-formation in cancers of the breast. It may be that the want of proper organic arrangement and particularly the lack of excretory ducts account for the lack of function; but whatever the cause, it is certain that as a rule the functional activity is practically *nil*, or at all events perverted. With very few exceptions it may be said that tumors are entirely parasitic, living at the expense of the organism and contributing nothing to its development or nutrition.

Certain tumors disturb the general health. This result may be due to secondary degenerative or inflammatory changes dependent upon lack of nutrition or upon irritation and bacterial infection; or to obscure causes connected with the tumor-growth itself. The progressive cachexia of carcinoma is still unexplained, though in some cases hemorrhage and interference with organic function play a part.

Tumors may be classified as *benign* or *malignant*. The former do not affect the general health of the patient in any notable degree, and are dangerous mainly by reason of the pressure they may exert on vital structures or the secondary changes (hemorrhages,

softening, suppuration) to which they are liable. Malignant tumors generally disturb the general health from the first, and, in addition, tend to recur after removal and spread to other parts of the body (by direct invasion or by metastasis through the circulation or lymphatic channels). The terms *primary* and *secondary* tumors refer to the original and the metastatic growths respectively.

Classification of Tumors.—No very satisfactory classification is possible at the present time, and it is unlikely that any will be constructed until more definite knowledge regarding the etiology is obtained. The older classifications were based upon the shape, the physical properties, or the nature (whether destructive or harmless) of various forms. Virchow offered a classification based on the histology (histogenetic classification); others have grouped tumors according to the embryologic derivation of the tissues from which the new-growths originate or of the tissue composing the tumor. It is perhaps wisest to attempt no classification of any kind, and in the following sections I have arranged the various tumors according to their histologic characters without attempting to establish groups.

FIBROMA.

Definition.—A fibroma is a tumor composed of connective-tissue cells and fibers resembling those seen in fibrillar tissue.

Etiology.—The causes of fibroma are as obscure as are those of tumors in general. There are many facts, however, which point to the importance of irritation or injury as exciting causes. Among these may be mentioned the development of a peculiar form (keloids) in scar-tissue and the resemblance of these tumors to spontaneous fibromata, and the appearance of fibrous nodules in the skin at points of friction or definite pressure or in places irritated by discharges.

It is impossible to draw sharp lines between fibromata and hyperplasias of connective tissue following irritation. In the skin and superficial tissues there occur hyperplastic connective-tissue processes, constituting elephantiasis, which in some cases are distinctly the result of irritation and in other cases seem purely spontaneous. The elephantiasis of tropical countries, often due to occlusion of the lymphatic channels by filariæ, and the thickening of the skin and adjacent connective tissue of the legs around old ulcerations or eczematous areas, are instances where distinct irritation is the cause. On the other hand, congenital elephantoid conditions of the skin are seemingly spontaneous or causeless, and some of the cases in later life have the same characteristic. The diffuse hyperplasias of the viscera, though often distinctly inflammatory, may appear without adequate discoverable cause, and, according to the view of some authorities, are to be looked upon as diffuse fibrosis or fibromatosis, rather than

as inflammatory conditions. In ordinary cases of cirrhosis of the organs the connective-tissue growth is entirely diffuse, but thickenings may occur in certain situations and the resemblance to tumor-formation is much more striking. This is sometimes the case in the liver, but particularly in the kidneys. In the breast there are cases in which no dividing-line can be drawn between chronic interstitial mastitis and fibroma. The microscopic appearances are practically identical. A distinction, if any can be made, is based upon the nodular character and spontaneous origin in the one and the opposite conditions in the other.

Appearance.—The naked-eye appearance of fibromata is usually quite characteristic. The tumor may be hard (Fig. 38)

FIG. 38.—Hard fibroma (Warren).

or soft (Fig. 39), according as it resembles loose or dense connective tissue in structure and according to the amount of

FIG. 39.—Soft fibroma of the subcutaneous tissue.

edematous liquid or associated myxomatous degeneration of the intercellular substance. The growth is more or less rounded and

usually enclosed in a distinct capsule. In the substance of organs it is spherical or tuberous, and when near the surface projects more or less. When it springs from a mucous or serous membrane or from the skin the weight of the tumor may gradually lead to a polypoid formation. Some of the fibromata of the skin are arborescent or dendritic in form, and keloids are frequently irregular or star-like in outline. The rounded and encapsulated tumors may be lobulated, though more frequently they occur in a uniform mass.

Seats.—The points of origin from which fibroid tumors arise are very numerous, though they always spring from pre-existing connective tissue. Among some of the more common localities may be mentioned the subcutaneous connective tissue, the submucous tissue, the periosteum of bones, tendons and tendon-sheaths, and the fibrous covering of nerves. Of the internal organs, the uterus, the ovaries, the kidneys, and heart-muscle are the most important. Less frequently fibromata are found in the serous membranes of the chest and abdomen or of the central nervous system. The fibroids of the skin, the uterus, the nerves, and the mucous membrane of the nose are the most important.

The mammary gland presents several interesting forms of inflammatory or fibromatous new-growth. First, there is a diffuse form of interstitial mastitis in which the entire breast becomes indurated; this is distinctly inflammatory. In other cases nodular or lobular areas of thickening occur, and in these the evidences of

FIG. 40.—Intracanalicular fibroma (Perls).

inflammatory action are sometimes obscure or wholly wanting. Some of these are certainly instances of true fibroma (*fibroma mammæ nodulum*). In still another group of cases the fibromatous proliferation of the connective tissue projects into the tubules and acini of the gland, pushing the epithelium before it and sometimes sprouting or proliferating in polypoid form within the tubules.

The gland in such cases may present a striking macroscopic appearance on section. Numerous cystic formations may be visible with projecting dendritic formations within, causing an appearance somewhat like that of a section through a cauliflower (Fig. 40). Microscopically the proliferations of the connective tissue between the tubules and projecting within the tubules constitute the characteristic features. The term *intracanalicular fibroma* has been given to such cases. Obstruction of the tubules in certain areas may lead to very marked cystic distention. Combinations with sarcoma are frequent.

Structure.—The definition explains the structure of fibromata. On section through the body of the tumor the fibrous nature may be revealed by a distinct concentric or radiating striation, particularly in the case of hard fibromata. The softer varieties are much less likely to present this feature. The color is usually gray or whitish, and may be glistening when there is mucous degeneration, or yellow in the case of associated lipoma. Microscopically a striking feature is the connective-tissue cell, which is star-like and branching in the softer tumors, and compressed, spindle-shaped, or elongated in the case of the hard varieties. The intercellular substance is composed of a fibrillar network and homogeneous or granular material traversed by thin-walled blood-vessels, ofttimes having merely an endothelial coat. Cavernous dilatation and rupture of the vessels may cause a distinct hemorrhagic appearance of the section; but such conditions are rare.

In some cases embryonal round cells may be abundant and a distinct sarcomatous transformation of the tumor may occur. This, however, is rare. In other instances, as has already been remarked, myxomatous tissue may be conspicuous, and all grades of transformation from a pure fibroma to a pure myxoma may be met with, especially in the case of soft fibroma. Fatty degeneration of the cells and lipomatous infiltration or associated lipoma are also frequent. These forms, the myxomatous and lipomatous, are particularly frequent in the submucous and subcutaneous connective tissues. Calcareous degeneration occurs in large fibromatous tumors, particularly in those of the uterus, and very rarely true ossification has been reported. Less commonly association of fibroma with other forms of tumor-growth is found. Among these the combination of fibroma with leiomyoma is usual in the uterus.

Nature.—Fibroma is essentially a benign tumor, though recurrence occasionally takes place after removal, this being particularly the case with keloids and some of the polypoid growths of mucous membranes. In some of these instances there is undoubtedly a resemblance to sarcoma, if not actual sarcomatous transformation. As a rule, fibroid tumors are destructive only in

so far as they are capable of producing mechanical injury by pressure. The growth of the tumors is usually exceedingly slow.

MYXOMA.

Definition.—Myxoma is a tumor composed of connective-tissue cells and an intercellular substance containing mucoid material in more or less abundance. The gelatinous substance of Wharton in the umbilical cord and the vitreous humor of the eye are normal types which myxomata resemble in their structure.

Etiology.—The causes and the nature of myxomata are practically the same as those of fibroma, and intermediate forms make it difficult to draw a sharp line between the two.

Appearance.—A typical myxoma is a soft, more or less flabby growth enclosed by a capsule, and having a rounded outline. It may project from the surface of the body or of an organ as a hemispherical elevation, or may hang by a narrowed pedicle in the form of a distinct polyp. The latter is frequent in the mucous membranes, but may occur in the skin as well. Sometimes the tumor is lobulated, and the lobules may be visible or may be easily felt. Occasionally lipomatous growths are diffuse, having no capsule and marked by no definite limits.

Seats.—Among the common situations are the subcutaneous and submucous tissues and the connective tissues of certain organs, notably the mammary glands. They may occur along the course of nerves, in the brain or the spinal cord. The tumor may be

FIG. 41.—Myxoma, showing stellate cells separated by a gelatinous (mucoid) intercellular material.

solitary, or, like fibroma, may be met with in numbers. Congenital myxoma has frequently been found.

Structure.—Microscopically the characteristic features are stellate or spindle-shaped connective-tissue cells which lie within

a matrix of myxomatous material (Fig. 41). The latter is homogeneous or slightly granular, and somewhat refractive to the light, giving the surface a glistening quality. The cells themselves may be entirely normal young connective-tissue cells, or they may present evidences of fatty degeneration. Round granulation-tissue cells are met with in some instances, either scattered through the tumor or in certain areas, and may be so abundant as to justify the term myxosarcoma. The vascular supply is usually poor, and the blood-vessels resemble those of fibroma in being only partially developed. Association with fibroma and lipoma is frequent. Cartilaginous tissue may be found in myxomatous tumors of the parotid gland or testicle, and in these cases the myxomatous portion is rather an association than a degeneration of the original chondroma. Myxomatous degeneration of chondromata, osteomata, fibromata, and sarcomata is, however, a frequent occurrence.

Nature.—Myxoma is benign like fibroma, but recurrence is not infrequently observed, and in a few instances metastasis has been reported. It is difficult, however, to assert the absence of sarcomatous change in these instances. The growth of myxomata is slow.

LIPOMA.

Definition.—A lipoma is a tumor composed of fatty tissue like that of the normal subcutaneous tissue. The epiploic appendages of the intestines are the normal type which lipomata resemble.

Etiology.—There seems to be a tendency, consisting perhaps in some derangement of the trophic nervous system, to the growth of these tumors. It is difficult at times to draw a sharp line between circumscribed lipomata and diffuse fatty growth. Localized fatty or myxolipomatous accumulations in myxedema and a curious and apparently causeless deposit of fatty tissue sometimes observed in the subcutaneous tissue of the neck in men, represent the border-line between lipomata and ordinary obesity. Some individuals have a marked liability to constant overgrowth of fat in different parts of the body, and the term "lipomatosis" is not inapplicable. This fatty growth does not apparently depend upon the character or quantity of food, nor even upon sedentary life in some cases, but rather on an obscure tendency to adipose accumulation. Traumatism seems to play no part, though fatty infiltrations are prone to occur around areas of injury or disease, and in degenerated organs.

Appearance.—Lipomata are usually circumscribed and encapsulated tumors having a lobulated character, the latter being due to septa of connective tissue. On the surface of the body they appear as somewhat hemispherical elevations which may reach enormous proportions. Rarely they become polypoid. In

the interior of the body, as, for example, when they arise in the submucous or subserous connective tissue, they are very frequently, though not always, polypoid. Sometimes they become detached and may be retained in one of the cavities of the body as free bodies. On section the appearance is that of fatty tissue, though in some cases it is more firm from the association of fibrous tissue, and in other cases less firm from the nature of the fatty tissue itself or from associated myxomatous change. Lipomata may be solitary tumors, or there may be many. As a rule, they appear in adult years or middle life, but congenital lipomata are not very rare; and occasionally they are found to begin in childhood.

Seats.—Among the situations in which lipomata occur the most common are the subcutaneous fatty tissue of the back, shoulders, buttocks, or limbs, the submucous, and the subserous tissues. They may arise either in the normal fatty tissue or in connective tissues in which fat is not normally present. Some authors, however, deny the possibility of lipomata arising excepting from preexisting fatty tissue. Of the organs, the mammary gland and the kidney are most frequently involved.

Structure.—Microscopically lipomatous tumors resemble the normal fat. It is notable that the cells are larger—that is, contain more oil—than the normal fat-cells, and this is strikingly the case in some instances, but is not always demonstrable. The vascular supply is about the same as in normal fat, though occasionally large vessels with thin walls are seen. Associated myxomatous or fibrous change may cause a variation of the microscopic appearance.

Lipomata may undergo softening from necrosis, but more frequently become calcareous in part or completely.

Nature.—This is the most benign form of tumors. Recurrence after more or less complete removal does, however, at times occur. A lipoma is dangerous only from its weight or position. It does not contribute to the support of the system in case of starvation.

XANTHOMA.

Definition.—This term is applied to two possibly distinct though similar forms of new growth. The *xanthoma vulgare* occurs most frequently in the eyelids and may be confined to that situation. The growth appears in the form of flat elevations of a yellow color. Generalized xanthoma beginning about the eyes is less frequent. *Xanthoma diabeticorum* is a similar affection of diabetic patients. It occurs at a more advanced age, is more distinctly inflammatory, the masses are more rounded, and the eyelids and face are rarely affected.

Structure.—The histology of xanthoma is that of modified fatty tissue. It resembles embryonal adipose tissue, and there is usually more or less round-cell infiltration as well. Some authors regard the latter as a tendency to sarcomatous change; others look upon it as inflammatory.

Nature.—Xanthoma is eminently benign. The diabetic form is subject

to sudden and apparently causeless involution. The ordinary form may similarly subside, though much less commonly.

CHONDROMA.

Definition.—A chondroma is a tumor composed largely or entirely of cartilage. It is difficult to draw a sharp line between outgrowths of cartilage from existing cartilage or bone due to irritation from definite and independent tumor-like growths. A group of cases of intermediary character is that including cartilaginous nodules formed in tendons of muscles subjected to frequent irritations, as in the deltoid muscles in soldiers carrying heavy arms, and in the adductor muscles of the thigh in horseback riders. In these cases normal connective tissue seems to be directly transformed into cartilage, though the influence of irritation is undoubted.

Etiology.—A congenital disposition, sometimes hereditary, is unquestionably present in certain cases. Virchow maintained that chondromata often spring from remnants or islands of cartilage left in abnormal situations, as in the midst of bone, as the result of imperfect fetal development. The same explanation would account for parotid chondromata on the assumption that parts of the branchial arches are misplaced and remain in the substance of the parotid gland.

Irritation has been referred to. Direct traumatism is sometimes the cause of cartilaginous outgrowths from bone, particularly when fractures have occurred.

Appearance.—Two distinct forms may be considered, and these are somewhat different in appearance. They are (1) cartilaginous outgrowths, ecchondroses or ecchondromata, and (2) independent cartilaginous tumors, or chondromata proper.

Ecchondromata present themselves as rounded or somewhat irregular outgrowths from bones or cartilages. Sometimes they are wart-like in form and may occur in rows or groups. They may be firmly attached, or may be loosely united to the bone. The most frequent and the most characteristic are the outgrowths in the articular cartilage occurring in chronic arthritis, particularly in rheumatoid arthritis. Occasionally they become detached after their formation, and in the joints may thus become free bodies. The large chondromata are generally distinctly lobular or irregular in outline.

Chondromata springing from the inner surface of bones (possibly originating from the marrow itself) may grow uniformly by repeated or constant proliferation and lead to a globular swelling of the affected bone (Fig. 42). The true bony covering becomes more and more thin until it may actually perforate.

The true chondromata are usually rounded bodies; they pre-

sent lobular irregularity when they reach considerable size, the lobules being separated by connective tissue.

All forms are hard, though secondary softening may occur.

FIG. 42.—Chondroma of the thumb (Warren).

In cases in which association of mucous, sarcomatous, or other soft tissue is present the consistency is correspondingly less. In some cases central softening leads to cystic formation. The liquid in the cyst is more or less turbid and occasionally sanguinolent.

Seats.—Ecchondroses and chondromata, for the most part, take their origin from bone, cartilage, or periosteum. In some cases, however, they originate in connective tissue, as that of the tendons, by a process of cartilaginous metaplasia. Cartilage-tumors are met with in some of the glandular organs, notably the parotid gland, testicle, and ovary; and rarely they occur in the lungs, especially at the root and springing from the peribronchial cartilages.

Ecchondroses are most frequent about the long bones, as those of the extremities, and particularly at the epiphyseal attachments. They are not at all infrequent, and may reach considerable proportions in these situations. Situations of great clinical importance are the interpubic and occipitosphenoidal junctions. In the former situation ecchondroses projecting inward may interfere seriously with labor, and in the latter place cartilaginous outgrowths may penetrate the dura and exercise injurious compression on the brain. Allusion has been made to the ecchondroses of the joints in arthritis.

Chondromata proper may occur in the neighborhood of bones, in the muscles and tendons near their bony attachments, and in the organs mentioned, but in the last situation are rarely pure, myxoma being the most frequent associate.

Structure.—Chondromata resemble hyaline, fibrous, or elastic

cartilage, the first-named being much the most frequent. The tissue differs from normal cartilage in the fact that the cells are frequently without capsules and are much less regularly arranged (Fig. 43). The intercellular substance is more abundant and is

FIG. 43.—Chondroma of the hyaline type.

frequently gelatinous, mucoid, or fibrous, and not rarely the different types of cartilage occur within narrow limits. Association with myxoma and sarcoma, or both, is common, especially in the parotid and testicles, the proportion of the several ingredients varying greatly. Tumors of this kind are spoken of as *mixed tumors*. Calcification and true ossification are not infrequent, particularly in cartilage-tumors intimately connected with bone. The term *osteochondroma* is applied in such cases. The name *osteoid-chondroma* is applied to chondromata in which the intercellular substance is trabecular in arrangement, suggesting bone-structure, but in which actual ossification has not occurred. Such growths are met with about the bones and, as a rule, spring from the periosteum.

Degenerative changes are frequent. Myxomatous degeneration may occur, though myxoma is more frequent as an association than as a degeneration. Softening may occur in the center of the mass, and may lead to cyst-formation, this being particularly common in the myxochondromata. Growths of this kind are frequently quite vascular and hemorrhages into the cysts may occur. Eventually such cases may show scarcely any cartilage-cells, a few being perhaps detected in some part of the cyst-wall. A single hard lump may be left at one side of the cyst, the rest of the tumor having softened.

Nature.—Chondromata are essentially benign, and are danger-

ous only through the pressure they exert. Removal of a part may have a beneficial influence in causing calcification of the remainder. Metastasis may undoubtedly occur in pure chondromata through transportation of particles in the circulation. Such cartilaginous emboli have often been demonstrated. The secondary growths are most frequent in the lungs. Metastatic chondromata are, however, more frequently chondrosarcomata than pure chondromata.

OSTEOMA.

Definition.—An osteoma is a tumor composed of osseous tissue. Osteomata are closely allied to cartilaginous tumors, and frequently transformations occur.

Etiology.—The same difficulty is experienced in distinguishing inflammatory outgrowths or exostoses from true bony tumors, as in the case of cartilaginous growths. Enlargement

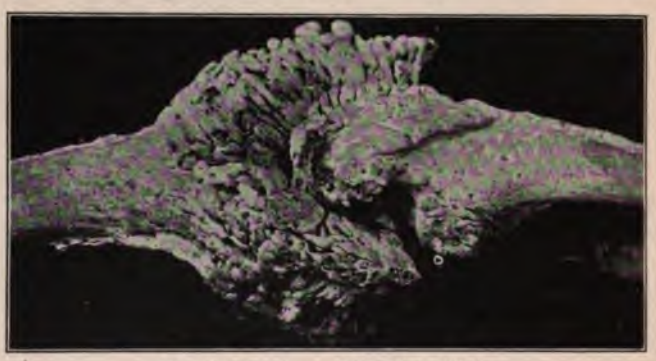

FIG. 44.—Exostoses of the elbow-joint.

of the facial bones in leontiasis ossea, of the bones of the extremities in acromegaly and hypertrophic pulmonary osteo-arthropathy, and ossifications of the muscles in myositis ossificans, are instances of border-line conditions separating true tumors from inflammatory hyperostoses. Irritation and traumatism undoubtedly play a part in the etiology, even in neoplasms unattached to the bone, and in the case of bony outgrowths injury is generally the immediate cause. An underlying predisposition undoubtedly exists, and explains the occurrence of congenital multiple bony tumors.

Appearance.—Two forms may be distinguished, as in the case of chondromata: (1) outgrowths or exostoses and osteophytes, and (2) the osteomata proper, or heteroplastic osteomata. Exostoses and osteophytes are distinguished one from the other by their shape and appearance rather than by any essential difference. The former are direct outgrowths of more or less wart-like character; the

latter are more extensive and present the appearance of bony deposits upon bones, and are less closely attached (Fig. 44). In both forms the surface of the growth is irregular, nodulated, or wart-like (Fig. 45). The consistency is that of bone, and the size varies from that of small outgrowths to masses as large as a fist. On section two forms may be distinguished; the hard or *osteoma durum*, and the soft or *osteoma spongiosum*. Sometimes the substance of the tumor is exceedingly dense, and the term *osteoma eburneum* is applied.

FIG. 45.—Osteoma of the lower jaw (Warren).

The heteroplastic osteomata, or those separated from the bone, are more rounded and, when of considerable size, usually nodulated and lobulated. In the serous membranes they occur as flat bony plates.

Seats.—Osteomata spring from the bone or cartilage, or from connective tissue near the bones. More rarely they arise in other connective tissues, in the serous membranes, or in certain organs, notably the testicle and parotid gland.

Osteomata connected with bones are most frequent about the epiphyses, at the attachments of muscles, or at the seat of old fractures from which abundant callous has been deposited. The skull-bones may be affected on the outer or inner surface, and often an elevation is noted without and within at the same spot. A form of clinical importance is that in which exostoses occur on the inner aspect of the metatarsal bone of the great toe from compression of tight shoes. In the maxillary bones osteomata may originate about the roots of malformed teeth. In cases of accumulation of cement-substance beginning at the neck of the tooth the term *dental osteoma* is applied, and these are strictly comparable to osteomata. In cases in which proliferation of the dental pulp has occurred the term *odontoma* is applicable, and the tumor is not of osseous character. The bony growths sometimes seen in the serous surfaces nearly always arise in areas in which there has been thickening from chronic inflammation. They are most frequent in the dura mater of the brain, particularly the falx cerebri; though the membranes of the cord, the pleura, or pericardium may be involved.

Structure.—Microscopically osteomata resemble more or less accurately bone-tissue. They vary, however, in different areas, and mixtures of cartilage with bony tissue are frequent. Secondary degenerative changes (softening) may occur and association

with tumors of other character are not infrequent (chondroma, myxoma, fibroma, sarcoma).

Nature.—These growths are eminently benign, do not recur, and do not give metastasis. Their situation sometimes makes them troublesome or dangerous.

LYMPHANGIOMA.

A lymphangioma is a tumor composed of dilated lymph-vessels or lymph-spaces; more frequently the latter. It is difficult to separate dilatations of lymphatic channels due to obstruction from hyperplastic processes. Congenital enlargements of certain parts are met with which seem entirely dependent upon the abnormal development of the lymph-spaces. These constitute the condition called *elephantiasis congenita mollis*, in which the subcutaneous tissues are boggy or edematous, and even distinct cystic formations occur. *Congenital cystic hygroma* is an instance of dilatation of the lymph-spaces. Congenital enlargement of the tongue, termed *macroglossia;* of the lips, *macrocheilia;* and of the skin, *nævus lymphaticus;* are other instances of the same process. In all of these, in addition to the dilatation of the lymphatic spaces, a marked proliferation of the connective tissues as well as the muscle (in the case of the tongue) is striking; but the process in all probability originates as a dilatation of the lymph-spaces. The terms *lymphangioma cavernosum* and *cavernoma lymphaticum* have been suggested for these cases of dilatation of the lymph-spaces. On staining with silver-salts the endothelial lining of the spaces may be readily demonstrated. Actual enlargement and varicosity of existing lymphatic vessels may occur, but is extremely rare in the form of circumscribed growths; it is met with more frequently in association with general processes, such as elephantiasis. The bursting of dilated lymphatics may lead to *lymphorrhea* or external discharge of lymph when the process involves the skin, or to effusions of lymphatic character when the serous cavities are involved. Chylous pericarditis, pleuritis, and ascites are thus produced. Rupture of dilated lymphatics along the urinary tract (kidney or bladder) occasions *chyluria*. Lymphangioma is a benign process in the pathologic sense.

HEMANGIOMA.

Definition.—An hemangioma, or angioma as it is more frequently called, is a tumor-like formation composed principally of blood-vessels. Strictly speaking, many of these are not tumors, being merely localized dilatations and elongations of pre-existing blood-vessels. Some, however, represent actual proliferations. Two varieties may be described, that in which the blood-vessels are merely distended (*angioma teleangiectaticum*), and that in which

there are enlarged spaces lined with endothelium (*angioma cavernosum* or *cavernoma*). In many tumors the blood-vessels are somewhat enlarged; these are spoken of as teleangiectatic.

Etiology.—Congenital malformation certainly plays some part in certain cases, as the frequency of hemangiomata in the new-born and particularly at the junction of the branchial arches would indicate. Injury, however, and mechanical causes generally also play a part, and pre-existing disease, particularly fibroid inflammatory processes, may contribute to the subsequent dilatation and proliferation of the vessels (see below).

Appearance and Seats.—The angioma teleangiectaticum may involve only the arterioles and capillaries, and in this case a bright-red color is observed. The tumor appears as a spot on the surface of the skin, more or less sharply outlined from the surrounding tissue. It is not elevated and has the same consistency as the healthy parts. Usually it occurs as a multiple condition, and the larger are often surrounded by smaller spots. The skin is the favorite seat; but the subcutaneous tissue and sometimes the mucous membranes are involved. Less commonly the veins are implicated, when a dark-red color is observed (port-wine-stains).

If a circumscribed portion of the circulation is uniformly involved, the vessels thicken and elongate, and a peculiar form of hemangioma results. In these cases the arteries are greatly thickened and tortuous, and form bunches under the skin, suggesting to palpation a bundle of earth-worms; while the surface of the skin presents peculiar irregular elevations without of necessity any change of color (aneurysma racemosum seu cirsoideum). This is not infrequent in the scalp. A similar condition of the vessels is observed in the varicosity of the legs, labia, or other parts. It is most frequent in the hemorrhoidal veins, constituting the ordinary hemorrhoids. (These conditions will be more fully described in discussing the diseases of the vessels.)

Cavernous angiomata present themselves as more distinctly tumor-like formations of dark venous color, involving the skin or subcutaneous tissues, the retrobulbar tissue of the eye, the mucous membranes of the nose or pharynx, and certain organs, as the mammæ, the kidney, the spleen, but particularly the liver. Like the other variety, they may be congenital, but more frequently arise in later life, especially that of the liver, which is most common in old persons. The appearance is that of a more circumscribed tumor, sometimes showing a distinct capsule and varying in consistency with the degree of distention of the blood-spaces. In the skin it projects slightly from the surface (nævus prominens); in the liver the tumor does not project.

Structure.—The definition explains the structure in general. The blood-vessels of teleangiectatic angiomata may be simply di-

lated capillaries with a lining of endothelium and a fibrous outer coating. More commonly the vessels are considerably thickened and held together by a reticular connective tissue. In rare instances the vessels are so closely packed and the walls so thickened that when the blood is removed the appearance is not unlike that of the tubules of a sweat-gland. The cavernous angiomata present large spaces lined with endothelial cells (Fig. 46). Between these

FIG. 46.—Cavernous angioma (Warren).

spaces are parallel fibers of connective tissue which form the framework of the tumor. In cases involving the liver the proper substance of this organ disappears completely, leaving only anastomosing spaces with a fibrous framework. Virchow taught that the fibrous process was primary, and by traction and pressure gradually induced dilatation of the vessels and atrophy of the liver-substance. Some of the more recent writers believe that the dilatation of the vessels is the primary condition. The capsule sometimes found surrounding the cavernous angioma is certainly a secondary formation.

Angiomata of the skin may enclose the hair-follicles and sweat-glands; those of the subcutaneous tissue frequently show areas rich in fatty tissue (angiolipoma); secondary angiomatous change of tumors is probably the result of dilatation of the pre-existing or new-formed vessels. Sometimes secondary change may occur in the connective tissue of the vessels of an angioma,

as in the plexiform angiosarcomata, in which the blood-vessels are surrounded by ensheathing sarcoma-cells (see Fig. 46). Certain cylindromata have the same origin.

Nature.—Angioma is essentially benign, and may continue through life without enlarging. Hemorrhage and inflammatory or necrotic changes are its dangerous consequences.

LYMPHADENOMA.

Definition.—This term is here used to designate a more or less malignant form of new-growth affecting the lymphatic glands or other lymphadenoid tissues, and having the structure of lymphatic tissue. The lymphadenomata may be considered as forms of sarcoma. The term *lymphosarcoma* is sometimes applied, but is more appropriately given to growths of more definite sarcomatous nature, but having the reticulated structure of lymphadenoid tissue. Other names applied to lymphadenoma are malignant lymphoma and lymphoma.

Etiology.—It is exceedingly difficult to establish the limitations of the term, and especially to decide whether or not certain cases in which definite etiologic factors have been discovered belong to the group under consideration or should be separated. There are cases of infectious enlargement of the glands and traumatic swellings that cannot be distinguished histologically. In some cases even the clinical course is the same and a separation seems impossible. For example, the glands in a number of instances of Hodgkin's disease (as far as the clinician can establish this diagnosis) have been found to contain tubercle-bacilli. We must conclude that general lymphatic tuberculosis may occur in the clinical form of Hodgkin's disease, but cannot assert that all cases of the latter are tuberculous. In other cases various micrococci and bacilli have been found, but none of these organisms have been shown to be specific. In a few instances bodies resembling protozoa have been discovered.

Appearance and Seats.—Lymphadenomata present themselves as more or less considerable enlargements of the lymphatic glands of a single group or more commonly of a number of groups in different parts of the body. All of the glands of the group may be involved, or only a few. The individual glands retain their shape, as there is usually no tendency to extension beyond the capsule of the gland. In exceptional cases, however, the process is of a more infiltrating kind and the capsule is penetrated or destroyed. These instances furnish a connecting link between the lymphadenomata confined within the capsule of the glands and the true lymphosarcomata, tumors of lymphadenoid structure occurring in tissue normally devoid of lymphoid elements.

Lymphadenomata may be *soft* or *hard*, according to the amount

of connective tissue and the denseness of the cellular infiltration and proliferation. On section the tumors are found to be grayish or whitish in appearance, and exceptionally may show slight areas of necrosis or softening. Extensive softening is exceedingly rare. The individual glands of the group may be clearly distinct, or may be fused together by interglandular connective-tissue overgrowth or by the penetration of the lymphadenomatous process through the capsule.

When superficial lymphatic groups are involved tumors of various sizes are produced, and project as knobby or rounded enlargements beneath the skin. The latter is freely movable over the tumor unless the growth has penetrated the capsule or secondary inflammatory changes have occurred. In the case of internal

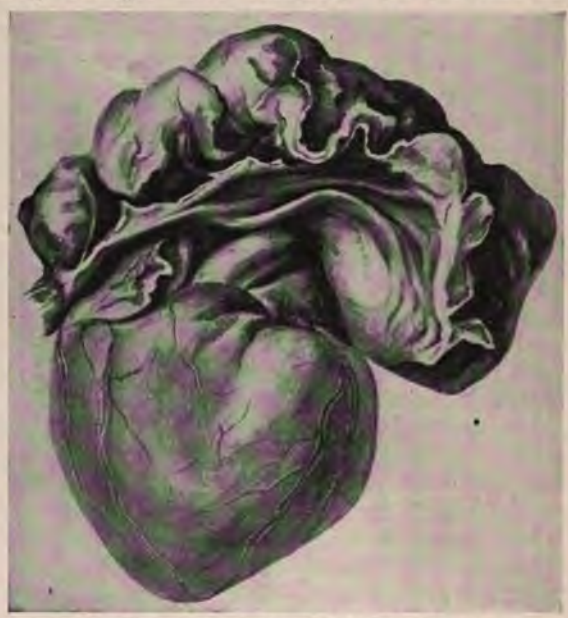

FIG. 47—Lymphadenoma (lymphosarcoma) probably originating in remnant of thymus gland: the tumor covered the upper part of the heart like a hood. The illustration shows the tumor turned upward and exposing the pericardium on its under surface.

glands large intrathoracic or abdominal growths may be formed, and may exercise destructive compression of vital parts.

Similar lymphadenomatous growths may spring from the lymphatic tissues of the gastro-intestinal tract—tonsils, lymphatic follicles of gastric and intestinal mucosa.

Sometimes the primary growth seems to begin in the thymus gland or its remnant (Fig. 47). Tumors of considerable size are produced in these cases, and their origin is recognized by their shape (two lateral parts united by a sort of isthmus) and by the absence

of the appearance of a conglomeration of glands. In these cases the adjacent glands, and later more distant groups, are involved. Lymphadenoma may be confined to the glands, but frequently extends to the solid organs by metastasis. The spleen, liver, and kidneys are the organs most frequently affected. They become enlarged and indurated, and on section show light-colored areas of lymphadenoid tissue. Similar "lymphoid infiltration" may be seen in the heart, lungs, or other parts.

Lymphadenoma may affect the bone-marrow secondarily and perhaps primarily. (Reference will be made to this under the title Myeloma.) Sometimes the tumors have a yellow or green color and are called *chloromata* (*q. v.*).

Structure.—The finer structure of lymphadenomata is precisely that of lymphadenoid tissues. There is a reticulum, more or less pronounced, formed by branching cells which are united by their prolonged extremities. In the meshes of this lie round cells containing large rounded nuclei. The cells are perhaps less uniform in size than those of normal lymphatic glands and large cells are more abundant. The secondary lymphomatous infiltrations of the spleen, liver, etc., have similar structure, but the reticulum is less distinct. Sometimes this may not be apparent in the primary growths; in such instances the tumor is likely to be considered a simple round-celled sarcoma.

Nature.—Lymphadenoma is variably malignant. In a small proportion of the cases this malignancy is of local character—that is, the growth tends to invade the neighboring parts. In most instances there is rather a tendency to general involvement of the lymphatic system, with metastatic deposits in various organs. To cases of this kind the terms Hodgkin's disease, pseudoleukemia, and adenia have been given. These cases present themselves in the form of a progressive anemia (lymphatic anemia—Wilks), often with irregularly relapsing fever (chronic relapsing fever—Epstein), and especially with lymphadenomatous tumors in the superficial or deep lymphatic groups (axillary, cervical, inguinal, mediastinal, or abdominal). The disease progresses more or less rapidly, and terminates in death from cachexia and exhaustion in from one to three years. Occasionally the course is rapid, repeated hemorrhages or purpura may occur, and a fatal termination is reached in a few weeks or months. The whole course of the disease is suggestive of an infectious process.

The relation of cases like the above and leukemia is certainly very close. The glandular tumors and the secondary changes in the organs are the same, excepting that the lymphatic glands are more prominently involved in ordinary lymphadenoma. The only striking difference is found in the blood. In leukemia there is marked and characteristic leukocytosis; in the other condition this is absent. Many cases have, however, been observed in which

Hodgkin's disease has become leukemia; and some authors do not hesitate to speak of the two diseases as identical and representing merely two stages of a common affection. According to this view, we might classify cases as *leukemic* or *aleukemic lymphadenoma*. This view seems to me well grounded.

The blood in aleukemic cases shows more or less pronounced reduction in the number of red cells, and a normal, reduced, occasionally a moderately increased, proportion of leukocytes. The mononuclear leukocytes are sometimes in relative excess. In acute cases nucleated red cells may be found.

The causes and nature of the irregular fever are uncertain. It may be due to an infectious cause, or may be the result of breaking up of leukocytes and liberation of ferments.

SARCOMA.

Definition.—The term sarcoma is applied to tumors composed of connective-tissue cells with very little intercellular substance. It is often said that sarcoma-cells resemble those of embryonal connective tissue; more properly speaking, they may be likened to the ordinary connective-tissue cell falling short of complete development. There is little tendency in sarcoma to the formation of fibrous intercellular substance, but a great tendency to continuous cell-proliferation.

Etiology.—Of all the tumors sarcoma furnishes the best ground for Cohnheim's theory. Its frequent occurrence in young persons, the relation of melanosarcomata to congenital pigment-spots of the skin, and the sarcomatous mixed tumors of the parotid and testis were cited by Cohnheim among the evidences pointing to a congenital origin. Traumatism and inflammation certainly play some part, either in stimulating sudden growth of a latent sarcoma or in developing a lesion from which sarcoma springs. The parasitic theory has gained many adherents in recent years. The resemblance to tubercle is very striking in certain cases and the peculiar dissemination is most suggestive. No specific form of bacteria, however, has been demonstrated, and experiments at implantation of the disease in animals have been unsatisfactory (von Eiselberg, Duplay and Cazin). Recently intracellular protozoan organisms have been described, but whether these are really organisms or cellular degenerations is doubtful. In some cases the structures described are certainly nuclear degenerations. It is not improbable that lymphosarcomata are due to the action of bacteria.

In connection with the supposed infectious nature of sarcoma it is of interest to note that a relationship has been observed between syphilis and sarcoma. This is based on the fact that some cases disappear under anti-syphilitic treatment.

Appearances.—Sarcomata are generally more or less rounded tumors often enclosed by capsule; they may, however, be irregular, infiltrating, and therefore unencapsulated. Some forms appear on surfaces, spreading as flat elevations more or less irregular in outline. The consistency is soft or hard according to the number of cells and the amount of intercellular substance, or according to the kind and amount of associated tissue (myxomatous, chondromatous). Typical sarcoma, as the name implies (σάρξ, flesh), is flesh-like in consistency, and frequently on section the color is pink or of a flesh tint. Many of the sarcomata, however, are quite white or gray, and a whitish liquid exudes from the surface on section.

Dilatation of the blood-vessels may cause a decidedly hemorrhagic appearance, and actual hemorrhages may take place, causing

FIG. 48.—Secondary sarcomata of the lung: the primary growth was attached to the pleura.

blood-cysts or, subsequently, serous cysts. Other degenerative changes, such as necrosis, mucoid change, and simple liquefaction-necrosis, may render sarcomata soft and often cystic. Sarcomata of glandular organs like the breast may present a cystic appearance in consequence of compression of the glandular ducts and acini and consequent dilatation.

Angiosarcomata (the variety in which sarcoma-cells spring

from the adventitia of blood-vessels) present themselves as more or less irregular growths, frequently flattened and branching when the surfaces of organs are involved.

Secondary sarcomata are nodular in character and nearly always present a capsule if the size is at all considerable (Fig. 48). They are usually white or pinkish; on section rather firm, but with a tendency to central necrosis or softening. In some cases almost every part of the body may be studded with minute white spots scarcely distinguishable from miliary tubercles. This condition is called *sarcomatosis.*

Seats.—Sarcomata spring from pre-existing connective tissues, such as the subcutaneous, intermuscular, periosteal, or tendinous tissues; bone, cartilage, fat, lymphatic glands, the submucous and serous surfaces. They may arise in the internal organs: kidney, liver, spleen, thyroid gland, testis. The individual seats will be further considered under the different forms.

Structure.—The sarcoma-cell is rounded, cylindrical, spindle-shaped, or of polymorphous forms, the latter usually being larger than the round or spindle-forms. The large number of cells in comparison with the amount of intercellular substance is always conspicuous. The cells themselves contain rather large nuclei of a somewhat vesicular appearance, though sometimes quite granular. In rapidly growing tumors karyokinetic figures may be very abundant; less frequently the cells show evidence of direct division of the nuclei. Nuclear degenerations (karyorhexis, karyolysis, and hyperchromatosis) are frequent, and doubtless cause some of the appearances supposed to be protozoa. The arrangement of the cells in sarcomata is usually very irregular; in some cases, however, particularly in spindle-celled sarcomata, the cells lie in fasciculi or parallel columns. The intercellular substance consists of a homogeneous matrix with a few fibers in the case of the spindle-celled variety, but with none at all in most other cases. The cells may be all of one type, but more frequently different forms or shapes occur in the same tumor. Among the polymorphous forms of cells may be noted large flattened cells resembling endothelial plates and giant-cells resembling myeloplaques. (These forms will be discussed under the headings Endothelioma and Giant-celled Sarcoma.)

The blood-vessels of sarcoma are usually channels lined with a single endothelial coat (see Fig. 50), or there may be more fully developed vessels. In some cases the vascular network is very conspicuous and forms the skeleton of the tumor, the sarcoma-cells being ranged round the vessels in the form of mantles and probably springing from the adventitia. Secondary changes may occur in the cellular masses surrounding the vessels, and peculiar forms of tumors thus result (see Cylindroma).

Combinations of sarcoma with other forms of tumor are not

rare. All grades between the true sarcoma and the fibroma may be met with, and it is difficult to draw a line of distinction. Wherever a tendency to cellular proliferation is conspicuous and the formation of fibroblastic cells with elongated fibrous projections is not conspicuous it is warranted to record the tumor as sarcomatous. Primary fibromata may become sarcomatous, and sarcomatous tumors perhaps at times become more benign by fibromatous transformation. Combinations with chondroma, osteoma, myxoma, and other connective-tissue tumors; with adenoma, rhabdomyoma, and fibromyoma are not infrequent. More rarely the fibrous tissue of the benign tumors may undergo sarcomatous change.

The structure of individual forms of sarcoma will be separately considered.

Nature.—Sarcoma is essentially malignant. It tends to recur after removal; it affects the general health of the patient; and metastasis is frequent. Metastasis occurs through the circulation. The degree of malignancy varies greatly. The small round-celled and melanotic varieties are the most dangerous. Some forms, as the giant-celled and the fibrosarcomata, are comparatively benign. The relatively benign form of tumor called *recurrent fibroid tumor* by Paget is in reality a fibrosarcoma. The growth of sarcomata is usually rather rapid, and may become very rapid in consequence of irritation.

Sarcomata are injurious to the general health in some obscure way. The evidence of this is the anemia and leukocytosis and the irregular fever observed in various cases. The anemia may be trivial or severe, and may become extreme. Leukocytosis is frequent, but rarely marked. The polymorphous elements may be specially increased, but I have found the lymphocytes excessive in a number of cases. Irregular fever is often noted in lymphosarcoma and general sarcomatosis. Necrotic change may increase the tendency to fever. The exact influence of sarcoma on metabolism is unknown.

Spindle-celled Sarcoma.

This form may consist of either large or small spindle-shaped cells with attenuated and sometimes branching extremities (Fig. 49). Angular or stellate cells are not infrequent. The cells may be ranged in parallel columns, so that the tissue becomes quite compact; and fasciculi of such cell-masses may run in different directions, interlacing, and thus giving the section a fibrous appearance. In other cases the cells present no definite arrangement. Spindle-celled sarcomata are harder than the round-celled varieties and usually more grayish or flesh-colored. They may be quite soft and white or degenerated and cystic.

The amount of intercellular substance in some cases is quite considerable, and the term fibrosarcoma may be justified. It is very

FIG. 49.—Cells from a large spindle-celled sarcoma (Ziegler).

difficult sometimes to decide whether the tumor is sarcomatous or purely fibromatous.

Spindle-celled sarcomata occur in the dense connective tissue of the periosteum, tendons, and fasciæ; less frequently in the softer tissues. Relatively they are benign, some cases showing no tendency to metastasis, though recurring after removal.

Round-celled Sarcoma.

Sarcomata may be composed almost entirely of spherical or round cells, small or large in size. The designations small and large round-celled sarcomata are used, but do not really define separate varieties. The round cells when small resemble those of

FIG. 50.—Small round-celled sarcoma: in the center is seen a blood-vessel with its wall of endothelium.

lymphatic organs. There is little intercellular substance. The blood-vessels may be quite large and hemorrhages with secondary changes may occur (Fig. 50). The larger cells contain relatively more protoplasm, frequently several nuclei, and not rarely different forms of cells (spindle-shaped and polymorphous) are associated.

The naked-eye appearances of round-celled sarcomata are usually quite characteristic. They are milky-white, gray, or pink in

color; sometimes quite soft or cheesy in the center, and a milky liquid exudes. Cystic changes and even calcification may occur in the center. The small-celled variety is, as a rule, softer than the larger, though both are soft.

Round-celled sarcomata are always malignant, the small-celled form being perhaps the most malignant of all varieties.

Lymphosarcoma is a variety of round-celled sarcoma. The appearance is the same as that of the other forms, but microscopically a close resemblance of structure with that seen in lymphatic glands is discovered. The principal characteristic is the reticulum or stroma formed by branching stellate cells united by their prolongations. In the meshes of this reticulum lie lymphoid round cells (Fig. 51). The stroma may not be plainly visible

FIG. 51.—Lymphosarcoma of nasal mucous membrane: *a*, on left side a blood-vessel, on right side reticulum; *b*, cells of reticulum; *c*, sarcoma-cells (Ziegler).

unless sections are shaken to dislodge the cells from the reticulum. Lymphosarcomata occur in the lymphatic glands and lymphadenoid tissues of the mucous membranes. Occasionally the thymus gland and other organs may be the seat. The distinctions from lymphadenoma have been discussed under that heading.

Alveolar sarcoma is a sub-variety of round-celled sarcoma, though there are always spindle-cells as well. It is distinguished by the occurrence of acini filled with large round cells having a more or less decided epithelioid appearance. The stroma forming the acini is composed largely of spindle-shaped cells with a certain amount of fibrous tissue (Fig. 52). The blood-vessels supplying the tumors traverse these trabeculæ. The round cells within the alveoli may vary greatly in size, though they are usually large. The macroscopic appearance is not specially distinctive; many of the cases, however, are pigmented (see below). Alveolar sarcoma is most frequent in the skin, where it springs from moles and warts. It may also occur in the lymphatic glands, the serous membranes, and other parts.

In some cases the alveolar appearance of the sarcoma is due to

the fact that the sarcomatous proliferation has occurred in the adventitia of blood-vessels forming a plexus. In this way the

FIG. 52.—Alveolar sarcoma (Warren).

meshes of the vascular plexus become filled with round cells and the alveolar appearance results. In other cases the alveolar character is due to the occurrence of sarcomatous foci of circumscribed character in a connective tissue. These in their growth push the connective-tissue elements aside and thus form alveolar structures.

Angiosarcoma.

In this variety the sarcomatous proliferation begins in the adventitious coat of blood-vessels. Certain authors have attempted to show that all forms of sarcoma originate in the blood-vessels; this view, however, cannot be supported. Angiosarcomata are met with in the serous membranes, in the skin, and especially in the salivary glands. Very rarely they occur in other parts of the body. The tumor is, as a rule, quite vascular, but may not be strikingly so. Sometimes teleangiectatic change in the blood-vessels has been noted. Histologically these growths are characterized by round-celled masses surrounding the blood-vessels. The origin of the cells from the adventitia may be evident or obscure. In cases in which a vascular network is involved and each vessel has a coating of sarcoma-cells a plexiform appearance or arrangement results (*Plexiform Angiosarcoma*). In other instances in which a network of vessels is involved the sarcoma-cells accumulate in the vascular meshes in the form of cell-nests, and thus give rise to an alveolar form (*Alveolar Angiosarcoma*). Such forms occur in sarcomata springing from moles or warts. They are prone to melanotic change. The endothelium

of the vessels is occasionally the point of origin of vascular sarcomata; this form is a rare variety of endothelioma. The angiosarcomata are liable to degenerations, chiefly myxomatous (Fig. 53)



FIG. 53.—Angiosarcoma with myxomatous degeneration (cylindroma): the figure represents one of the blood-vessels with the sarcomatous cells springing from its walls, and outside of these myxomatous tissue.

and hyaline, and thus a certain proportion of the cases of cylindroma (see below) have their origin. The blood-vessels may give way and hemorrhagic infiltration results.

Angiosarcomata are in a measure benign, metastasis being very rare in the ordinary forms. The alveolar and melanotic varieties are highly malignant.

Cylindroma.

This term was originally applied by Billroth to tumors showing gelatinous masses or trabeculæ traversing their substance. Histologically different forms of growths may be distinguished. We deal here only with *Sarcomatous Cylindromata.*

The latter may be simply sarcomata in which hyaline or myxomatous degeneration has occurred in more or less insular fashion, or in which sarcoma and myxoma are peculiarly combined. Nearly always there is some hyaline change with the myxomatous. In most cases it is the angiosarcomata that present this peculiar condition. The sarcoma-cells surrounding the blood-vessels become converted into hyalomyxomatous tissue or cause the formation of this. There result branching columns of hyalo-

myxomatous character traversing the sarcoma. In some cases the walls of the blood-vessels themselves may be the seat of hyaline change (Fig. 54), the proliferated sarcoma-cells surrounding the

FIG. 54.—Cylindroma showing pronounced hyaline degeneration of the walls of the blood-vessels.

vessel being merely pushed aside. The term *Angiosarcoma Myxomatodes* is given to these vascular forms. Cylindromata occur in the salivary glands, the brain, the lachrymal glands, and rarely in the subcutaneous tissues. In nature they are more or less benign.

Melanosarcoma.

Melanosarcoma, or pigmented sarcoma, is a form in which the tumor is dark colored from the presence of black or brown pigment. The latter, according to the careful chemical studies of Berdez and Nencki, contains no iron, and is therefore not simply blood-pigment. Ferruginous pigment has been found by certain authors, but is always outside the cells, and very probably is accidental, resulting from hemorrhagic extravasations. True melanotic pigment occurs in the cells or intercellular substance as a brownish-black granular matter, or in the cells as a diffuse stain. The tumor itself has not any definite characteristics aside from the pigment; it may be round-celled (Fig. 55) or spindle-celled; very frequently it is angiosarcomatous and alveolar in type. Melanotic sarcomatata most frequently arise in the skin, particularly in pigmented moles or warts, in the eye or in the pia mater. They are

exceedingly malignant, often grow with great rapidity, and give rise to widespread metastasis, the liver being peculiarly liable to

FIG. 55.—Melanosarcoma, mainly round-celled: from a nodule in the skin.

involvement. The secondary growths have the same structure as the primary, and frequently are even more pigmented than the original tumor.

Giant-celled Sarcoma.

This variety is characterized by the presence of large multinuclear cells resembling exactly the myeloplaques of bone. The remaining portions of the tumor may be spindle-celled or round-celled; perhaps more frequently round and spindle-cells are associated. The giant-cells are often exceedingly large and contain several or many nuclei in the center of the cell (Fig. 56). The formation of these cells is most likely due to rapid nuclear multiplication. In some cases they would seem to be caused by obliteration and transformation of capillary blood-vessels; but the theory that they result from a fusion of cells seems unwarranted. Ziegler maintains that the presence of giant-cells does not form an essential characteristic of a peculiar type of tumor, but that it is accidental, resulting from continued irritation. The occurrence of giant-cells in sarcomata of bones would then be explained by the constant irritation of the bony particles, as in some cases the presence of masses of blood-pigment in the sarcoma accounts for the development of giant-cells in the vicinity. This view is supported by considerable authority and seems reasonable.

Giant-celled sarcomata occur most frequently about bone, and the terms *osteosarcoma* and *myeloid sarcoma* have been given in consequence. They may, however, occur in other situations. Their nature is usually benign, metastasis being rare.

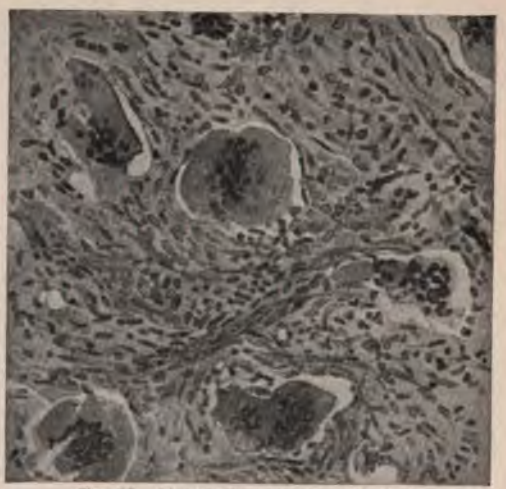

FIG. 56.—Giant-celled sarcoma (Warren).

The giant-celled sarcoma of bone is usually rather slow in growth, and gives rise to hard and irregular tumors, firmly attached

FIG. 57.—Myelogenous osteosarcoma of the tibia (modified from Kast and Rumpel).

to the bone-structures. It may begin within the bone as a *myelogenous form* (Fig. 57) or from the periosteum. Secondary myxoma-

tous or other change may cause more or less softening. The bone most frequently involved is the maxilla, the tumor known as *epulis* (sarcoma springing from the gums or alveolar processes) being generally a giant-celled sarcoma.

MIXED TUMORS.

All forms of connective-tissue tumors may be associated one with another; association of several forms are known as mixed tumors. Very frequently there is more or less sarcomatous tissue in such growths. With this will be found myxomatous, fibromatous, chondromatous, or osteomatous elements. The various constituents of the tumor are arranged with no special order, but simply present themselves as masses of cells or intercellular substance of different forms combined to make a heterogeneous tissue. Among the frequent seats of such mixed tumors the parotid gland and the testicle are most important.

Chloroma.

This tumor is no special form of new growth, but rather a variety of lymphosarcoma or round-celled sarcoma occurring with special frequency in the periosteum or the bones of the head and secondarily in other parts of the body. The name is applied because of the peculiar greenish pigmentation of the cells. The nature of this pigment is not certainly determined. Clinically cases of chloroma may present symptoms of leukemia or pseudoleukemia.

Psammoma.

This represents no distinct species of tumor-growth, but rather a peculiarity of different kinds. The name refers to the presence of calcareous matter like that of the brain-sand (acervulus cerebri), and psammoma has sometimes been called *acervuloma*. The calcareous matter occurs in the form of rounded masses or concentrically arranged whorls. The tumor-elements themselves may be fibromatous, gliomatous, sarcomatous, or even adenomatous or carcinomatous. In most instances it is angiofibromata or angiosarcomata that present these appearances. Psammomata are met with in the membranes of the brain, the choroid plexus, and the pineal gland.

MYCOSIS FUNGOIDES.

Mycosis fungoides or granuloma fungoides is a pathologic condition of the skin and subdermal structures having certain resemblances to sarcoma and to some of the infectious inflammations.

Etiology.—Very little is known regarding the causes of this disease. Various bacteria, principally micrococci, have been discovered in the lesions, but none of these has been shown to be pathogenic. A few observers have found bodies resembling protozoa; but it is not certain that these were really animal organisms.

Appearance.—The disease frequently presents distinct stages. First, the skin becomes somewhat swollen and red and presents eczematous lesions. In some cases the appearance is that of an erysipelatous inflammation. In the next stage nodular elevations occur, and finally tumors of considerable size, sometimes as large as an orange, and more or less fungoid in appearance. Necrosis is frequent and watery or bloody liquid is discharged. The tumors may have an angry, red appearance and have been likened to tomatoes. Rapid disappearance and reappearance of the tumors are a peculiar feature.

Any part of the body may be affected and usually the lesions are multiple.

Structure.—Microscopically the structure of the tumors is allied to that of lymphadenomata. There is a proliferation of connective-tissue cells about the blood-vessels and glands at the base of the papillæ of the skin, forming a network or reticulum in which round (lymphoid) cells are embedded. Epithelioid cells and giant-cells may occur. The tumors are poorly supplied with blood-vessels, and to this is attributed the tendency to central necrosis. Inflammatory infiltration of polymorphous leukocytes is not observed to any considerable degree, excepting in the later stages around and in the areas of necrosis. Mast-cells are often abundant.

Associated Conditions.—In some cases enlargement of the lymphatic glands, liver, and spleen has been observed, and has suggested the term *pseudoleukemia cutis*. Occasionally the blood presents leukemic characters.

Nature.—The disease presents many resemblances to sarcoma or lymphadenoma, and it has frequently been described as multiple sarcoma of the skin. In other respects it is allied to the infectious inflammations, though there is much less evidence of true inflammatory infiltration than in these. The relationship to leukemia and pseudoleukemia is unsettled.

ENDOTHELIOMA.

This tumor, which is also sometimes designated *endothelial cancer*, resembles cancer very closely in histologic appearances in

FIG. 58. - Endothelioma of pleura: the pleural cavity was distended with effusion and the lung was compressed and invaded by secondary nodules.

some cases. It appears, however, to be purely endothelial in origin, and therefore rather of the connective-tissue group or sarcomata. It affects the pleura, peritoneum, and membranes of the brain most frequently, but may be found in the skin, walls of the blood-vessels, and elsewhere. The serous membranes when affected become greatly thickened, tough, and white in color (Fig. 58), and irregular elevations or nodules may occur. Metastasis is infrequent, but the adjacent organs are sometimes involved, and occasionally more distant structures.

FIG. 59.—Microscopic section from the above (Fig. 58).

Histologically the tumor is characterized by more or less tubular or acinus-like aggregations of endothelial cells. The latter vary in character from those which are distinctly endothelial to the most differentiated, which may be almost typical cylindrical epithelium (Fig. 59). Between these cellular columns or acini the connective tissue of the part affected may be seen in a normal state, though it is more frequently thickened by proliferation. Careful inspection of microscopic sections shows that the columns of epithelioid cells occupy lymph-channels, and it may be possible to demonstrate that the endothelium of the latter has been the starting-point of the cellular proliferation. In cases of carcinoma with penetration into the lymphatic channels it is notable, on the other hand, that the endothelial lining of the channels is uninvolved.

GLIOMA.

Definition.—The term glioma is applied to tumors composed of neuroglia. It is difficult to distinguish between the circum-

scribed tumors of this structure and the diffuse neurogliar hyperplasia or gliosis met with in certain cases. (See section on Diseases of the Nervous System.)

Etiology.—It is probable that congenital defects of development play some part in the causation of these tumors, particularly in the forms more frequently spoken of as gliosis.

Appearance.—A typical glioma is usually a solitary tumor, rounded in outline, though its limits are difficult to determine, as it merges gradually into the surrounding nervous tissue. Gliomata are somewhat harder than the normal brain-substance, and often the color is a little different, either more grayish or pink or reddish. Sometimes they are quite vascular and dark red. The normal shape of the part may be a little disturbed, or there may be indefinite elevation. In size the tumor varies up to masses as

FIG. 60.—Glioma of the corpora quadrigemina (Perls).

large as a lemon. Diffuse gliosis causes a swelling of the affected parts, sometimes quite regular, at other times irregular. When the spinal cord is affected its thickness may be considerably increased. On section the area of gliosis is rather firm and grayish in color. Nearly always there is a tendency to excavation or cyst-formation. In the cord this leads to the development of considerable cavities, as a rule communicating with the central canal.

Seats.—Gliomata occur in the brain and less frequently in the spinal cord. In rare cases the cranial nerves have been involved. Glioma of the eyeball will be referred to below. Diffuse gliosis is particularly common in the cord. It is usually met with in the vicinity of the cavities of the brain or cord.

Structure.—A glioma consists of cells containing rounded or oval nuclei with very little protoplasm and fine protoplasmic extensions which interlace and form an intercellular reticulum, giving the sections a granular appearance when viewed with low powers of the microscope. Special staining and higher powers may demonstrate the filamentous prolongations of the cells (Fig. 60). The number of cells and the density of the intercellular network vary greatly. As a rule, the cells are larger than the normal neuroglia-cells, and sometimes they contain several nuclei.

The tumor is generally quite vascular and occasionally teleangiectatic vessels may be observed. Secondary hemorrhages are prone to occur in the latter case. Softening may occur, and occasionally sarcomatous transformation has been described.

Diffuse gliosis has similar microscopic appearances, though the tissue is likely to be more compact and less vascular. In the spinal cord the process begins as a subepithelial proliferation of the glia at the posterior raphé of the central canal, the lining epithelium of this at the same time undergoing a certain amount of proliferation. Subsequently the gliosis increases and cavities form within. These may be lined with epithelial or epithelioid cells which are occasionally ciliated. Gliosis may also present itself in the form of scattered nodular hyperplasias of the neuroglia.

Nature.—Glioma is essentially benign. It is dangerous mainly on account of the pressure it exerts. Sarcomatous transformation may possibly occur, but is exceedingly rare. The growth of the tumor is rather slow.

Glioma of the eyeball is a form of tumor that is sometimes considered true glioma. It is, strictly speaking, a round-celled sarcoma. It springs from the retina and resembles in structure the granular layer of the retina. It occurs most frequently in children, particularly in early life (two to four years), and often on both sides simultaneously. Family predisposition, in some cases, is very striking. Extension along the optic nerve or externally, and a tendency to recurrence after removal, indicate the malignant character of the growth.

Glioma Ganglionare.

Definition.—This term indicates a form of mixed tumor composed of neuroglia and nerve-fibers with large ganglionar nerve-cells.

Etiology.—Probably congenital abnormality of development furnishes the groundwork for the subsequent development of these tumors.

Appearance.—A ganglionar glioma may resemble the ordinary glioma, occurring as a solitary tumor, the outlines of which are difficult to distinguish from the surrounding tissue. More frequently it occurs in the form of multiple nodular condensations scattered through the brain or cord. The contour of the affected parts may not be altered, and on section the growths may be recognized only by the light-colored patches and areas of increased density. A few cases of ganglionar gliomata of the spinal or sympathetic ganglia have been described. In these cases the tumors appear as rounded enlargements of the affected ganglia. Occasionally the nerve-roots are seats of these tumors; the suprarenal capsules may also be affected.

Structure.—The definition indicates the usual structure. The glia-fibrils are generally conspicuous in number, the nuclei being comparatively few. Traversing the tumor there may be more or less abundant nerve-fibers with or without medullary sheaths. Large ganglionar cells may be found in considerable abundance or in small number. The vascularity of the growths differs greatly.

Nature.—The nature of these tumors is the same as that of the ordinary glioma.

NEUROMA.

Definition.—Strictly speaking, neuroma is the term applied to tumors composed of nerve-fibers. Ordinarily, however, the name is given to fibrous growths springing from the perineurium or endoneurium of nerves. The terms *true* and *false neuroma* distinguish between the two forms. True neuromata are exceedingly rare.

Etiology.—Very little is known regarding the causation. Injury may play a part, as in the case of amputation-neuromata.

Appearance.—False neuromata occur as nodular thickenings along the course of nerves. They may be fusiform or elongated, may extend considerable distances along the nerves, and may form networks of ridges or elevations when the peripheral nerves are involved (Plexiform Neuroma). As a rule they are multiple, and sometimes occur in exceedingly great numbers scattered over the entire body or involving a single part of the body, as the nerves of the arm or leg. After amputations rounded thickenings may occur at the ends of the nerves, constituting painful conditions of the stump.

Seats.—The peripheral nerves are most frequently involved, but the nerves may be implicated near their roots, or the terminal fibers within the organs may become affected.

Structure.—Ordinary false neuroma consists of fibrous tissue in the form of reticular connective tissue with greater or less abundance of cells pushing aside or surrounding the nerve-fibers proper. The latter are prone to degenerate in consequence of the pressure. Proliferation of the nerve-fibers has sometimes been described, but it is doubtful whether such actually occurs. More probably the existing fibers increase in length and form a mass by curling at the end. True neuromata of two kinds are described: those composed of medullated and those consisting of non-medullated nerve-fibers. The former are called *myelinic*, the latter *amyelinic*.

Nature.—Neuromata are painful tumors, but benign in a pathologic sense. Their growth up to a certain point is often rapid.

LEIOMYOMA.

Definition.—Leiomyoma, or myoma lævicellulare, is a tumor containing smooth muscle-fibers. Nearly always there is a certain amount of fibrous tissue associated, and in the most common form, myomata of the uterus, there is always considerable fibrous tissue, and the term fibromyoma is appropriate. Occasionally a few unstriped muscle-cells may be seen in tumors of other kinds.

Etiology.—Some of the myomata of the uterus exhibit glandular acini in the interior and suggest a congenital origin.

This, however, is by no means certain. In other cases there are features suggesting that irritation is the important cause, though this also remains to be proved.

Appearance.—Leiomyomata are usually rounded growths, varying in size from minute nodules to huge solid masses weighing as much as sixty to seventy pounds. The largest (heaviest) solid tumor I have ever seen was a degenerated fibromyoma weighing eighty pounds. Leiomyomata are surrounded by a capsule more or less well developed and are generally quite hard, though secondary degeneration at times alters the consistency, making the tumor quite soft in the case of mucous transformation, or stony-hard when calcification has occurred. On section through the growths the stratified or fasciculated arrangement of the cells is visible to the naked eye. Concentric layers may be apparent, or a more wavy irregularity may be seen. They are grayish or flesh-colored, or in rare instances quite red (myoma cavernosum) in consequence of enlarged vascular channels. Central softening may lead to cystic change (myoma cysticum).

When the myomata spring from the submucous or subserous tissues they may become polypoid, hanging from a point of attachment by a narrow pedicle. In rare instances the latter is severed and the tumor becomes a free body. Submucous myomata of the uterus may thus eventually be discharged after a spurious labor. Subserous myomata may become free in the peritoneal cavity.

Myomata of the uterus may have three situations—submucous, subserous, or interstitial. In the latter, the tumor occupies the wall of the uterus without any tendency to project particularly toward either surface. Uterine myomata are usually multiple, occur during the third and fourth decades of life, continuing their growth until the menopause and usually decreasing after that epoch. They endanger life by their pressure and by the copious uterine hemorrhages which they occasion. Very frequently salpingitis is associated, and recently attention has been called to degenerated conditions of the myocardium in patients suffering from uterine fibroids.

Myomata of the skin occur in younger patients, even in childhood, and are generally multiple and often painful (tubercula dolorosa).

Seats.—The common situations are the uterus, the gastro-intestinal tract, and the ovaries; the less common seats are the walls of the blood-vessels, the skin, and the nipple. In all situations the tumor springs from pre-existing unstriped muscle-fiber. In most cases, according to some authors, the origin is in the walls of the minute blood-vessels, but direct origin from the muscular layer of the affected organs, or from the erectores pilorum in the case of the skin, cannot be denied. Myomatous metaplasia of the connective tissue, as in the case of myomata originating in the areas of old pleural thickening, has been assumed, but is improbable.

Structure.—As has been said, association with fibrous tissue is usual. Microscopically the tumor presents a characteristic appearance. Bundles of muscle-cells are seen running in different directions. Those cut longitudinally show cylindrical nuclei as the most conspicuous feature, the outlines of the cell being indistinct (Fig. 61). Where the cells are transversely cut the nucleus

FIG. 61.—Leiomyoma of uterus.

presents a circular outline with clear protoplasm surrounding it. The picture of a leiomyoma is often suggestive of sarcoma, but may be distinguished by the greater regularity in direction of the cells in different bundles and by the more distinctly cylindrical outline of the nucleus. The cells of leiomyomata may be isolated by maceration of the sections in 20 per cent. solution of nitric acid for twenty minutes, or in 30 per cent. solution of caustic potash for fifteen minutes. They are spindle-shaped structures containing a nucleus about one-third the length of the entire cell.

Leiomyomata are generally poor in blood-vessels, but may show a teleangiectatic condition of the vessels. The lymphatic spaces may similarly dilate, forming cystic spaces containing spontaneously coagulable material.

Of the degenerative changes calcification is the most common, particularly in the uterine fibromyomata. This begins in the center of the tumor, but may eventually involve the whole mass. Myxomatous change may occur in myomata containing much fibrous tissue, and sarcomatous transformation has been described, but is rare.

Nature.—The nature is eminently benign. Myomata of the digestive tract may cause occlusion or strangulation, or by their weight may exercise serious traction. Uterine myomata are dangerous in the ways already indicated. The growth is usually slow.

RHABDOMYOMA.

Definition.—Rhabdomyoma, or myoma striocellulare, is a tumor containing more or less striped muscle-fiber. Usually there is but a small quantity of the latter, the bulk of the tumor being of some other tissue, most frequently sarcomatous.

Etiology.—Congenital defective development seems an important cause, as the tumors occur in early life and in situations in which striped muscle-fiber does not normally occur.

Appearance and Seats.—The rhabdomyomata of the kidney (the most frequent seat) present themselves as large rounded or irregular masses, more or less encapsulated. In the testicle they are similar, though of smaller size. A few cases have been described in which irregular tumors of the retroperitoneal tissues have contained muscle-fibers.

Structure.—The microscopic appearance is usually that of a spindle-celled sarcoma, containing more or less striped muscle-fibers. These are elongated spindle-shaped cells, partly striated, and suggesting embryonal muscle-tissue and rarely more fully developed muscle-fibers. Large areas of the tumor may contain no muscle-fiber at all, while certain portions are richly supplied. Adenomatous elements are not rarely associated. The tumors of the kidney which contain striped muscle-fibers are in the main sarcomatous or adenosarcomatous.

Nature.—These tumors are malignant in proportion as the sarcomatous element is predominant. Metastasis is, however, infrequent. General cachexia and hemorrhages reduce the vitality and lead to fatal termination.

PAPILLOMA.

Definition.—The term papilloma indicates a tumor arising from the surface and covered with epithelium representing more or less accurately the structure of the papillæ of the skin.

Etiology.—It is difficult to draw a line between certain papillomatous growths that are the result of chronic irritation and others that arise in a seemingly spontaneous manner. It would appear that irritation is an important factor in most, if not all, cases, but there is also no doubt some form of predisposition. Whether this resides in structural peculiarities or not is difficult to determine. A peculiar form of inflammatory growth resembling the spontaneous papillomata is that known as *venereal wart*. It occurs about the genitalia or anus and especially after gonorrhea. Another form of inflammatory papillomata is that found in the mucous membranes surrounding carcinomata or chronic ulcerations of syphilitic or other kinds.

Appearance.—The most familiar form of papilloma is that which occurs in the skin and which is commonly called *wart*.

Warts or papillomata may be single, but more frequently occur in groups, and there may be many growths in widely scattered areas of the body. A wart may be simply a smooth hemispherical elevation, or it may have a cauliflower appearance. The epidermis covering it is, as a rule, somewhat more granular or rough than is that of the normal skin. The size of these growths varies from minute points to nodules as large as a walnut. On the mucous surfaces, especially where the epithelial covering is columnar, the papilloma presents itself as a soft and more distinctly cauliflower growth (Fig. 62). It is red in color, or, if the epithelium is stratified and squamous, grayish or pink. The growth is usually comparatively hard when covered by squamous epithelium.

FIG. 62.—Papillomata of the vocal cords (from a specimen in the Museum of the Philadelphia Hospital).

Two varieties are sometimes distinguished. The *hard papillomata*, such as those which occur in the skin, and the *soft papillomata*, or the form usually seen in the mucous membranes.

Seats.—Papillomata occur in the skin of the neck, hands, back, and other parts, and in the mucous membranes, particularly in the bladder, larynx, nasal chambers, and gastro-intestinal tract. Small papillomatous outgrowths may spring from the lining membrane of glandular ducts, as in the breast or ovary. These may lead to subsequent cystic change in the organ, or they may arise after cystic change has begun by proliferation of the lining membrane of the cyst.

Structure.—The essential parts of papilloma are the center or groundwork of connective tissue containing blood-vessels and the epithelial covering. In the skin the growth imitates the normal papillæ, all portions of the latter, however, being greatly exaggerated. When there is tendency to cauliflower appearance the papilloma shows a branching form on vertical section. Each of the branches contains a connective-tissue framework with an epithelial covering. The latter consists of stratified, squamous cells and shows a decided tendency to horny change. Distinct concentric whorls of horny epithelium, such as occur frequently in epitheliomata of the skin, may be met with in papillomata. In some cases the amount of connective-tissue groundwork in the papilloma is excessive; in others the new-growth consists almost entirely of proliferated epithelium. In some of these latter cases the resemblance to epithelioma may be quite suggestive, but a distinction can be made by observing that the tumor tends to grow outward

rather than into the deeper structures, and always shows some connective-tissue stroma at least. The papillomata of the mucous membranes differ according to their situation. In the larynx and other portions covered with squamous epithelium they may present much the same appearance as that seen in the skin, though the epithelium, as a rule, remains softer. There are cases, however, in which a distinct pachydermatous change is found in the epithelial covering of papillomata. In the gastro-intestinal tract and in the bladder papillomata are prone to be soft and villous in appearance and are covered with a scantier epithelial coating. Cystic change is not unusual as a result of degenerative processes or of distention of the mucous glands.

Nature.—The nature of these tumors is benign, but they may be destructive of the general health in consequence of repeated hemorrhages or by interfering with the function of the organ or part in which they are situated. In some cases they are supposed to become malignant, but this has not been definitely proved.

ADENOMA.

Definition.—Adenoma is the term applied to a new-growth corresponding more or less in structure with certain epithelial glands, and therefore presenting acini or tubules containing glandular epithelial cells (cylindrical or polyhedral) and a reticulum of connective tissue and blood-vessels. It is difficult to separate simple glandular hyperplasia on the one hand and carcinoma on the other hand from true adenoma. This will be discussed in referring to the structure.

Etiology.—The causation of adenoma is obscure. In some cases congenital misplacements of tissue-elements appear to play a part, as is seen in the cases of adenomata of the kidney having the structure of suprarenal bodies. These tumors which, it is true, some authorities refuse to consider as adenomata, have a general resemblance to adenomata and spring from remnants of suprarenal tissues embedded in the kidney-substance. Traumatism may be a factor in the etiology by exciting the proliferation of such misplaced tissue-elements. In other cases the ordinary glandular structures seem to be stimulated to abnormal hyperplasia and tumor-growth in consequence of continued irritation.

Appearance.—The appearances of adenomata vary greatly with their seat. On the mucous surfaces there may be a simple thickening or more or less diffuse and irregular elevation of the surface, or in other cases distinct papillomatous outgrowths and rarely definite nodular tumors. In some of these cases the condition is purely one of inflammatory hyperplasia; in other cases there is undoubted tumor-growth. No sharp demarcation can be established. In the substance of the organs adenomata occur as

nodular tumors, usually singly and well circumscribed, and not rarely surrounded by a fibrous capsule. They are moderately firm, and on section whitish or pink in color. Sometimes cystic change occurs as the result of dilatation of the glandular acini or in consequence of degenerative softening; in these cases the consistence is correspondingly altered.

Seats.—Among the situations in which adenoma is frequent may be mentioned the mucous membranes, the skin, and certain organs, notably the mammary gland, liver, kidney, suprarenal bodies, thyroid gland, and ovaries. Clinically important seats are the pylorus, the duodenal papilla, the rectum, and the uterus. In these situations adenomata spring from the epithelial tubules or mucous glands. In the skin the points of origin are the sebaceous and sweat-glands.

Structure.—The definition in general indicates the structure of these tumors. They are more or less typical; that is to say, there are acini of normal appearance presenting a single layer of columnar epithelium, with perhaps in places a tendency to heaping up the several rows of epithelial cells. These acini are well inclosed by a surrounding connective-tissue reticulum, and the appearance of normal gland-tissue is thus produced. Unlike normal glands, there are no excretory ducts, or at most imperfectly developed ducts.

Two varieties of adenoma are sometimes distinguished, the tubular and the racemose or alveolar. In the former the glandular system is simple and consists of tubular formations lined with columnar epithelial cells; in the latter the appearance is that of more complicated glands with closely aggregated acini of circular outline containing columnar and often cubical or polyhedral cells. The number of varieties may be carried further, however, for in the liver the adenomata resemble the normal liver-structure rather than the ordinary glandular formation above described, while in the suprarenal capsules and kidney the appearance is that of slightly atypical suprarenal structure, or in other cases that of embryonal renal tubules.

With the further growth of adenomata the appearance may be little changed. In other cases considerable variations occur, and there is a tendency, more marked in some situations than in others, to active proliferation of the epithelium, which may cause a considerable alteration in the appearance of the tumor, and eventually transformation into definite carcinoma. In other cases the structure from the beginning is so atypical and the epithelial proliferation so irregularly active that the term adenocarcinoma is applicable.

The connective-tissue stroma of adenomata may be moderate in quantity or may be considerable. In some adenomatous proliferations of the mucous membranes the number of gland-

acini or tubules may be relatively small, while the interglandular connective tissue shows active round-cell infiltration to a very considerable degree. Sometimes the interglandular tissue is distinctly sarcomatous (adenosarcoma). In other instances the bulk of the tumor may consist of connective tissue of fibrous character in which are embedded a relatively small number of glandular alveoli. In all of these cases it is difficult to determine whether the connective-tissue process was primary and the epithelial secondary, or the reverse.

Secondary changes are common, the adenomata of the stomach and uterus being particularly prone to change their character to that of carcinoma. In these cases there may be noted active proliferation of the epithelial cells, so that the acini or alveoli become completely filled, or that the ends of the tubular structures become blocked up. There is a tendency to extension of epithelial infiltration beyond the limits of the acini, cancerous outgrowths being the result. In other cases the malignancy is manifested by the excessive epithelial proliferation in the form of new acini of irregular character (Fig. 63). This form is known

FIG. 63.—Destructive adenoma (Beyea).

as *destructive adenoma*, *adenoma destruens*, or *adenocarcinoma*. Eventually the tumor may become purely carcinomatous; in other cases, however, it continues to increase in size, always retaining its adenocarcinomatous appearance, but never becoming typically carcinomatous.

Degenerative changes may be met with as in other tumors. Hyaline transformation or production may give the tumor an

appearance justifying the term "cylindroma" or "cylindro-adenoma." Such cases are rare. Myxomatous and even calcareous change may sometimes be observed. The connective-tissue stroma may proliferate actively and assume sarcomatous appearances—adenosarcoma. Cystic change may result from gradual dilatation of the glandular acini or from distention of normal ducts or alveoli of the gland in which the tumor occurs. In these cases the term cystic adenoma or cyst-adenoma is applicable (Fig. 64).

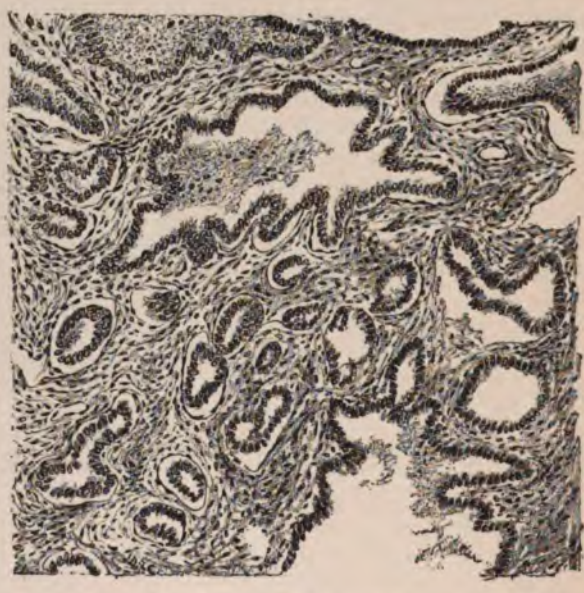

FIG. 64.—Adenoma of the mammary gland, with cystic enlargement of acini and abundant interglandular hyperplasia of connective tissue.

Nature.—Adenomata are benign tumors. In some cases, however, a pure adenoma may give rise to metastasis. Those of the liver, for example, not rarely cause secondary deposits in the spleen and less frequently elsewhere. The adenomata of the thyroid gland similarly cause metastasis, though it is less certain that these are to be considered as pure adenomata. Destructive adenomata or adenocarcinomata are malignant in proportion to the amount of carcinomatous transformation.

The effect of adenomata on the general health is variable. They do not contribute to the organic metabolism as far as is known, though occasionally biliary pigmentation of the adenomata of the liver and the secretion of milk-like fluid in mammary adenomata evidence the partial preservation of function by the cells. The general health may be unfavorably influenced by

adenomata of the mucous surfaces in consequence of their interference with normal functions or in consequence of secondary ulceration and hemorrhage.

CARCINOMA.

Definition.—The term carcinoma or cancer may be applied to tumors in which epithelial proliferations in the form of solid blocks or columns, or in the form of atypical acini, separated by more or less connective tissue, present themselves, the epithelial proliferation showing a tendency to extend beyond normal anatomic limits. It is extremely difficult to construct a definition that will be universally applicable. Some have regarded the tendency of the epithelial proliferation to break through the normal limits and extend beyond the confines of the epithelial structures from which it rises, as the important fundamental element of carcinoma. Others have held that there is a peculiar atypical character in the epithelial cells themselves, shown by irregular cell-division, hyperchromatosis, and other features. The older authors believed that polymorphism and certain irregularities of cell-contour suffice to distinguish carcinoma-cells from normal cells or those of other tumors; but this polymorphism is now recognized to be the result entirely of compression in the growth of the tumor, and to be therefore accidental. Some have believed that the term carcinoma should include all epithelial tumors giving rise to metastasis, but this necessarily restricts the term too greatly on the one hand, and, on the other hand, includes certain tumors probably purely adenomatous. I prefer to regard as carcinoma any epithelial growth atypically reproducing certain glandular or other structures and showing a manifest tendency to irregular extension.

Etiology.—The causes and nature of carcinoma are still obscure. A number of theories have been offered. These may be considered under different headings.

(*a*) **Congenital Theory.**—The theory of Cohnheim regarding the etiology of tumors in general is less applicable to cancer than to certain other growths. There are a few examples, however, which would seem to prove that misplaced epithelial cells undergo carcinomatous proliferation; for example, there are cases of apparently primary carcinoma springing from bones which would seem to require this explanation. It is not always certain, however, that such cases are actually primary. They may represent metastases from small primary growths which have escaped notice. The rarity of carcinomata in early life would seem to negative the congenital theory, and at all events would show that other influences of importance are requisite. Of late, a number of hypotheses that in a measure contain the idea of congenital

origin have been put forward to explain the formation of carcinoma.

In these there are assumed some form of peculiar irregularity in cell-multiplication and a tendency to independent proliferation supposed to originate in faulty development. These hypotheses are vague and uncertain.

(*b*) **Traumatic Theory.**—Clinicians everywhere incline to give great weight to this. A single traumatism probably has little importance, though women frequently state that they recall distinct injuries from which carcinoma of the breast has seemed to originate. It must be recalled that such injuries are sustained by practically every woman, and the presence of carcinoma would readily be attributed to a preceding hurt. In cases of epitheliomata of the lip in pipe-smokers, in the carcinomata of the scrotum and limbs in chimney-sweeps and paraffin-workers, and in cases of uterine carcinomata following laceration of the cervix, the effect of chronic irritation would seem to be important.

(*c*) **Parasitic Theory.**—The peculiar growth of cancer, its destructiveness of the general health, and its metastasis readily suggest an infective origin. Bacteriologists sought to isolate micro-organisms without success; later investigators have turned their attention to low forms of animal life, protozoa. (For further discussion, see Animal Parasites.) A few successful experiments have been made at implantation from man to animals, or from one animal to another; but as Hanau, one of the few successful experimenters in this work, himself states, these experiments do not prove infectiousness. The secondary growths in the second animal may be simply of the nature of metastasis, due to implantation of the cancer-cells and subsequent proliferation. Occasionally an endemic occurrence of carcinoma has been claimed, and some authors have even referred to houses in which carcinoma frequently arose.

Age plays an important part in the formation of carcinoma, as this tumor is essentially one of advanced years. Among 275 cases collected by Lubarsch, 55.6 per cent. occurred between the ages of forty-five and sixty-five. There were a few instances in childhood and early life. Between fourteen and nineteen there were 1.46 per cent.; between twenty and twenty-five, 1.8 per cent.; between twenty-six and twenty-nine, 1.1 per cent. The frequency in later life was formerly ascribed to some alteration in the vitality of the epithelial cells, rendering them more liable to abnormal proliferation. The nature and cause of such alteration, however, remain obscure and theoretical, though there is certainly a greater tendency to cancer-growth as age increases.

Tumor-dyscrasia.—This indefinite term is supposed to indicate a tendency to cancer-growth probably due to peculiarities of the

liquids of the body. No proof of the existence of any definite dyscrasia has ever been furnished, though it is apparent on study that some form of disposition to this growth acts as the predisposing cause, even if traumatism, infection, or other factors are the immediate cause.

Heredity was formerly regarded as of great importance. Certainly in some cases there seems to be hereditary transmission of the tendency to develop carcinoma.

Appearance.—Carcinomata differ considerably in appearance in different parts of the body. Those of the surfaces present themselves as more or less nodular, flat elevations. In the skin the nodules may remain hard and rather smooth, or they may soften upon the surface, forming unsightly ulcerations. In the mucous membranes the growths are more frequently soft and polypoid or cauliflower-excrescences (Fig. 65). Ulceration may occur

Fig. 65.—Carcinoma of the duodenal papilla (modified from Kast and Rumpel).

on the surface of such elevations, or from the first the tumor may be of ulcerative character, causing spreading excavations limited by thickened projecting edges. Carcinomata of the glandular organs form more or less nodular tumors or irregular infiltrations. These vary greatly in consistency, some being almost stony hard, others soft in consequence of their preponderating cellular character or of secondary degenerations. On section the tumor is found to be white or grayish in color, generally somewhat translucent and glistening, and milky liquid may ooze from the surface. Capsule-formation is rarely seen, though in occasional instances the normal connective tissue of the organ is pressed outward by the growth of the tumor, and thus forms an imperfect capsule. The primary growth is nearly always solitary. Occasionally instances are observed in which two separate masses develop simultaneously

and apparently independent of each other: as in the two breasts. More frequently apparent multiplicity is caused by the early appearance and rapid growth of metastases.

Secondary carcinomata are nodular in character and nearly always multiple. The larger are often distinctly encapsulated. Central softening or contraction of connective tissue may give the surface of the nodule an umbilicated character (Fig. 66). The

FIG. 66.—Metastatic nodules of carcinoma on the surface of the liver (Hanot and Gilbert).

number varies greatly, from a few large or small nodules to innumerable tubercle-like forms in *general carcinomatosis*. In some situations, as in bones, secondary carcinoma has an infiltrating character.

Seats.—The situations in which carcinomata occur are very numerous; they invariably arise from pre-existing epithelial structures. In the rare instances in which a presumably primary carcinoma has occurred in bone or other connective tissues, the presumption is warranted that the tumor originated from remnants of epithelial tissue left by faulty development. Among the frequent places of origin the most important are the uterus, the skin, the gastro-intestinal tract, particularly the esophagus, pylorus, and rectum, the mammary gland, the ovaries; less frequently the liver, kidney, thyroid gland, prostate, or testicle may be the starting-point. Secondary carcinomata curiously do not often affect parts in which the primary growth is frequent. Of the many seats of secondary carcinoma, the lymphatic glands, the liver, spleen, lungs, heart, and serous membranes are the most important. Secondary carcinoma of the bones is specially frequent after carcinoma of the breast or the thyroid gland.

Structure.—The histology of carcinoma varies greatly in different situations and in different forms. There are two distinct

elements involved—viz., epithelial cells and a connective-tissue stroma. The epithelial cells are medium-sized or large cells of epithelial appearance, having a rather large and clear nucleus; the shape of the cell, however, differing widely. In epitheliomata of the skin the cells are large and of a squamous variety. In carcinomata of mucous membranes they are more often cylindrical or columnar, and there is a tendency to the formation of cuboidal or polyhedral epithelium. The last-named forms are habitually present in the cancers of glandular organs. The mutual compression exercised may occasion a polymorphous character, and the older writers regarded this as a distinctive feature by which a carcinoma-cell could be recognized as such. Secondary changes may occasion wide variations in the appearance of the cells; thus the epithelia of cancers of the skin tend to become arranged in concentric whorls and at the same time to become somewhat glistening from horny transformation (Fig. 67). The nucleus

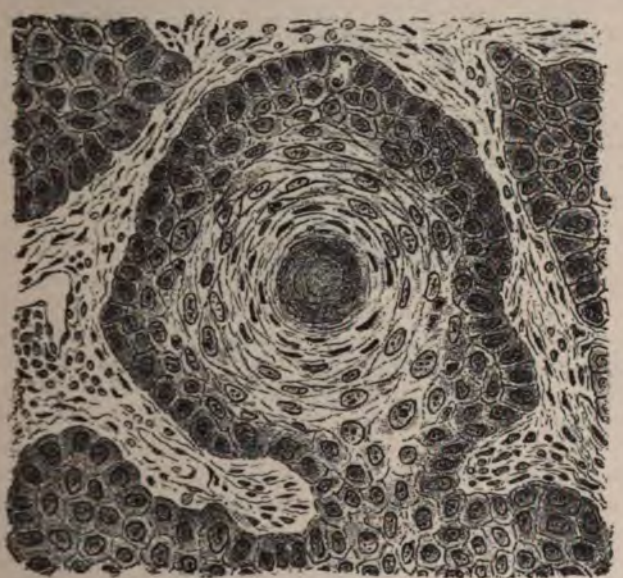

FIG. 67.—Epithelioma of skin, showing concentric arrangement and degeneration of cells.

may be clear and quite structureless, or may show a distinct nucleolus and a definite chromatin network. Karyokinetic figures may be quite abundant and are frequently atypical. Degenerative changes (dropsical infiltration, myxomatous change, fatty degeneration) may alter the nucleus as well as the body of the cell.

The epithelial cells are usually grouped in the form of acini;

either completely filled so as to form epithelial clumps or columns, or in alveoli with a central lumen surrounded by epithelial cells in a number of layers. In the last respect the alveoli differ strikingly from those of adenoma, and there is the further difference that cellular outgrowths may be seen at the periphery of the acini, the cells having broken through the retaining wall (basement-membrane) and proliferated outside to form new clumps (Fig. 68).

FIG. 68.—Carcinoma of uterus.

On examination of the epithelia within the acini it is found that those of the peripheral layer frequently retain the columnar character seen in the normal alveoli of the gland from which the tumor springs. The connective-tissue stroma of carcinoma is more or less dense, but practically is always of fibrous character. It is arranged in such manner as to form hollowed spaces or columns in which the epithelial structures already described are embedded. Frequently infiltrating leukocytes and plasma-cells or mast-cells are seen within the stroma, and the latter also bears the vascular channels that supply the tumor.

The above description applies to the ordinary carcinoma of glandular organs. Differences are observable in the cancers of the skin and other external surfaces. In these the structure is rather that of much enlarged papillæ penetrating into the deeper tissues. The cells are similar to those of the deeper layers of the skin, are larger than those of glandular cancers, and more translucent. Hollowed alveoli are exceptional.

Degenerative Changes.—Carcinomata are quite prone to

degenerations. In nearly all cases in which the tumor has reached considerable size more or less fatty degeneration of the cells becomes apparent. Preceding this or associated with it may be cloudy swelling or dropsical infiltration of the cells, rendering the nuclear outline less distinct and sometimes causing vacuolations. Irregular and multiform nuclear degenerations are met with, and probably occasion some at least of the structures known as parasites of cancer. The epitheliomata of the skin are particularly prone to a horny transformation, this occurring first and most prominently in the concentric whorls already described. In the adenocarcinomata of the ovaries and other genital organs of women the degenerated epithelial cells frequently undergo calcareous infiltration, and psammomata are thus formed. Colloid degeneration of the epithelial cells is a rare event, and the term colloid cancer is generally a misnomer, the real degeneration in most of these being myxomatous, affecting the connective tissue principally, though the epithelial cells are to a certain extent involved. Complete degeneration by myxomatous or associated myxomatous and fatty change may destroy all of the characteristics of the original tumor. In some cases cystic transformation occurs in organs the seat of cancer, or in the cancer itself. This may be due to occlusion and subsequent dilatation of the ducts of the organ or of the acini in the tumor, the cystic spaces becoming filled with mucoid or gelatinous material. In some instances cystic carcinomata are secondary developments originating in cystic adenomata. Hyalin-change and pigmentation are rare in cancer.

Inflammatory processes are quite common. Cancers on free surfaces are prone to undergo ulceration in consequence of irritation and infection. Among the micro-organisms discovered in such instances the staphylococcus and streptococcus are conspicuous. A distinct erysipelatous inflammation may occur in cancers as in other structures. Invasion of tubercle-bacilli and the deposit of miliary tubercles in carcinoma are rare events, though they sometimes occur. Associations of carcinoma and tuberculosis or syphilis may in other cases result from the secondary growth of cancer in pre-existing gummatous or other syphilitic lesions or in lupus. Practically all carcinomata show some leukocytic infiltration. The amount of this, however, varies greatly.

Nature.—Carcinoma is essentially malignant, the degree of malignancy depending, however, upon the seat and upon certain peculiarities of disposition of the individual. Sometimes a small growth may remain practically latent for a long time, until accidental circumstances, like traumatism, intercurrent disease, pregnancy, or the like, stimulate active growth.

Carcinoma exhibits all the elements of malignancy: the tendency to recur after removal, metastasis, and general destruction of the health. Recurrence after removal is most readily explained

upon the assumption that the entire growth had not been removed. Microscopic studies show that the area of infiltration is usually much greater than the naked-eye appearances would indicate, and this explains why the surgeon cannot well remove the whole disease. Metastasis, as a rule, follows the lymphatic channels, and thus primarily involves the lymphatic glands in the neighborhood of the growth. The process may be explained as follows: some of the epithelial cells in their advancing proliferation penetrate the lymphatic channels and are carried in the lymph-stream to the nearest lymphatic gland, where they again proliferate and form secondary nodules; from these a similar extension occurs, and eventually widespread metastasis results. Less frequently the primary growth penetrates the walls of a vein and metastasis occurs through the circulation. This is quite common in the case of cancers of the stomach or intestines. The metastatic foci first spread through the portal circulation to the liver. In still other instances secondary growths result from mechanical transportation in the movements of the body; thus in carcinomata of the abdominal organs the peristaltic movements may transfer particles to different parts of the abdominal cavity.

Pathologic Physiology.—The general health of patients suffering with carcinoma is affected very profoundly, though the manner in which this occurs remains obscure. It would seem to be of the nature of a toxemia. Emaciation and loss of strength are habitual, though often, perhaps, in large part the result of interference with organic functions, as, for example, in carcinoma of the stomach. Progressive anemia may make its appearance, the red corpuscles becoming less abundant and the quantity of hemoglobin falling decidedly. There is usually a moderate amount of leukocytosis, the large mononuclear forms increasing particularly. Toward the end of life the tissue-destruction increases greatly, though the excretory products of such may not be notably increased in the excretions in consequence of failing circulation and imperfect renal function. At this stage the accumulation of such products in the blood may lead to sudden death from coma (see Acid-intoxication). Hemorrhages and ulcerations may also contribute to the impairment of health in cases of cancer.

Varieties of Carcinoma.

There are several forms of cancer sufficiently different to require separate description. The classification of these is generally based upon the character and arrangement of the epithelium. We may distinguish (1) carcinomata composed of surface-epithelium, either (*a*) squamous or (*b*) cylindrical, and (2) glandular carcinomata, having either (*a*) more or less distinct adenomatous structure

or (*b*) solid plugs or columns of epithelial cells, or (*c*) a mixture of acini and solid columns.

Epithelioma.

This form, which consists of surface-epithelium, is of two varieties, the squamous and the cylindrical.

Squamous epithelioma occurs in the skin or mucous membranes, where squamous epithelium exists normally. Among the frequent seats are the lips, the esophagus, the larynx, and the cervix uteri. Occasionally squamous epithelioma arises in parts normally covered by other kinds of epithelium; as, for example, in the fundus of the uterus. In these instances there is probably a primary metaplasia of the epithelium followed by carcinomatous growth. Squamous epitheliomata present themselves as nodular, wart-like elevations of the skin or mucous membrane, tending to become ulcerated on the surface. Those of the mucous surfaces are more elevated and softer. Histologically there are seen branching columns of epithelial cells extending downward from the papillæ of the skin into the deeper structures. These consist of large translucent squamous cells which show a tendency to arrange themselves in certain places concentrically to form epithelial *perles*. The latter frequently undergo a horny transformation and sometimes even calcareous change (Fig. 69). The same



Fig. 69.—Squamous epithelioma, showing whorls of epithelial cells with central degeneration (from a photograph by Dr. W. M. Gray).

structures occasionally occur in benign papillomata, but much less frequently. Metastasis is frequently seen in the neighboring lymphatic glands, but the malignancy is less marked than in glandular carcinomata.

Cylindrical Epithelioma.—This form is composed of columnar or cylindrical epithelium, and arises in the mucous membranes, especially in the gastro-intestinal tract and the uterus.

The epithelial cells of the tubular glands or sometimes those of the surfaces form the starting-point of the growth. More or less acinus-like tubular structures, composed of a layer of epithelial cells, or more frequently of a number of layers of epithelia, the outer layer being often distinctly columnar, constitute the characteristic feature of the tumor (Fig. 70). In the later stages

FIG. 70.—Cylindrical epithelioma of the intestine (Perls).

the acini become filled with proliferated epithelial cells of various shapes and the cylindrical or tubular character of the acini is lost. Carcinomata of the kidney, liver, and mammary gland, though not originating from surface-epithelium, strictly speaking, may be of the cylindrical form. Cylindrical epitheliomata are more nearly like the glandular carcinomata in their malignancy and general behavior than the squamous variety.

Glandular Carcinoma.

This term includes the carcinomata that have a resemblance to racemose glands in their histologic structure. They consist of acini or alveoli containing epithelial cells, usually in several layers or completely filling the lumen, and a stroma of connective tissue. Some authors distinguish three forms: the *simple*, the *medullary*, and the *scirrhous*. These are simply variations of the same tumor. In the simple form there is a combination of epithelium and stroma in about the proportion seen in normal glands. The tumor is therefore neither strikingly hard nor soft. In the

medullary or soft carcinoma the amount of epithelium is excessive and the tumor has a soft character (Fig. 71); while the scirrhous,

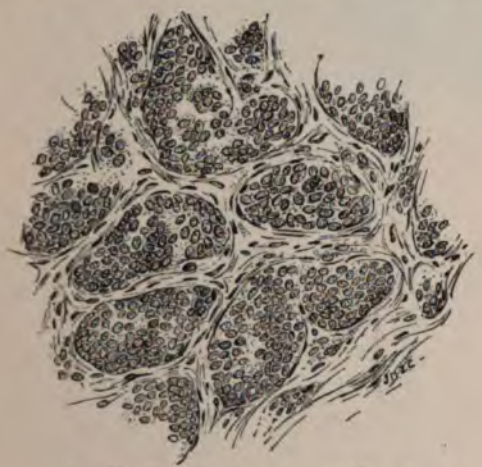

FIG. 71.—Medullary carcinoma of breast.

or hard, cancer is an indurated form, due to excess of fibrous tissue and deficiency of the epithelium (Fig. 72).

The glandular cancers are more or less nodular or infiltrating

FIG. 72.—Scirrhous cancer of breast (Warren).

growths varying in consistency in different cases, but having on section a glistening white color with a certain amount of translu-

cency. Milky liquid exudes from the surface on section. This is composed of albuminous fluid containing degenerated epithelium and free oil-droplets. Among the seats in which these forms occur the most important are the pylorus and other mucous surfaces, the mammary gland, the pancreas, kidneys, ovaries, and testicles. Widespread metastasis and other features of malignancy are noted. In the case of the scirrhous form the primary tumor may be strikingly small in comparison with the amount of metastatic deposit.

Colloid Cancer.

This term is usually a misnomer, as most of the colloid cancers contain no colloid material. The name *gelatinous* would be more appropriate, but has not been generally accepted. Colloid cancers are met with in the stomach and intestinal tract, in the mammary gland, and in the ovaries. The tumor has a peculiar transparent, glistening appearance. The entire mass may be uniformly jelly-like, or only portions of it are affected. Microscopically mucous degeneration of the connective tissue as well as of the epithelial cells is discovered (Fig. 73). In some cases no trace of carcinom-

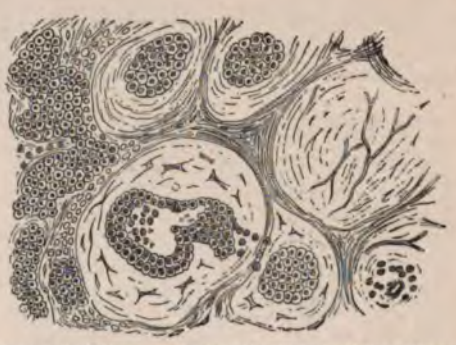

FIG. 73.—"Colloid cancer" of the breast, showing myxomatous change in the stroma and fatty degeneration and partial disappearance of the epithelial cells (Perls).

atous tissue may be discoverable, the whole tumor having undergone degeneration. Sometimes the process involves the epithelium rather than the connective tissue. Colloid cancers frequently spread by direct extension, and the entire abdominal cavity may become filled with gelatinous material, representing degenerated secondary growths. Occasionally the same kind of peritoneal growths seem to originate primarily in the peritoneum, springing from fetal remnants of epithelial tissue (Fig. 74).

True colloid cancer—that is, carcinoma with colloid degeneration of the epithelium—is sometimes seen, though it is very rare. It occasionally causes a gross appearance resembling that of sar-

comatous cylindroma, and the term *carcinomatous cylindroma* has been applied.

FIG. 74.—Colloid cancer of the peritoneum (modified from Birch-Hirschfeld).

SYNCYTIOMA MALIGNUM.

This term is applied to a form of tumor originating at the placental site during pregnancy or the puerperium. It has also been called deciduoma malignum, sarcoma deciduocellulare, destructive epithelial tumor of the placental site, and chorio-epithelioma.

The tumor occurs as a hemorrhagic infiltrating growth, somewhat resembling placental tissue in gross appearance, and frequently gives metastasis by breaking into the blood-vessels. The metastatic nodules are found in the external genitalia, frequently in the lungs, less often in the liver, spleen, or other organs. The growth is rapid, the uterine wall being quickly invaded and metastasis occurring in a short time.

The nature of this tumor is still the subject of some controversy. Two types of cellular elements are recognized in its structure. One of these consists of irregular masses of protoplasm containing dark nuclei. The nuclei probably multiply by direct division. These protoplasmic masses are arranged in islands or in branching columns which form a network. In the meshes of this network are blood-spaces containing thrombi or masses of blood-corpuscles. Sometimes masses like those above described are found within the blood-spaces. The second form of cells consists

of smaller irregular-shaped elements, which are unusually rich in glycogen, and in which cell-division by karyokinesis is observed. These cells lie in masses, of greater or less size, between and beside the larger protoplasmic areas before described. In the later stages of the growth obliterative thrombosis of the vessels leads to necrosis of the cellular constituents, particularly of the columns of large epithelium-like cells. These are converted into homogeneous fibrinous masses, and even the thrombi themselves may degen-

FIG. 75.—*a*, Fibrin, with numerous small round cells caught in the meshes; *b*, cells resembling decidual cells, probably a proliferation of the Langhan's cells; *d*, protoplasmic masses containing large free nuclei.

erate. The view of Marchand regarding the nature of these tumors is most widely accepted. He holds that the larger cells are derivatives of the syncytium (a structure composed of epithelial cells, probably of fetal origin), while the smaller cells are formed from the epithelial covering of the chorion villi (Langhan's cells). The tumor, therefore, is epithelial in nature, and it has malignant properties. It differs, however, from ordinary epithelioma and from carcinoma in its peculiar structure and in its clinical course and dissemination.

CYSTS.

Definition.—This term includes pathologic formations of varied character. Some are true tumors; others are of quite different nature.

The term cyst is applied to pathologic formations consisting of a more or less well-defined wall and enclosing liquid or semiliquid contents of different character from the surrounding parts. This definition is not entirely applicable, as certain structures that do

not present a definite capsule are sometimes termed cysts. Accordingly we may distinguish between *true cysts* and cyst-like formations or *cystoids*, the former being enclosed by a capsule lined with epithelium or endothelium; the latter merely presenting a circumscribed collection of softened material.

Classification.—According to the method of formation, we distinguish retention-cysts, softening-cysts, cysts due to the presence of foreign bodies, and proliferation-cysts.

Retention-cysts are formed when the excretory ducts of a gland become occluded and the secretions accumulate and cause distention of the acini or of parts of the duct. Among such cysts may be named the distended sebaceous glands of the skin in the formations called *wens;* the cysts of the salivary or small mucous glands or ducts under the tongue, called *ranulæ;* retention-cysts formed in the uriniferous tubules, the tubules of the ovary, or in the parovarium, in the acini and ducts of the mammæ, pancreas, and other glands. An entire organ may become converted into a cyst, as in cases of distention of the kidney (hydronephrosis) from obstruction of the ureter.

These cysts are distinguished by the fact that they have a distinct connective-tissue wall lined with epithelium or endothelium. The contents of the cyst depend upon the part in which the formation has taken place.

Softening-cysts occur in consequence of degenerative softening of normal or pathologic tissues. They are not rarely the result of hemorrhage, the blood-clot first becoming inspissated and then serous exudation occurring in the area of hemorrhage. Softening-cysts are very common in tumors of different kinds.

Cysts due to foreign bodies are in part softening-cysts. The tissues in the immediate vicinity may be injured and undergo necrotic softening, while connective-tissue reaction produces a capsule. This form of cyst is most frequently the result of invasion of parasites, and the cyst-contents may be composed of the parasite or the parasite and tissue-elements more or less degenerated.

Proliferation-cysts.—This term is applied to formations more closely analogous to true tumors than those mentioned before. They merit more extended description than the other forms of cysts, and may be designated as epithelial cysts.

Epithelial Cysts.

Definition.—In certain glandular organs, notably the ovary and mammary gland, cystic formations occur which present striking appearances; and though perhaps they represent adenomatous or carcinomatous new growths, are so striking as to deserve special mention.

Etiology.—These growths, in part at least, result from obstruction of excretory ducts and subsequent irritation by retained secretions. Congenital abnormalities of structure may possibly play a part in their causation.

Appearance.—Cystomata may be single or multiple, the entire tumor being composed either of a single cyst or of one large cyst subdivided into many smaller, or again of numerous separate and unconnected cysts of varying size. On section the cystic cavities are found to contain more or less serous or gelatinous liquid, and sometimes hemorrhagic fluid is observed. Most frequently the liquid is gelatinous or ropy, and is commonly spoken of as colloid material. The inner lining of the cyst may be smooth, like a serous or mucous surface, or elevated irregularly in the form of polypoid outgrowths into the cavity of the cyst. The entire cyst may thus be filled with papillomatous elevations from the epithelial lining. The term *papilliferous* or *proliferative cystomata* is given to these forms (Fig. 76). The size of cystomata



FIG. 76.—Papilliferous adenocystoma of the kidney (Karg and Schmorl).

varies from minute tumors not larger than a pea to enormous masses weighing as much as sixty or eighty pounds. Secondary degenerations may occur in the form of softening, hemorrhage, or calcification.

Seats.—The mammary gland and ovary are the principal situations in which tumors of this description are met with, but analogous growths may make their appearance in any of the glandular organs.

Structure.—Microscopically these growths present cystic cavities lined with typical or modified columnar epithelium and a stroma or reticulum of connective tissue. The amount of the

latter and the appearance of the cysts themselves vary in different cases. At times the stroma is very abundant and takes the form of well-organized fibrous tissue, while the cysts and acini are small and few in number. In these cases the appearance suggests a primary proliferative connective-tissue process with secondary implication of the epithelial elements. Such cases occur particularly in the mammary gland, and there is difficulty in separating them sharply from instances of chronic interstitial mastitis or diffuse fibroma. In other instances the process manifestly begins with the formation of epithelial acini, and the hyperplasia of the connective tissue is certainly secondary. The acini in these cases present themselves as hollow spaces of varying shape and size, often branching, and lined with columnar epithelium in a single layer or sometimes with several layers of more or less differentiated columnar epithelium.

Nature.—These cystic growths often have a decided tendency to malignancy. They may remain benign throughout; but frequently they undergo carcinomatous change and spread widely or give rise to metastasis. The malignancy is generally in proportion to the amount of the epithelial proliferation and papilliferous change, but there are instances in which metastasis occurs from adenocystomata having regular gland-acini lined with single layers of typical columnar cells. The cystomata of the ovary not rarely extend to the surface of the organ, break through the capsule, and present upon the surface as papillary growths, and frequently they extend to the peritoneum and neighboring structures. The entire abdomen may be involved. At the same time, or in other cases independent of such direct extension, metastatic deposits may be seen in nearby lymphatic glands. Somewhat the same conditions may be observed in cystoma of the breast, but in this situation the tumor is much more frequently confined within the capsule of the organ.

TERATOMA.

Definition.—The term teratoma is applied to tumors of peculiar mixed character, representing different elements of complex tissues or structures in a situation in which these do not normally occur. For example, the most frequent form of teratoma contains various epidermal structures, such as hair, teeth, etc., and occurs in internal organs.

Etiology.—The causation of teratoid tumors or teratomata is to be sought in congenital misdevelopments. We may, with Klebs, distinguish *endogenous* forms, in which inclusions of superficial tissues are retained in internal parts by a process of constriction; and *ectogenous* forms, in which a separate fetal deposition is the origin of the tumor. The latter form represents a separate and

ill-developed fetus within the developed organism—a *fetus in fetu.* A regular gradation may be traced from distinct teratoid tumors having irregular mingling of tissue-elements, to malformations in which a more or less systematic outgrowth, somewhat approaching double monstrosities, occurs. Of the distinct teratoid tumors the most frequent is the dermoid cyst.

Dermoid Cyst.

This tumor presents itself as a cystic formation with a connective-tissue membrane and an inner lining resembling the skin. This may present all the elements of the skin, such as stratified epidermis, a papillary layer, and even subcutaneous connective tissue. Hair-follicles and sebaceous glands are frequent, and habitually long, light-colored hairs are found within the contents, and teeth may be found in the lining membrane or free in the contents of the cyst. The cyst is filled with a semifluid, cheesy mass consisting of epithelial cells, fatty matter, and other detritus. Occasionally dermoid cysts may contain nerve-tissue, muscle, or structures resembling intestine.

The dermoid cysts vary in size from minute bodies no larger than a pea to huge masses, the latter being most frequent in the ovaries. Among the situations in which dermoids occur the ovaries are most common; less frequently they are found in the testicles, in the peritoneum, in the membranes of the brain, about the eye, in the neck, floor of the mouth, and elsewhere. Growth is very slow, and they may remain practically latent through life.

The nature of these tumors is usually benign, though carcinomatous change may occur, and in the ovaries cystoma is prone to be associated, and the latter may be malignant.

Other Teratoid Tumors.

Nodular masses may appear about the head or neck or in various parts of the body, consisting of mingled tissues of various kinds, such as glandular tissues, connective tissues, nerve, muscle, etc. These can be classified as teratoid growths. Sometimes they resemble some definite organ, as in the case of growths appearing at the umbilicus of the new-born and simulating the structure of normal intestine.

In the neck there are sometimes seen more or less cystic growths lined with epithelium and having in their walls muscle-fibers, lymphoid tissue, cartilage, etc. These growths probably spring from remnants of the embryonal branchial clefts. The mixed tumors of the parotid gland (see Sarcoma) are allied to these.

Cholesteatoma.—This tumor is characterized by glistening, whitish, or pearly bodies composed of concentric layers of cells resem-

bling epithelium (Fig. 77). Sometimes crystals of cholesterin are found in the center of these bodies, whence the name cholesteatoma. Cholesteatomata are found in the membranes or substance of the brain, and present themselves as single or multiple nodules. They are usually soft and glistening in appearance.

FIG. 77.—Cholesteatoma from the membranes of the brain.

Some authors consider them endotheliomata, but Ziegler has found hair-follicles and hairs in certain specimens, and from this, as well as from the horny change to which the cells in the pearly bodies are prone, classifies them among the teratoid growths.

Somewhat similar tumors occur in the pelvis of the kidneys, in the testicles, parotid glands, ovaries, and middle or external ear.

CHAPTER VII.

BACTERIA AND DISEASES DUE TO BACTERIA.

History.—Although for many centuries there had existed the idea that disease and decay are due to the action of minute organisms, it was not until the use of the lens enabled the Dutch naturalist Leeuwenhoeck actually to demonstrate their presence in water and in human intestinal contents that the hypothesis of a "contagium vivum" became more than mere guesswork. He discovered, even with his imperfect instruments, short rods, curved and straight, and described their motility. Müller (1785), by the use of the compound microscope, attempted a more systematic

classification of these micro-organisms, and from this time many investigators have added much to our knowledge of microbes, that group of organisms which had been denominated by Linnæus by the term Chaos. To the German Henle is due the credit of having first introduced an idea of order into this disorder. He held that fermentation was the result of organic life, and that the action of a contagium was analogous to that of a ferment. The earliest systematic experimental work was that of Pasteur, in which he established beyond doubt this relation between fermentation and the life and development of bacteria. The first definite ideas of the physiology of these micro-organisms are found in his experiments on lactic-acid fermentation, and those of their pathogenesis, in his demonstration of the microbic origin of the silkworm-disease (1869). Davaine and Rayer about the same time established the causal relation of a bacillus found in the blood of a sheep dead of anthrax to that disease.

CLASSIFICATION.

Bacteria (schizomycetes, or cleft fungi) is the name given to a branch of the lowest and simplest of the orders of the vegetable kingdom. They are small, unicellular organisms, generally free of chlorophyll, and colorless; they possess a cell-membrane albuminoid in composition and homogeneous protoplasmic cell-contents. Some varieties are motile. Nuclei are absent, though in the opinion of some the whole cell may be regarded as a nucleus. Bacteria multiply by cell-division, sexual distinctions being absent. In many species resistant forms—spores—occur.

The simple elementary forms that occur are of three kinds: the coccus, the bacillus, and the spirillum (Fig. 78).

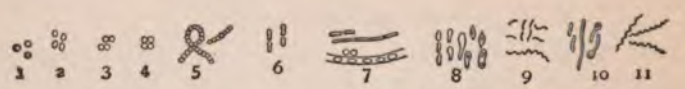

FIG. 78.—Various forms of bacteria: 1 and 2, round and oval micrococci; 3, diplococci; 4, tetracocci, or tetrads; 5, streptococci; 6, bacilli; 7, bacilli in chains, the lower showing spore-formation; 8, bacilli showing spores, forming drumsticks and clostridia; 9 and 10, spirilla; 11, spirochetæ.

Coccus.—This is a spherical cell, varying in size up to 1 μ in diameter. It takes the anilin-stains readily. Spore-formation and motility are rare. When the cocci are found in groups, the individuals being entirely separate, they are termed staphylococci, from the resemblance of the groups to a bunch of grapes; when in pairs, diplococci; when in chains, streptococci; when in groups of four, tetrads or merismopedia; when in packets, sarcinæ.

Bacillus.—A rod-shaped, cylindrical cell of varying length and thickness. Spore-formation and motility are common. Most

of the group stain easily with the anilin dyes, but some require special methods of staining.

Spirillum.—A cylindrical, rod-shaped cell, curved or spiral, sometimes motile. It stains readily.

Many other classifications, all of them being to a certain extent artificial, have been made by different authors. Probably one of the most useful and scientific is that of Migula:

I. Coccaceæ.—Spherical cells dividing in one, two, or three directions. Endospores rare.

1. *Streptococcus.*—Division in one direction, the individuals cohering to form chains. Motility absent.
2. *Micrococcus.*—Division in two directions, the individuals when coherent forming groups of four. Flagella absent.
3. *Sarcina.*—Division in three directions, forming packets of eight, twenty-seven, or more cells. Motility absent.
4. *Planococcus.*—Division in two directions, as in the micrococcus. Motility present.
5. *Planosarcina.*—As the sarcina. Motility present.

II. Bacteriaceæ.—Rod-like, cylindrical cells, dividing at right angles to the long axis.

1. *Bacterium.*—Cells without flagella, often with spores.
2. *Bacillus.*—Cells with peritrichous flagella, often with spores.
3. *Pseudomonas.*—Cells with polar flagella; spores rare.

III. Spirillaceæ.—Cells cylindrical, curved, bent, or spiral. Division as in II.

1. *Spirosoma.*—Cells rigid, without flagella.
2. *Microspira.*—Cells rigid, with one, rarely two or three, polar flagella.
3. *Spirillum.*—Cells rigid, with five to twenty polar flagella.
4. *Spirocheta.*—Cells flexible, motile, but without flagella: perhaps possessing an undulating membrane.

IV. Chlamydobacteriaceæ.—Cells united in a simple unbranched filament. Division in one direction. Forms non-motile; conidia.

1. *Streptothrix.*—Cells united in a simple unbranched filament. Division in one direction. Forms non-motile; conidia.
2. *Cladothrix.*—Cells united in a filament, with a false branching.
3. *Crenothrix.*—Cells united in an unbranched filament, and dividing in three directions into small rounded cells.
4. *Phragmodiothrix.*—Cells at first united in an unbranched filament, and dividing in three directions. Later the separate cells break through the thin membrane and grow out as branches.
5. *Thiothrix.*—Cells united in an unbranched filament contained in a thin membrane. Division in one direction. Cells contain granules of sulphur.

V. Beggiatoaceæ.—Cells united in a filament without sheath. Motile, the movement being due to an undulating membrane.

MORPHOLOGY.

Cell-contents.—The body of the organism in unstained conditions appears as a perfectly homogeneous protoplasmic mass. On staining with anilin dyes a granular appearance is often observed, which under high powers is resolved into a hyaline mass containing numerous chromophilic granules. Vacuolations also are often

present. Some modern observers (Bütschli *et al.*) have made out a network immediately within the membrane and surrounding a central body which readily stains with the nuclear dyes. This latter they regard as a nucleus. Others, however, affirm that this appearance is due to a concentration of the cell-protoplasm (endoplasm), the result of the rather complicated method of staining. The question of the presence or absence of a nucleus is still an open one. In many organisms, as the Bacillus diphtheriæ from a blood-serum culture, for example, there exist certain transparent refractive bodies which stain differently from the rest of the microbe. These metachromatic bodies, as they are called, were regarded by Ernst as nuclear in character. Others look upon them as possibly the primary state of spore-formation.

Spore.—The spore is a non-vegetative resistant form that the microbe assumes when the conditions for growth are unfavorable. The endoplasm seems to concentrate and become a small, oval, highly refractive body, separated from the bacterial protoplasm by a membrane of its own. It is generally of the same diameter or somewhat smaller than the bacillus itself, and is situated either in the middle (equatorial) or at the end of the microbe (polar spore). It may be larger in diameter than the microbe and cause a swelling at that point. When in the center of the rod this gives rise to the form known as clostridium; when polar, to the so-called drumstick-form (as in the Bacillus tetani).

Such intracellular spores or endospores occur among many bacilli. Among the micrococci they are rare; but it is supposed that certain individual cocci become larger and more refractive in appearance and assume the spore-state. These are called *arthrospores*. Whether these can be regarded as true spores is still doubtful.

The spore is extremely resistant to conditions to which the vegetative form readily succumbs; to the action of certain chemical reagents, light, heat, etc. Bacteria that are grown on media poor in nutrient material tend to become asporogenous. A certain temperature is also necessary for spore-formation. Thus, although the anthrax bacillus develops well at a temperature of 14° C. (57° F.), it does not form spores below 18° C. (64° F.). To obligate aërobes oxygen is necessary for their development, and anaërobic cultures present them only in the absence of that gas. Placed under conditions favorable to its vegetation the spore loses its clearness, absorbs water, and swells. A small prominence presents at the side or end, which gradually lengthens and develops into a young bacillus. The membrane of this new microbe is formed from the inner layer of the spore-membrane (*endosporium*), while the outer layer (*exosporium*) is cast off. In not all of the varieties of bacilli does sporulation take place, and even where it does occur there may, under certain conditions, as in growth at

high temperatures, arise races which have lost this power (asporogenous races).

The spore does not stain readily with the ordinary anilin stains, and special methods have been devised for coloring it.

Cell-membrane.—Surrounding each organism is a membrane (*ectoplasm*) denser and more highly refractive than the cell-contents (*endoplasm*). In some cases this is not to be differentiated from the endoplasm; but in others it is larger, and under certain conditions becomes a gelatinous mass. In this case it is easily seen, especially after appropriate staining. This is called the *capsule*. In general this occurs only when the bacteria develop within the animal organism, and not upon artificial culture-media. It is probable that the ectoplasm is not a mere protective envelop, but has to do with the functional activity of the bacterium. The fact that the flagella, to which is due the motility of certain microbes, are directly continuous with and are simply prolongations of this membrane, points to this view.

The cell-membrane is not easily colored by ordinary methods.

Flagella.—Motility is often a property of bacteria. It is manifested in different ways, and is often characteristic of the several varieties of bacteria. Some move slowly forward across the field, others with great rapidity; others again dart hither and thither, slowly or so quickly as to be with difficulty observed. They may at the same time have a rotary movement around their long or their short axes.

After appropriate staining the cause of this motility is seen to be the presence of slender, whip-like prolongations, originating directly from the ectoplasm (Babes). They may be twenty times as long as the body of the bacterium, and are arranged in the different species in different ways. Bacteria that possess no flagella are termed Gymnobacteria; those that have these organs, Trichobacteria. There may be but one flagellum, situated at the pole (*monotrichous*), or a number may be present (*lophotrichous*). When they are situated at both poles the microbe is termed *amphitrichous;* when distributed over the whole body of the bacteria, *peritrichous*. The presence and the activity of flagella depend on many factors: on the condition of the medium, bacteria grown from liquid media being more active than those from solid; on temperature; on presence of air; on light; and on the age of the culture. They are easily broken off from the microbe, and care must be used in staining them. A special method is employed.

Involution-forms.—By involution-form is meant the irregular appearance a microbe often assumes when its conditions of growth are unfavorable. Numerous bacteria melt together and become irregular chains, or they appear pear- or club-shaped. The protoplasm becomes retracted and irregular staining takes place. Sometimes the microbes lose all characteristic appearances.

Sometimes forms with branching projections are discovered. These have often been described as involution-forms, but are now more commonly regarded as normal, though unusual, structures. This applies to tubercle bacilli, diphtheria bacilli, and some others. This true branching (dichotomy) must not be confounded with false or pseudodichotomy, due to mere apposition of separate organisms, as seen in various bacilli, streptococci, etc., and habitually in the cladothrices.

Chemistry.—The bacterial cells are of variable composition, depending to a great extent upon the kind of nutrient matter. It consists mainly of water (85 per cent.). The chief solid material is albumin. This varies according to the medium of growth, and has been given the general name of *mycoprotein* (Nencki). Fat is also present. The nuclein-bases, xanthin, guanin, adenin, and cellulose, have been found by some. Some contain certain coloring-matters, bacteriopurpurin and a green substance similar to chlorophyll. Organic acids and ferments of different kinds are also found. In some special forms—the sulphur bacteria—sulphur is present.

DEMONSTRATION.

The success of the microscopic examination of bacteria in the several fluids and tissues of the diseased body and in pure cultures depends upon the differentiation of the microbes from the surrounding substances by certain chemical reagents. The process is twofold: to render more transparent the non-bacterial elements and to render more visible the bacteria themselves. Thus a $1\frac{3}{10}$ per cent. solution of sodium hydrate dissolves the histologic elements except the fatty, elastic, pigmentary, and amyloid substances and bacteria.

Methods of this sort have been entirely superseded by the use of the anilin dyes. We can with these render bacteria more visible and at the same time differentiate them from the surrounding tissue by means of contrast- or counter-stains.

Microbes, generally, stain with dilute aqueous or alcoholic solutions of the anilin colors, but they differ greatly in the readiness with which they take the stain and the tenacity with which they hold it after treatment. To stain some it is necessary to employ heat or to add some chemical substance to act as a mordant and enable the stain to pass through the cell-membrane. The most important of these are potassium hydrate, anilin oil, alcohol, carbolic acid (1–5 per cent.), acetic acid (0.5–1 per cent.).

Some bacteria decolorize easily, even with water; others can be placed in alcohol, and some in strong solutions of mineral acids, without losing their color. Those bacteria that stain easily are the most readily decolorized.

Among the more frequently used of the anilin dyes are: methylene-blue, dahlia, fuchsin, vesuvin, gentian-violet and thionin. The following are useful formulæ:

Löffler's methylene-blue:

Saturated alcoholic solution of methylene-blue	30 cc.
Aqueous solution of potassium hydrate (0.01 per cent.)	100 cc.

Carbolized thionin:

Saturated alcoholic solution of thionin	10 cc.
Carbolic-acid solution (1 per cent.)	100 cc.

Bacteria stained with these upon cover-glasses need no after-treatment, but tissues are to be decolorized with alcohol. With Löffler's solution the decolorization must be stopped at a point where the protoplasm is colorless and the nuclei are faintly stained. The bacteria remain a bright blue. Bacteria stained with thionin retain a reddish tinge, however, even after prolonged action of the alcohol.

Ziehl's solution is the best known stain for the Bacillus tuberculosis:

Fuchsin	0.25 gm.
Alcohol	10 cc.
Carbolic-acid solution (5 per cent.)	100 cc.

Treated with this for some three to five minutes (for tissues longer) and with heat, the bacilli retain their red color after the use of strong mineral acid solutions (sulphuric, nitric, or hydrochloric acid, 25 per cent.). A counter-stain, to color the decolorized cellular elements, is used, and methylene-blue is generally employed. Gabbett mixes the contrast-stain with the sulphuric-acid solution.

Gram's Method.—Another important differential stain is that devised by Gram. The specimen is treated for some minutes in an anilin-water solution of gentian-violet. Anilin-oil (4 cc.) is well shaken up with 100 cc. of distilled water, filtered, and to this is added 1 cc. of saturated alcoholic solution of the violet. The specimen, stained a few minutes with this, is treated with an iodid-iodin solution (iodin, 1 gm.; potassium iodid, 2 gm.; water, 300 cc.), which fixes or in some way modifies the stain in the bacteria and decolorizes other elements. The further action of alcohol decolorizes certain varieties of bacteria stained in this, while others it leaves unchanged. Bacillus anthracis, tuberculosis, tetani, lepræ, diphtheriæ, rhinoscleromatis; Staphylococcus aureus, albus, and citreus; Streptococcus pyogenes; Pneumococcus;

Micrococcus tetragenus; and Actinomyces hominis are the most important species that retain the stain. The Gonococcus; Bacillus pneumoniæ, typhi abdominalis, coli communis, mallei; and Spirillum choleræ Asiaticæ are among those that are decolorized.

Staining sections is more difficult: it takes longer time and must often be aided by heat. This results in overstaining, and decolorization is necessary. Many substances have the power of decolorizing the tissue-elements in the following order: the first to lose the color is protoplasm, then the nuclei, and lastly the bacteria. For such differential decolorization alcohol, anilin oil, or acid alcohol is the most used, the point aimed at being to stop the decolorization as soon as the nuclei have begun to lose their color. Some stains are not removed by this means, as Gram's and thionin.

To *stain spores*, the specimen is fixed by passing through the flame and then put for a half to one hour in fuchsin, either an aqueous or alcoholic solution, or in Ziehl's solution. The bacterial protoplasm is then decolorized by alcohol or very dilute nitric acid and counter-stained with Löffler's blue.

The *capsule* is colored with Ziehl's stain and the cell-contents decolorized with dilute acetic acid (1 drop to 5 cc. of water). Ribbert saturates with dahlia the following: distilled water, 100 cc.; alcohol, 50 cc.; acetic acid, 12.5 cc.), and stains but a few seconds. A very useful method is to stain the bacilli with Löffler's blue for a few minutes and wash for the same time with anilin-gentian-violet. The bacilli are blue against a reddish background, the capsule standing out uncolored. This is especially useful in staining sputa.

Flagella are still more difficult to stain. The cover-glasses must be carefully cleansed from all dust and grease. After fixation they are treated with a mordant while hot:

Aqueous solution of tannin (20 gm. to 80 cc.) . .	10 cc.
Aqueous solution of ferrous sulphate	5 cc.
Alcoholic solution of fuchsin	1 cc.

The stain is a saturated solution of fuchsin in anilin-water. As used by Löffler, a certain quantity of alkali or acid is added to the mordant, according to the species of bacteria, but this has been found to be unnecessary.

BIOLOGY.

Bacteria may be divided into two great classes: those that live only on dead organic matter are termed *saprophytes;* those that develop in and at the expense of the living organism, *parasites.* These latter by their growth cause certain pathologic con-

ditions in the host, and are called pathogenic. By *obligate* saprophytes or parasites we mean those that can exist only under the conditions named; by *facultative* saprophytes and parasites, those that can develop under both conditions.

Conditions of Growth.—Certain surrounding conditions are necessary to bacteria, and any marked change in them will inhibit the growth or totally destroy it.

Mechanical Conditions.—A slight shaking of a liquid culture seems to help the development of bacteria, while a more violent and long-continued agitation, destroys them.

Physical Conditions.—*Electrical currents* destroy the growth, but probably by the action of certain products of the electrolysis, and not by direct action.

Light.—Diffused daylight inhibits the growth of bacteria: sunlight and, to a less extent, electric light destroy them.

Heat.—A certain temperature is necessary, the degree varying with the species of microbe. Most of the water bacteria and saprophytes grow between 0° and 30° C. (32° and 86° F.), the optimum being 15°–20° C. (59°–68° F.) (Psychrophilic). The pathogenic flourish between 10° and 45° C. (50°–113° F.), best at the body-temperature, 37° (98.6° F.) (Mesophilic). There are some that develop well at 40°–70° C. (104°–158° F.) (Thermophilic). Above these limits the members of the several groups are killed, and each bacterium has its own thermic death-point. That of most of the pathogenic varieties lies between 50° and 60° C. (122° and 140° F.). Below the lower limit the growth is inhibited only; very low temperatures (—250° C.; —418° F.) having been used without preventing the future development of the microbe.

Spores are extremely resistant to higher temperatures. While no bacterium can live after exposure to 100° C. (212° F.), the spores of some of the earth microbes are killed only after exposure for an hour to steam heated to 115° C. (239° F.).

Chemical Conditions.—The essential substances for the growth of bacteria are water, carbon, nitrogen and oxygen, and certain salts. For the carbon, they require already prepared carbon compounds, as the sugars, glucose, saccharose, lactose, etc., mannite, glycerin—in fact, most of such as are soluble in water. Most of the proteids and many simpler substances, even such as ammonium carbonate, furnish the nitrogen. Free oxygen is necessary for many microbes. Those for which this is absolutely required are termed obligate aërobic. Facultative aërobes are those that grow best in the presence of oxygen, but may develop in its absence. Anaërobic microbes are those that grow best without oxygen and are also obligate and facultative. It has been found possible to produce races which, although naturally obligate anaërobic, develop also in an atmosphere of oxygen.

Artificial Cultivation.—It is difficult and often impossible to study the growth of bacteria in their natural habitat. Hence we have recourse to artificial media, upon which we can study the growth and morphology of the organisms and the various phenomena that it brings about in different substances.

Media for Cultivation.—*Uschinsky's fluid* is a non-albuminous medium:

Water	1000 cc.
Glycerin	30–40 gm.
Sodium chlorid	5–7 gm.
Calcium chlorid	0.1 gm.
Magnesium sulphate	0.2–0.4 gm.
Calcium phosphate	2.5–3 gm.
Ammonium lactate	6–7 gm.
Sodium asparaginate	3–4 gm.

Bouillon.—Water, 1000 cc.; lean beef or veal, 500 gm.; salt, 10 gm.; peptone, 5 gm. The beef is soaked in water and then filtered. To the filtrate are added the salt and peptone, and the whole boiled for some fifteen to twenty minutes. It is then rendered slightly alkaline and filtered and sterilized. Ordinary beef-extract may be substituted for the fresh meat. Growths of bacteria in this medium are not especially characteristic, but in some species important differences appear. The liquid may become clouded or remain clear, the growth settling to the bottom of the tube as a flocculent deposit. The presence or absence of any growth on the surface of the bouillon (a membrane or mycoderm) is noted, as is also any change in the reaction.

Peptone solution, prepared in the same way, but omitting the beef, is of use in the determination of the indol-reaction (see Bacillus typhi abdominalis).

Liquid blood-serum is rarely employed.

Milk, slightly alkaline and to which a small quantity of litmus or lacmoid may be added, is employed in determining changes of reaction and the action of caseating ferments.

Extracts of many vegetable substances are also used, as hay, potato, brewer's malt, etc.

Potato-extract, prepared by rubbing up 500 gm. of potato in 500 cc. of water, decanting and diluting to 1000 cc., and adding 40 cc. of glycerin, is a good culture for the Bacillus tuberculosis.

Solid media.—The two most important solid media are *gelatin* and *agar-agar*. These are used in 10 per cent. and 1 per cent. solutions, respectively, in bouillon. Many bacteria produce a proteolytic ferment that liquefies gelatin. Other distinctions also are met with in cultures upon this media.

Blood-serum is placed in test-tubes, slanted and sterilized for

one to two hours on five consecutive days at 60° C. (140° F.). The temperature is then raised to the point of coagulation of the albumin and the serum is thus solidified. Löffler mixes with the liquid serum one-third part of bouillon containing 1 per cent. of glucose. A more rapid way is carefully to solidify the serum on a water-bath or in the hot-air sterilizer, and then sterilize in steam on three separate days.

Glucose, lactose, or saccharose, added to these media, may be used to study the action of the various ferments.

Glycerin (5–6 per cent.) added to agar-agar forms good media for the growth of the tubercle-bacillus.

Potatoes and other vegetables, cut in the form of half cylinders, are also used.

Inoculation of Media.—In studying the growth of micro-organisms a portion of the culture-fluid, or other substance to be examined, is transferred to the various culture-tubes. To do this an inoculating-needle (*öse*) is employed. This is most conveniently made with a piece of platinum wire one to one and a half inches in length, either straight or with looped end, and fastened into the extremity of a glass rod. It should be an invariable rule to sterilize this needle in the naked flame both before and after it is used. In inoculating liquid media the transference of a loopful of the culture or other substance is made to the culture-tube. When solid media are employed a straight puncture may be made into the medium, or this latter may be solidified in a slanted position and the needle drawn along the surface. Due regard must be had for the richness in bacteria of the substance examined. With pure cultures but a minute quantity is transferred; with blood, however, large amounts, even ½ to 1 cc., is often used.

To study the appearance of the separate colonies cultures on gelatin or agar plates are made. The medium is melted and then cooled to a temperature not destructive to the bacteria; 40° C. (104° F.) for agar, lower for gelatin. The liquid medium is inoculated carefully and poured into sterilized shallow glass dishes. Those devised by Petri are useful. They are from three and a half to four inches in diameter and half an inch or less deep. Each microbe is supposed to form by its growth a separate colony, and in this way different species can be easily isolated and reinoculated on fresh tubes. When cultures are used, or when the bacteria are very numerous, the requisite dilution may be made by inoculating a second tube from the first, and in like manner a third from the second. Esmarch, instead of pouring plates, quickly rolled the tubes on a piece of ice or in ice-water, thereby forming a thin coating of the solid medium on the inner surface of the tube. If it is necessary to make a numerical estimation of the bacteria, definite quantities of the medium and

culture must be employed in the dilution. Sterilized pipettes are used in the process of diluting.

Anaerobic Cultures.—These are made by growing the inoculated tubes or plates in the absence of oxygen, either by exhausting the air or by replacing it by some inert gas, preferably hydrogen. Many tubes have been especially devised for this purpose. A more convenient method is to make a deep puncture in a gelatin or agar tube, and then preventing the absorption of oxygen by nearly filling the tube with melted sterile medium. It has been also proposed to inoculate the surface of such a tube with a culture of a strict aërobic microbe. Glass tubes of small caliber and a foot or more in length, and filled with inoculated melted media and sealed in a flame, give good results.

Aërobic cultures grown in the absence of oxygen do not form spores, and may be destroyed by a subsequent temperature of 80° C. (176° F.), thus permitting the sporogenous anaërobic forms to develop in pure culture.

FUNCTIONS AND PRODUCTS OF BACTERIA.

The study of the substances that result from the action of the life of bacteria and the changes that they produce in their various media of growth is really a branch of organic chemistry. The function of bacteria is essentially a destructive one. They split up the higher nitrogenous and non-nitrogenous compounds into simpler substances.

The various substances that are found in the media of bacterial growth comprise: (1) the components of the bacterial cell proper, as the proteins; (2) the secretions of the cell, as the ferments; and (3) substances that are the result of the action of microbes upon the medium of growth.

(1) The first group has already been spoken of (see page 186).

The proteins may produce suppuration (*pyogenic*) or fever (*pyrogenic*), or they may be the cause of an inflammatory process (*phlogogenic*). The best known examples are mallein, derived from the bacillus of glanders, and tuberculin, from that of tuberculosis. These are pyrogenic when injected into animals suffering respectively from glanders or tuberculosis, but have no, or at least very slight, effect upon healthy subjects. Other proteins are shown to have similar effects on tuberculous animals. In practice the curative effect of these has not proved of much worth.

(2) The second group of products includes the ferments and possibly the toxins.

Ferments.—A ferment is a complex body about which we know but little except the effects that it produces. By its presence, and probably without entering into intimate chemical combination, it possesses the power of breaking up more highly organ-

ized nitrogenous and non-nitrogenous compounds into simple, and more diffusible molecules. They are termed *enzymes* or *unformed ferments* in contradistinction to the bacteria themselves, which are called *formed* or *living ferments*. That the action of ferments is not due directly to the microbe is shown by the facts that bactericidal substances, such as phenol (5 per cent.), chloroform, ether, etc., have no effect on them, and that cultures freed from bacteria by filtration still possess fermentative power. The action of ferments is termed *fermentation*, but the term is more especially limited to their effect upon non-nitrogenous compounds, particularly the carbohydrates. The result of fermentation upon nitrogenous material is called *putrefaction*, which generally occurs with, though often without, the formation of odorous gases and other substances.

The principal bacterial ferments are:

Proteolytic Ferments.—These transform albumins into more soluble and diffusible substances. One form very often met with is that which liquefies gelatin. This acts in an alkaline medium, and is therefore akin to the animal ferment trypsin. This liquefaction of the gelatin affords a means of distinguishing many species of microbes.

Diastatic Ferments.—These transform the starches into sugars, and are found in many bacterial cultures, as of Bacillus mallei, Bacillus pneumoniæ, etc.

Inverting Ferments.—These change the non-fermentiscible sugars into those that undergo direct fermentation. Such ferments are found, for instance, in cultures of Spirillum choleræ and Metschnikowi.

Emulsifying Ferment.—This is formed by but few microbes. One example is Micrococcus pyogenes tenuis.

Coagulating Ferment.—One of the means of differentiation of bacteria is the coagulation of milk used as a culture-medium for the bacteria under observation. This coagulation is due not to acidity produced in the medium, but to the action of a ferment.

Some varieties of microbes produce a ferment that has the power of dissolving this coagulum when formed (casease); and still others produce both ferments—the coagulating and the dissolving.

Hydrolytic ferments are such as break up urea into ammonium carbonate and hippuric acid into glycocol and benzoic acid.

Fat-splitting ferments split the fats into glycerin and the fatty acids.

Oxidizing and **nitrifying ferments** are other less important forms.

Effects of Ferments.—The single or combined action of these various ferments causes certain special kinds of fermentation distinguished by the principal substance produced. Alcoholic,

lactic-acid, and butyric-acid fermentation of the sugars, acetic-acid fermentation of alcohol (Bacillus acidi lactici, Bacillus butyricus, Bacillus acidi butyrici, Bacillus aceticus, etc.); cellulose fermentation with the production of carbonic-acid gas and ammonia; nitrification, due to the oxidation of ammonium and the production of nitrates (Winogradsky's nitromonas) and nitrites; mucoid fermentation of glucose and invert-sugar are examples.

(3) Substances produced by bacteria from the culture-media and tissues are varied and numerous. Besides those produced by the various fermentative processes there are: the products of digestion of albumin, albumoses, peptone, etc.; the ptomains; nitrogenous substances, as leucin and tyrosin, methyl-, dimethyl-, trimethyl-, ethyl-, propylamins; organic fatty acids, formic, acetic, propionic, butyric, margaric, lactic, etc.; certain aromatic compounds, as indol, phenol, kresol, skatol, mercaptan, hydrochinon, etc.; and finally, hydrogen, carbonic dioxid, hydrogen sulphid, ammonium, water, etc.

Toxins.—Further, the pathogenic bacteria produce both by analysis and synthesis certain toxic substances which are akin to the poisonous venom of certain serpents and other animals, and to certain poisonous principles of plants, as abrin and ricin. These are of indefinitely determined character, and act deleteriously upon the organism only after the lapse of a certain time—a period of incubation. They are considered the *specific toxins* of the several bacteria. According to some, these give all the reactions of albumin, and have been termed *toxalbumins* (Brieger). It is probable, however, that a toxalbumin is but an impure form of the true toxin, a combination of it and various substances derived from the medium of growth. Some authors regard it as an albuminose; others, as a peptone. Most recent investigators look upon the toxin as a ferment akin to the diastatic or hydrolytic ferments. Roux and Yersin, in their monograph on the Bacillus diphtheriæ, hold this view. Many facts seem to support this theory. The analogous pathologic action of the toxins and ferments, their common origin in the bacterial cell, their destruction (oxidation) in the presence of light, their precipitation by alcohol, their precipitation from solutions by colloid bodies, their long and imperfect dialysis, all point to this. High temperatures affect both similarly, both being destroyed at from 60° to 100° C. (140° to 212° F.). Chemical substances that have no effect (chloroform, ether, etc.) on the ferments are without action upon the toxins; and, *vice versâ*, those that destroy the ferments (formaldehyd) are also injurious to toxins. Both may be absorbed with impunity through the intestines, although pathogenic when injected subcutaneously or intraperitoneally. When the microbe is grown in some inorganic medium, or in a non-albuminous one (as Uschinky's solution), the toxic principle obtained

corresponds in its chemical reactions to a ferment. Most important is the fact that extremely minute doses are effective. Ferments act without regard to the mass employed, and it would seem that toxins act in almost imponderable amounts. It has been estimated that $\frac{1}{1000}$ gm. of tetanus toxin will kill a horse weighing 600 kg.—six hundred million times its weight; and that $\frac{1}{1000}$ mg. of tuberculin causes a reaction in a diseased man weighing 60 kg.—sixty trillion times its weight. Finally, both act only after a definite period of incubation. Courmont and Doyon found that by increasing the amounts of tetanus toxin injected into a dog they were not able to diminish beyond a definite limit this latent period. Blood taken from the animal during the subsequent convulsions caused, when injected into another animal, an immediate tetanic attack. According to these authors, the ferment, possibly not toxic in itself, is capable of elaborating within the body or culture-medium the tetanizing substance.

Fate of Toxins.—It is certain that there exist in various cells of the animal organism certain oxidizing ferments by which the toxin is destroyed. Not all of the toxin is thus oxidized. A part is eliminated unchanged through the kidneys in the urine and to some extent through the liver in the biliary secretion. Beside these there is still another method of defence of the organism against the action of toxin—the antitoxin (*q. v.*).

Chromogenesis.—Many bacteria form colors which give to the culture a characteristic appearance. Some attempt has been made to classify those pigments according to their solubility in alcohol, ether, etc. The pigment-forming bacteria themselves are called *chromophoric* when the pigment is a component of the bacterial cell itself; *chromoparic*, when the coloring-matter is an excretion and the microbe remains colorless; and *parachromophoric* when both conditions exist. The production of the pigment depends to some extent upon the constitution of the medium, and it is possible to produce cultures and even races of pigment-forming bacteria by the use of appropriate media.

Photogenesis.—The phenomenon of phosphorescence observed in decaying fish is due to the action of bacteria. This production of light is observed in many of the cholera-group of vibriones.

THE LOCAL EFFECTS OF BACTERIA.

These may be either (*a*) mechanical or (*b*) histologic, the mechanical effects being least in importance. (*a*) Sometimes masses of micro-organisms more or less completely occlude small blood-vessels and occasion secondary changes in the tissues in this mechanical way. In other cases the obstruction is incomplete, but occasions thrombosis in the blood-vessel and various conse-

quential disorders. (*b*) The histologic changes occasioned by bacteria are *proliferative* and *destructive*, among the latter being various degenerations and necrosis. The proliferative changes may be non-specific or specific—that is, there may be simply proliferation such as occurs from any irritation; or there may be special forms of proliferation more or less characteristic in extent, distribution, and nature of the individual micro-organism. This is seen in the characteristic lesions of tuberculosis, glanders, rhinoscleroma, etc. The cellular degenerations and necroses occur coincidentally or subsequent to the proliferative changes. On the contrary, in many cases the first effects of bacterial invasion seem to be degeneration or necrosis of the tissues immediately around the organisms.

EFFECT OF TOXIC PRODUCTS OF BACTERIA.

Bacteria usually gain entrance into the animal body through some lesion of the epithelial layer, often the result of traumatism. Sometimes the microbes find in certain cavities of the body favorable conditions for growth, as in the pulmonary or alimentary tracts, and there develop and elaborate their toxins.

Intoxication and Infection.—In one class of diseases the infecting microbe remains localized at the point of inoculation, and is never or only exceptionally found in the fluids of the body, the general symptoms of the disease being due to absorption of the toxic products. Such are true *Intoxications*. In other cases the microbe is found circulating in the blood throughout the body and finds lodgement in most of the organs. These are called *Infections*. Tetanus is the type of the first class; anthrax, of the second. There is, however, no distinct line to be drawn, for the symptoms of all infections are due to the toxins and other toxic products. While some bacteria always produce pure intoxications (tetanus), most of them may, under varying conditions, cause either intoxications or infections. This difference is due to a relative lack of virulence. Either the microbe is weak in toxin-producing power or the resistance of the tissue too great. The toxin is essentially negatively chemotactic (see Inflammation), and thus prevents the phagocytic action of the leukocytes; while many other bacterial products and the bacterial proteins (Buchner) are positively chemotactic. When a pathogenic microbe is wanting in virulence, there is a determination of leukocytes to the point of inoculation and *Suppuration* results. A virulent microbe in the strict sense, then, is one that easily invades the animal body and there produces its more or less powerful toxin; an avirulent one produces but little, if any, toxin and is destroyed by phagocytosis, either with or without suppuration.

Sapremia, Septicemia, and Pyemia.—From local sup-

purative foci toxic products may be absorbed into the general circulation, and a condition known as *Sapremia* results. The infecting bacterium itself may invade the blood-current without giving rise to any secondary collection of pus. This is termed *Septicemia*. When, however, the microbe is carried to various parts of the body and there gives rise to secondary suppuration, the condition is called *Pyemia*.

The destruction of leukocytes that takes place in the formation of pus is due probably to bacterial proteins. From this point of view suppuration is not specific, and its production by various chemical substances proves this.

IMMUNITY.

Definition.—In the present state of our knowledge of the condition of immunity it is most difficult to give a precise definition of this term. It denotes that condition of an organism which enables it to resist the attacks of bacteria and their toxic secretions. In one sense it is the reverse of susceptibility. An animal that is not susceptible to an infection is said to be immune, and the term immunization is applied to the process by which an animal becomes thus refractory.

Varieties.—Immunity may exist in an animal naturally as an inheritance from immune ancestors (*Natural Immunity*). While *absolute immunity* is rare, examples of *relative immunity* are common. It may be individual or racial. Thus dogs and Algerian sheep are refractive to anthrax, while other species of sheep are extremely susceptible to this infection. The lower animals in general seem to be perfectly immune against certain diseases common to man, such as syphilis. Immunity may be produced by a previous infection (*Natural Acquired Immunity*), or by artificial means (*Artificial Acquired Immunity*). It may be the result of injections of cultures of the specific microbes, the virulence of which has been naturally or artificially reduced, as in the vaccines of variola and anthrax; or of cultures, the living organisms having been destroyed by heat or other means; or of filtered cultures, as in the production of diphtheria-serum; or of the serum of animals that have been rendered immune by these methods. In the first three cases the condition is more lasting and seems to be a permanent adaptation of the organism (*Active Immunity*), while in the last case it is but temporary (*Passive Immunity*).

In many cases immunity asserts itself against both the infecting microbe and its specific toxin, as in the rat with regard to the diphtheria-bacillus and its toxin; but more often an animal is resistant to the infection, though susceptible to the toxin. An example of this is the action of the guinea-pig toward tetanus (Vaillard). The reverse may be true, and we see an injection of

tuberculin without effect upon a healthy animal that is very susceptible to tuberculous infection. Most commonly natural immunity exists toward the infecting microbe and not its toxin.

Mechanism of Immunity.—In many cases the fluids of the animal organism prevent the growth (*inhibitory action*), or wholly destroy the bacteria (*bactericidal action*). Thus the blood of the naturally immune rat is bactericidal to the anthrax bacillus. Very many examples of this coexistence of immunity and bactericidal power of the blood can be given, and some authorities suppose this to be the general explanation of the mechanism of immunity. According to Buchner, this action is due to the presence in the blood and fluids of the body of certain albuminous bodies, which he terms *Alexins*. These are probably leukocytic in origin, and are not specific in their action, but protective toward all micro-organisms. This coexistence of bactericidal action and immunity, however, is by no means universal. Rabbits, for instance, possess a bactericidal blood-serum, but are not naturally immune to anthrax; while, on the contrary, the adult dog is immune to this disease, though its serum has no effect upon the Bacillus anthracis.

Another theory asserts that the inhibitory effect of the serum causes some change in the vital properties of the bacteria. Cultures of bacteria in the serum from immune animals seem to show some such effect, but this is probably due rather to the immunizing action of the serum in which they are suspended, as bacteria freed from this by filtration may show no such physiologic degeneration.

The theory that has influenced our ideas of immunity more than any other is that of *Phagocytosis* of Metschnikow. He holds that the destruction of the microbes in the animal body is to be explained, not by the conditions of the body-fluids, but by purely cellular activity. The infecting microbes are taken up by certain cells of the organism and are destroyed by intracellular digestion. These cells—*phagocytes*—are of two kinds: the mobile macrophages including the mononuclear and polymorphonuclear leukocytes; and the fixed macrophages, including the vascular endothelial cells, the cells of the bone-marrow and spleen, certain connective-tissue cells and liver-cells, and even those of the nerve- and muscle-tissue. After injection of a culture into the subcutaneous tissue of an animal, naturally or artificially immune, he noticed that the bacteria were all taken up by the leukocytes. That these microbes were still living and virulent, and were not taken up as mere dead matter, Metschnikow regards as fully established. One proof he cites is the fact that an exudate containing no free bacteria, but all intracellular, is capable of producing cultures on artificial media and causing infection in susceptible animals.

To these facts Pfeiffer opposes the experiment of injecting

cholera vibriones into the peritoneum of artificially immune guinea-pigs. He observed a complete destruction of the microbe by the peritoneal fluid—an agglutination into masses and a gradual degeneration. There were few, if any, leukocytes present, and he therefore claimed that such destruction was entirely extracellular and humoral in character. However, if a preliminary injection of some substance that determines a local leukocytosis is made, there occurs, instead of the reaction of Pfeiffer, a true phagocytosis. Metschnikow interprets Pfeiffer's phenomenon as the result of a dissolution of the leukocytes by bacterial action and solution in the peritoneal fluid of the destructive substances. It "is not a general phenomenon, and occurs only after intraperitoneal injections, and then only inconstantly."

Both schools now agree that the bactericidal substances are derived from the leukocytes: the one, however, holding that phagocytosis is but a secondary and infrequent phenomenon; the other, that it is the fundamental principle of immunity.

Whether or not phagocytosis is the only essential element in immunity, many points have been established by corroborative investigations. It is certain that phagocytosis does occur after subcutaneous injection; that this is much more marked in resistant and immune animals than in susceptible ones; that such intraphagocytic bacteria, at least in the early stages of the process, are still living and virulent; and that the same phenomenon takes place even in the peritoneum after a preliminary injection of a positively chemotactic substance.

As has been said, the blood-serum and fluids of animals artificially immunized are often capable of producing a passive immunity when injected into other animals. It is probable that the substances producing this are the result of the destruction of the phagocytes (*phagolysis*), either within the animal body or after the withdrawal of the serum.

Toxin-immunity; Antitoxin.—Immunity is manifested in two ways, against the microbe or against the toxin; and the substances that so act are therefore anti-infectious or antitoxic. One theory explains the condition of immunity by supposing that the cells of the body become accustomed to the poison (the old theory of Chauveau). A blood-serum, however, may be extremely anti-infectious without having any antitoxic properties, and numerous examples of this prove that the theory just mentioned cannot be a sufficient explanation.

The term antitoxin is applied to the serum of an animal that protects against a specific disease, and it is generally both antitoxic and anti-infectious. The two best known examples are the tetanus and diphtheria antitoxins, although in the laboratory antitoxic sera have been prepared for many of the infections of man and of the lower animals.

Toxin-immunity exists naturally in some individuals against certain animal poisons, such as the poisons of snakes, scorpions, etc., and chemical poisons and alkaloids, as arsenic, abrin, ricin, etc. It may also be developed by frequent exposure to such poisons. Similarly, immunity against the toxin of a bacterium is produced by the injection of gradually increasing doses of the microbe and its products. Either a culture which has been sterilized by filtration or by heat, or one containing bacteria of very low virulence, is used for the first injection. Preferably, small doses of the toxin freed from microbes by filtration are used. The doses are then increased until the animal is able to react against a small injection of the pure culture, and this is then given in increasing quantities. An animal thus treated is often able to withstand tremendously large doses of culture. Curious and at present unexplainable conditions often arise. For instance, the antitoxin may disappear from the blood of an animal thus artificially immunized without any loss of immunity, and some animals die from the disease whose blood is still extremely antitoxic, a condition, as it is called, of supersusceptibility. These few facts seem to point out that immunity cannot be due to the antitoxic action of blood-serum.

Formerly Behring explained all toxin-immunity as a histogenous immunity: that is, that the tissues of the body become accustomed to the toxin, a sort of Mithridatization. Later, however, he regarded acquired immunity, both active and passive, as an hematogenous immunity and due to the action of an antitoxin.

Antitoxin is probably a modification of the toxin by cellular action, or a substance elaborated by the cells under the stimulation of the toxin.

Electrical Production.—Some investigators have been able to produce antitoxin *in vitro* by the action of either the continuous current or the rapidly interrupted direct current on the toxin. If this is so, the fact would point toward a direct modification.

Action of the Antitoxin.—It was at first thought that the reaction between toxin and antitoxin was a purely chemical one, but probably, as in bacterial immunity, it is an indirect one. A mixture of snake-toxin and its antitoxin which has no effect when injected into an animal, if previously heated to 70° C. (158° F.), may cause the death of the animal. It is supposed that the antitoxin is destroyed at that temperature, while the toxin is not. The death of supersusceptible animals cannot be due to any lack of antitoxin, but may be explained by a want of reaction of the body-cells.

On the other hand, however, there are many experiments that seem to show the reverse; that the neutralization may take place in the test-tube, and that it is really a chemical and not a physiologic reaction.

The protective substances present in the body, normal and immune, are the defensive proteids of Hankin or the alexins of

Büchner. The former further subdivides them into sozins—those proteids present in the normal animal body, and the phylaxins—those in the body of the immune animal. The former are bactericidal and globulicidal, destroying the red and white blood-corpuscles; and are easily destroyed by light and a temperature of 55° C. (131° F.). The phylaxins, the true antitoxins, are neither bactericidal nor globulicidal, and withstand a temperature of from 70° to 80° C. (158° to 176° F.). In their other chemical reactions they are similar to the toxins.

Hankin further divides the sozins and phylaxins, according to whether they act against the microbe itself or its toxin, into myco- and toxo-sozins and myco- and toxo-phylaxins.

There is a certain amount of immunity that can be produced by the injection of substances that have an attractive power for microbes (positive chemotaxis), such as salt-solution, peptone, extracts of certain organs.

This immunity, however, is not specific, but acts toward all varieties of bacteria. It is found that even the so-called specific antitoxins are active against other kinds of toxins, as tetanus-antitoxin is partially preventive against snake-poison. It is therefore difficult to draw a distinct line between the specific and non-specific forms of antitoxin. Indeed, it is questionable if our present knowledge on the whole subject is sufficient to allow us to formulate a definite theory of immunity.

Elimination.—Antitoxin is probably eliminated through all of the secretory organs. It has been found in the urine and to a large extent in the milk. Brieger and Ehrlich obtained a quite concentrated form of antitoxin by precipitation of the casein by ammonium sulphate and purification by dialysis. As in the case of toxins, the whole of the antitoxin seems to be carried down by the precipitated colloid casein.

DISEASES DUE TO BACTERIA.

The bacterial diseases form a large and increasing group. In some cases it has been shown by the positive application of Koch's rules (see page 30) that the suspected micro-organisms are the actual causes of the diseases under consideration; in more numerous instances all of the rules cannot be applied, but other considerations go far toward establishing the specific nature of certain bacteria; in still other cases the evidence warrants a strong suspicion of the pathogenicity of bacteria found in connection with certain diseases, but there is nothing approaching actual demonstration.

Division of infectious diseases into those of certain and those of uncertain bacteriology must cause differences of opinion. It is adopted only for convenience, the merits of each individual case being considered in the discussion of the individual diseases.

DISEASES OF CERTAIN BACTERIOLOGY.

SUPPURATIVE DISEASES.

Definition.—Under this heading we include for the present various forms of suppurative inflammation, such as furunculosis, abscess-formation, and allied diseases, like osteomyelitis, endocarditis, etc.

Etiology.—A variety of organisms have been found to have the power of producing suppuration. Among these the staphylococcus group is most important. The Streptococcus pyogenes seu erysipelatis is also of great significance; less frequently the Diplococcus pneumoniæ, the Pneumobacillus of Friedländer, the Bacillus pyocyaneus, the typhoid bacillus, the Bacillus coli communis or the Bacillus pyogenes fœtidus, the gonococcus, and others. Some cases are due to a single organism; in many there is double infection.

1. The Staphylococcus Group.—Among these have been described three important forms, the Staphylococcus pyogenes aureus, albus, and citreus.

The Staphylococcus pyogenes aureus is a minute, rounded body about $\frac{5}{10}$ to 1 μ in diameter, having no motility and not forming spores. When found in the tissues the cocci are apt to be associated in clusters, whence the term staphylococcus (Fig. 79).

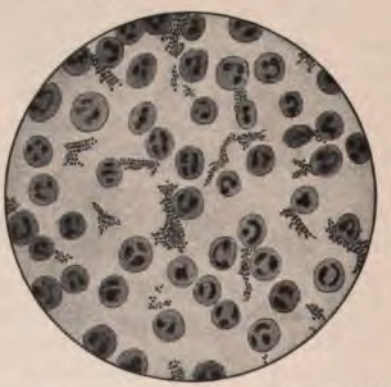

FIG. 79.—Staphylococcus pyogenes albus (Jakob).

Sometimes they are grouped in pairs, and may thus present a resemblance to gonococci. The opposed surfaces, however, are flat instead of concave, as is the case with the gonococci. The staphylococcus may be stained with ordinary anilin solutions and is beautifully demonstrated by Gram's method. Cultures are easily obtained upon the ordinary media. The most characteristic growth is that upon agar. Along the line of inoculation a moist

colony develops, with at first a whitish but soon an orange-yellow color. The growth in gelatin causes rapid liquefaction and the precipitation of orange-yellow particles. The growth is best obtained at oven-temperatures, but may be secured at lower degrees.

Distribution.—The Staphylococcus aureus is frequently found upon the skin or in the various external secretions of healthy individuals. It does not seem to flourish anywhere apart from the bodies of man or animals, but may remain in an active state in the dust of rooms or upon clothing and the like. It has been found in various lesions of the body; notably, however, in furuncles, abscesses, and carbuncles, and in ulcerative conditions of the exterior or of the mucous membranes. It is also frequent in internal suppurative inflammations, such as malignant endocarditis, osteomyelitis, appendiceal abscesses, etc. In many of these lesions other organisms may be associated.

Pathogenicity.—When pure cultures are injected into animals abscesses are produced and a fatal termination may follow. In the latter cases diffusion through the blood is found, and infarcts of the kidneys, lungs and other organs caused by bacterial emboli are discovered. Multiple abscesses may be seen. The organism readily loses its virulence, as in the case of those found, upon the skin of healthy persons, and in other accidental situations. When rubbed in a virulent state into the skin of man it produces abscesses or boils.

Staphylococcus Pyogenes Albus.—This organism is practically identical with the last-named in morphology, but in culture produces a white instead of a yellow growth. It has been found as a frequent harmless parasite of the skin (Staphylococcus epidermidis albus of Welch). It occurs in abscesses and various suppurative diseases, but rarely alone. As a rule, it is associated with the golden staphylococcus or other organisms. It is distinctly less virulent than the aureus.

Staphylococcus Pyogenes Citreus.—This form is the least important of the three. It is not so common and, as a rule, less virulent. It differs in the brilliant lemon color obtained upon culture in various media.

2. **The Streptococcus Pyogenes seu Erysipelatis.**—The Streptococcus pyogenes was first studied by Rosenbach in cases of suppuration. A similar organism was afterward described as the Streptococcus erysipelatis by Fehleisen. It would seem, however, that these two organisms are identical. At all events, there are no distinguishing features which we can point out. The streptococcus is a small spherical organism of variable size, frequently associated in chains of from three to twenty or more individuals (Fig. 80). It is easily stained with ordinary anilin solution or by Gram's method. The cocci are not motile. Spore-formation has not been observed, but occasionally in chains one of the individual

members is larger than the rest, suggesting arthrospores. Upon artificial media scanty but rather characteristic growths are obtained. On the gelatin plate there are formed small, translucent, whitish or yellowish colonies of irregular outline. The gelatin is

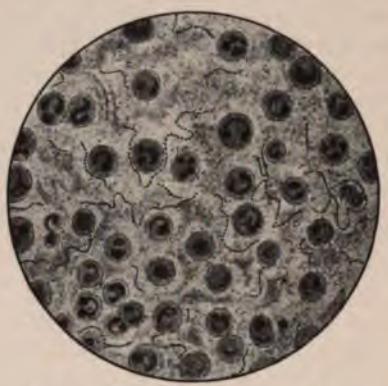

FIG. 80.—Streptococcus pyogenes (Jakob).

not liquefied. Upon agar a very thin, transparent growth forms around the line of inoculation. It consists of separate colonies which do not become confluent.

The *distribution* of the streptococcus is much the same as that of the staphylococci, though it is less commonly discovered about the healthy body. It may, however, be found upon the mucous membranes or in the various secretions or excretions of the body. It is probably a strict parasite, multiplying only within the living organism.

In disease it has been found in various forms of suppuration, such as phlegmonous forms of inflammation of the subcutaneous or submucous tissues, either alone or in association with other organisms. It occurs occasionally in focal suppurations, such as abscesses, though these are more commonly due to staphylococci alone. The streptococcus occurs at times in ulcerative endocarditis, and not rarely in infectious endometritis. Streptococcic inflammations of the throat are of great interest. They may occur in persons previously in good health, or in the course of infectious diseases, like scarlatina, measles, or influenza. To the clinician, the resulting lesion may be indistinguishable from that of diphtheria; bacteriologic examination alone serves to establish the diagnosis. The streptococcus is found in all cases of erysipelas, in the tissues, and in the serum or other exudations.

Pathogenesis.—When cultures of streptococci derived from suppurative diseases or from erysipelas are injected into rabbits erysipelatous inflammation may result. Subcutaneous injections,

however, may cause no local or general symptoms in mice or rabbits. It would seem that animals are rather resistant.

Pathologic Physiology.—When injected into the subcutaneous tissue the staphylococcus produces local effects. The organism may become liberated, gain entrance to the circulation, and produce widespread results; but it does not seem to produce toxins that cause generalized results. The effects of the staphylococcus seem to be due rather to a certain poisonous body contained in the organism itself. This has been termed the bacterial protein, and it seems to belong to the group of alkaline albuminates. This body by its chemotactic effect causes the leukocytic accumulations found in suppurative inflammations. The same body, or perhaps others, appears to have a simultaneous irritative and stimulating influence upon the fixed connective tissue of the part, leading to proliferation. The staphylococcus also leads to liquefaction in the tissues, as in gelatin, but whether directly or through the accumulation of bodies derived from leukocytes is uncertain. The defence of the organism against the staphylococcus is partly mechanical and partly vital. The leukocytes probably swallow a certain number of organisms and cause their destruction, while soluble bactericidal bodies, probably albuminous in character, seem to be produced in the course of the infection. These have been termed alexins, and are largely derivatives of the leukocytes.

The streptococcus would seem to be more active in the production of soluble toxins than the staphylococci. The *toxin* has been made by inoculating small quantities of bouillon with virulent cocci, allowing these to grow for several weeks, and then destroying the organisms by heat. The injection of the toxins thus produced leads to local and general reaction. An *antistreptococcic serum* has also been produced, and seems to possess some power to combat infection with the organism in question.

Other Organisms of Lesser Importance.

The *Bacillus pyocyaneus* is an occasional pathogenic organism found in pus having a bluish or greenish color. The bacillus is small in size, frequently occurring in chain-formation, and is actively motile.

Upon artificial media it produces colored growths and a soluble pigment, which gives to the culture-medium for some distance from the growth a greenish, or in some cases a dark-blue, coloration. The organism in pure culture is highly virulent, producing intense suppurative inflammations.

The *Bacillus pyogenes fœtidus* is probably identical with the Bacillus coli communis, or is at least a close relative. These organisms, as well as the typhoid bacillus, the Diplococcus pneumoniæ, the Diplococcus meningitidis, and the Pneumobacillus of Friedländer, are referred to elsewhere.

Micrococcus Tetragenus.—This form is a micrococcus from 1 to 2 μ in diameter, and receives its name from the peculiar association in groups of four. It occurs in the sputum and contents of cavities in pulmonary phthisis, and occasionally elsewhere. It may give rise to general sepsis.

GONORRHEA.

Definition.—Gonorrhea is an infectious inflammation of the urethral or other mucous membranes due to a specific organism, the *gonococcus* of Neisser.

Etiology.—There is no doubt that the gonococcus is the specific cause of gonorrhea. This organism is a micrococcus, usually arranged in pairs, the opposed surfaces of each being slightly concave. This arrangement has suggested the designation "biscuit-shaped" diplococcus (Fig. 81). Sometimes groups

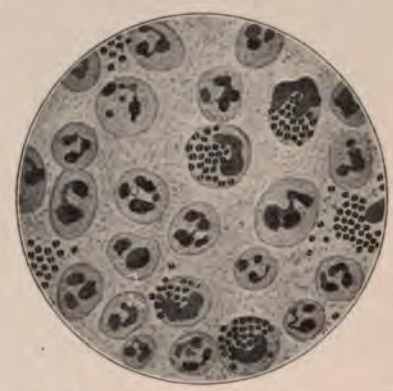

FIG. 81.—Pus from gonorrhea, showing gonococci (Jakob).

of four or more are found, while in other cases the cocci occur singly. The organisms are abundant in the pus of acute gonorrhea, less abundant in advanced stages, in the pus of gonorrheal salpingitis or other conditions, and may not be discovered at all. They generally occupy the pus-cells, lying in the protoplasm, and occasionally within the nucleus, in small numbers or so abundantly as to fill the cell uniformly. In the tissues the same intracellular position is usual, but here, as in the free pus, some organisms may generally be found between the cells. The gonococcus stains readily with ordinary solutions of anilin dyes, but is readily decolorized by Gram's method.

Cultivation of the gonococcus is difficult. Growths may, however, be obtained upon media consisting of human blood-serum and agar-agar, upon acid gelatin or albuminous urine. The growth in blood-serum consists of small colonies of grayish color that coalesce and form a film on the surface of the medium; around the colony may generally be seen an irregular and inconspicuous extension.

The gonococcus cannot be positively distinguished by its morphology nor by the intracellular position. Other organisms may in certain stages of their growth show a typical biscuit-form

(staphylococci and others); and the intracellular position is not rarely assumed by a variety of bacteria. The failure to stain by Gram's method and the failure to grow on ordinary media are strong points in favor of the gonococcus. Typical cultures alone settle the diagnosis.

Pathogenicity.—It has been demonstrated by direct implantation of pure colonies upon the healthy urethra that this organism will cause characteristic gonorrhea. Urethritis may, however, be due to other organisms; the specific form termed gonorrhea is probably always due to the gonococcus. Secondary lesions, such as salpingitis, oöphoritis, arthritis, peritonitis, conjunctivitis, endocarditis, etc., may also be due to this organism, no other form of bacteria being present. Sometimes, however, complications, such as periurethral abscesses, suppurative adenitis, etc., are due to secondary infectious.

Pathologic Anatomy.—The lesions of gonorrhea will be considered elsewhere. Suffice it to say in this place that the organism causes suppurative catarrh of the mucous surfaces with which it comes in contact. There is abundant round-cell infiltration, and the organisms tend to penetrate deeply into tissues.

Pathologic Physiology.—Gonorrhea is in most cases a purely local disease. Little is known of its power to produce soluble toxins. The distant lesions are in all cases, as far as we definitely know, dependent upon deposit of the specific organism. These have been found in the effusions of arthritis and in the vegetations of gonorrheal endocarditis, as well as in the blood in the last named condition.

CROUPOUS PNEUMONIA.

Definition.—There are a number of forms of inflammation of the pulmonary tissues to which the term pneumonia is applicable. The most definite form of disease is that spoken of as croupous, fibrinous, or lobar pneumonia. In its typical form this is a specific and well characterized disease. It is infectious, more or less contagious, and caused by a specific organism.

Etiology.—The organism most likely the cause of croupous pneumonia is the *Diplococcus pneumoniæ*. This organism is also called the pneumococcus and the pneumobacillus. In reality the last name is most applicable, but has not found general favor. The diplococcus of pneumonia was recognized in the saliva of healthy persons by Sternberg and Pasteur, but its relation to croupous pneumonia was demonstrated by Fränkel, and later by Weichselbaum. The individual organism has a somewhat elongated, lanceolate shape, and therefore deserves the name bacillus, though it does not always show this bacillary shape distinctly (Fig. 82). In the sputum and lungs, and in the blood of inocu-

lated animals, it is commonly found in pairs; the broader end of the organisms adjacent, and the pointed ends projecting outward;

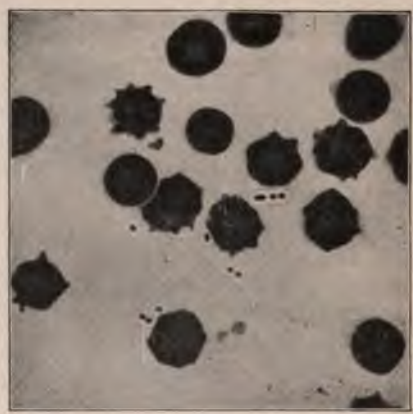

FIG. 82.—Diplococcus pneumoniæ in the blood (Fränkel and Pfeiffer).

and the group is surrounded by a transparent capsule, which does not take stains and therefore becomes conspicuous (Fig. 83). Sometimes a number of the organisms are grouped in chains, so that the name Streptococcus pneumoniæ has been suggested. The capsule is not seen when the organism is obtained from cultures. The diplococcus does not possess individual motility and has no flagella. It does not seem to produce spores.

FIG. 83.—Diplococcus pneumoniæ: *a*, cocci, without capsules; *b*, single and paired cocci, with capsules; *c*, chain-form; *d*, colony of cocci (Ziegler).

It may be readily demonstrated in the sputum or in the tissues by staining with the ordinary anilin dyes or by Gram's method.

Cultivation.—The diplococcus grows readily upon ordinary media, excepting potato. It forms characteristic colonies upon agar-agar plates or in gelatin. Upon the surface of the agar there appear transparent drop-like colonies hardly visible to the naked eye, which under the microscope have a finely granular appearance. Upon gelatin plates similar growths are produced, while in gelatin punctures the growth occurs along the path of the wire as granular whitish spots separated from each other. The organism tends to die out very readily in cultures, and also loses its pathogenic property when propagated for several generations. It is most luxuriant at 37° C. (98.6° F.).

Pathogenicity.—The specific character of this organ has not been definitely proved according to the rules of Koch, but it is

highly probable that it is the usual cause of pneumonia. The diplococcus is frequently found in the saliva of healthy persons. When this is introduced into animals, particularly rabbits, the animal dies, with evidences of rapid sepsis. The post-mortem shows some fibrinous exudate and occasionally a little pus at the point of inoculation. The spleen is enlarged, and bacteria of distinct lanceolate-form and with capsules are widespread throughout the body. Injections of lung-tissue or of pneumonic sputum produce similar results, and the organism in pure culture likewise causes this form of septicemia. It has been claimed that injection of the diplococci into the trachea will produce true pneumonia in susceptible animals. This remains to be proved more definitely.

Besides the diplococcus there are certainly other elements which contribute to the causation of the disease, else the frequent occurrence of the micro-organism in question in the saliva would make pneumonia a much more common affection. The nature of the contributing causes are, however, obscure. Exposure to cold, general depression of the system, traumatism, alcoholism, and other causes certainly predispose or help to determine the occurrence of the disease. These causes may act by temporarily increasing the virulence of the diplococcus or by lowering the resistive power.

Pathologic Anatomy.—(See Diseases of the Lungs.)

Pathologic Physiology.—The diplococcus produces, in the first place, local lesions of the lungs; and, in the second place, systemic intoxication by toxins of uncertain character. The organism itself, however, gains access to the blood and may produce secondary lesions in other organs. Infection with the diplococcus of pneumonia causes a pronounced reaction on the part of the blood in the form of leukocytosis. This is not invariable, but is usually seen. After the attack of pneumonia there is temporary immunity, and it has been claimed that animals may be immunized for considerable lengths of time. This, however, is uncertain. No definite antitoxic substance has thus far been secured.

The Diplococcus in Other Diseases.—The Diplococcus pneumoniæ has been found in various conditions complicating pneumonia, and occasionally without the existence of a previous croupous pneumonia. Among other lesions, meningitis, pleurisy, and other inflammations of the serous surfaces, abscesses, otitis media, and arthritis have been found to be due to this organism; or, at least, this organism alone has been found in some of these cases.

OTHER FORMS OF PNEUMONIA.

Among other varieties of pneumonia may be mentioned the catarrhal or lobular form, the tubercular form, and various irregular pneumonias, partly cellular, partly fibrinous, partly purulent

or hemorrhagic. A number of different organisms may be found in such cases, and some of these may be of etiologic importance in certain cases.

The Bacillus Pneumoniæ of Friedländer.—This organism was regarded at one time as the cause of croupous pneumonia. It is probably in most cases an accidental associate, though it may occasionally be the cause of catarrhal or irregular forms of pneumonia. It occurs as a distinct bacillus, usually in pairs and surrounded by a capsule like that of the diplococcus (Fig. 84). Sometimes it may form chains of three, four, or more organisms. It stains well with the anilin dyes, but is decolorized by Gram's method. A characteristic culture is obtained in gelatin. The puncture-culture is characterized by a luxuriant growth at the top and a considerable vegetation all along the track. This leads to a nail-shaped growth. The gelatin does not liquefy. Upon agar a considerable whitish or yellowish growth occurs upon the surface. There is formation of gas in media containing glucose, and often also on potato.

FIG. 84.—Bacillus pneumoniæ of Friedländer.

In *catarrhal pneumonia* this organism may be discovered, or the various forms of staphylococcus or the Streptococcus pyogenes; more rarely the influenza-bacillus, the Bacillus coli communis, the typhoid bacillus, and others are discovered. In some of these cases the disease may be the result of double infection.

Tubercular pneumonia, in which a uniform pneumonic process is found in the lungs, may be due to simple infection with the tubercle-bacillus, or to mixed infections.

Irregular pneumonias may be of varying pathologic type, and may be occasioned by a great variety of organisms. No satisfactory classification can be attempted, as the limitations of the term pneumonia can scarcely be established.

RHINOSCLEROMA.

Rhinoscleroma is a disease affecting the skin about the anterior nares and adjacent parts, and probably caused by a specific bacillus. The disease has been especially observed in central Europe. It presents itself in the form of nodular thickening of the skin of the nose and lip, and sometimes spreads to the neighboring mucous membranes—mouth, pharynx, or larynx. In the latter situations ulceration of the surface is frequent; the lesions of the skin rarely ulcerate. Histologically the growth consists of round granulation-tissue cells. Frequently the cells suffer hyaline degeneration, forming rounded hyaline bodies. The bacilli may be found between the cells and within these, especially such as pre-

sent hyaline degeneration. The micro-organism resembles the bacillus of Friedländer, but, unlike this, stains well by Gram's method, and when cultivated upon blood-serum or agar retains its capsule. In other respects the two forms are identical. Inoculation-experiments have thus far failed to produce the disease in animals.

DIPHTHERIA.

Definition.—Diphtheria is an infectious and contagious disease caused by a specific bacillus.

Etiology.—The Bacillus diphtheriæ was discovered by Klebs, and more accurately studied by Löffler, and is therefore called the Klebs-Löffler bacillus. This organism is a rod about the length of the tubercle-bacillus and twice its thickness, with somewhat swollen ends. It is readily demonstrated in the local lesions of the mucous membranes or skin, where it may be quite abundant; the individual bacilli, however, are separate from one another. The organism is peculiar in its great irregularity of shape and size, particularly in cultures (Fig. 85). Frequently one end is

FIG. 85.—Bacillus diphtheriæ from a pure culture.

especially large, giving a club-shaped appearance; some of the bacilli are very large; some present rounded granules at either end, the so-called polar granules. The bacillus is readily stained with aqueous solutions of basic stains, especially with those rendered slightly alkaline. (Löffler's stain—saturated aqueous solution of methylene-blue, 30 cc. in aqueous solution of potassium hydrate, 1 : 10,000, 100 cc.—is the favorite stain.) The stained specimen shows the morphology of the bacillus very clearly. The rounded ends generally stain more deeply than the shaft of the bacillus, so that the appearance somewhat suggests a diplococcus. Not rarely transverse fractures give the organism the appearance of disjointed segments. There are no flagella and the bacillus is not motile. Spores have not been demonstrated.

Cultivation.—The most characteristic cultures are obtained

upon blood-serum, especially such as contains a small amount of glucose. Upon this medium there is formed within six, twelve, or twenty-four hours a thin, whitish or yellowish-white layer of irregular outline, and often showing separate smaller colonies around the edge. A small portion of the colony may be removed and stained, and the diagnosis thus established with ease in a short time. Other organisms found in the throat are slower in growth, and do not therefore interfere with the diagnosis.

Pathogenicity.—When cultures in bouillon are injected beneath the skin of a guinea-pig a fibrinous inflammation with more or less widespread edema results, and the animal dies in from twenty-four to thirty-six hours. Necrotic foci in the liver and other organs are found post-mortem; the neighboring lymphatic glands are enlarged. If the animal survive, paralysis may make its appearance, as in human beings recovering from the disease.

Non-pathogenic diphtheria bacilli are found in the pharynx of healthy individuals in some cases, as well as upon the hands, hair, or other parts of the body. These may differ from the virulent bacilli in being somewhat shorter and in growing more luxuriantly. Their distinctive character, however, is their *harmlessness* when injected into animals. The term *pseudodiphtheria bacillus* is unfortunate, as it is probably the same organism, but one having lost its virulence by growth in an unfavorable situation. Moreover, the name pseudodiphtheria bacterium was formerly applied to various organisms having nothing whatever in common with the Klebs-Löffler bacillus.

Klebs-Löffler bacilli may be found in the pharynx of a person showing no indication of disease. This means that the organism has not found a favorable soil for its development or no abrasion or opening into tissues that will support its growth. The bacillus may, however, thrive and multiply for a considerable time upon the mucous membrane of such a throat, as it may upon food, clothing, or other infected materials.

Predisposing Causes.—Some predisposition is necessary for the development of the disease. In part this is personal, some individuals being highly susceptible, others scarcely at all. In part, accidental conditions, such as pharyngitis, laryngitis, abrasions, etc., furnish a favorable opportunity for the infection.

The *diphtheria of birds*, calves, and certain other animals is distinct from the human disease; and the organisms are in no way related. Human diphtheria may occur in cats, and these animals may propagate epidemics.

Distribution of the Bacilli.—The organisms are abundant in the pseudomembranes of diphtheria, but are only exceptionally found in the blood or internal organs. The visceral or nerve-lesions are due to the toxins, and not to the bacillus. The same is true of experimental diphtheria. The internal lesions may be produced

by injection of the toxin obtained by filtering a bouillon-culture through a Pasteur filter.

Pathologic Anatomy.—Diphtheria is primarily a local disease of the pharynx (pharyngeal), of the larynx (laryngeal), of the nose (nasal), or of the skin (dermal). The bacillus lodges in the mucous membrane or skin, and produces a pseudomembrane. This consists of fibrinous exudation in the form of fine granular material or a fibrillar network, in which are embedded the epithelial cells and other tissue-elements and infiltrating leukocytes. The epithelial cells rapidly undergo coagulation-necrosis or granular degeneration, as do also the connective tissues when the process extends beneath the mucosa. The blood-vessels become obstructed by thrombosis or compression, and the tissue is therefore avascular. Nearly always the pseudomembrane thus formed is attached to the underlying tissues, and when removed a raw and bleeding surface is exposed. The depth of involvement, however, varies; sometimes the submucosa is soon involved; more often the disease is practically confined to the mucosa.

The macroscopic appearance is that of a whitish, dirty-yellowish, or brownish membrane upon the mucous lining of the throat. This begins as one or several patches upon the tonsil, and spreads rapidly to the neighboring parts. In other situations the appearance is much the same. Inflammatory swelling beneath and around the diseased area is habitual. It is of great clinical importance to recognize that true diphtheria may occur in the form of typical follicular tonsillitis.

Internal or **visceral lesions** may occur in the course of diphtheria or during convalescence. They are due to the action of the toxin, and not of the bacillus. Necrotic foci in the liver, showing advanced cellular degeneration of the cells with hyperchromatosis of the nuclei, and similar lesions of other organs, may be seen in the human body, as in animals killed with the organism or its toxin. Myocarditis and myocardial degeneration, renal degeneration and nephritis, and, most interesting of all, degeneration of the peripheral nerves and neuritis, may be met with. All of these will be described elsewhere.

Pathologic Physiology.—As has been said, the disease is primarily local, and the bacilli nearly always remain localized in the superficial lesions. The general manifestations—fever, prostration, and the visceral lesions—are caused by poisonous substances elaborated by the growth of the bacilli. There are probably several substances of this sort, but one in particular—the *toxin*—is most important. This may be obtained by filtering bouillon-cultures through porcelain, and by its injection the constitutional and some of the local manifestations of the disease may be induced in animals. Successive introduction of increasing doses of toxin causes the development of antitoxic substances that

may finally accumulate in the blood to such extent that the animal becomes immune to the most virulent bacilli. The *antitoxic* substance or substances, or *antitoxin*, found in the blood and the blood-serum of immunized animals, will render other animals immune for a time, or combat and overcome the disease if already existing. Simultaneous injection of antitoxin and of many times the ordinarily fatal dose of toxin or diphtheria-cultures leaves an animal unharmed. Later, when the immunity has passed off, a small dose of toxin or culture without the antitoxin will kill the same animal. The value of the antitoxin in animal experimentation is beyond doubt. In the human being there is scarcely any doubt of its potency, though, of course, crucial experiments cannot be made.

After an attack of diphtheria there is temporary immunity, but this passes off and successive attacks may thus occur in the same person.

TYPHOID FEVER.

Definition.—Typhoid fever is an infectious disease, with characteristic lesions of the intestines, and due to a specific bacillus.

Etiology.—Certain predisposing features make individuals more liable at one time than another to this disease. It occurs in adolescence and the young, though rarely also in the old. Climatic conditions are supposed to play some part, and doubtless do have an influence. Typhoid fever is especially a disease of the temperate zones, and is most abundant in the autumn. Drainage and other conditions affecting the surroundings of persons may influence the predisposition. One attack usually confers immunity for the rest of life; exceptions, however, are met with.

The Bacillus.—The *Bacillus typhi abdominalis*, the specific organism, was discovered by Eberth and isolated by Gaffky. It is a short bacillus, from 1 to 4 μ in length and 0.5 to 0.8 μ in thickness. The ends are rounded and often somewhat plump. In culture these rods or bacilli occasionally form long chains, but in the tissues they are never so arranged. The organism is actively motile, this being due to flagella, of which there are eighteen or twenty attached to the periphery (Fig. 86). When stained with alkaline methylene-blue or other stains there are sometimes seen dark-colored spots at the ends of the organism. These were formerly regarded as spores, but are now recognized as areas of condensation. Under certain circumstances the condensation is seen in the center and vacuole-like formations are found at the ends. The organism is readily stained, but decolorizes very easily, and is therefore difficult to demonstrate in tissue. Prolonged staining, however, and rapid decolorization sometimes give beautiful results. The bacilli are, as a rule, found in clusters.

These groups may, however, be few in number, and thus difficult to detect in the organs.

Cultivation.—Artificial cultures of the bacillus have been obtained from the spleen and other organs, as well as directly from the stools and urine of patients suffering from the disease. They grow very well upon the ordinary culture-media, such as agar-agar, gelatin, and potato, the temperature of the body being most favorable,

FIG. 86.—Bacillus typhi abdominalis, from an agar-agar culture six hours old, showing the flagella stained by Löffler's method; × 1000 (Fränkel and Pfeiffer).

but some growth occurring at the ordinary temperature of the room. Upon gelatin and agar there are formed irregularly whitish films, which on close inspection with the lens show a granular appearance. This growth, however, is not distinctive. Upon acid potato a characteristic transparent pellicle is formed. This may be invisible except to the trained eye, but on scraping the surface with a platinum wire the pellicle can be raised, and on microscopic examination it is found to be composed of bacilli. Sometimes the pellicle is yellowish or brownish. When cultivated in milk there is slight acidity, but coagulation does not occur. When grown in agar containing a little glucose practically no fermentative gas results. Another feature of importance is the absence of indol-reaction, the addition of potassium nitrite and sulphuric acid to bouillon-cultures causing no rose color, such as occurs with some other organisms.

Pathogenicity.—Animal-experimentation has thus far been unsatisfactory. A few observers have succeeded in producing intestinal lesions and illness by feeding animals with typhoid cultures, particularly after the stomach and intestines have been rendered alkaline with soda and peristalsis has been checked with opium.

In most cases injection of the typhoid bacillus has produced septicemic manifestations. The constant occurrence of the germ, its absence from other conditions, and the absence of any other germ as a constant accompaniment of typhoid fever, have led to the general acceptation of this as the specific cause. Moreover, its properties are such that the spread of the disease in the acknowledged ways is entirely compatible with the acceptance of the bacillus as the specific cause.

The diagnostic features of the bacillus are plainly distinctive, except that the Bacillus coli communis has a puzzling resemblance. The latter, however, grows upon acid potato as a yellowish or brownish film, coagulates milk promptly and causes decided acid reaction, and is an active gas-producing organism when grown in glucose-agar. The serum-reaction of Widal is a recent and important distinguishing mark. The serum from typhoid patients must not, however, be relied upon absolutely, as it may contain substances produced by the Bacillus coli as well as those produced by the typhoid germ (see Widal reaction).

Distribution.—The typhoid bacillus occurs both within and without the human body, and doubtless multiplies greatly in the external world when the conditions are favorable. It occurs in the lesions of the intestines and in the intestinal contents, especially during the second and third weeks of the disease. It is usually less abundant, but often present in the spleen, liver, and kidneys; it may occur in considerable abundance in these organs when there are local complications. It also occurs in the lungs, in the parotid gland, and in other organs, and post-typhoidal abscesses may contain the organism in abundance. Complicating lesions of other organs may be dependent solely upon the specific bacillus, this being capable even of acting as a pyogenic organism, or they may be dependent upon secondary or mixed infections. The bacillus is not found in the blood in abundance, but has been demonstrated in the blood derived from the macular spots in the skin.

The typhoid bacillus is peculiarly resistant, and may thrive upon clothing, in soil, and in water for a long time. Cold has no effect, the germ being virulent after freezing and thawing several times. Carbolic acid in strengths that prove destructive to most organisms has little effect on this germ. These features explain the spread of the disease and its general prevalence. The organisms are discharged from the body of a patient suffering from the disease mainly in the stools, but in part also in the urine, sweat, and other excreta. If they are not at once destroyed, contamination of clothing, soil, water, etc. may occur, and subsequent infection of susceptible individuals takes place through drinking-water or food with which the infected water or other matters have come in contact. It is possible that infection may occasionally

take place through the lungs by inhalation of dust. This must be very rare. Intra-uterine infection undoubtedly occurs in some instances in which the mother is suffering from typhoid fever.

Pathologic Anatomy.—The lesions of typhoid fever are considered with the diseases of the intestines. It is important, however, to add in this place that widespread changes may occur in this disease as a result of the action of the bacillus, but especially of toxins. Thus there may be focal necroses in the spleen and liver, degenerative changes in the kidneys and muscles, and inflammatory changes in various glandular organs, the periosteum, the bones, or the connective tissues, the result of the direct action of the bacillus.

Sometimes typhoid infection occurs without specific lesions of the intestines, the disease in these cases presenting itself as a form of cryptogenetic sepsis. In cases of intra-uterine infection this form is habitual, intestinal lesions being exceptional.

Pathologic Physiology.—The typhoid bacillus produces by its local action toxic substances which give rise to fever and other general symptoms as well as to secondary lesions. Brieger and Fränkel claim to have separated a specific toxalbumin. Whether this be the poison or not, there is no doubt that some form of toxin is present. During the existence of the disease the system reacts in some way as yet unknown to check its progress and to bring it to a termination at the end of four weeks, and permanent immunity is usually conferred. Whether or not there are distinct antitoxic substances remains to be determined.

A reaction of importance is that studied by Gruber and perfected by Widal. These observers showed that the serum of typhoid blood in certain dilutions causes the bacillus in culture to clump or form small masses and to lose its motility. If the serum be added to the bouillon-culture, the uniform turbidity of the latter is lost and the bacilli fall to the bottom as a sediment. Under the microscope the uniform distribution of the motile bacilli is destroyed, clumps being rapidly formed and the motility of the bacilli in the clumps rapidly or gradually subsiding. This reaction was found in 2283 cases of typhoid fever reported by various writers, and was absent in 109 cases of typhoid fever. It was absent in 1365 non-typhoid cases, and present in 22 non-typhoid patients. It was therefore found in 95.5 per cent. of the typhoid cases, and was absent in 98.4 per cent. of the non-typhoid cases; or, taking the entire 3779 cases, the correct result for diagnosis was arrived at in 96.5 per cent. The reaction sometimes persists for some years after the attack of typhoid fever. Sometimes it occurs in cases in which there is typhoid infection without typhoid fever in the ordinary sense. These facts may explain some of the positive results obtained in non-typhoid cases. The serum must be diluted with nineteen parts or more of water. Reactions with

stronger serum or partial reactions may be deceptive. Whether the Widal reaction is produced by a substance connected with the infection, or by substances concerned with immunization, is not as yet determined. The latter seems more probable.

BACILLUS COLI COMMUNIS.

Synonyms.—Bacterium coli commune. A number of organisms described under different names are probably identical. Among these are Bacillus Neapolitanus of Emmerich; Bacillus pyogenes fœtidus of Passet.

Morphology.—The Bacillus coli communis is an organism almost exactly like the typhoid bacillus in appearance. It is rod-shaped, but sometimes elongated and filamentous, at other times (young forms) short and rather rounded—coccus-like. It is actively motile, and has flagella attached to the periphery of the bacillus. The flagella are less numerous than are those of Eberth's bacillus (three to ten), and the motility of the organism is less uniform and active. It may be stained by ordinary solutions of anilin dyes, particularly with alkaline or carbolized solutions. It is decolorized by Gram's staining-method. The stained bacillus shows light-colored or unstained portions like those of the typhoid bacillus. True spores have not been detected.

Cultivation.—The organism grows luxuriantly upon ordinary media. The most distinctive growth is obtained upon acid potato. An elevated brownish colony is produced, which is usually easily distinguished from the typhoid culture in the same medium. When cultivated in gelatin or agar containing glucose active gas-production results. In liquid media (bouillon) a peculiar odor is developed. Addition of nitrites and pure hydrochloric or sulphuric acid causes a rose-red color—indol-reaction.

Distribution and Pathogenicity.—The coli bacillus is a normal inhabitant of the gastro-intestinal tract. In certain inflammatory diseases of the intestines, however, it seems to increase in numbers and doubtless also in virulence. The organism may be found outside the body in various situations, particularly in water.

The bacillus coli is capable of producing inflammatory conditions in different situations. Injected into the peritoneal cavity of animals it gives rise to acute fibrinopurulent peritonitis, and in other parts of the body has analogous effects.

It has been found in various diseases of the gastro-intestinal tract, of the biliary passages, of the urinary system, and of other parts, and is doubtless the direct cause of some of these, as the conditions present are practically the same as those produced by experimental inoculation of pure cultures.

Among the gastro-intestinal troubles it has been found in suspicious abundance in various forms of enteritis, in the distended

and suppurating appendix, and even in Asiatic cholera. It is known that the strangulation of a knuckle of intestine by a ligature leads to rapid increase of virulence of the contained bacilli. It is possible that in appendicitis and in other intestinal diseases similar conditions lead to increased infectivity, and thus cause an ordinarily harmless organism to become virulent. In the cases of Asiatic cholera in which this organism has been found the specific germ of cholera has probably been overlooked or has disappeared during the rapid multiplication of the saprophytic Bacillus coli.

Peritonitis may result from escape of the bacillus through a ruptured intestine or directly through the wall of the bowel. The latter is particularly prone to occur in cases of strangulation of the intestines.

Various inflammatory diseases of the urinary tract, such as cystitis, pyelitis, and pyelonephritis, seem to be occasioned by this same germ.

Finally, there are cases of peritonitis secondary to enteritis, pleurisy, endocarditis, and other inflammatory diseases, apparently caused by this organism.

Pathologic Physiology.—Little is known of the toxic effects of coli-infection. There is doubtless some toxic substance produced. A reaction similar to the Widal reaction obtained with the typhoid germ has been found to occur when cultures of the coli bacillus are subjected to the action of serum from an animal inoculated with this organism or from a person suffering with appendicitis or other diseases, either due to coli-infection or accompanied by such. Occasionally the coli bacilli agglutinate and their motility is checked by typhoid serum. The explanation of this may be that in certain cases of typhoid fever the coli bacillus is also active in the intestines, and in consequence a mixed form of infection is present.

CHOLERA.

Definition.—Cholera is an acute infectious and contagious disease caused by a spirillum or vibrio.

Etiology.—The specific cause of cholera is the Spirillum or Vibrio choleræ Asiaticæ. This organism is frequently spoken of as the comma-bacillus of Koch. It is a short rod, from 0.8 to 2 μ in length, and usually somewhat curved. The term comma-bacillus is applied to it on account of the latter fact. It is found abundantly in the rice-water discharges of choleraic patients, and is not rarely arranged in rows, though the vibriones are not actually attached to one another (Fig. 87). It is motile, the motility being due to a single flagellum attached at one end. In artificial cultures the organisms are actually joined to form spirals of greater or less length, and these may present a rapid rotary movement.

The demonstration of the cholera-spirillum is usually easy, as ordinary stains color it intensely. Even the flagellum may be



FIG. 87.—Spirillum of Asiatic cholera, from a bouillon-culture three weeks old, showing numbers of long spirals; × 1000 (Frankel and Pfeiffer).

stained by the ordinary stains, though more definitely shown by special methods.

Cultivation.—The cultivation of the spirillum is usually easy. Cultures may be obtained upon agar-agar, blood-serum, or other media, but the gelatin-culture is most characteristic. In puncture-cultures the growth occurs along the entire length of the puncture, but particularly at the top, where the supply of oxygen is abundant; and the gelatin becomes liquefied. This give rise to a peculiar nail-shaped or funnel-shaped formation (Fig. 88). In plate-cultures the growths first appear in the lower strata of the gelatin as small granular whitish spots which extend toward the surface, liquefy the gelatin, and thus produce excavations. The appearance to the naked eye suggests small air-bubbles in the media. Under low powers of the microscope the culture is seen to be coarsely granular, the size of the granules varying with the age of the culture. The bottom of the growth presents an appearance like that of a surface sprinkled with powdered glass.

FIG. 88.—Puncture-culture in gelatin of spirillum of cholera; sixty hours old (Shakespeare).

When grown in bouillon or other liquid media the cholera-microbe produces nitrites and indol, so that the addition of a little pure sulphuric acid or hydrochloric

acid leads to a reddish coloration. This may be extracted with chloroform or benzol, and "cholera-red" may be thus obtained.

The cultures of cholera grow best at a temperature about that of the body, but they may thrive at much lower degrees of heat. Exposure to a temperature of 52° C. (125.6° F.) for four minutes may cause their destruction, but ten or fifteen minutes' exposure at 55° C. (131° F.) does not always prove destructive. They may thrive in distilled water, or in water containing saline matter; in or upon various forms of food; upon clothing and the like. The resistance, however, is not very great, and this has been urged as an objection to the likelihood of the organism being the cause of a disease having such evident tenacity.

Pathogenicity.—The pathogenicity of the cholera-spirillum is now admitted universally. Injected into the peritoneum of animals it causes a rapid fall of temperature, abdominal tenderness, and collapse. The peritoneum shows signs of beginning inflammation, and the organisms are found in abundance within the cavity. It has been possible also to produce intestinal changes almost, if not, identical with those of human cholera in animals by arresting the peristalsis of the intestines with injections of opium, rendering the liquids of the stomach alkaline with sodium carbonate, and then feeding cultures. In man a few auto-infections have been practised, the experimenter swallowing cholera-cultures. In one case at least typical cholera was admitted by Pettenkofer, the most important opponent of the acceptance of this germ as the specific cause.

Other Causes Operating in Cholera.—Certain climatic conditions favor the development of the disease. Thus it is constant in certain regions of India, and spreads thence when the conditions become favorable. The evidence shows that the germ is carried by individuals, or by infected food and the like. The disease flourishes in warm seasons of the year, and an epidemic is usually brought to a close by winter frosts.

Individual disposition plays a part in the occurrence of the disease, for the germ is easily destroyed by the acid gastric secretions, and infection is therefore most likely to occur when gastro-intestinal derangements furnish a favorable predisposition.

Pathologic Anatomy.—The lesions of this disease are found in the intestinal tract, and will be described in the appropriate section.

Secondary lesions of other organs are met with in severer cases, and result from the circulation of toxic substances produced by the bacillus.

Pathologic Physiology.—A number of toxins have been isolated from the blood of cholera-patients and from cultures. The exact nature of these and the relations of the several forms remain to be determined. It is certain, however, that toxins pro-

duced in the intestinal tract give rise to many of the symptoms of the disease. The human or animal organism in some way develops immunizing or protective substances in the course of infection, and it has been found possible by a process of vaccination with cultures of gradually increasing virulence to protect animals and human beings from the disease. Pfeiffer found that the serum of animals so vaccinated had a distinct action upon cholera-spirilla, causing their agglutination or destruction, and probably in this way exercising a protective influence. This, or a similar, reaction has now been perfected in the case of typhoid bacilli, and forms the basis of the well-known Widal test. The same test is applicable to Asiatic cholera. The rapid and copious intestinal discharges of cholera lead to considerable inspissation of the blood, and doubtless contribute to the causing of some of the symptoms of the disease. Examination of the blood during the height of the malady may show greatly increased numbers of red blood-corpuscles.

Organisms Resembling the Cholera-vibrio.

Spirillum of Finkler and Prior.—This organism was discovered by the investigators, whose names it bears, in the stools of a case of cholera nostras. It resembles the vibrio of Asiatic cholera in its shape and somewhat in its manner of growth and its production of the indol-reaction. It differs, however, in being somewhat longer and more slender and in coagulating milk when this is used as the culture-medium. The growth upon gelatin is more rapid, so that within twenty-four hours in the case of a puncture-culture the liquefaction has proceeded so far all along the puncture that an elongated sac-like excavation is formed, in which turbid liquid is contained. It has not yet been proved positively whether or not this organism has an etiologic relation to cholera nostras.

Spirillum Tyrogenicum.—This is an organism discovered in old cheese by Denecke. It resembles the last-named variety very closely, and differs from the vibrio of cholera in liquefying gelatin quickly, though the rapidity is not so great as in the case of the Finkler and Prior organism.

Spirillum Metschnikowi.—This organism was discovered by Gamaleia in the intestines of chickens affected with choleriform disease. It is somewhat shorter and thicker than the cholera-spirillum. In culture it resembles the vibrio of cholera very closely, though the trained bacteriologist can easily distinguish them. The organism is non-pathogenic for man, but chickens, pigeons, and guinea-pigs are highly susceptible.

Besides these spirilla or vibriones which have been discovered in various diseases, a number of organisms that resemble closely the spirillum of cholera have been found in the water of streams supplying the drinking-water of cities. Among these Neisser

described the Spirillum Berolinensis, obtained from the water of the Spree in 1893. Dunbar and Oergel isolated a similar organism from the water of the Elbe, and a number of others of like character are known. The relations, however, of the different forms to each other and the differentiation of these varieties have not as yet been definitely determined.

Pathogenicity.—Some of the forms described produce violent gastro-intestinal disturbance and death in a certain proportion of animals prepared by injection of opium and alkalinization of the intestinal tract with soda and then fed with pure cultures of the organisms. They are evidently highly irritating bacteria, and some remote relationship seems to exist between them. This, however, cannot be positively asserted.

TUBERCULOSIS.

Definition.—The term tuberculosis refers to various conditions due to infection with the tubercle-bacillus, no matter what the form or individual peculiarities of the case. The name was originally employed because of the occurrence of small nodules or "tubercles." It must be remembered, however, that other diseases show small miliary nodules, perhaps indistinguishable to the naked eye from miliary tubercles, and that tuberculosis sometimes occurs without a single tubercle.

Etiology.—Tuberculosis is infectious and contagious, the bacilli being transferred by the secretions and excretions from diseased persons to a susceptible individual through the air, food, drink, or in other ways. The infectious character of the disease was long suspected, but was definitely proved by Villemin in 1865, and in 1880 Koch succeeded in isolating the infective bacillus. Predisposing causes are of some importance. Formerly family susceptibility was thought an all-important cause, and the disease was supposed to be transmitted directly in families. At the present time we recognize the transmission of susceptibility, and very rarely transmission of the disease itself, from parent to child. Susceptible persons frequently show delicate organization with poor development of the body, particularly of the chest. Besides inherited susceptibility, acquired predisposition may result from occupations which lower vitality, from grief, prolonged nervous strain and exhaustion; and some one of the organs may be specially predisposed by injuries, as in cases of tuberculosis occurring in the lungs of those inhaling sharp particles of metal, coal, and the like. Such mechanical lesions prepare a place of lesser resistance, and tubercle-bacilli more easily gain a footing than in normal tissues.

The *tubercle-bacillus* is a rod-shaped organism about 1.5 to 3.5 μ in length and from 0.2 to 0.5 μ in breadth. It often occurs in

pairs or in groups, arranged end to end, but not rarely overlapping somewhat, and evidently not closely attached one to the other. A beaded appearance is caused by the alternation of portions well stained and intervening parts with little or no stain (Fig.

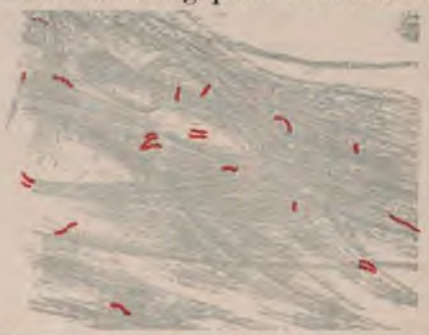

FIG. 89.—Tubercle-bacilli in the sputum; Zeiss's homog. immersion $\frac{1}{12}$, Oc. 4; magnified about 1000 diam.

89). These light areas were formerly regarded as spores (Koch), but are now believed to be the result of fragmentation of the bacillus and retraction of the substance of the organism, causing vacant areas. In other words, they are phenomena of degeneration. They are almost certainly not spores. The tubercle-bacillus is not motile and does not have flagella. It is therefore transported by outside agencies entirely.

Artificial culture of the Bacillus tuberculosis was first successfully accomplished by the use of blood-serum as a medium. The bacillus grows very slowly; after ten days or two weeks the surface of the medium shows dry flakish deposits, somewhat resembling the scales in certain skin-diseases (Fig. 90). The edges of these flakes tend to elevate themselves a little, and the substance of the growth has a crumbled appearance. Placed under a cover-glass in mass and examined with the microscope these flakes are found to be composed of contorted masses of bacilli (Fig. 91). Pure cultures are best obtained from the lymphatic glands of animals artificially infected and destroyed before the tuberculous foci have advanced to the stage of necrotic change. Cultures may be obtained with some difficulty from the sputum or other excreta. At the present time blood-serum is less frequently used, as it has been found that agar-agar slightly acidulated and containing a large proportion of glycerin, and bouillon containing glycerin, serve as useful media. Even potato and other simple substances are found to be satisfactory media. The bacillus requires a rather even temperature for its growth; it flourishes best at 37.5° C. (99.5° F.), and does not grow below 29° C. (84° F.), or above 42° C. (107.6° F.). Exposure to higher temperatures (75° C.) (167° F.) rapidly destroys it; and strong sunlight is destructive.

It requires considerable air and always grows upon the surface of the medium in which it is cultivated. Prolonged cultivation upon artificial media lessens its virulence.

Demonstration.—The demonstration of the tubercle-bacillus by staining-methods is extremely easy and satisfactory. It has been found that this organism, like that of lepra and the smegma-bacillus, does not readily stain, but after receiving a stain retains it despite the action of strong mineral acids. Upon this principle the methods of staining are based. Koch used as a stain a gentian-violet solution containing anilin-oil, the latter playing the part of a mordant or an agent to fix the stain in resistant bacilli. The specimen was then

FIG. 90.—Culture of tubercle-bacilli on glycerin-agar, four weeks old (Fränkel and Pfeiffer).

FIG. 91.—Bacillus tuberculosis; adhesive cover-glass preparation from a fourteen-day-old blood-serum culture: × 100 (Fränkel and Pfeiffer).

decolorized by treating it with a solution of a mineral acid, which removes the stain from everything but the tubercle-bacillus. A counter-stain might then be used to render the detection of the bacilli more easy.

The most convenient method is the following: sputum is spread in a film upon thin cover-glasses or slides. These are allowed to dry in air and then thoroughly fixed by drawing the specimen through a Bunsen flame three times; a drop or two of Ziehl's solution of carbol-fuchsin (see p. 187) are added and heated until the liquid steams. After two or three minutes the stain is washed off with water and a few drops of Gabbett's solution (methylene-blue, 2; sulphuric acid, 25; water, 75) placed upon it

and allowed to remain a minute or two. The specimen is again washed with water, and should then be uniformly blue; if not, a little more Gabbett's solution is added as before. In this method the carbol-fuchsin stains everything, including the tubercle-bacillus; the sulphuric acid of the second solution decolorizes everything but the tubercle-bacillus; and the methylene-blue at once stains the cells and other elements, leaving the bacilli dark red. Even more satisfactory results may be obtained by allowing the carbol-fuchsin to stain at ordinary temperatures for twelve hours; and in the staining of bacilli in tissues this prolonged cold staining is particularly desirable. Gram's method gives positive results.

Distribution of the Tubercle-bacillus.—This organism is probably a pure parasite, occurring and multiplying only in the body or excreta of diseased individuals, human or animal. Sputa or other excreta containing the bacillus may dry and retain the bacillus in a dormant though still potential form for long periods of time, outside the body. Multiplication of the organism, however, probably very rarely occurs, except within the body. The bacillus is found in the lesions of all parts of the body.

Modes of Infection.—The bacillus may gain access to the body either by direct inoculation, by the inhalation or swallowing of the germs, or by intra-uterine transference through the placenta. Direct inoculation through external wounds is perhaps more frequent than is believed. Definite lesions of the skin have been caused by vaccination, and are not infrequent upon the hands of anatomists, in the form of the so-called anatomic tubercles. In some of the cases of scrofulous or tuberculous glands of the neck in children, it is likely that the bacillus gains entrance through abrasions of the skin or of the mucous membrane of the mouth or pharynx. Genital tuberculosis is quite possibly frequently produced by direct implantation. The most common form of infection is through the inspired air. The breath of phthisical patients does not ordinarily contain bacilli, but the dust of rooms in which tuberculous patients have lived may contain numerous bacilli in a dry state, and these readily become mixed with the air and are thus inhaled. Tuberculosis of the lungs, or more rarely of other parts of the respiratory tract, is thus produced in susceptible persons. The swallowing of tuberculous material may lead to tuberculosis of any part of the gastro-intestinal tract by the direct inoculation that results. Thus intestinal tuberculosis in particular is produced. Sometimes, however, the bacilli pass through the wall of the intestine and cause a primary lesion in the lymphatic glands of the abdomen. The bacilli are swallowed with milk or meat, or they may gain access to the mouth, in the form of dust or particles of various kinds, and be swallowed with the saliva. The milk and meat of infected cattle frequently contain bacilli, and undoubted instances of infection in this way have

been proved. The intra-uterine transmission of tuberculosis is rare, but does occur. Most of the cases, however, of tuberculosis in early life may be explained as post-natal infections through milk, inspired air, etc.

Relations of Human to Animal Tuberculosis.—The lower animals are liable to tuberculosis in varying degrees. The disease is very common among cattle and less frequent in hogs, goats, horses, dogs, cats, sheep, rats, guinea-pigs, and rabbits. Animals become more susceptible when kept in confinement. Captive monkeys are particularly liable. Birds and fowl of various kinds are susceptible, though the disease is somewhat different in them from that seen in man.

Animals may become infected from man, and may further spread the infection by their discharges or excretions. In the case of cattle the danger of dissemination is particularly great, as tainted milk is liable to produce intestinal tuberculosis, and meat if insufficiently cooked may similarly cause infection.

Pathologic Anatomy.—Tuberculosis is characterized by the eruption of small nodules varying in size from one or two millimeters in diameter to that of a small pea. These are known as *miliary tubercles.* As already mentioned, the latter in gross appearance are not distinctive of tuberculosis, as similar nodules are met with in other diseases. Besides the tubercle there are *inflammatory lesions* occurring between the tubercles and varying with the anatomic character of the organs affected. Thus in the lungs the tubercle may be inconspicuous, whereas the pneumonic infiltration of the lung-tissue surrounding the tubercles and filling in the spaces between them gives the organ its most striking anatomic characters. There are instances of tuberculosis in which the whole process runs its course without the development of any definite tubercles. For example, in the lungs the inhalation of tubercle-bacilli in considerable number may be followed by rapid tuberculous pneumonia without definite tubercles, and in other situations similar results may be produced. In the further progress of a case of tuberculosis *caseous change* is important. This may present itself in the form of areas of considerable size having a dull, opaque, lusterless, grayish or whitish character, and not inaptly likened to the appearance of cheese. These centers of caseous necrosis may finally become liquefied, and cavity-formations may result. These changes are particularly frequent in tuberculosis of the lungs, less frequent in bones, skin, glands, kidneys. In connection with tuberculosis of bones there may be formed small or large cavities filled with liquefied caseous or puriform material. These may involve the surrounding tissues as well as the bones themselves. The term cold abscess is applied to them. Small tubercular areas and sometimes even large foci are prone to be surrounded by reactive fibrous-tissue

hyperplasia, and thus a complete encapsulation may result. Small foci may be uniformly transformed by organization of proliferating connective tissue and may be thus entirely healed. In other cases simple encapsulation occurs, the tuberculous mass within perhaps undergoing calcification. These changes will be more particularly referred to below.

Tuberculous lesions of the mucous membranes frequently begin with the formation of distinct tubercles occupying the deeper layers of the mucosa or the submucosa. These by confluence may form considerable areas of tuberculous disease, while at the same time reactive inflammation of the surrounding tissues adds to the mass. Sooner or later ulcerative changes upon the surface make their appearance and irregular, more or less necrotic, ulcers result. The caseous appearance of these and the occurrence of distinct tubercles in the edges or base manifest the character of the process.

Structure and Evolution of the Tubercle.—When the tubercle-bacillus is received into any tissue or organ its first effect, according to the investigations of Baumgarten, is to stimulate or irritate the fixed connective-tissue elements and cause a proliferation of round cells, which resemble in their abundance of protoplasm the epithelial cells, and are therefore known as epithelioid cells. These

FIG. 92.—Miliary tubercles in the liver, showing abundant round cells in the peripheral parts, epithelioid and giant-cells within.

have usually a single nucleus, of rather clear vesicular appearance, not deeply staining, and a relatively large amount of protoplasm. They may be produced in greater or less abundance, as the first reactive change of the tissues to the irritation of tubercle-bacilli. Next there follows an infiltration with leukocytes from

the surrounding blood-vessels, and the focus of irritation thus becomes surrounded with numerous small round cells mostly mononuclear, with darkly staining nucleus and a small protoplasmic body (Fig. 92). Some of the cells are polynuclear. This leukocytic infiltration represents the reaction of the vascular system to the tubercular irritation or infection. The number of small round cells varies greatly in different instances. Sometimes, as in certain tubercles of lymphatic glands, they may be relatively few, while the epithelioid cells are present in abundance. In other cases the leukocytes are so quickly attracted and in such numbers that the tubercle seems composed of these cells alone, no epithelioid cells appearing in view. These tubercles are known as the lymphoid. In the later stages the round cells may disappear by degeneration, exposing the previously hidden epithelioid cells to view.

At the stage of the tubercle when it is composed mainly of epithelioid and lymphoid cells it appears to the naked eye as a grayish, somewhat translucent pearly body. It is avascular, no tendency toward formation of new blood-vessels being apparent. In the further evolution of the lesion degenerative changes take place. These are coagulation-necrosis, fatty change, and eventually a transformation into cheesy material, the so-called caseous necrosis. These changes result from the specific action of the living tubercle-bacillus, though in part also from the avascular condition of the tissue. Avascularity alone, however, is not the cause of caseous necrosis. One of the first changes noted is a granular change in the cell-protoplasm which lessens the affinity of the cell-protoplasm and of the nucleus for ordinary stains. There may be seen among the cells of the tubercle here and there individuals which show this beginning necrosis. These are usually grouped in the center of the tubercle, though at times also at different points. The outlines of these cells become less distinct and they are progressively less deeply stained, until with advanced necrosis the cell is broken down into particles or débris (Fig. 93). In the early stages of necrosis the epithelioid cells tend to run together, forming large, irregular *giant-cells* with many nuclei arranged either around the periphery or frequently at either pole of the cell. Some observers believe that giant-cells result from rapid multiplication of nuclei within the epithelioid cells. This is very rare. Others have supposed that the running together of leukocytes or lymphoid elements of the tubercle causes the formation of giant-cells. This does not seem ever to occur. The giant-cell is not characteristic of tuberculosis, as it may be found in many of the specific inflammations and also in foci of chronic irritation due to foreign bodies, as well as in tumors. In no condition, however, are they so abundant or so conspicuous as in tuberculosis. In some cases they may not be seen in the tubercles

at any stage. In other cases they are very numerous. The giant-cell falls an early victim to the advancing necrosis, and the protoplasm becomes granular and opaque, and eventually breaks down completely. This change usually occurs at the opposite side of the cell from that in which the nuclei are gathered; or in cases in which the nuclei surround the cell the necrotic changes begin in the center. Finally, a tubercle undergoes almost complete necrosis and is transformed into a cheesy mass, the surrounding connective tissue perhaps still showing proliferative changes which may

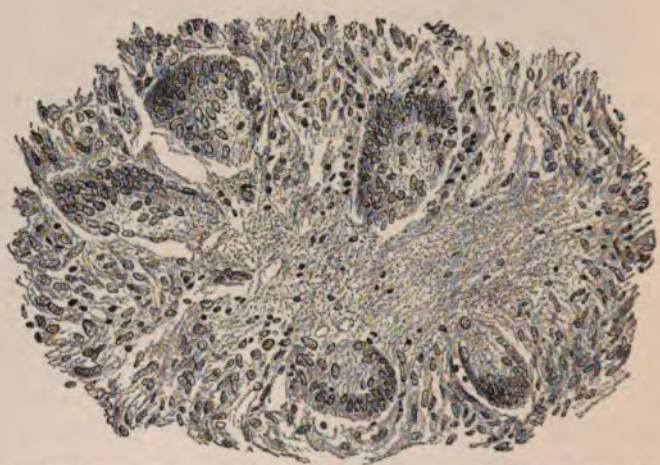

FIG. 93.—Large tubercle of the lung, showing cheesy necrosis in the center: the epithelioid and giant-cells around the cheesy center are more or less degenerated.

eventually cause encapsulation of the tubercle. Calcification may ensue in the cheesy mass and thus lead to permanent destruction of the nodule.

In the growth of tuberculosis the normal tissue-elements of the part affected are pushed aside, or may be softened and destroyed by the disease-processes. The connective-tissue fibers of the part, however, are longest retained, and remain as a reticulum or tubercle-stroma long after the other elements of the tissue have disappeared or been pushed aside.

Tubercles tend to coalesce, forming larger tubercular masses, and sometimes distinct tuberculous tumors are so produced. In the lower animals, particularly in cattle, such tubercular tumors of the serous surfaces are not uncommon. They may simply stud the membranes, or they may hang as polypoid masses; the term "pearl disease" is applied to these cases. Somewhat similar tubercular tumors are met with in human tuberculosis, especially in the brain. As a rule, however, increasing areas of tuberculous disease of organs are only partly composed of tubercles, the bulk

of the diseased area presenting evidences of ordinary or peculiar inflammatory changes to which the presence of the tubercles has stimulated the tissues.

The tubercle-bacilli in the earliest stages of the tubercle may be seen lying in the tissue and perhaps between the epithelioid cells first formed. With the evolution of the disease they are more and more abundant, are largely within the cells, and the giant-cells in particular may contain large numbers (Fig. 94). As

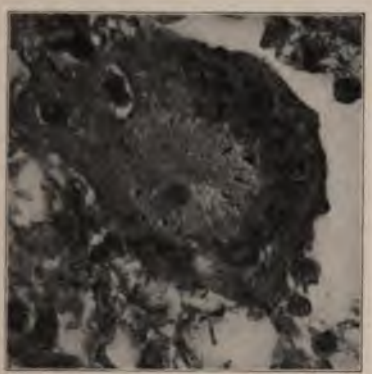

FIG. 94.—Giant-cell containing bacilli (from a photograph made by Dr. Wm. M. Gray).

the necrotic changes increase the bacilli become less conspicuous, and eventually none may be visible. The existence of the bacilli or their spores, however, cannot be doubted, since injection of portions of such tubercles produces the disease in guinea-pigs.

After the establishment of the local lesion of tuberculosis in any part of the body two opposing tendencies struggle for supremacy, the tendency of the tuberculous disease to spread and the tendency of the normal tissues to encapsulate or limit the spread of the invading disease. In most cases the former succeeds and the secondary tubercles first appear in adjacent parts, the transportation of the bacilli from the primary to the secondary focus being accomplished either by the flow of the lymph or juices of the body, or by the phagocytic activity of leukocytes. The latter take from the edges of the tubercle some of the bacilli and transport them either by their own ameboid activities or in the lymph-stream to neighboring parts, where they themselves fall victims to the organisms they have appropriated, and thus deposit the germs of new foci of disease. The dissemination of tubercles to more distant parts may occur in various ways. In the case of tuberculosis of the mucous membranes bacilli may be cast off from the surface and spread to other parts of the mucous tracts with the contents of these, as in the case of tuberculosis of the gastro-intestinal tract. In the case of pulmonary lesions the ulcerative processes,

or attacks of coughing, may loosen infected particles from lesions of the bronchi, and the deep inspiratory efforts following the cough, or the ordinary inspirations, may carry the bacilli into the finer bronchioles, where new foci arise. If the tubercular lesion involves the walls of the lymphatics, particularly the larger lymph-channels, like the cervical or thoracic ducts, bacilli may gain access to the lymph-stream and thus be transported to the venous circulation, and then through the heart to the lungs or perhaps to other organs. When the tuberculous lesion invades the wall of a vein the dissemination of the bacilli is even more rapid and widespread, as the organisms find their way to the heart by a more direct route. In rare instances an artery is invaded and the organisms are scattered through the terminal distribution of this. Upon surfaces the disease may spread by direct continuity or by the movements of the body. Thus lesions of the peritoneum may become almost universal in consequence of the peristaltic movements, though more frequently the extension occurs along the lymphatic channels.

The condition which results from general infection and formation of tubercles in various situations is known as *miliary tuberculosis.* In these cases the progress is usually rapid and a fatal termination is not long delayed. The tubercles therefore remain small, and at autopsy are still typically gray miliary tubercles. Sometimes, however, miliary tuberculosis may assume a more chronic form, perhaps in consequence of the gradual admission of bacilli to the circulation and the formation of small crops of tubercles during a considerable period of time.

Miliary tuberculosis may be local or general. In the former case the bacilli are admitted to the vascular distribution of a restricted area only; in the latter widespread dissemination through the blood occurs, and practically all parts of the body may be involved. Localized miliary tuberculosis is most frequent in the lungs.

Seats of Tuberculosis.—Among the frequent situations in which tuberculosis makes its appearance are the lungs, the lymphatic glands, the bones and joints, the mucous membranes, particularly those of the larynx and intestines, the serous membranes, the prostate, testicle, ovaries, Fallopian tubes, kidneys, uterus, suprarenal capsules, brain, liver, spleen. In some of these situations the lesions are practically always secondary, as, for example, in the liver and spleen. In others they are most frequently primary, as in the lungs. The occurrence of primary tuberculosis in the internal organs may be difficult to explain. It is possible, however, for the bacilli to gain access to the lymphatic or blood-circulation without causing a lesion at the point of entrance. Their deposit in some internal organ then occasions the first or primary focus of disease. Thus primary tuberculosis of the mesenteric

glands, of the lymphatic glands of the neck, or of the post-bronchial glands, may occur without primary disease of the intestines, of the mouth or skin, or of the lungs in the several instances. Similarly primary tuberculosis of the kidney or of the suprarenal capsule may occur without any evidence of the point of entrance of the micro-organisms. In some cases, of course, the primary lesion may be so small and in such a hidden situation that it escapes notice.

After the discovery of the tubercle-bacillus a number of diseases not previously recognized as tuberculous became identified as forms of this disease. Among these is *Lupus Vulgaris* of the skin. The histologic examination shows numerous tuberculous granulations, sometimes arranged in striate fashion along the small blood-vessels of the skin and containing epithelioid and lymphoid cells and giant-cells. The presence of the bacilli and the proved infectiousness of the tissue, with the histology, render the nature of this disease certain. The warty formations frequently acquired by anatomists at points of injury have likewise been shown to be in many cases due to tuberculous infection. *Scrofula*, which was formerly regarded as a special condition predisposing strongly to tuberculosis, is now regarded as tuberculosis occurring in different forms and situations. The scrofulous glands of the neck constitute tuberculous adenitis, the infection in many cases gaining access through the mucous membranes of the mouth and pharynx or through the skin. Scrofulous rhinitis and sinuses have similarly been shown to be forms of tuberculous disease. Many cases of joint-disease regarded as scrofulous or otherwise are dependent upon the action of the tubercle-bacillus.

Latent Tuberculosis.—A tuberculous lesion may become encapsulated and limited in its extent before it has invaded tissues widely, and may so remain for years without giving rise to manifest clinical symptoms. Subsequently, however, the encapsulating membrane may be penetrated and widespread infection, local or general, may occur. Such latent tuberculosis is particularly frequent in the post-bronchial glands. These glands are often found enlarged at autopsies in which no tuberculous disease of other organs is found. Injections of emulsions of such glands in a notable proportion of cases produce tuberculosis in guinea-pigs, and thus it has been determined that the glands in question are frequently the seat of latent tuberculous disease. The existence of such lesions explains the cases of sudden generalized miliary tuberculosis, in which no primary focus of the disease was recognized during life.

Pathologic Physiology.—The effect of tuberculosis upon the general health varies greatly. Undoubtedly the bacillus is capable of producing toxins that have an effect upon the general organism; the nature of these, however, still remains undeter-

mined. The tuberculin of Koch, a glycerin-extract from cultures of the tubercle-bacillus, produces fever with general symptoms such as are frequently associated with pyrexia and local reactive changes in existing tuberculous lesions. Among the latter redness or increased vascularization of the tubercles, and softening or necrosis of the cells surrounding the bacilli, are most important. The last-named change deters the growth and multiplication of the bacilli themselves, but at the same times makes their escape from the focus of disease more easy and thus exposes the individual to the liability of general infection. The active substance contained in tuberculin is probably an albuminous body. It does not act upon the tubercle-bacillus directly and is not an antitoxin. In addition to this the tubercle-bacillus in its dead state contains some body or bodies capable of influencing the organism, as was shown by the experiments of Prudden and Hodenpyl, who were able to produce nodular lesions and small local abscesses by injecting dead bacilli into the circulation of animals. These lesions, of course, are not strictly tuberculous, though they possess some elements of the natural tubercle. It is altogether probable, however, that in addition to the tuberculin of Koch and the chemotactic substances contained in the body of the tubercle-bacilli, there are other poisonous substances produced by the growth and multiplication of the bacilli in the tissues, that lead to a general deterioration in the health of victims of this disease.

Tuberculosis is primarily a local process, but influences the general organism by its direct effect upon the organic functions of the parts in which it is located by the development of these as yet unknown toxic substances, and later by the widespread infection of the organism. The mechanism of defence against tuberculosis is only partly known. In the case of local lesions of the lungs or other parts the reaction of the tissues probably resulting from the activity of chemotactic substances in the body of the bacilli themselves, or of similar substances produced by the cellular necrosis, leads to the formation of an embankment of cellular or fibrous tissue that serves to hold the disease in check. Subsequently the disease may be wholly eradicated by degenerative changes terminating in calcification. That such favorable results are not uncommon is proved by the frequent occurrence at autopsies of small sclerotic or calcareous areas in the lungs. Tuberculosis is frequently cured in these early stages, but after it has reached the degree of intensity or the widespread character that makes it recognizable by our present methods of physical examination, the reactive processes are usually no longer able to cope with its progress.

PSEUDOTUBERCULOSIS.

This name has been applied to conditions occasionally met with in which nodular lesions resembling tubercles, but containing

micro-organisms of different kinds, have been found in the liver, kidneys, and other organs. One of the best studied of the organisms in question is a bacillus, motile and easily stained by methods which do not color the tubercle-bacillus. Pure cultures inoculated in other animals give rise to the same lesions. Pseudotuberculosis is probably not a specific form of disease; a variety of conditions may present this appearance.

FOWL-TUBERCULOSIS.

Tuberculosis of various forms of fowl or birds (Avian Tuberculosis, Tuberculosis Gallinarum) is a disease similar to, but not identical with, human tuberculosis. The spontaneous disease of birds occurs most frequently in the liver. There are nodules composed of round cells, but showing no tendency to coagulation-necrosis or to the formation of giant-cells. The bacillus, which is found in abundance, resembles the human tubercle-bacillus and may be stained by the same methods, but differs from this organism in the fact that it grows upon ordinary media and not upon potato, and is more resistant to heat, at least as far as its retention of virulence is concerned. When inoculated in rabbits abscesses result at the point of inoculation, and later lesions of the lungs develop. The lungs are never primarily involved in the spontaneous disease of birds. Many believe this disease a variety of tuberculosis modified by its occurrence in birds.

LEPROSY.

Definition.—Leprosy, Lepra, or Elephantiasis Græcorum, is an infectious and mildly contagious disease, caused by a specific bacillus, the Bacillus lepræ, discovered by Hansen.

Etiology.—The essential cause of leprosy is a bacillus which closely resembles the tubercle-bacillus, though it is less frequently curved and is somewhat more easily stained. Further, it differs in its grouping in the tissues and in its failure to grow satisfactorily on artificial media. The organism is usually found in large numbers in the leprous lesion, and is readily stained by any of the methods applicable for tubercle-bacilli or by Gram's method. It frequently shows light areas like those of the tubercle-bacillus, and these have been regarded as spores; more probably they are produced by fragmentations, as in the case of tubercle-bacillus. Attempts at culture have thus far been unsuccessful, though Neisser claims to have obtained cultures on blood-serum containing gelatin and on coagulated egg-albumin. Others have claimed definite results with similar media, but cultivation at the present time is not ordinarily possible.

The specific nature of the bacillus has not been demonstrated, as it is almost, if not entirely, impossible to produce the disease

in animals. Some successful experiments have been made by inoculating portions of leprous tissue in the anterior chamber of the eye or other parts of animals; but definite generalized leprosy has not been thus far produced. In one case the disease has been given to a condemned criminal by direct inoculation.

Besides the specific bacillus other conditions are important in the etiology. Thus the disease flourishes in certain localities extensively and little in other places. It is uncommon in the United States, but some of the Gulf States, particularly Louisiana, have considerable colonies, and in the Northwest and on the Pacific Coast it is met with among the Norwegian and Chinese immigrants. In Mexico, South America, Norway and Sweden, India, and other Asian countries it is common, and the Sandwich Islands are particularly affected. During the Middle Ages it flourished in Europe as a universal scourge, unsanitary conditions probably acting as the predisposing cause. Certain articles of diet are believed to occasion it, particularly fish; this view, however, lacks proof.

The disease must be regarded as contagious, though less so than tuberculosis. Intimate association for a long time seems to be necessary for its transference. It is probably transmitted from parent to offspring in rare instances.

Pathologic Anatomy.—Leprosy presents itself in two forms, the *tubercular* and the *anesthetic* form. In the former there are developed in the skin of the face, the extensor surfaces of the elbows and knees, about the hands, or less frequently elsewhere, small or large nodular elevations. These at first are reddish in color, with apparent inflammatory reaction. Later they lose their redness and remain as indolent lesions that grow very slowly or remain stationary. They may break down, forming ulcerations which do not readily heal, or they may be gradually converted into fibrous cicatricial tissue, causing unsightly deformities of the skin. The appearance of the patient's face is highly characteristic, and is known as *leontiasis leprosa* (Fig. 95). The mucous membranes and some of the internal organs may be involved. The anesthetic form is usually marked by less conspicuous lesions, but subjective symptoms, such as hyperesthesia and neuralgic pains, and later ulcerations partly trophic in nature, may make it a more serious variety. In the skin there are found whitish or brownish spots, slightly if at all elevated or altered in consistency. Later, ulcerations may appear. Very commonly the anesthetic and tubercular varieties are coexistent.

The nodules occurring in the liver, spleen, and testes in this disease are admitted to be similar to the nodules of the skin; those found in the lungs, kidneys, and intestines, as well as those of the serous surfaces, are believed by many to be tuberculous and the result of secondary infection. These two diseases are certainly

FIG. 95.—Nodular leprosy (Goldschmidt).

and *lepra gangrænosa* are applied to such; and various
i and saprophytic organisms have been discovered in
s.

bacilli occur within the cells and possibly also between them. They are always found in groups and usually in large numbers. They multiply within the cells, the protoplasm of the latter at the same time undergoing a process of swelling and degeneration. This at first spares the nucleus, but finally the nucleus itself is broken down and the cell is thus converted into a sac containing degenerated protoplasm and abundant bacilli (Fig. 96). The term *lepra-cell* has been given to these. Giant-cells may be formed, though they are not frequent and are rarely typical. Secondary infections or injuries may lead to suppurative or other forms of softening, and the final termination either with or without previous softening may be cicatrization. The lesions of the internal organs met with in some leprous cases, notably those of the lungs, intestine, kidney, and serous surfaces, are avascular, show more tendency to necrosis, and contain more giant-cells; in some cases inoculation has showed that the lesions contained the tubercle-bacilli. Whether they are strictly tubercles, or whether they are lepromata with secondary infection with tubercle-bacilli, cannot be decided. They are certainly not pure leprosy, and more probably are purely tuberculous.

FIG. 96.—Lepra-bacilli in a lepra-cell (Karg and Schmorl).

The anesthetic areas and pigmented or light-colored spots of the anesthetic form present somewhat the same histologic features as the leprous nodule, though in a diffuse form. Formerly these lesions were considered entirely the result of trophic changes. In these cases the more conspicuous lesion is that of the nerves. These may show nodular thickening of the perineurium with inflammatory and degenerative changes of the nerve itself. The bacilli are present in these lesions. Changes in the spinal cord have occasionally been discovered.

Pathologic Physiology.—Infection with the lepra-bacillus leads to local rather than general disturbances. The toxins of the disease, if such there be, are not of great virulence, and constitutional symptoms are therefore wanting as a rule. In the later stages fever and other systemic disorders may be occasioned by secondary infections. A supposed antitoxic substance has been prepared and has been largely used. It is impossible to claim or disclaim the antitoxic nature of this, as no toxins have as yet been isolated or obtained in any form, and the supposed antitoxic substances cannot therefore be tested.

In the anesthetic form it was formerly customary to regard the pigment or light-colored spots as a result of trophic disturbance, and more destructive lesions, such as ulceration and gangrene,

received a similar explanation. Recent investigations, however, seem to show that in these cases there is usually from the first a leprous change in the tissues, and that secondary infections frequently play a part, though trophic disturbances must still be admitted to a certain extent.

GLANDERS.

Definition.—Glanders is an infectious and contagious disease of horses and asses, sometimes communicated to other animals and to man, and caused by a specific bacillus.

Etiology.—The Bacillus mallei was discovered by Löffler and Schütz. It is an organism resembling the tubercle-bacillus, though somewhat shorter and thicker. It occurs in the lesions of the disease singly or in clumps, and has been found in the blood. The bacillus is non-motile and does not possess flagella. Stained specimens show parts that do not receive the stain. These have been regarded as spores, but are more generally thought to be areas of degeneration. Ordinary solutions of anilin dyes, and especially alkaline solutions, stain the organism very well. The demonstration of the bacillus in the tissues requires prolonged staining and rapid decolorization.

Cultivation.—Cultures are best obtained from softened nodules of guinea-pigs inoculated with infected pus, or from the testicles after injection of infective matter into the peritoneal cavity. The organism grows quite readily upon ordinary media, but the most characteristic culture is seen upon boiled potato. The colony first appears as a honey-like layer, which becomes brownish in color. The potato itself becomes greenish-brown beneath and around the colony. The cultivation is most successful between 30° and 40° C. (86° and 104° F.).

Drying and elevated temperatures rapidly destroy the organism, and antiseptics kill it quite readily. The bacillus is a pure parasite, multiplying only in the body of infected animals or man.

Pathogenicity.—The specific character of the bacillus is unquestionable. Inoculation of guinea-pigs, rabbits, field-mice, or other animals with infected pus or with pure cultures leads to nodular lesions at the point of introduction, with subsequent softening and ulceration. After death nodules are found in the liver, spleen, kidneys, or other organs, and these contain the bacilli. In horses and asses characteristic lesions of the mucous membranes have been produced experimentally; while in man accidental infection of hostlers or others coming in contact with diseased animals, and of bacteriologists working with cultures, has been repeatedly observed. In one case in my own knowledge a man was infected in a stable in which a glandered horse was kept, and the bacteri-

ologist who isolated the organisms from the patient accidentally infected himself with the cultures.

Pathologic Anatomy.—In horses glanders presents characteristic lesions of the mucosa of the nose. At first there are found slightly elevated nodules, which have a marked tendency to soften, forming irregular ulcerations that become confluent. The floor and edges of the ulcers are yellowish and necrotic in appearance, and discharge more or less purulent matter. The lymphatic glands of the neck and elsewhere enlarge and may suppurate. In the skin the lesions are much the same, but more sluggish. Nodules are not rarely met with in the lungs. These are grayish or pinkish in color, and tend to rapid necrosis. More rarely nodules or ulcers are found in the mucosa of the gastro-intestinal tract.

In man similar nodules and ulcerations may be found in the nose, larynx, or trachea; and external lesions resembling small or large carbuncles are found.

Histologically the lesions of glanders consist of aggregations of round cells of lymphoid or polymorphonuclear type. There is a marked tendency to suppurative or necrotic softening, and sometimes hemorrhagic infiltration may be pronounced.

Pathologic Physiology.—A toxic substance called *mallein* (a bacterial protein) has been obtained from cultures of the bacilli. Injected into infected animals this acts somewhat as does tuberculin in tuberculosis. A special toxin is probably active in the production of the general symptoms of the disease. By repeated dosage with mallein it is claimed that immunity may be conferred.

MALIGNANT EDEMA.

Definition.—Malignant edema is a form of intense infective inflammation and necrosis observed in certain animals and in man, and is due to a specific micro-organism. The condition has frequently been described by clinicians as gaseous gangrene, traumatic gangrene, gangrene foudroyante, etc. Infectious emphysema (*q. v.*) has doubtless often been mistaken for this disease.

Etiology.—The micro-organism of malignant edema was described by Pasteur and named the *Vibrion septique*. Koch showed that it does not flourish in the blood, and that the name given by Pasteur is therefore not appropriate. He named it therefore *Bacillus œdematis maligni*. This organism is widely distributed. It is very commonly present in the soil, particularly in garden-earth, and is often found in dust and in the intestinal contents of animals. Introduced into the subcutaneous tissue of animals it multiplies greatly and sets up a violent local process. The bacilli are readily obtained from the diseased area, and may be stained with the ordinary anilin dyes, but not by Gram's method. The bacillus resembles the anthrax-bacillus very closely, but is somewhat more

slender. It is prone to occur in long chains, the organisms being apparently in contact end to end. Movement of the organisms is frequently observed, and flagella are found by appropriate stains. In the spore-formation the center of the organism swells and the spore is developed within.

Cultivation.—The cultivation of this organism is generally easy. White mice or other susceptible animals are first infected by introducing powdered garden-earth into a subcutaneous sac. Direct infection of the open wound will not succeed, as the organism is strictly anaërobic.

From the pus in the subcutaneous tissues growths may be obtained upon the surface of gelatin in an atmosphere of hydrogen, or in puncture-cultures in gelatin from which oxygen has been excluded. On the surface of the gelatin are formed small grayish-white bodies, which increase in size with advancing age. Portions removed from these and stained show masses of bacilli in the form of long filaments. In the gelatin-tube there are formed whitish spherical colonies of a somewhat cloudy appearance. These consist of a turbid liquid, the gelatin undergoing liquefaction. There is also some gas-production, the gas formed having a peculiar and unpleasant odor. This is marked when the medium contains glucose (Fig. 97).

FIG. 97.—Bacillus of malignant edema growing in glucose-gelatin (Fränkel and Pfeiffer).

Distribution.—The bacillus of malignant edema occurs only in the subcutaneous tissues near the point of inoculation, in the muscles, and in the peritoneal cavity at the time of death. It does not invade the blood, as the amount of oxygen there present prevents its growth, and it flourishes in the subcutaneous tissue because this is least accessible to oxygen. In bodies dead some time the organism may spread to the blood and the organs of the body. The distribution of the organisms outside the body has been referred to.

Pathogenicity.—The bacillus of malignant edema is undoubtedly the cause of the disease in question, as has been proved by inoculations upon mice, guinea-pigs, and other animals. Cats and dogs are less susceptible than other animals; cattle seem to be almost wholly immune.

Pathologic Anatomy.—The lesions of malignant edema consist of various forms of rapid suppuration and necrotic inflammation of the subcutaneous tissues. There may rapidly form emphysematous and gangrenous alterations of the subcutaneous tissues,

with sometimes pus-formation, at other times extensive hemorrhagic infiltration.

Pathologic Physiology.—Toxins are doubtless formed, but these have not as yet received special attention. A few cases of malignant edema have been reported in man; some following injection of musk in the course of typhoid fever; some occurring in the puerperium, and some apparently without external injury. Infection in the latter probably occurred from the mucous surfaces. In all cases the general vitality of the patient was reduced by some previous disease.

ANTHRAX.

Definition.—Anthrax is a specific infection due to a characteristic bacillus. It occurs most frequently in cows and sheep; it may affect other animals and man. Dogs, cats, birds, and cold-blooded animals are quite immune. In animals it is called splenic fever; in man, malignant pustule and wool-sorters' disease.

Etiology.—The *Bacillus anthracis* is a non-motile rod-shaped organism that has a decided tendency to form long chains. The individual bacillus is from 5 to 20 μ in length and from 1 to 1.25 μ in thickness. The chains appear as threads, with often a little thickening at the ends of the individual bacilli showing the points of contact. The ends are squared or often slightly concave. In

FIG. 98.—Bacillus anthracis, stained to show the spores (Fränkel and Pfeiffer).

artificial cultures in the presence of oxygen spores are formed within the bacilli. These are elliptical or oval in shape, and do not alter the configuration of the bacillus (Fig. 98).

The organism is easily stained with the simple anilin dyes, and

may be demonstrated in the blood or the tissues by Gram's or Weigert's stains. There are no flagella.

Cultivation.—The anthrax-bacillus may be obtained in pure culture from the diseased organs upon various media. The culture in gelatin is most characteristic. Upon plates there are formed whitish colonies, which under low powers of the microscope show a tufted, irregular character at the edges and upon the surface, suggesting bunches of twisted wool-fibers. The gelatin is slightly liquefied. The tufts may be removed by pressing a cover-glass against the surface of the colony, and when stained are found to consist of curved parallel chains of bacilli. In puncture-cultures filaments project at right angles to the puncture toward the sides of the test-tube, and the growth at the surface, where oxygen is abundant, is luxuriant, while that in the depth is comparatively sparse.

Pathogenicity.—The infectiveness of the bacillus is undoubted. A small portion introduced into a susceptible animal gives rise to marked symptoms in twelve or twenty-four hours, and death soon follows. The bacilli may be demonstrated in the blood and in various organs in great abundance. When the bacillus is killed and the spores are introduced into the body similar results follow.

Distribution.—The anthrax-bacillus occurs in all of the local lesions, and from these extends into the blood and into the organs, particularly the spleen, liver, kidney, and lungs, where they are found in the capillaries in immense numbers. The structure of these organs is, as a rule, little affected, probably because death occurs before changes may take place. The organisms are discharged from the body in the stools, urine, and other discharges, and thus conveyed to other animals. At one time it was supposed that they are scattered about by earth-worms obtaining them from cadavers. This is scarcely probable. Multiplication of the organisms outside the body does not occur to any extent, but the organisms, and particularly the spores, may live a long time, and may be conveyed to great distances in infected materials, particularly wool, hides, bristles, and the like.

Mode of Infection.—In animals infection most frequently occurs through the gastro-intestinal tract, the bacilli being swallowed with fodder that has been contaminated. The organisms may, however, gain entrance through the lungs or through external abrasions. The latter form of infection is most common in man; though gastro-intestinal and pulmonary infection sometimes occurs.

Pathologic Anatomy.—The lesions produced by anthrax are more or less local, but occasion general septicemia. In man, after infection of the skin through abrasions in persons handling the hides or wool, or other materials from diseased animals, a swelling of greater or less size develops. This is intensely in-

flammatory, often covered and surrounded by slight bullous vesicles, and attended with considerable edema. Erosion of the surface may take place and sanious liquid may be discharged, with the formation of crusts. Histologically the process consists of rapid infiltration of the corium and papillary bodies with leukocytes. The bacilli are found in abundance between the cells, and hemorrhagic infiltration and sero-sanguinolent edema are observed. Necrosis subsequently occurs, though not to a considerable extent. When infection takes place through the gastro-intestinal tract, as is sometimes observed in man and very commonly in animals, lesions somewhat like the above are formed in the mucosa and submucosa of the small intestine, less frequently of other parts. At first these lesions appear as hemorrhagic extravasations, then swelling follows, and finally the surface ulcerates, leaving irregular excavations with blood-stained bases and edges. Profuse diarrhea with bloody discharges may occur. Infection through the lungs occurs in men engaged in handling infected wool (wool-sorters' disease), and in persons working in paper-factories, where infected rags carry the germs. In these instances the bacilli lodge in the alveoli of the lungs, causing rapid cellular exudation with considerable edema and hemorrhagic infiltration. The process is lobular in character, but large areas of the lungs may be simultaneously involved. Serosanguinolent pleurisy, swelling of the lymphatic glands of the mediastinum, and hemorrhagic extravasations of the mediastinum are not unusual.

Pathologic Physiology.—The presence of the anthrax-bacillus leads to the formation of toxic materials in the blood, and a poisonous albumose has been obtained from cultures. The general symptoms, however, are probably in large measure the result of dissemination of the bacilli themselves and their local effects.

It has been found possible by cultivation at high temperatures and by introducing the organisms into insusceptible animals, and also by adding chemical agents to cultures, to alter the pathogenicity of the bacillus to such an extent as to make it harmless, even to white mice. By introduction of such cultures and subsequent successive inoculation with cultures of increasing virulence protection has been afforded. Antitoxic substances have been obtained from the blood of protected animals, but the method of successive vaccinations rather than the use of antitoxic serum is at present relied upon to combat the disease.

INFECTIOUS EMPHYSEMA.

Definition.—This term is provisionally applied to a form of infection that has been described under various names, such as gaseous gangrene, gas-phlegmon, emphysematous necrosis, and the

like. Undoubtedly it has been mistaken for malignant edema in certain cases. The disease is caused by the Bacillus aërogenes capsulatus of Welch and Nuttall.

Etiology.—The bacillus in question is a non-motile organism of variable size, 3 to 6 μ in length and about the thickness of an anthrax bacillus, with adjacent ends slightly rounded or square cut, and occurring singly, in pairs, clumps, or sometimes in short chains. Very rarely it occurs in long threads. It is easily stained with the ordinary anilin dyes or Gram's stain. A capsule is sometimes demonstrable in specimens obtained from the body or from agar-cultures. The bacillus does not form spores. It is probably identical with the Bacillus phlegmones emphysematosæ of Fränkel.

Cultivation.—The organism is anaërobic, no growth occurring on the surface of solid media in the presence of oxygen. In media containing fermentable material gas-formation is regularly observed. The colonies in agar are grayish-white or slightly brownish; those in the depth appearing as small spheres or ovals slightly flattened, with knob-like or feathery projections. The cultures in gelatin show slight and slowly developing liquefaction.

Pathogenicity.—By experiments on animals exactly the same lesions are produced as those found in man.

Pathologic Anatomy.—The lesions of this infection are widespread. At the point of inoculation there may be found edematous infiltration, with blood-stained fluid, and emphysema due to gas-formation. Rapid necrosis or gangrenous softening of the tissue may occur. The entire surface of the body sometimes becomes emphysematous, and at the autopsy the organs, especially the myocardium, kidneys, liver, and spleen, present a characteristic appearance. They are lighter in color, and on inspection are found to be filled with minute vacuoles or gas-bubbles. The blood of the heart and vessels presents a foamy condition, due to the gas-formation. Practically any of the tissues of the body may be affected. Microscopically, the occurrence of gas-vesicles with numerous bacilli in their walls is the most striking feature.

Regarding the mode of infection, it seems likely that in all cases the organisms enter through some injury or abrasion connected with the external world. Some cases have followed traumatic injuries, others occur in connection with disease marked by ulcerations of the surface of mucous membranes, and at least one instance has been carefully studied in which the disease occurred during the puerperium, probably due to uterine infection. It is not improbable that many of the cases of supposed air-embolism from douching of the uterus after labor are in reality cases of this form of infection.

TETANUS.

Definition.—Tetanus is an acute infectious disease due to a specific bacillus. The bacillus of tetanus was discovered by Nicolaier and isolated by Kitasato.

Etiology.—The *bacilli* occur in the form of cylindrical rods, which are frequently swollen at one end, due to the presence of a rounded spore (Fig. 99). They are non-motile, or but slightly

FIG. 99.—Bacillus tetani; × 1000 (Fränkel and Pfeiffer).

motile, although they may have flagella. They usually occur singly, though occasionally a few may be seen end to end. They occur in the local lesions from which traumatic tetanus takes its origin, and may sometimes be readily demonstrated by spreading some of the pus or exudate upon a cover-glass and staining with the ordinary anilin stains. They also stain by Gram's method. The bacillus does not diffuse itself through the body, but in a few cases it has been found in the central nervous system. The organism is readily destroyed by heat, but its spores are quite resistant.

Cultivation of the tetanus-bacillus is difficult. It is obtained from garden-earth or the pus of infected wounds by submitting the material to sufficient heat to destroy other organisms, even the bacillus of tetanus itself, leaving the spores uninjured. With this material animals are inoculated, and from the products of the local lesions or directly from the original material cultures are made in gelatin.

The organism is strictly anaërobic. The typical culture is obtained in the depth of gelatin. Deep beneath the surface there are formed along the line of puncture pointed processes standing out at right angles from the puncture. After a week liquefaction of the gelatin occurs, and an accumulation containing

grayish-white turbid liquid is formed. When the growth is formed on the surface of gelatin in an atmosphere of hydrogen a similar radiating structure is found in the colonies, the centers of which are rather dense. Liquefaction of the gelatin subsequently takes place. Considerable gas with a pungent odor is produced in the growth of this bacillus.

Distribution.—The tetanus-bacillus is found very frequently in garden-earth, in the intestinal discharges of animals, and upon various articles about stables. Infection occurs in human beings or animals through punctures made by nails, splinters, and the like.

Pathogenicity.—The bacillus placed upon an open wound may not give rise to the disease, from the fact that the presence of oxygen prevents its growth. Subcutaneous inoculation, however, causes rapid destruction of animals with typical symptoms. The period of incubation may be only a few hours, or one or two days, or it may be several weeks. The association of certain other organisms, such as the pus-producing organisms, seems to favor the development of the disease by preventing phagocytic action of leukocytes, or by consuming oxygen and thus allowing the tetanus-bacillus to flourish.

Pathologic Anatomy.—No characteristic lesions are found in this disease. Locally a wound or injury through which inoculation has taken place may be discovered; but this is only exceptionally extensive. Sometimes no local injury can be discovered, and it is supposed that infection at times occurs through the gastro-intestinal tract, or through other mucous membranes. Intense congestion of parts of the nervous system may be found at the autopsy, but this is not characteristic.

Pathologic Physiology.—Tetanus is essentially a toxemic disease. The bacillus produces, at the point of its growth, poisons of almost inconceivable power. Two distinct substances have been isolated, *tetanin* and *tetanotoxin*. These occur in the blood, urine, and probably other fluids of the body. The bacilli are not found in these fluids. When the toxin of tetanus is introduced into animals in gradually increasing quantity immunity is developed and the serum is found to have antitoxic power. The *antitoxin* may be precipitated from the blood by alcohol, and kept in a dry state. In practical medicine the antitoxin of tetanus has not proved as useful as experiments seemed to promise. This may be due to the fact that the intoxication is generally so extensive by the time the disease is recognized that treatment comes too late.

ACTINOMYCOSIS.

Definition.—Actinomycosis is a chronic infectious process characterized by inflammatory reaction of the tissues with a tendency to the formation of suppurative foci, and due to the specific action of a micro-organism, the Actinomyces bovis seu hominis.

Etiology.—Actinomycosis is a disease of cattle, horses, swine, and occasionally of man, being communicated to the latter from animals directly or indirectly.

The specific cause of the disease, the actinomyces, is an organism which occurs in the tissues in the form of clusters having a radiate structure, and it has therefore been termed the "ray fungus." These clusters may be so small as to be invisible to the naked eye, or they may reach considerable dimensions by their growth and aggregation. The central part of the cluster frequently has a granular appearance, suggesting a mass of micrococci. Reaching out from this may be seen more or less regularly diverging striæ or rays, and the periphery is composed of what appear to be bulbous extremities of the rays (Fig. 100).

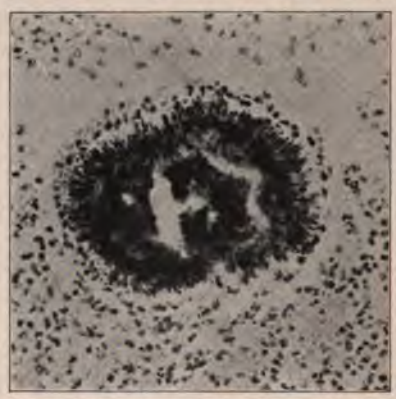

FIG. 100.—Actinomyces cluster (Karg and Schmorl).

The exact biologic position of the organism has not yet been determined. By some it is regarded as one of the hyphomycetes; others place it among the bacilli.

Pure cultures of the organisms have been obtained from the lesions in animals, but are only developed with difficulty from the human disease. The infectiousness of actinomycosis has been abundantly demonstrated by inoculation-experiments. The cultures may be obtained upon ordinary media, such as agar-agar, with or without glycerin, and form firm points, small in size and sometimes almost cartilaginous in consistency. The characteristic striate or ray-like structure is not seen in cultures as in the original clusters, but the organism may present a somewhat branched appearance.

The manner of infection with the actinomycoses is not completely determined. It is quite likely, however, that the parasite is carried to the tissues by various vegetable substances, particularly the spears of the oat-seed and other grains. Sometimes these have been found embedded in the lesions; in other cases splinters

of wood have been discovered. It seems possible that the specific agent is conveyed into the tissues by these foreign bodies.

Pathologic Anatomy.—The pathologic changes induced by the actinomyces consist of round-celled infiltration and proliferative changes in the connective tissue surrounding the parasite, and sometimes secondary softening, necrosis, or suppuration. In cattle the disease affects the lower jaw, less frequently the upper jaw or other bones; the tissues of the neck, the tongue, and other parts. In man it is met with in the gums and floor of the mouth, in the lungs, intestines, and other internal organs. The naked-eye appearance of the lesions may first be simply that of a hard red papular formation, with more or less induration surrounding it; later this tends to increase in size and may break down, forming necrotic or suppurative excavations. The process of repair or cicatrization may proceed in some parts to the extent of almost complete repair, while the suppurative or necrotic change advances in other directions, and thus cavities and irregular communicating sinuses are established. The part in which the disease exists may be considerably disfigured and much enlarged. The pus or necrotic material within the lesions has a peculiar granular character, the granules or actinomycosis-bodies frequently containing a group of the organisms. Occasionally calcification of the diseased area may take place. When the jaw-bone is affected the disease, as a rule, begins about carious teeth, fistulæ communicating with the roots of teeth.

In the case of disease of the lungs some have observed a preliminary catarrhal inflammation of the bronchi. More frequently, however, there are from the first nodular areas of bronchopneumonia, which tend to undergo changes similar to those already described. The surrounding lung-tissue frequently becomes indurated from interstitial pneumonitis. Extension may occur to the pleura, pericardium, and mediastinal tissues.

In the case of actinomycosis of the intestinal tract there are first elevations of the mucous membrane, the disease involving the mucosa and the submucosa. Subsequent softening of these leads to the formation of ulcerations. Extension to the peritoneum and to the other organs of the abdomen may take place.

In any case of actinomycosis a penetration of the blood-vessels or lymph-channels may lead to metastases. Thus in actinomycosis of the abdominal cavity the liver is frequently involved; and other parts of the body may be similarly affected. Actinomycotic lesions of the brain (abscesses) are sometimes seen in such instances. In other cases of cerebral involvement there may be no evidence of the original focus or point of entrance of the germ.

Microscopically the characteristic feature of this disease is the parasite itself surrounded by lymphoid cells in considerable numbers, with some epithelioid cells and occasionally giant-cells.

When the process tends to a favorable termination by cicatrization fibrous-tissue formation proceeds in the usual manner.

Pathologic Physiology.—The actinomyces is mainly active as a local parasite, the general disturbances of health being comparatively slight. There is a marked tendency to limitation or retardation of the disease, and sometimes this is effected completely.

MYCETOMA.

Mycetoma, or Madura-foot, is an infectious disease occurring in India and elsewhere, and caused by an organism of an uncertain biologic class. The disease is not infrequent in Madura, Delhi, and other parts of India, and has been observed in Africa, Southern Europe, and America.

Etiology and Pathologic Anatomy.—As its name indicates, the disease affects the foot, and usually follows injuries, particularly thorn-wounds. In rare cases the hands or other parts are affected. At first there is nodular inflammatory swelling, beginning on the plantar surface or dorsum of the foot and spreading to the sides. These swellings are hard and painless. Later, softening occurs and rupture takes place. Thin, watery pus is discharged, and this contains grayish or reddish granular bodies or black granules resembling particles of gunpowder. In the former case the term pale mycetoma is applied; the latter variety is called black or melanoid. In the later stages of the disease discharging sinuses may remain, while newer nodules in turn are formed and soften. Finally, the member affected becomes greatly deformed, the portions not involved growing thin, while the diseased part increases in size. Death occurs from exhaustion or complications.

FIG. 101.—Streptothrix Maduræ in a section of diseased tissue (Vincent).

Histologically the nodules resemble large tubercles, but are highly vascular. The bulk of the growth consists of granulation-tissue cells, those in the center being small, those near the outer edge often large and containing two or more nuclei. True giant-cells are rare. In the center may be found a branching micro-organism, called *Streptothrix Ma-*

duræ (Vincent). This stains by Gram's method, and sometimes shows somewhat bulbous swelling of the ends of the threads and their branches (Fig. 101). Around the organism may be seen an area of degeneration, having a striate arrangement suggesting that seen in actinomycosis. Extensive degeneration and pus-formation occur in the center of the diseased areas in the later stages; and hemorrhage may occur from the new blood-vessels. Histologic examination of the granules in the pus shows the micro-organisms in the form of interlacing threads. Bodies resembling spores have occasionally been described.

The organism has not as yet been definitely classified. It is certainly allied with the actinomyces, but probably not identical. It has been cultivated upon various media, particularly infusions of hay and the like, rendered slightly acid in reaction. It forms small nodular and hard growths, which become rose-red in color when they cling to the sides of the test-tube near the surface of the liquid, or brownish when they sink to the bottom. Upon agar isolated grayish or later rose-red clusters are formed. Inoculation-experiments have thus far met with little success. Local reaction has been so produced, but not a definite disease.

RELAPSING FEVER.

Definition.—Relapsing fever, or typhus recurrens, is an infectious and contagious disease, probably caused by a specific organism which is found in the blood.

Etiology.—The Spirochæta Obermeieri is a spiral organism, in length several times the width of the red corpuscle (16 to 40 μ). It is found in the fresh blood, and presents active movements due to flagella (Fig. 102). The organism stains well with ordinary anilin dyes. The relation of this spirillum to the disease can hardly be questioned, as it is invariably present and appears in the blood during the paroxysms of fever and disappears in the intervals, thus showing its relation to the symptoms of the disease. The organism has not as yet been cultivated, but by inoculation with blood a number of investigators have transferred the disease to monkeys and human beings.

FIG. 102.—Spirochæta Obermeieri in the blood (von Jaksch).

Pathologic Anatomy. — The spleen becomes greatly enlarged; it frequently presents a variegated appearance on section, due to areas of anemic infarction and necrosis or fatty degeneration alternating with deeply congested portions.

Pathologic Physiology.—The peculiar feature of relapsing fever and the one that has given it its name is the recurring paroxysms of fever. The cause of this periodicity is as yet unknown, though it is likely that the development of the spirochæta is such as to determine the relapses.

INFLUENZA.

Definition.—Influenza is an infectious disease occurring in widespread epidemics and caused by a specific bacillus.

Etiology.—The Bacillus influenzæ was discovered by Pfeiffer and Canon in 1892. The bacilli are extremely small and usually occur singly, though they are occasionally united by the ends, forming short chains. They may be stained with the ordinary anilin dyes, especially with carbol-fuchsin, but are decolorized by Gram's method. The ends of the bacillus are somewhat swollen and usually stain rather more deeply than the shaft. This gives the organism somewhat the appearance of a diplococcus or dumbbell-shaped bacillus. It is not motile. It has been cultivated upon glycerin-agar and upon blood-serum, forming minute drop-like colonies, seen with difficulty with the naked eye, but clearly with the aid of a lens. The colonies do not coalesce. The appearance of the growth is somewhat like that of condensed moisture on the surface of the culture-medium.

The bacilli occur abundantly in the sputum of the disease, decreasing in quantity as the case advances. When purulent expectoration ceases the bacillus disappears entirely. In fatal cases it has been found in abundance in the tissues of the lung, particularly in cases in which complicating pneumonia has existed. It does not occur in other diseases. Animal experimentation has thus far been unsatisfactory, though the organism has proved pathogenic for certain animals. Definite results have not, however, been reached, and the specific character of the organism is inferred rather than demonstrated.

Pathologic Anatomy.—There are no specific lesions in this disease. The organisms provoke intense catarrhal processes and doubtless at times pneumonia. In some cases the pneumonia of grip is caused by mixed or secondary infection.

Pathologic Physiology.—Very little is known regarding the mode of activity of the bacteria. The constitutional symptoms suggest toxemia, but the nature of the poison is obscure. The immunity from the disease must be exceedingly short, as recurring attacks and relapses may be frequent and succeed one another rapidly. Certain complications and sequels, such as inflammations of the serous surfaces and neuritis, indicate generalized infection and intoxication.

BUBONIC PLAGUE.

Definition.—The bubonic plague, or pest, is an infectious disease due to a peculiar bacillus.

Etiology.—The bacillus of bubonic plague was discovered by Yersin and Kitasato independently in 1894. In blood drawn from a puncture of the skin and in pus from the affected glands may be found small bacilli somewhat resembling the influenza-bacillus. These organisms may be stained readily, and are then seen to be swollen somewhat at the ends and more deeply stained at the poles than in the center (Fig. 103). This gives them an

FIG. 103.—Bacillus of bubonic plague (Yersin).

appearance resembling that of the diplococci, and in specimens from the blood or tissues there is an indistinct capsule. The bacillus is feebly motile, but flagella have not been detected. Pure cultures have been obtained upon various media. Upon glycerin-agar moist, rounded, whitish or bluish-white colonies are formed. Portions of such colonies removed for examination show the bacilli ranged in chains.

Pathogenicity.—The bacillus has been found pathogenic for mice, rats, guinea-pigs, and rabbits, and the symptoms produced by pure cultures are the same as those induced by inoculating animals with blood or portions of tissue from diseased persons. The lymphatic glands may be swollen and petechial hemorrhage may occur as in the human disease.

Distribution.—In the human being suffering from bubonic plague the bacilli are found in the local lesions of the lymphatic glands, the buboes; and also in the blood and various organs. Rats and mice frequently die during epidemics, and doubtless help to spread the disease by infecting the soil and dust about dwellings. Yersin showed that flies die of the disease, and succeeded in obtaining the bacillus from their dead bodies.

Pathologic Anatomy.—The organism produces swellings and suppuration of lymphatic glands, particularly those of the groin, and secondarily lesions of internal organs. The lymphatic glands swell quickly, become tender and congested, and then soften, forming a rather thick pus. This is sometimes somewhat blood-tinged. Petechial hemorrhages and blood-stained effusions into the serous cavities may occur. Petechiæ of the skin are apt to develop as a result of slight traumatisms. Thus the bite of an insect, instead of producing its usual results, may cause distinct ecchymoses in persons suffering from the disease.

Pathologic Physiology.—It seems that the distribution of the bacillus in the blood, as well as toxic substances, contributes to the general disturbance of health. By successive inoculation immunity has been produced, and toxins and antitoxins have been obtained from the serum. The importance of these latter, however, is still under investigation.

DISEASES OF UNCERTAIN BACTERIOLOGY.

SYPHILIS.

Definition.—Syphilis is a specific contagious disease of man, of uncertain etiology. The disease has never been observed in any of the lower animals.

Etiology.—The attempts to find a specific cause of this disease have not as yet met with definite success. The organism which at the present time has the best claim to recognition is that observed by Lustgarten. This resembles the tubercle-bacillus very closely. It is 3 to 7 μ long, and often somewhat curved and swollen at the ends. It stains with difficulty, and a complicated method was suggested by the discoverer. The bacilli are found in the diseased areas in small numbers, lying within the cells and partly between them. It has also been claimed that they occur in the blood. The organism has never been isolated or cultivated upon artificial media. Furthermore, it is difficult to distinguish this supposed specific germ from other bacilli, notably the smegma-bacillus, by the staining-methods suggested.

Whatever the nature of the organism, it is quite certain that the disease is definitely infective. In the great majority of cases infection occurs by direct inoculation in sexual intercourse. It may, however, be conveyed in many other ways. Physicians are sometimes infected in performing surgical operations or in examining syphilitic cases; persons have frequently been inoculated in the process of tattooing or vaccination when saliva or vaccine-lymph from diseased individuals was employed. Infection may be caused by kissing, or indirectly by the use of drinking-vessels which have been employed by the diseased. The new-born may be syphilitic in consequence of disease of the father or mother; and

healthy wet-nurses may be infected by syphilitic nurslings. In addition to the specific cause, surrounding conditions and individual susceptibility doubtless play a part. During the Middle Ages this disease at times and in certain places almost attained the character of a universal scourge. Its manifestations were severe, its course rapid, and in every sense its nature was malignant. Cases of this description are exceedingly rare at the present day.

Pathologic Anatomy.—The pathologic course of this disease may be divided into three stages: the *initial stage*, the *secondary stage*, and the *tertiary stage*.

Chancre.—In the initial stage there is formed at the point of inoculation a primary lesion, commonly termed chancre. This may make its appearance first as a somewhat red and inflamed papule, or as a vesicle which ruptures and thus produces an erosion. When it begins as a papule the surface soon becomes eroded, and thus a superficial ulceration is established. The peculiar feature of this lesion, to which Hunter called particular attention, is its hardness or induration, and it is by this feature largely that it is distinguished from the soft chancre or chancroid. The initial or primary lesion may remain indolent or as a small erosion for a long time, or it may soon cicatrize and leave a more or less definite scar. The chancre occurs upon the glans penis or prepuce, or within the urethra of the male; and in the vagina, urethra, or upon the cervix uteri and external genitalia of the female. Extragenital chancres may be observed in the rectum or anus, on the lips or tongue, tonsils or pharynx, the fingers, or other parts.

Secondary Lesions.—At the end of a variable period of time after the eruption of the initial sore secondary manifestations of the disease make their appearance. The first among these, as a rule, are swelling and induration of the neighboring lymphatic glands (*syphilitic bubo*). Later the superficial lymph-glands of the entire body become swollen and, like those in the neighborhood of the lesion, indurated. At the same time eruptions upon the skin and mucous membranes make their appearance. The interval between the primary and the secondary manifestations is variable. Sometimes it is but a few weeks (three or four), at other times it may be several months. The manifestations of the secondary stage may begin with fever and constitutional symptoms, suggesting sudden and recent infection, and at the same time changes in the blood (rapid reduction of red corpuscles, moderate leukocytosis) make their appearance. Among the *lesions of the skin* various forms of papules, macules, and scaly eruptions are most frequent and characteristic. The lesions are usually symmetrically arranged on the two sides of the body and cause but little irritation. The color of the skin is frequently said to be somewhat coppery. On the mucous membranes and neighboring skin the most characteristic lesion of this stage is the *condyloma*

latum, or *mucous patch*. This appears as a somewhat elevated patch with superficial erosion or ulceration. The surface has a necrotic appearance, and may be covered with more or less secretion.

Tertiary Lesions.—These may take the form of ordinary inflammatory changes of the mucous membranes or of other parts, with a pronounced tendency to fibrous-tissue overgrowth and thickening, or of definite nodules—the syphilitic *gummata*, or *syphilomata*. Among the diffuse syphilitic changes of the tertiary stage may be ranked atheromatous thickening of the intima of the blood-vessels, certain changes in the liver, spleen, kidneys, and heart-muscle, and doubtless also similar alterations in the nervous system.

The localized lesions of the tertiary stage—the gummata—are most frequent in the bones (tibia, sternum, and skull); and in the internal organs, such as the liver, lungs, kidneys, heart, and brain.

The gumma presents itself as a nodular mass, varying in size from small tubercle-like formations (miliary gummata) to tumors the size of an orange, or larger (Fig. 104). It is hard, and has

FIG. 104.—Gummata of the liver.

frequently an elastic character, which has suggested the name gummy tumor or gumma. On section the substance is frequently found to be gelatinous or mucoid in appearance; but there is nearly always considerable induration, either peripheral, in the form of a capsular enclosure, or striate, in the form of bands extending from the center to the periphery and into the surrounding tissue. Occasionally gummata soften very rapidly and become converted more or less completely into puriform collections. When situated in the mucous membranes or adjacent to the surfaces of the body, suppurative, fatty or necrotic softening may lead to the formation of superficial ulcerations. These may re-

main indolent, or may gradually become cicatrized. Sometimes a gummatous lesion disappears entirely by absorption without leaving a trace of its existence.

Histology.—In syphilitic processes of all kinds and in all of the stages there is a tendency to accumulation of the round cells and proliferation of connective-tissue cells, the processes being first manifest around the smaller blood-vessels, but subsequently extending to other parts of the tissue. The walls of the blood-vessels themselves are frequently involved, and thickening of the inner or of all the coats may be observed. Complete destruction of the vascular channels is not rarely the consequence. In the subsequent course of the disease there is a tendency to the formation of distinct cicatricial connective tissue, giving rise to indurated scars or diffuse sclerosis; and a less pronounced tendency to the occurrence of degenerations, mucoid and fatty, causing areas of degenerative softening.

The Chancre.—The initial lesion first presents small areas of round-cell infiltration in the deeper layers of the skin or mucous membrane, and as a rule in the neighborhood of the blood-vessels. The connective tissue at the same time undergoes proliferative change, and spindle-shaped cells or irregular embryonal connective-tissue cells are found mingled with the round lymphoid cells, or surrounding the foci of the latter. Thickening of the blood-vessels may be observed in the later stages or from the very first. The tissue-elements of the skin and of the subcutaneous tissue are usually separated by infiltrating liquid, and the latter may loosen the tissues of the surface and cause exfoliation of the superficial epidermis, and thus lead to the development of the primary vesicle or the erosion so commonly seen. The induration of the chancre is probably the result of the sclerosis of the vessels and the general connective-tissue hyperplasia, as well as in part due to the tense infiltration of serous liquid.

The Mucous Patch.—The condyloma latum is very similar in structure to the initial lesion. There is, first, round-cell infiltration of the deeper layers of the mucous membrane, with serous exudation and erosion of the surface. Later, there is a tendency to connective-tissue hyperplasia, though this is less marked than in the case of the chancre.

The Tertiary Lesions.—The gumma is composed in large part of round cells derived from the blood-vessels and proliferated connective-tissue cells having a spindle-shape or various irregular forms. Epithelioid cells are less abundant, and giant-cells, though occurring at times, are usually few in number. The blood-vessels are nearly always more or less affected, the intima particularly being thickened; there is also new formation of blood-vessels, the lesion in this respect differing from the nodular lesion of tuberculosis (Fig. 105). Secondary changes are almost always

seen in gummata of considerable dimensions. Among these may be recognized a gradual necrotic transformation of the cells in the center of the lesion, with distinct fatty degeneration or myxomatous change. The degenerated tissue may be infiltrated by leukocytes in a state of fair preservation.

In the diffuse tertiary lesions of syphilis the tissues of the affected organ are indurated, the connective tissue showing more

FIG. 105.—Gummatous meningo-encephalitis (Ziegler).

or less pronounced hyperplasia. These processes cannot be certainly distinguished by their microscopic or general features from sclerosis due to other causes.

Pathologic Physiology.—Syphilis is one of the most persistent of the infectious diseases, and occasions widespread changes that are doubtless toxic in character. The nature of the toxic principles, however, is entirely unknown. In the tertiary stage pronounced anemia (cachexia) is frequent; and in the secondary stage rapid chloro-anemia with leukocytosis is quite common.

Congenital Syphilis.

Syphilitic lesions may be found in the new-born, or may develop some time after birth. Not rarely they occur in the new-born fetus, and cause its premature death. Frequently there is maceration of the fetus prior to expulsion. Among the lesions observed, sclerotic changes in the lungs, liver, spleen, pancreas, and other organs are conspicuous; and a certain condition of the bones is quite characteristic. The latter consists of a hyperplasia of connective tissue and fatty degeneration at the junction of the

epiphyses of the long bones with the shafts. Various superficial lesions of the skin in the form of vesicles or bullæ, fissure, and the like may be observed. The blood may present considerable excess in the number of leukocytes. An almost distinctive condition of second dentition is that known as Hutchinson's teeth. This consists of a notched indentation of the cutting surface of the upper central incisors. In addition, the tooth is often wedge-shaped and peg-like (Fig. 106). All cases of inherited syphilis do not present this condition, and it occasionally occurs in non-syphilitic children.

FIG. 106.—Hutchinson's teeth.

SOFT CHANCRE.

Definition.—The soft chancre or chancroid is an infectious, venereal sore appearing upon the external genitalia. Its probable cause is the bacillus of Ducrey.

Etiology.—The soft chancre occurs almost exclusively upon the genital organs or the surrounding parts. It is always caused by direct contagion.

The bacillus of Ducrey and Unna is a rod-shaped organism about 1.8 μ in length and 0.5 μ in thickness, and is somewhat compressed in the middle, so that it has a figure-of-8 shape. The ends are rounded and the organisms often occur in chains, or later in the disease in pairs as a diplobacillus.

The demonstration of the bacillus in the pus is comparatively easy. The specimen is stained with alkaline solutions of methylene-blue and quickly decolorized with weak acetic-acid solution. In the tissues the demonstration is more difficult.

The cultivation of the bacillus has not thus far proved successful, though certain bacteriologists claim they have succeeded.

The bacillus is found in the pus of the soft chancre, as well as in the deeper parts, lying between the cells and frequently within the leukocytes. It has also been discovered in the pus and walls of ulcerating buboes, but is generally absent in the pus of unopened buboes.

Mixed Infection.—Various other organisms have been found associated with the bacillus, including streptococci, staphylococci, the gonococcus, and bacilli of uncertain nature.

Pathologic Anatomy.—The soft chancre is an ulcer of variable character. Usually it is a simple ulcer, with suppurating base and edges, not differing from ulcers due to other causes. Sometimes the ulceration seems more malignant and takes on a phagedenic or serpiginous character (see Ulceration). The neighboring lymphatic glands are usually enlarged and sometimes undergo suppurative softening (bubo).

Pathologic Physiology.—Little is known of the existence of special toxic bodies in this disease. It is believed, however, by some that toxins are produced by the bacilli, and that these are capable of producing secondary lesions (bubo) without the presence of the bacilli themselves.

YELLOW FEVER.

Definition.—Yellow fever, or typhus icteroides, is now recognized as infectious and contagious, and it is probably caused by a specific bacillus recently isolated.

Etiology.—The *Bacillus icteroides* was discovered in 1897 by Sanarelli. This is a small bacillus from 2 to 4 μ in length, with rounded extremities. It is frequently united in pairs, and is actively motile, the motility being due to from four to eight lateral flagella. The organism is pleomorphous. It is readily stained by the ordinary anilin dyes, but is decolorized by Gram's method.

Cultivation.—Sanarelli succeeded in obtaining cultures upon the ordinary media, but the growth on the surface of agar is most distinctive. When incubated for twelve hours at 37° C. (98.6° F.) and then allowed to develop further at lower temperatures there will be found, first, semitransparent rounded colonies, and, later, enlargement of these with the formation of a thick white border, giving the appearance of a drop of sealing-wax. The characteristic growth is thus obtained in twenty-four hours.

Distribution.—Sanarelli found the bacillus in the various organs as well as in the blood. He succeeded in obtaining cultures in 58 per cent. of the cases studied. Failure in a large proportion of cases he attributed to the small number of bacilli present.

Pathogenicity.—The pathogenic *rôle* of this organism is becoming quite widely recognized. The discoverer succeeded in producing in animals lesions and symptoms very analogous to those of the human disease. The dog responded most satisfactorily. Injected into the veins of a dog there is active emesis, then hemorrhages throughout the body, and finally extensive fatty degeneration of the liver and kidneys. In one case extreme jaundice developed.

Other Micro-organisms.—Previous to Sanarelli's work a great variety of organisms had been described. Among others a bacillus by Richardson, a micrococcus by Finlay and Delgado, a bacillus by Gibier, and other organisms by Freire and Carmona and by Sternberg. None of these organisms appears to have importance, or to be the same as that discovered by Sanarelli. The organisms isolated by Havelberg about the same time as Sanarelli's appear to be of no importance.

Pathologic Anatomy.—The lesions of this disease are mainly those of the internal organs—liver and kidneys. In the liver extensive fatty degeneration leads to some swelling and light

color of the organ, and on section there may be mottled appearance due to the alternation of healthy and fatty areas. In the kidneys degenerative changes of the parenchyma and extravasation of blood are associated in varying proportions. The appearance may be that of an acute hemorrhagic nephritis, or more particularly that of degenerative nephritis. Hemorrhages in the mucous and serous surfaces are frequent, particularly extravasation of the mucosa of the stomach.

Pathologic Physiology.—The organism of yellow fever probably produces abundant toxin. Small numbers of the bacilli seem at times to give rise to violent symptoms. Sanarelli has claimed that antitoxic serum is obtainable from immunized animals. Recently an agglutinative reaction, like that of Widal for the typhoid germ, has been described.

MEASLES.

Measles, or rubeola, is an infectious and contagious disease in all probability due to some micro-organism. A number of micro-organisms have been discovered, but none as yet has been definitely proved to be the cause. Several observers (Canon and Pielicke, Czajkewski) have found a bacillus somewhat resembling that of influenza, but the matter is still unsettled. Doehle described a protozoan organism occurring in the blood.

SCARLET FEVER.

Scarlet fever, or scarlatina, is an infectious and contagious disease probably due to a micro-organism. A variety of organisms have been discovered in cases of scarlet fever, but none as yet has proved to be specific. The weight of evidence seems to suggest the pyogenic micrococci (streptococci) as probable etiologic agents. Protozoan organisms have also been described (Doehle).

MUMPS.

The bacteriology of mumps is uncertain. Charrin and Capitan isolated a number of organisms, mainly micrococci and motile bacilli. A number of other authors subsequently obtained similarly indefinite results. Laveran and Catrin in 1893 found a diplococcus.

WHOOPING-COUGH.

A short bacillus was discovered in the expectoration of pertussis by Afanassiew in 1887. He injected cultures of this into the trachea and lungs of dogs, and found that the animals became ill and died, after presenting convulsive cough with bronchitis similar

to that of whooping-cough. Wendt confirmed these results; but Ritter found a diplococcus in his cases, and Cohn and Neumann found small cocci, often arranged as diplococci or more rarely as short chains. Czaplewski and Hensel describe a bacillus resembling the influenza-bacillus, and believe that the organisms of Cohn and Neumann were identical with theirs. Others have discovered organisms similar to the ordinary pyogenic micrococci; and some have described protozoa in the blood.

TYPHUS FEVER.

A number of micro-organisms have been discovered in this disease, including strepto-bacilli (Hlava), small granular bodies growing to thread-like organisms (Thoinot and Calmette; Lewascheff), diplococci (Dubief and Brühl). Lewascheff has more recently concluded from a study of 158 cases that the micrococci of Dubief and Brühl, which have also been described by others, are the important agents, and proposes the name *Micrococcus exanthematicus.*

RABIES.

Hydrophobia is doubtless an infectious malady, but the bacteriology is still obscure. Micrococci and bacilli of different kinds have been described. Memmo isolated a form of blastomycetes, and claims to have produced the disease in dogs with pure cultures of this.

THE HEMORRHAGIC DISEASES.

The hemorrhagic diseases constitute a group of affections of probably quite divergent character, which, however, are similar in presenting hemorrhages in and from the mucous membranes, in the skin, serous surfaces, and in the deeper tissues or organs.

The general causes of hemorrhage must be considered in connection with these diseases. Among the causes capable of producing hemorrhages such as occur in the hemorrhagic diseases are *mechanical conditions*, as atheroma or other diseases of the walls of the blood-vessels; *toxic conditions*, such as poisoning by the venom of animals and by various blood-poisons, and probably obscure poisons produced in the course of anemic or other diseases; *infectious conditions*, such as occur in hemorrhagic variola, scarlatina, etc.; and *nervous conditions*, as are illustrated in the hemorrhages following injuries to the brain and those accompanying certain states of cerebral excitation.

Clinically the hemorrhagic diseases or purpuras may be classified as *primary* and *secondary*, the former occurring without any definite preceding disease; the latter being symptomatic of various

disorders. Among the primary there are: (1) *infectious forms*, including, with more or less probability, purpura, scurvy, and various forms of cryptogenetic sepsis; (2) *toxic forms*, as those due to drugs and venom of animals; (3) *mechanical forms*, as hemophilia. Among the secondary purpuras are: (1) *infectious forms*, as scarlatina, variola, and the like; (2) *mechanical forms*, as those due to cardiac and arterial diseases, or embolism; (3) *toxic forms*, as those resulting from intestinal auto-intoxications, jaundice, pernicious anemia, etc.; and (4) *nervous forms*, as those due to hysteria, diseases of the brain, etc.

The infectious purpuras interest us particularly in the present place. Various micro-organisms have been found in different forms of hemorrhagic disease. Kolb described a bacillus pathogenic for animals, which occurred in five cases of hemorrhagic purpura. Babes and Oprescu isolated a bacillus from one case of hemorrhagic septicemia, and others have found various micrococci, especially the streptococcus. It is not unlikely that many of the micro-organisms may assume a peculiar virulence and acquire the power to produce hemorrhages under certain circumstances.

In scurvy several micro-organisms have been described, but the one which has the best claim for consideration is that discovered by Babes, a delicate bacillus occurring in the gums. Streptococci were found in association with it.

RHEUMATISM.

Definition.—Acute articular rheumatism is probably an infectious condition; the nature of the infectious agent, however, is uncertain.

Etiology.—The manifestations of rheumatism agree very well with those of infectious diseases, and some of the lesions frequently complicating the disease, such as endocarditis, are invariably infective. The relationship between tonsillitis and rheumatism has been explained by some as that between primary and secondary disorder. It is supposed that the infectious agents effect an entrance into the body through the tonsils, causing primary tonsillitis and secondary general infection, with localization in the joints. In other cases it has been held that the organisms enter through abrasions of the skin or in other ways.

Guttmann, one of the first to maintain the infectious origin, described a Staphylococcus pyogenes flavus discovered in one of his cases. Sahli found an organism which he classified as Staphylococcus pyogenes citreus. He enunciated the theory that rheumatism represents a form of staphylococcic infection, the organisms, however, being of a low grade of virulence. They are not found abundantly in the exudations in the joints, as they remain fixed in the synovial tissues. Hence, they are difficult of discovery.

Other organisms, including various forms of bacilli, have been described.

Very recently Achalme has described a bacillus which he and others have found in a number of cases of acute articular rheumatism. It is a large bacillus resembling that of anthrax; sometimes it is motile; it stains well with anilin dyes and with Gram's stain; may have a capsule; and forms polar spores much larger than the bacillus. This organism is obligate-anaërobic, growing best in liquid media, in which it forms small bubbles of gas. Thioroloix claims to have produced typical symptoms in the rabbit; and the inoculation-experiments of others have given suggestive results. This bacillus was obtained from the blood in a number of cases; and from the pericardial fluid and blood in a state of purity in one case. The organisms have been found in sections of the heart-muscle and valves.

[For the pathologic anatomy of rheumatism, see Diseases of the Joints.]

MALTA FEVER.

Synonyms.—Mediterranean Fever; Gibraltar Fever; Febris Undulans.

Definition.—This disease has been described as a form of irregular fever occurring along the Mediterranean coasts. It has been regarded as an aberrant form of typhoid fever, but is probably independent and due to a special micro-organism.

Etiology.—The micro-organism discovered by Bruce, and designated Micrococcus Maltensis, is by many regarded as the specific cause. This is an oval micrococcus about $\frac{1}{3}\ \mu$ in diameter, occurring singly or sometimes in pairs, but never in chains. It has no motility of its own. It may be stained with ordinary solutions of anilin dyes, but not by Gram's method. It occurs abundantly in the spleen, but not in the blood. Pure cultures have been obtained, and inoculation in monkeys has seemed to give positive results. Malta fever is not contagious. The micro-organisms seem to enter the body through the respiratory or the intestinal tract.

Pathologic Anatomy.—The mucous membrane of the small intestine is red and the solitary follicles and Peyer's patches are sometimes swollen. The mucosa of the large intestine is generally dark red and presents small round or larger irregular ulcerations, from which intestinal hemorrhages occur. In some cases lesions of the ileum resembling those of typhoid fever have been described; but it is doubtful if the cases in which these occurred were Malta fever, and not typhoid. The spleen is enlarged and hyperemic.

Pathologic Physiology.—Malta fever is characterized by irregular febrile movements. The cause of this irregularity and the nature of the toxic substance generated in the disease are un-

known. Recently a serum-reaction, like that of Widal for typhoid fever, has been obtained with the serum and cultures of Malta fever.

BERI-BERI.

Definition.—This disease is an infection due to undetermined causes. It occurs in tropical and subtropical countries, and is characterized by muscular weakness, generalized muscle-pains, dropsy, and cardiac failure. The essential lesions seem to be degeneration and inflammation of the peripheral nerves.

Etiology.—Beri-beri occurs among young persons and usually affects numbers of people. It is most frequent along ocean coasts and great rivers, and is most prevalent during damp seasons of the year. It does not seem to be contagious.

Various micro-organisms have been described, including a number of bacilli and micrococci, as well as organisms resembling the malarial hematozoa. One observer (Taylor) was able to produce the disease in animals by the injection of blood from a diseased person.

Pathologic Anatomy.—Among the lesions observed are punctate hemorrhages in the serous surfaces; parenchymatous and fatty degeneration of the heart-muscle; enlargement of the liver and spleen. Degeneration and inflammation of the peripheral nerves are constant and important conditions.

CHAPTER VIII.

ANIMAL PARASITES AND DISEASES CAUSED BY THEM.

PROTOZOA.

AMŒBA COLI.

Description.—This organism, first accurately described by Lösch, is an ameboid body from 20 to 30 μ in diameter, consisting of a clear protoplasmic outer portion and a finely or coarsely granular protoplasm within (Fig. 107). It frequently shows vacuoles and sometimes a nucleus. It presents active ameboid movements when studied on a warm stage of the microscope; and frequently contains foreign bodies, such as bacteria, pigment-particles, and portions of blood-corpuscles or other cells.

In the movements of the organism pseudopodia are projected from some part of the periphery. These at first draw upon the clear peripheral zone, but after their formation the granuloplasm

flows into the projected pseudopods. When in unfavorable surroundings the organism undergoes a form of change called the *encysted state.* In this the body becomes spherical, and the wall is eventually stiff and firm and usually presents a double contour.

FIG. 107.—Amœba coli in intestinal mucus, with blood-corpuscles and bacteria (Lösch).

The division into a clear and a granular protoplasm is lost, the organism being uniformly granular.

Distribution and Pathogenesis.—The organism in question has been found abundantly in the stools of patients suffering from dysentery. It is readily detected in the necrotic particles or the mucus of the stools, and has also been found in the tissues of the bowel-wall adjacent to the dysenteric ulcers and abundantly in the liver-abscesses secondary to dysentery.

It has, however, been found in the dejections from cases other than dysentery, and even in the stools of healthy individuals.

The pathogenic importance of this organism cannot be positively established until cultures are obtainable. Thus far, attempts to secure pure cultures have failed. The injection of mucus containing the ameba into the rectum of cats and other animals has occasionally produced typical dysentery, but this does not prove the pathogenicity of the ameba. The regularity of the occurrence of the organism in certain forms of dysentery and its relations to the lesions are the strongest evidences in favor of its pathogenic *rôle.*

OTHER AMŒBÆ.

Several other amœbæ of lesser importance have been discovered. Among these are the *Amœba urinalis,* found in the urine in cases of cystitis, and several forms met with in the mouth, especially about the teeth.

HEMATOZOÖN MALARIÆ.

The organism which is now recognized as the cause of malaria is an animal organism of the protozoan group, the exact biologic position of which, however, remains undetermined. Most authors regard it as one of the sporozoa. It occupies the blood and the vascular channels of the various organs, deriving its nourishment, for the most part, directly from the blood-corpuscles. The mode of infection and the life-history of the organism outside the human body are unknown. It seems most probable that the organisms are conveyed to man through the air. Many clinicians, however, hold that the infection may be conveyed by drinking-water. Direct contagion does not occur, but it has been shown that the blood is infectious when introduced into the circulation of a healthy person. The drinking of the blood does not give rise to the disease. Certain external conditions are favorable or necessary to the development of the disease, and probably are important in fostering the development of the organisms outside the body. These external conditions are moist, marshy soil, atmospheric humidity, and high temperature. The disease occurs in the lowlands or bottomlands, and very rarely in high and dry ground. Extensive excavations and the like may cause the appearance of the disease or increase it, and, on the other hand, suitable drainage may cause its diminution or disappearance.

The Hematozoön.—Three forms of malarial parasites have been distinguished; and it is likely that these are three definite species, although some still maintain they are merely alterations of the same organism.

The Parasite of Tertian Fever.—Examination of the fresh blood of a patient some hours after a tertian chill shows in some of the red corpuscles small hyaline bodies, having ameboid movement and often assuming cross- or star-shapes. These are the so-called *plasmodia*. Later, the plasmodia have pigment about their periphery, and finally the amount of pigment may become considerable. During this time the organism grows and the red corpuscle becomes paler. Eventually the ameba may almost completely fill the corpuscle. At this stage, which occurs just prior to the paroxysm, *segmentation* begins. The pigment, which previously has shown active movements, collects toward the center and becomes motionless, and lines of radiate striation are formed in the organism, giving it a rosette-like figure composed of twelve to twenty parts. Segmentation proceeds until each of the segments becomes a small spherule. The corpuscle then bursts and the spherules or spores escape, probably to begin their cycle of development from the start by entering new red corpuscles as minute plasmodia. This cycle of development requires forty-eight hours.

The Parasite of Quartan Malaria.—This is similar to the last

named, but differs in the fact that the pigment-granules are much less abundant and coarser. The red corpuscle is not decolorized, as in the case of the tertian, but assumes a somewhat greenish hue. In about seventy-two hours segmentation occurs, six to ten segments and then spherules being formed.

The Parasite of Irregular Malaria.—In the irregular malarial fevers of the summer and fall (the estivo-autumnal fevers) the organism is smaller than in the other cases, and rarely presents much pigment. The plasmodium frequently presents itself as a ring-shaped body, highly refractive and with a shaded central part. A few pigment-granules may be seen, but rarely more. The organism itself does not become larger than about one-third the diameter of the corpuscle in which it occurs. The red corpuscle itself is greenish, as in the quartan variety. Segmentation is not observed in the circulating blood, though centrally placed pigment may be seen. The segmentation takes place in the spleen, bone-marrow, and other parts. The duration of the cycle of development is indefinite.

Other Types Assumed by the Malarial Hematozoa.—Besides the regular forms described there is a *flagellate variety*, which is seen only in the blood kept for a little while outside the body. This is formed by the projection of thread-like processes which have active thrashing-movements. The pigment of the body itself is in the central part and is actively motile. These ciliated hematozoa may be found in tertian or quartan fever, but especially in irregular malaria. Recent observations on the blood of birds, as well as the studies of Manson and Ross in malaria, seem to show that the formation of these flagellated bodies is important in the reproduction of the organism.

In the estivo-autumnal fevers a very curious form of the hematozoa is found; this is the *crescent form* described by Laveran. It occurs in cases of some weeks' duration, and is developed within the corpuscles; first, as a somewhat oval body, which becomes more and more crescentic, the pigment at the same time clumping in the center. The red corpuscle may entirely disappear, with the exception of a small portion seen in the concave part of the crescent as a mere shadow.

The Organism Outside the Human Body.—It has been impossible up to the present time to discover the malarial organism in soil or water, and only a few uncertain observations of its occurrence outside the body have been made. Recently Manson suggested that the mosquito is the probable carrier of the contagion.

Pathologic Anatomy.—The most important fact in malarial infection is the destruction that it occasions in the blood. Rapid anemia with liberation of the hemoglobin (hemoglobinemia) and the appearance of granular pigment in the blood are among the results. The pigment accumulates in the spleen, liver, bone-

23

24

25

26

27

marrow, and in other situations. Congestive enlargement of the spleen and, after long-continued attacks, cirrhotic changes may be observed. Thrombi of the capillaries and arterioles are not rare, and to these, in part at least, are due the focal necroses observed in the liver and elsewhere.

Pathologic Physiology.—The curiously paroxysmal seizures of malaria are probably the result of the liberation of toxic substances. The periodicity depends upon the duration of the cycle of development of the organism. A single group of tertian organisms cause a tertian fever (a paroxysm every other day). Infection with two groups of tertian organisms, maturing on alternate days, produces a quotidian fever (a paroxysm every day). One group of quartan organisms causes quartan fever (a paroxysm every third day); these groups (maturing on successive days) cause quotidian fever.

COCCIDIUM OVIFORME.

Description.—The coccidia are small bodies from 30 to 40 μ in length and from 15 to 20 μ in width, having a thick and rather glistening capsule. The body is filled with granular material, which is not rarely aggregated in the center. Outside the body sporulation takes place. The granular protoplasm divides into four rounded capsulated spores, each containing a granular resting-body lying in the concavity of a sickle-shaped daughter-spore. Sometimes endogenous sporulation is said to occur, the parasite simply breaking up into a large number of sickle-shaped bodies. The term *psorospermiæ* is applied to the rounded spores found in the coccidium (Fig. 108).

Occurrence and Pathogenesis.—The coccidium is a fre-

FIG. 108.—Coccidia from the human liver (Leuckart).

quent parasite of rabbits and certain other animals. It leads to the formation of yellowish nodules in the liver. It is an intracellular parasite, first invading the cells of the biliary passages and afterward the surrounding hepatic cells as well (Fig. 109). Less frequently it occurs in the intestinal tract, giving rise to nodular thickenings or ulcerations.

The parasite escapes from the body in the stools and then undergoes sporulation. Other animals are probably infected by ingestion of the spores or sporulating coccidia. Occasionally the disease decimates rabbits or guinea-pigs kept in confinement. The

animals become languid, lose their appetite, emaciate, and have fever. Later they suffer from convulsions, stupor, or coma, and die in this condition.

A few cases of coccidial disease of the liver have been observed in man. The lesions present themselves as cystic nodules springing from the bile-ducts, or less commonly as a diffuse involvement

FIG. 109.—Coccidia in the wall of the bile-duct and the adjacent hepatic structure of a rabbit.

of the liver with cirrhosis and causing jaundice. Coccidial lesions of the intestines have also been discovered in man, and less commonly invasion of the heart, of the kidneys, and other parts.

The close association of the organism with the lesions, and the number of organisms discovered in the tissues, justify the belief that it is the specific cause of the lesions.

The coccidium of the intestinal tract is generally smaller and the sporulation more rapid than that of the hepatic form. It was therefore supposed by Leuckart to be a special variety, and has been called *Coccidium perforans*. More recently this has been regarded as identical with the ordinary form.

ANIMAL PARASITES AND CARCINOMA.

The theory that carcinoma and other malignant tumors are due to some form of infection is by no means of recent origin. Bacteriologists sought to isolate micro-organisms without success; and later observers have turned their attention to certain structures supposed to be animal organisms.

In 1889 Thoma found in the protoplasm and nuclei of carcinoma-cells bodies which he regarded as coccidia; and about the

same time Malassez and Albarran found similar structures in the cells of an epithelioma of the maxilla. Darier found bodies of the same kind in Paget's disease of the nipple, and many subsequent investigators have described more or less similar formations.

Among these supposed protozoan organisms some are *intranuclear*, some *extranuclear*, and some wholly *extracellular*. Among the intranuclear and extranuclear cell-inclosures Sjörbring described round bodies which tend to grow and eventually sporulate, forming cystic bodies containing twenty to thirty spores (spore-cysts). These structures resemble the parasites of silkworm disease, and are classified by Sjörbring as microsporidia. Sudakewitsch and others have described bodies more closely resembling coccidia in their sharp, double contour and the presence of peculiar, sometimes sickle-shaped, bodies within. Podwyssozki and Sawtschenko described forms differing from coccidia in the absence of a distinct capsule, and resembling rather the amebæ, such as those occurring in the blood of birds and in malaria. The views of these authors, particularly Sawtschenko, have, however, undergone some modification in their several contributions. Ruffer, Plimmer, and Walker described structures occurring only in the protoplasm of the cells, and resembling coccidia, but forming neither spores nor sickle-shaped bodies, but multiplying by direct division (Fig. 110). Many of the investigators lay stress upon the behavior of the supposed parasites

a *b* *c* *d*

FIG. 110.—Inclusions in cancer-cells: *a* and *b*, early stages of "parasitic" bodies; *c*, late stages, showing division by segmentation; *d*, cancer-cell containing leukocytes (Ruffer).

toward stains. Thus Ruffer and his collaborators point out that the nuclei of their parasites do not receive basic stains like cell-nuclei, but the acid-stains, and the body of the parasite is scarcely at all stained. This point, however, has certainly been overestimated as an indication of the parasitic nature of the bodies. Degenerated cells notoriously vary from normal ones in this respect. The supposed spores of Sjörbring and others are very probably products of degeneration, as Ruffer and others contend; and it has not yet been shown by anyone that all of these supposed parasites are not degenerated leukocytes or epithelial cells included within the cancer-cells or simple products of cell-degeneration.

Some authorities have advanced a theory quite different from the above, holding that the cancer-cells themselves are parasitic organisms. Korotneff distinguishes three kinds of organisms in carcinoma: amebæ, coccidia, and gregarinidæ. The ameboid form, which he calls *Amœba cachexica*, has a granular protoplasm and a clear nucleus. It is actively motile, and may leave the epithelial cells to enter the connective tissue. After establishing itself it becomes encysted, the nucleus breaking up and the protoplasm becoming more dense. Zoöids and sporozoöids result, the former going on to the formation of a gregarina (Rhopalocephalus carcinomatosus) (Fig. 111), or a coccidium, the latter forming new amebæ. Some of the structures figured by Korotneff are undoubtedly merely cancer-cells. A few authors claim to have found parasites of various kinds in the blood of cases of carcinoma.

Fig 111.—Rhopalocephalus carcinomatosus (Korotneff).

A close study of the so-called parasites of carcinoma shows that they are probably the result of cell-degenerations. This is evident in part from the fact that they are most abundant in degenerated carcinomata or in degenerated areas of carcinomata, and from the very divergent character of the forms described. Furthermore, similar structures occur in other tumors, some of them eminently benign, and even in ordinary inflammatory tissue. Russell, in 1890, described certain rounded bodies that stain intensely with fuchsin, and occur in or between the cells. These "fuchsin-bodies" are certainly not parasites, but cell-productions.

Recently it has been urged that certain *blastomycetes*, resembling the ordinary yeast-fungus, if not identical with it, are the actual cause of cancer, and that many of the bodies formerly regarded as protozoa are blastomycetes. This view lacks confirmation.

ANIMAL PARASITES AND MOLLUSCUM CONTAGIOSUM.

Definition.—Molluscum, or Epithelioma Contagiosum, is an infectious disease of the skin marked by the appearance of white and pink papules.

Etiology.—The cause of this disease is, no doubt, a micro-organism of some sort. Its contagiousness is evidenced by the occurrence of epidemics in houses or asylums, by the occurrence of accidental inoculations, and by direct experiments. The incubation-period seems to be a long one—sometimes extending to several months. The lesions have been found to contain small bodies whose resemblance to coccidia was long ago pointed out by Virchow. It is uncertain whether these are really parasites or

epithelial degenerations. Some authors are positive regarding the parasitic nature of the bodies; others are equally convinced of their nonparasitic character.

Appearances.—The disease occurs as single or, more frequently, multiple papules, at first quite small, but later becoming nodules of considerable size. In the larger a central depression or umbilication is seen, and on pressure cheesy matter may be expressed from this. After reaching about 3 or 4 mm. in diameter they remain stationary, or undergo softening and suppuration. In exceptional cases the tumor may reach the size of a small orange.

Seats.—The disease occurs on the face, neck, chest, genitals, or sometimes scattered over the whole body, sparing only the palms and soles. The lesions have occasionally been found on the mucous membranes.

Structure.—Microscopically the lesions of this disease are found to consist of epithelial proliferations having a somewhat acinous arrangement, a hair-follicle occupying the center of each group of cells. The interior of the nodules is filled with soft, cheesy matter which may be expressed. The epithelial cells are arranged in several layers, the upper being normal cells with large nuclei, the deeper layers showing beside the nucleus small droplets, or rounded spherules, the so-called *molluscum-bodies.* These bodies grow in size, and may be so large as to fill the cell, pushing the protoplasm and nucleus to one side. In this process the cell-wall and protoplasm become horny, and practically the entire body consists of the enlarged molluscum-corpuscle. Certain granulations and more or less definite segmentations within these bodies have been described as sporulating conditions. The nature of these bodies is very doubtful; they may be coccidia, gregarinidæ, or ameboid bodies; but they may also, as some contend, be the results of epithelial degenerations.

VARIOLA AND VACCINIA.

A number of bacteria have been described from time to time in these diseases, and various micrococci in particular have been found in the pustules, but none of these can be considered as specific. Several bacilli have been recently described.

In 1887, Pfeiffer and van der Lœff independently described a protozoan parasite of the order sporozoa, which occurs in the cells of the rete. This organism was found in variola as well as in vaccinia. Pfeiffer, Guarnieri, and other investigators found that by inoculation of the cornea of rabbits large numbers of the supposed parasites make their appearance in the epithelial cells. These organisms are rounded bodies lying in the protoplasm of the cells, sometimes singly, sometimes in groups of two or three. Slow ameboid

movements are visible and the organisms present one or more nuclei. Spore-formation has been observed by several investigators. Guarnieri suggested the name *Cytoryctes variolæ seu vaccinæ.* The nature and the significance of these supposed organisms have not yet been positively determined. Some authorities look upon them as products of cell-degeneration.

Secondary infections with various micrococci or other organisms are common in small-pox and vaccination, and may play an important part in pustulation, and in the more definite complications, such as septicemia, pneumonia, hemorrhagic septicemia, erysipelas, and the like.

VARICELLA.

The etiology of chicken-pox is even less definitely determined than that of small-pox. Pfeiffer discovered the same organism described by him in vaccinia and variola. Bacteria of one sort or another have been occasionally found.

MEASLES, SCARLET FEVER, AND OTHER DISEASES.

Certain investigators have discovered bodies having some of the appearances of protozoa in measles, scarlet fever, pernicious anemia, leukemia, sarcomata of various sorts, and in a number of other diseases. These observations, however, do not merit further discussion in this place. Future investigations must decide whether they have been accurate or not.

CERCOMONAS INTESTINALIS.

This organism is a pear-shaped body with a sharp anterior extremity provided with a delicate short cilium. The broader posterior end is provided with a long, tail-like flagellum. A larger and a smaller variety have been described (Fig. 112). The

FIG. 112.—Cercomonas intestinalis: *a*, larger, *b*, smaller variety (Davaine).

former is the variety usually found, and is from 10 to 12 μ in length. A minute oval aperture has been found at the anterior extremity.

Significance.—The organism has been discovered in great numbers in various diarrheal conditions, especially in cholera. It is not known to have pathogenic powers.

CERCOMONAS COLI HOMINIS.

A single observation of this organism was made by May. The body of the parasite was not quite the size of a red corpuscle; rather granular and glistening and slightly greenish. It was spindle-shaped, the anterior end more blunt than the posterior. Four cilia were found attached to this end, and upon one side of the organism was seen an undulating membrane. In the same case smaller bodies, less developed and probably younger parasites, were discovered. The patient suffered from carcinoma of the stomach and chronic diarrhea.

TRICHOMONAS INTESTINALIS.

This organism is pear-shaped; from 10 to 15 μ in length and 7 μ in breadth (Fig. 113). The anterior end is blunt; the posterior end is prolonged into a sharp, tail-like projection.

FIG. 113.—Trichomonas intestinalis (Zunker).

The body is granular and contains one or two bodies resembling vacuoles. Near the anterior end at one side may be seen a row of ten or twelve cilia, which give the organism active motility. It has also ameboid movements.

Significance.—This organism has been found in cases of diarrhea, but its significance is doubtful.

TRICHOMONAS VAGINALIS.

This form is rather smaller than the last, with an attenuated caudal end and a more blunt anterior portion, provided with three flagella; there is a lateral undulating membrane with six or seven short cilia.

Significance.—The organism has been found in cases of vaginitis due to various causes, but also in the absence of evident disease.

OTHER FORMS OF TRICHOMONAS.

Sternberg has found several forms in the mouth, and especially about the teeth. These have been termed Trichomonas flagellata, Trichomonas caudata, and Trichomonas elongata.

BALANTIDIUM COLI.

Balantidium or Paramecium coli is a rounded body from 7 to 10 μ in length and slightly less in breadth (Fig. 114). It is surrounded by a coat of cilia closely set. There is an oral aperture at one end and an anal opening at the other. The substance of the parasite is granular, and contains a nucleus and two contractile vacuoles besides various foreign matters. Encysted forms with a thickened capsule have been described.

FIG. 114.—Balantidium coli (Malmsten).

Significance.—The hog is the natural host of this parasite. Man is probably infected through drinking-water or contaminated food-stuffs. It is found particularly in northern countries of Europe, and occurs in cases of diarrhea principally involving the large intestine. Chronic catarrhal inflammation and dysenteric lesions have been described. The organism is probably irritating, but whether pathogenic or not is unknown.

MEGASTOMA ENTERICUM.

This organism in its active state is irregularly pear-shaped, and presents at its broad end a cup-shaped depression situated obliquely at one side (Fig. 115). On the anterior edge of the depression are

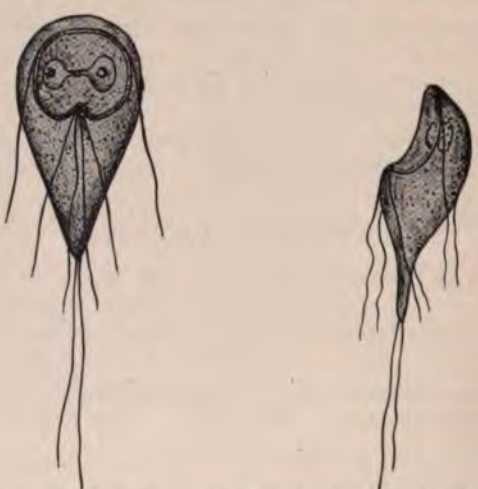

FIG. 115.—Megastoma entericum from the intestines of a mouse (Grassi and Schewiakoff).

attached two long cilia, and at one point of the posterior lip are two pairs of cilia. In the base of the depression are seen two vesicular structures (nuclei) united by a band. The protoplasm

is finely granular and is surrounded by a delicate capsule. When free the organism is capable of rather rapid motion, but in the intestine it is attached to the epithelial cells by its cup-shaped depression. The organism exists in this form in the duodenum and jejunum. In the colon or other unfavorable situations it forms oval encysted bodies showing the nuclei and cilia within.

Significance.—Megastoma is a frequent parasite of the mouse, but has been found in the intestines of other animals, and occasionally in man. It has been found especially in chronic diarrheal conditions, and at times appears in the stools in immense numbers. No definite lesions have been found, and the pathogenicity of the germ is uncertain.

CESTODES OR TAPE-WORMS.

General Biology.—The life-history of the different forms of tape-worms is much the same. They have two states of existence, the *larval*, which is generally found in one species of animals, and the *adult state*, usually occurring in another species. It is supposed that in the case of one or two tape-worms an intermediary host is unnecessary, but this is doubtful. The adult worm, or tape-worm, occupies the intestinal tract of man or the

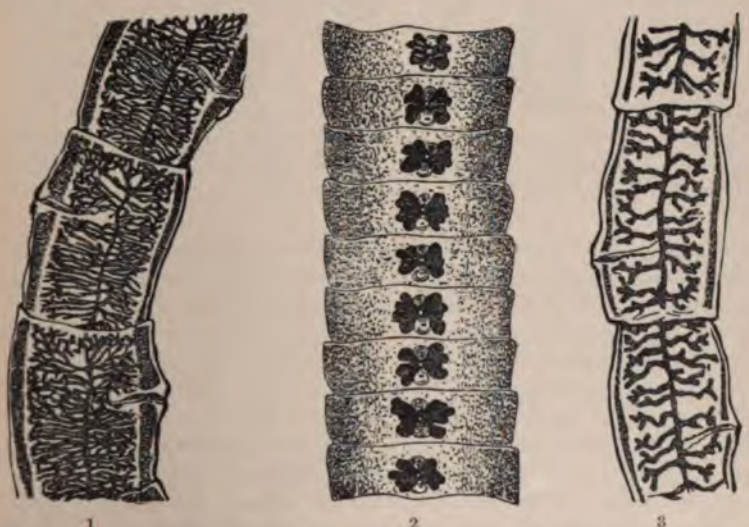

FIG. 116.—Segments of (1) Tænia saginata, (2) Bothriocephalus latus, and (3) Tænia solium, showing arrangement of uterus.

lower animals. It consists of a *head*, by which the worm fastens itself to the mucous surface; and after the head, a *neck* of greater or less size and length, and a body consisting of separate *links or*

proglottides. The latter represent complete organisms, containing a complicated genital apparatus, hermaphroditic in nature, which produces numerous eggs. The eggs are partly discharged from the segments in the intestinal tract through a *genital pore*, but especially escape into the outer world when the ripe segments are separated from the body of the worm, are discharged from the bowel, and subsequently rupture and scatter the contained ova (Fig. 116). The *egg* or *ovum* encloses an immature larval organism, which, when received into a suitable host, penetrates the walls of the stomach or intestine and finds its way to the muscles or organs, where it imbeds itself and forms the well-known *measles* (see Figs. 116 and 117). These are seen with the naked eye as small cyst-

FIG. 117.—Eggs of various worms found in the alimentary canal of man: A, Ascaris lumbricoides; B, C, Oxyuris vermicularis; D, Trichocephalus dispar; E, Anchylostoma duodenale; F, Distoma hepaticum; G, Distoma lanceolatum; H, Tænia solium; I, Tænia saginata; K, Bothriocephalus latus; × 400.

like bodies lying between the muscle-fibers. They contain a *scolex* or head, like that of the adult-worm, inverted into a sac filled with clear, watery liquid. When the measles or *cysticerci* occur in hollow cavities, such as the ventricles of the brain, they may reach considerable size. They differ somewhat in different forms of tape-worm, as will be described in connection with the individual species. When flesh infested with larval tape-worms is eaten by man or some suitable animal, the cysts are dissolved and the scolex fastens itself upon the mucous membrane of the intestine. The body of the worm is then slowly or rapidly formed.

Man is the host of tape-worms of adult or of larval type; most frequently the former. In one case, the Tænia echinococcus, only the larval worm occurs in the human body, in the form of hydatid cysts.

TÆNIA SOLIUM.

This form occurs in the adult state in man as a worm two or three meters in length; and in the hog or rarely in man in its larval condition. The head is about the size of a pin-head and very dark. Anteriorly it has a rostellum armed with a double row of from twenty-six to thirty hooklets. At the sides of the head are four suckers (Fig. 118). Attached to the head is a neck of thread-like appearance, which terminates in the immature segments of the anterior part of the body. The segments at first are broad and short, but become longer in proportion to the breadth toward the posterior end. The sexually mature segments are found at the middle and the posterior end of the worm. They contain a uterus consisting of a median tube and six to twelve lateral branches (Fig. 116). The genital pore is found at one side of the segment, irregularly alternating in successive proglottides. The eggs, which may be squeezed from the segments or obtained free in the feces, are rather oval or spherical, from 30 to 35 μ in diameter, and consist of a peripheral striated zone and a central granular portion, showing indistinctly six lines representing hooklets (Fig. 117). Groups of segments may be discharged from time to time, but this is not frequent; the discharge of single segments is less frequent. The proglottides have independent movement, and may sometimes be seen to move about upon the bed-clothes.

FIG. 118.—Head of Tænia solium (Mosler and Peiper).

The Larval State in Man.—When the ova are taken into the stomach the shell is digested and the embryo with its six hooklets is set free. This penetrates the wall of the stomach or intestine, and in some uncertain manner reaches the muscles or organs, where it effects a lodgement. The hooklets are discarded and a little cyst containing clear liquid is formed, and at one point may be found a bud-like projection into the sac. This develops a scolex or head, which eventually becomes identical with the head of the fully formed worm. The cyst may be surrounded by a wall of reactive connective tissue. The duration of this process of formation of the *cysticercus* varies somewhat (five to ten or twelve weeks). The size of the cysts in the muscles varies from minute points to that of a pea. In the ventricles of the brain the cysticerci may be as large as a small cherry. Occasionally compound or *racemose cysticerci* are met with.

Among the seats of special interest are the brain, the muscles,

especially the peripheral muscles, tongue, and heart-muscle, and the subcutaneous tissues.

The Adult Worm in Man.—When measled meat (hog, occasionally that of deer, sheep, and other animals) is eaten in insufficiently cooked form by man the capsules of the cysticerci (Fig. 119) are dissolved, the scolex attaches itself to the mucous membrane of the small intestine, and the worm is developed. Usually there is but one worm; occasionally several occur in the same case. The worm may remain in the intestine for years, despite repeated efforts to dislodge it. In other cases it is spontaneously discharged. Reverse peristalsis may cause portions to be carried to the stomach, whence they may be discharged by vomiting.

FIG. 119.—Measled pork; two-thirds the natural size (Leuckart).

Geographical Distribution.—The Tænia solium is an exceedingly rare parasite in America. It seems to be more common in certain parts of Europe.

TÆNIA SAGINATA.

This form is the common tape-worm of man. It is larger than the preceding form, being from four to eight meters in length. The head is large (2 mm. broad), cuboidal, and provided with four suckers. There is an abortive rostellum, but no hooklets (Fig. 120). The neck is short, and the segments rapidly become

FIG. 120.—Head of Tænia saginata (Mosler and Peiper).

FIG. 121.—Cysticercus Tæniæ saginatæ; natural size (Leuckart).

broader than long, but in the posterior half of the worm, where the sexually mature proglottides are found, the segments are longer than broad. The uterus is formed like that of the Tænia solium, but the lateral branches are more numerous (twenty to thirty, and

often dichotomously branched) (Fig. 116). The eggs are rather more oval and larger than those of Tænia solium, but otherwise closely resemble the latter.

The larval form, or cysticercus, occurs in the ox and sometimes in the giraffe. The measles are found in the muscles, liver, lungs, and occasionally in other organs (Fig. 121).

The adult form occurs only in man, and occupies the small intestine. The presence of the worm does not seem to occasion any definite disease of the intestines, except in rare cases, when a number are found present in a coiled mass, or when one worm is similarly coiled. This may cause intestinal obstruction, and possibly in exceptional instances rupture of the bowel.

The symptoms ascribed to tape-worms are some of them doubtless reflex; but it is noteworthy that they are often absent until the patient discovers segments in the stools. (Further reference to possible pathologic results is made in the discussion of Bothriocephalus latus.) It is an exceedingly common parasite in certain countries (Africa and the East), but is more or less commonly found in all parts of the world.

Fig. 123.—Tænia nana, much enlarged (Mosler and Peiper).

TÆNIA NANA.

This form, sometimes called the *dwarf tape-worm*, in its adult state is about 2.5 cm. in length (Figs. 122 and 123). It has a rounded head, with a rostellum that may be protruded or retracted and that bears a single circle of twenty-two to twenty-seven hooklets. The mature segments of the posterior end of the worm have a yellow color. The genital pore is on the same side in all the segments. The eggs are oval in shape, whitish and transparent; they are from 47 to 48 μ long and 38 to 39 μ broad.

Fig. 122.—Tænia nana, about natural size (Mosler and Peiper).

The intermediary host of this form is not certainly known, but is supposed to be some form of insect or snail. The adult parasite alone occurs in man. The head attaches itself deeply in the mucous membrane of the bowel and may cause considerable local disturbance. There are usually sev-

eral or many worms associated; sometimes there may be several thousands.

TÆNIA ELLIPTICA.

FIG. 124.—Tænia elliptica (Mosler and Pelper).

This form is identical with *Tænia cucumerina*. It is a common parasite of dogs and cats. The length is from 15 to 30 cm.; the head is provided with a rostellum bearing sixty hooklets ranged in four rows; the rostellum may be protruded or retracted. At the junction of the segments there is a considerable contraction of the diameter of the worm, giving the body a markedly linked character (Fig. 124). The mature segments have a reddish-brown color from the presence of the eggs. Each proglottide has a double sexual apparatus with a genital pore at each side. The intermediary host is probably the louse of the dog and occasionally the flea. The adult worm usually occurs in numbers in the intestinal tract, and in some cases seems to produce inflammatory disturbances.

TÆNIA FLAVOPUNCTATA.

This form (probably identical with Tænia diminuta) is from 20 to 30 cm. in length; the head is elongated and verges gradually into the neck. The suckers are small, but there is neither rostellum nor hooklets. The segments are marked by a yellowish spot which represents the male genital organs.

TÆNIA MADAGASCARIENSIS.

This form is from 25 to 30 cm. in length; the head is marked by four large suckers and a rostellum bearing hooklets.

OTHER FORMS OF TÆNIA.

Besides these more or less satisfactorily described forms, a number of uncertain varieties have been reported, such as the *Tænia tenella*, *Tænia Algeriana*, etc.

TÆNIA ECHINOCOCCUS.

The Tænia echinococcus in its adult form occurs in the intestinal tract of the dog, the larval condition occurring in man and in some of the lower animals. The mature worm is about 4 or 5 mm. in length, and consists of four segments (Fig. 125). The head, which constitutes the first, is provided with four suckers and a rostellum bearing fourteen to twenty-five hooklets in a double

row. The second segment is about the breadth of the head, but somewhat shorter. The third is considerably larger; and the fourth is the largest of all, constituting about one-half or two-thirds of the entire worm. The uterus consists of a median portion with few lateral branches. The eggs are oval, from 17 to 30 μ in diameter, and the shell is rather thinner than in the eggs of other tape-worms.

The adult worm occurs in great numbers in the small intestine of the dog. It is also found in the wolf and fox, and occasionally in other animals.

FIG. 125.—Tænia echinococcus; enlarged (Mosler and Peiper).

The Echinococcus Cyst.—This term is applied to the structure in which the larval worm is embedded. Three varieties have been distinguished.

(*a*) **Echinococcus Scoliciparens.**—When the eggs reach the stomach of man the embryo is freed and penetrates the mucous membrane. It is carried by the blood or lymphatic stream to the liver or other organs, where it develops an *echinococcus-cyst* (Fig. 126).

FIG. 126.—Echinococcus-cyst of the liver (from a specimen in the Museum of the Philadelphia Hospital.)

The wall of the cyst is composed of two layers, an outer cuticular and an inner parenchymatous, granulocellular layer. The parenchymatous layer is important as a budding or brood-membrane. After some weeks there may be seen upon its surface small buds or projections, which later become hollowed by a central excavation and form a small cyst; secondary budlets spring from the surface of this and gradually form embryonal heads or scolices (Fig. 127). When mature these are retracted or inverted into the cavity or cyst of the original bud. In this manner a large number of heads are formed upon the inner wall of the original

echinococcus-cyst, the cavity of the cyst at the same time increasing in size and being distended with characteristic liquid. This is a clear fluid, having a specific gravity of from 1009 to 1015 and a neutral or alkaline reaction, and containing no albumin or only traces, but a considerable quantity of chlorid of sodium. Sugar is sometimes found in the fluid.

FIG. 127.—Formation of buds upon the parenchymatous layer (Leuckart).

(*b*) **Echinococcus Hydatidosus.**—Besides this form of simple cyst with buds attached to the inner wall, there are cases in which daughter-cysts and even granddaughter-cysts are formed. The daughter-cysts are found within the original cyst, and are probably produced by cystic degeneration of the buds already described; and possibly in some cases by simple separation of the buds. They are variable in size, sometimes becoming as large as a nut or egg, and when granddaughter-cysts are contained within them the size may be even greater. To this form the term *Echinococcus hydatidosus* or *Echinococcus endogenes* is applicable.

In a subvariety of this form secondary cysts are produced outside the original wall. These are formed by a process of softening in the cuticular wall, with gradual projection of the parenchymatous layer toward the exterior and eventual rupture, with formation of secondary cysts outside.

(*c*) **Echinococcus Multilocularis.**—In a third form of echinococcus-disease there are numerous small cysts, from the size of a grape-seed to that of a pea, embedded in connective tissue, and altogether forming a more or less definite tumor-mass. On section this presents an alveolar appearance, the cysts containing somewhat gelatinous material. Careful examination of the inner walls of the small cysts shows them to contain pigment and calcareous particles. Scolices, however, are absent for the most part,

FIG. 128.—Echinococcus multilocularis (Luschka).

the cysts being generally sterile. The term *Echinococcus multilocularis* is applied to this variety of disease (Fig. 128). Its formation is explained by the assumption that there are secondary pro-

liferations in an outward direction from the original cyst, rather than a deposit of large numbers of ova or embryos. The whole mass presents the appearance of a tumor, and not rarely central necrosis and softening occur as in tumors.

Echinococcus cysts may continue to grow until they have reached huge dimensions without undergoing any secondary changes. In other cases the parasite may die and the growth may cease, or active proliferation of the tissues around the cyst may lead to early destruction. In still other cases suppurative change occurs in the cyst or its wall. In all cases when the cyst reaches a certain size the tissues around produce a connective-tissue capsule of greater or less thickness. When the parasite dies inspissation of the liquid occurs, and it may eventually disappear or be converted into a thick whitish material; the cyst-walls and the connective-tissue capsule at the same time shrivel and present peculiar concentric lamellations that are very characteristic. Eventually calcification of the wall of the cyst and to a certain extent of its contents takes place.

Seats.—Echinococcus cysts are most frequent in the liver. They also occur in the lungs, kidneys, spleen, and omentum, and less frequently in the brain or other parts of the nervous system. The pathologic effects are produced by direct mechanical pressure.

The geographical distribution is extensive, but the disease is common only in restricted localities, especially in northern countries (north of Europe, Iceland).

BOTHRIOCEPHALUS LATUS.

The Bothriocephalus latus is the largest tape-worm of man, reaching the length of from 5 to 9 m. The head is flattened and club-shaped and presents two groove-like suckers at its sides (Fig. 129). The neck is thin and gradually increases in diameter. The ripe segments are quadrate, and are distinguished by a rosette-like formation of the uterus, which is plainly visible in the center of each proglottid (Fig. 116). The genital pore is upon the flat surface of the segment and always upon the same side of the worm. The eggs are oval in shape and enclosed in a shell presenting a hinged lid at one pole. The intermediary host is some form of fish, most frequently the pike. The eggs first undergo a certain amount of development in water, the embryo becoming free and floating about or being propelled by a ciliated outer covering and then entering the digestive tract of fish.

FIG. 129.—Head and neck of Bothriocephalus latus (Leuckart).

The **geographical distribution** is comparatively restricted.

It is frequent in certain northern countries, as in Sweden, and in parts of central Europe, especially in Switzerland. It is only occasionally met with in America in immigrants.

Pathologic Physiology.—Local disturbances of the intestines are not observed; but persons harboring Bothriocephalus sometimes suffer from profound anemia. This has been attributed to poisonous substances elaborated by the worm, or resulting from decomposition of its segments. Similar anemia occasionally accompanies other forms of tape-worm.

BOTHRIOCEPHALUS CORDATUS.

This variety is much smaller than the last, the maximum being from 1 to 1.25 m. The head is short, broad, and heart-shaped, and the suckers are placed upon the flat surface. The uterine structure differs from that of Bothriocephalus latus in being narrower and more elongated, and also in having lateral branches. The body of the worm contains granular calcareous matter.

BOTHRIOCEPHALUS CRISTATUS.

This form is about 3 m. in length, and is distinguished by two crest-like projections upon the head. These are covered with numerous small papillæ. There are no definite suckers, and the head contains abundant granular calcareous matter.

BOTHRIOCEPHALUS LIGULOIDES.

This variety occurs only in the larval form in man. It has been found in the region of the loins and in the tissues about the eyes. The head of the worm is distinguished by a papilla-like projection.

NEMATODES, OR ROUND-WORMS.

ASCARIS LUMBRICOIDES.

The Ascaris lumbricoides, or ordinary round-worm, is one of the most frequent intestinal parasites. The male may reach a length of 25 cm. and a thickness of 2 to 4 mm.; the female is longer, up to 40 cm., and thicker, up to 5 or 6 mm. The body of the worm is brownish or sometimes pinkish in color, and presents parallel ridges or rings somewhat like those of the earthworm. The head is provided with three rounded prominences or lips, between which the mouth is placed (Fig. 130). The male shows two chitinous spicules at the cloaca. The eggs of the worm are produced in great numbers; they are covered with a tough shell, and surrounding this is a clear material in an irregular mass. The contents of the eggs consist of a granular material, sometimes showing the linear outlines of an embryo.

The ascaris develops in man from swallowing of the eggs in infested drinking-water or food. The parasites may be present singly or in numbers. They occupy the small intestine, but frequently migrate, entering the gall-ducts, the stomach, the esophagus, and even the larynx or nasal cavities. They may give rise to violent symptoms by obstruction of these passage-ways, or when in numbers or united in masses even intestinal obstruction may be caused. Occasionally abscess-cavities containing lumbricoids are found in connection with ulcerations and perforation of the intestines. These abscesses were believed by older authors to be caused by the worms; at the present time it is more generally held that the worms play no important part, their presence being due only to their coincidence in the intestine.

FIG. 130.—Ascaris lumbricoides: A, female; B, male; C, egg, magnified 300 diameters; b, head, magnified (after Perls).

ASCARIS MYSTAX.

This form, which is common in cats and dogs, is rarely met with in man. It is much smaller than the ordinary round-worm, the male reaching a length of 45 or 60 mm., and the female 120 or 130 mm. The head is distinguished by two lateral wing-like projections composed of chitinous material.

ASCARIS MARATIMA.

This form has been observed but once, and the female alone was found.

OXYURIS VERMICULARIS.

The oxyuris, seat-worm, or pin-worm, is one of the commonest parasites of man. The male is 2.5 to 5 mm. in length; the female, 10 to 12 mm. (Fig. 131). The posterior end of the male is blunt and curved upon itself; in the female it is elongated. The eggs of the oxyuris, which are produced in great numbers, are oval or elliptical and about 5 μ long. The embryo is visible within as a lobulated body. The parasite is developed directly from the eggs. When these are swallowed the outer coating is dissolved in the stomach and the embryos escape, to reach their full development in the small intestine. The impregnation occurs in the small intestine and within a short time after the swallowing

of the eggs. After impregnation and ripening the female parasites move toward the rectum and may be discharged, or may leave by their own movements. The life of the worm is short, but there is always the possibility of reinfection.

FIG. 131.—Oxyuris vermicularis: *a*, female; *b*, male (Mosler and Peiper).

Oxyuris is especially common in childhood. It is probable that the worms sometimes cause inflammatory troubles. In cases in which they accumulate in numbers a form of verminous diarrhea may be produced. In female children vaginitis frequently results from the migration of the parasites into the vagina.

TRICHINA SPIRALIS.

The Trichina spiralis occurs in its larval form in the muscles or organs of man and in the lower animals; in the adult form it is found in the intestines of man or animals.

The adult male is about 1.5 mm. in length and 0.14 mm. in thickness. At the posterior end there is a retractile cloaca flanked by two projections. The female is 2 to 4 mm. in length and 0.6 mm. in thickness. The eggs are provided with a very thin shell, and the embryos escape from this within the uterus. They are produced in immense numbers. The young embryos found in the intestinal tract are from 0.1 to 0.16 mm. in length, the anterior end thicker than the posterior. In part they escape with the feces, and die; the greater part penetrate the intestinal wall and are carried to various parts of the system, embedding themselves especially in the muscles, where they undergo further changes. Here the organism coils itself and becomes surrounded with a capsule, which is at first transparent, but may subsequently undergo calcareous change and become opaque (Fig. 132).

FIG. 132.—Trichina-capsule with its connective-tissue covering: *a*, early stage; *b*, calcified (Leuckart).

Trichinæ are acquired by man by eating improperly cooked ham. The capsules are digested and the larval trichinæ set free. In the small intestine they reach their maturity in about three days, discharging the embryos, some of which die or escape with the feces, while others bore their way into the mucous membrane. They are disseminated throughout the body by their own migrations or with the lymph- and blood-streams.

The favorite seat is the striated muscle-tissue, and they lie

within the muscle-bundles themselves or less frequently between them. They reach their destination in ten days after the primary invasion, but subsequent crops are deposited as the young continue to mature in the intestines. In two or three weeks they begin to become encysted in the muscles.

When the embryos are liberated in the stomach and intestines they occasion violent gastro-intestinal irritation, with vomiting, diarrhea, and often more or less pronounced collapse. In their later migration the worms set up intense muscular pains of rheumatoid character, with edematous swelling and fever.

Trichiniasis is common in all parts of the world, but has been largely reduced by greater care in the cooking of pork.

ANKYLOSTOMA DUODENALE.

The Ankylostoma duodenale, or Dochmius duodenalis, is a cylindrical worm, the female being from 7 to 16.5 mm. in length; the male, from 7 to 11.2 mm. The head is rounded, and is armed with six sharp, hook-like teeth. The female is usually of a brownish or reddish color, due to absorption of coloring-matter of the blood. The eggs are easily distinguished, being elliptical-shaped, from 0.056 to 0.063 mm. in length and 0.036 to 0.04 mm. in thickness. The shell is separated from the contents, and the latter have a granular appearance, are brownish, and in the state of segmentation. The eggs may appear in the stools in great num-

FIG. 133.—Anchylostoma duodenale: *a*, male, natural size; *b*, female, natural size; *c*, male magnified; *d*, female magnified; *e*, head, greatly magnified; *f*, eggs (von Jaksch).

bers. The embryo is fully developed outside the body, and entering the stomach and intestines of man there undergoes full development (Fig. 133).

The adult worm occupies the small intestine. It may be

present in small or large numbers, and is usually rather firmly attached to the mucous membrane. Changes in the latter, however, are not pronounced.

Patients harboring this parasite frequently become intensely anemic. It was this parasite which was found in many cases of Egyptian chlorosis, and it is the same organism that produced the intense anemias (pernicious anemia) of the laborers engaged in building the St. Gotthard tunnel.

ANGUILLULA INTESTINALIS AND RHABDITIS STERCORALIS.

The Anguillula intestinalis occupies the intestinal tract and the ducts communicating with it. It is an actively motile, cylindrical organism about 1 mm. in length, the male somewhat smaller than the female. In the latter the posterior extremity is drawn out to a fine point and straight; in the former it is thicker and curled upon itself. Besides this distinction the male bears two spicules projecting from the cloaca. The eggs are ellipsoid, 0.17 mm. in length and 0.45 mm. in thickness, and present evidences of segmentation or the formation of embryo within. The larval organism escapes from the egg and lives a certain length of time as a nonparasitic body; then becomes quiescent, until it is taken into the intestinal tract.

Associated with this parasite and often in greater numbers is a second form, the *Anguillula*, or *Rhabditis stercoralis*. This differs from the Anguillula intestinalis in being smaller and less organized in structure.

These organisms have been found with special frequency in Cochin China and other eastern countries, occurring in the intestinal tract in cases of severe diarrhea. It is doubtful whether they have definite pathologic significance.

TRICHOCEPHALUS DISPAR.

The anterior portion of this parasite is thin and thread-like, while the posterior portion is thicker. The length of the worm is

FIG. 134.—Trichocephalus dispar; natural size (Heller).

from 4 to 5 cm., the male being somewhat the smaller. The thicker part of the male is curled upon itself and blunt at the end, while that of the female is straight and more pointed. The

eggs are very characteristic, being brownish in color, covered with a thick capsule, and having at either pole a button-like projection (Fig. 117). The length of the egg is about 0.55 mm.

The parasite occupies the cecum in man, occasionally the vermiform appendix, and sometimes the small intestine. It is particularly frequent in children in Syria and Egypt. It does not, as a rule, produce serious disturbance. Recently it has been claimed that the parasite causes considerable disturbance by abstracting blood.

FILARIA MEDINENSIS.

The *Filaria* or *Dracunculus Medinensis* is a round-worm infesting the subcutaneous tissues and the skin. The male has never been discovered. The female sometimes reaches a length of 60 to 80 cm.; it is yellowish in color and exceedingly elastic. In general appearance it resembles a string of catgut. The body of the worm contains a highly developed uterus, which practically fills the cavity of the worm, the intestinal tube being crowded to one side. The uterus is found to contain innumerable small embryos; these escape when the parasite is ruptured.

The organism occurs very abundantly in tropical countries of the old world, notably Arabia, along the coast of the Caspian Sea, in Abyssinia, and Guinea. The parasite is sometimes called the Guinea-worm.

The parasite infests the subcutaneous tissues, particularly those of the lower extremities, and gives rise to inflammatory lesions resembling carbuncles. The method of invasion and the life-history of the organism are obscure. It is not improbable that the embryos occur in water of swamps and enter directly through the skin. Some authorities believe that the invasion occurs through the gastro-intestinal tract.

FILARIA SANGUINIS HOMINIS.

Several varieties of filariæ have been found in the blood and are included under this generic term. The discovery of the organism, or rather of the embryos, was made by Wucherer, in a case of hematuria.

The embryos appear in the blood, urine, the lymph, and the tissues as thread-like structures, varying in size in the different varieties. The ordinary form has a thickness of about the diameter of a red corpuscle, and is as much as 0.2 to 0.5 mm. in length. It consists of a transparent sheath, almost completely filled with the embryo, the ends, however, projecting a little beyond the organism, in a sac-like fashion (Fig. 135). The embryo is actively motile, squirming, thrashing, or curling and un-

curling itself rapidly, and thus producing more or less agitation of the corpuscles or solid bodies in its vicinity.

The number of the embryos found in the blood varies greatly; in many cases a search through several cover-glass preparations may be necessary to detect a single one. Usually they are more

FIG. 135.—Filaria embryo, alive in the blood (F. P. Henry).

abundant. A feature of importance is that they occur only during the night, unless the patient reverses the usual conditions and rests during the day.

The adult worm is found only in the lymphatic channels; it reaches a length of 38 mm., and has a rounded oral orifice at the anterior end. It produces embryos in great abundance, and these are carried along in the circulation.

Filariasis is particularly common in the warmer climates, but is occasionally met with in this country, especially in the Southern States. One of its most frequent forms is characterized clinically by *hematochyluria*. The embryos in these cases may be found in the blood and also in the chylous urine. Pathologically no gross changes may be found, but there may be in other cases evident distention of the lymphatic channels and blood-vessels of the pelvis of the kidneys, ureters, or bladder; and the embryos may be found in the substance of the kidneys or in the walls of the blood-vessels. Another form of filariasis is *elephantiasis*. In these cases there is obstruction of the lymphatic vessels in consequence of the presence of the parasites, of thrombi, or of inflammatory lesions, and as a result of these conditions dilatation of the peripheral lymphatic vessels occurs. The skin may be ruptured and chylous liquid may exude. The embryos may be found in this on microscopic examination.

Manson has described three varieties of filariæ—the original form, or *Filaria nocturna;* a second variety, in which the embryos are found at any time, night or day, called *Filaria perstans*, which he believes the cause of the sleeping-disease of Africa as well as of certain skin diseases (Craw-Craw); and a third form, the *Filaria diurna*, which appears in the blood only during the day.

OTHER FORMS OF FILARIÆ.

The *Filaria loa* is a small thread-like form met with in Africa and sometimes in tropical America. It invades the eye, lying beneath the conjunctiva. The *Filaria lentis* was found in the lens in a case of cataract. The *Filaria labialis* was discovered in a pustule on the lip of a student in Naples; and the *Filaria hominis oris* was found by Leidy in the mouth of a child. The *Filaria immitis* is the common filaria of the dog, and has been found in man. The *Filaria bronchialis* was found in bronchial lymphatic glands in a case of phthisis, and has also been found in the trachea and bronchi.

ECHINORRHYNCHUS GIGAS.

This is a large round-worm, the body being marked by distinct, transverse, parallel rings. The male may be from 7 to 10 cm. in length, the female from 31 to 50 cm. There is a retractile rostellum, with six rows of hooklets, at the anterior end, each row composed of eight spicules. The parasite occupies the small intestine of the hog, and has been found occasionally in man. The intermediate host seems to be the grub of the cockchafer and the June-bug.

Other varieties of echinorrhynchus have been described, but are not well-determined species.

EUSTRONGYLUS GIGAS.

The female of this species may reach a length of 1 m.; the male is but one-third this size. The anterior end of the worm is retracted, and the mouth surrounded by six papillæ. The posterior end is expanded, and provided with a spicule projecting from the cloaca. The color of the worm is brownish or blood-red. The parasite is found in the pelvis of the kidneys, ureters, and bladder of dogs, horses, cattle, and other animals, and rarely in man. Among its results are enlargement of the pelvis of the kidney and atrophy of the kidney-substance.

STRONGYLUS LONGEVAGINATUS.

This parasite was found in the lungs of a child. It resembles the strongylus met with in the lungs of sheep and other animals.

TREMATODES, OR FLUKE-WORMS.

The fluke-worms are usually flattened organisms, somewhat tongue-shaped and provided with powerful suckers and occasionally also with hooklets. The intestinal canal begins in the oral orifice anteriorly, but is closed at the posterior extremity. Repro-

duction may take place directly or by the formation of an intermediate organism which is parasitic to certain lower animals. In this stage they are actively motile, swimming about in water, and are known as the cercariæ.

DISTOMA HEPATICUM.

The Distoma hepaticum, or liver-fluke, is from 15 to 35 mm. in length and 6 to 20 mm. broad; it is pointed at either end, and anteriorly is provided with two suckers, one at the head and one upon the ventral surface, somewhat posterior to the first (Fig. 136). The genital pore lies between the two suckers. The eggs are oval in shape, 0.14 to 0.15 mm. in length, and provided with a lid at one pole.

FIG. 136.—Distoma hepaticum; two-thirds the natural size (Mosler and Peiper).

The adult organism occupies the biliary ducts and is a frequent parasite of sheep. It is occasionally met with in man, usually occurring in considerable numbers. It gives rise to obstruction of the biliary passages and consequent enlargement, congestion, and later degeneration of the liver. The gall-ducts above the point of obstruction have sometimes been found considerably dilated or cystic. Clinically ascites and jaundice have been found, with gastro-intestinal symptoms and distoma-eggs in the stools.

DISTOMA LANCEOLATUM.

This form is smaller than the last, 8 to 10 mm. in length and 2 to 2.5 mm. in breadth. The two suckers are far apart, and the genital pore lies between them (Fig. 137). The eggs are 0.04 to 0.05 mm. in length and 0.03 mm. in breadth.

FIG. 137.—Distoma lanceolatum; two-thirds the natural size (Mosler and Peiper).

This form is frequently associated with the last, and occupies the biliary passages of sheep and cattle. It is occasionally met with in other animals and in man.

DISTOMA HEMATOBIUM.

This organism occurs in sexually distinct forms; the male and female, however, occurring together. The male is 12 to 14 mm. in length and 1 mm. thick, and the posterior part is somewhat flattened and curved ventralward to form a groove, in which the female is attached

(Fig. 138). The latter is 16 to 18 mm. long, and 0.13 mm. thick. The eggs are 0.12 mm. long and 0.04 mm. broad, and drawn out

FIG. 138.—Distoma hematobium, with eggs (von Jaksch).

to a point at one end. The adult parasite occupies the portal vein and the veins of the spleen, mesentery, and the plexuses of the bladder and rectum. The eggs of the organism may be found in any of the organs, notably in the liver, in the intestinal walls, and in the mucous membranes of the urinary passages. They probably occupy the vascular system ordinarily, but cause rupture of the walls of the vessels and thus escape into the tissues.

FIG. 139.—Papillary thickening of the mucous membrane of the bladder, showing distoma-eggs *in situ* (Mosler and Peiper).

The pathologic changes caused by this parasite are most strikingly seen in the ureters and bladder in acute cases. Hyperemic spots or small hemorrhages may be seen in the mucous membrane, and the surface is covered with blood-stained mucus containing the eggs. In cases of longer standing roughness of the mucous membranes and usually small ecchymotic elevations or outgrowths, suggesting papillomata, are observed (Fig. 139). Section through these shows that they consist of proliferated cells with enlarged blood-vessels, from which the adult worm may be removed. The tissues surrounding the vessels may contain eggs in enormous numbers. The mucous membrane is frequently covered with a calcareous deposit composed of urate and oxalate of sodium, and the excrescences may be converted into calcified polyps. Among the final results may be cicatricial strictures of the ureter, pyelitis, and distention of the pelvis of the kidney, with atrophy of the kidney-substance. Similar pathologic processes may be found in the rectum. When the portal vein is occupied the eggs of the distoma may be abundant in the liver-substance. Distoma hematobium is a parasite occurring with enormous frequency in Northern Africa and

neighboring countries. It is comparatively rare in other parts of the world.

DISTOMA PULMONALE.

This organism is from 8 to 10 mm. in length and from 5 to 6 mm. in breadth. The eggs are brownish, and from 0.08 to 0.1 mm. in length. The worm occurs in the lungs, occupying excavated spaces, usually near the periphery of the organ. These cavities contain reddish or quite hemorrhagic mucopurulent liquid and abundant eggs. The cavities are in communication with the bronchi, and clinically the disease is marked by cough and hemorrhagic expectoration or even repeated hemoptysis. This parasite occurs very frequently in Japan, China, and Corea.

OTHER FLUKE-WORMS.

Among other forms of distoma of less importance are *Distoma crassum*, met with a few times in the intestine; *Distoma heterophyes; Distoma ophthalmobium*, found in the lens of the eye; *Distoma sinese*, found in the liver; *Distoma conjunctum*, also occurring in the liver; and the *Monostoma lentis*, occurring in the eye. The *Amphistoma hominis* occurs in the intestinal tract. Two forms, the Hexathyridium venarum and Hexathyridium pinguicola, are possibly forms of encapsulated Distoma hepaticum.

ANNELIDES.

Two forms of leeches are of some pathologic importance. The *Hirudo Ceylonica* is a form occurring with great frequency in Ceylon and other islands and in parts of South America. It is found in vegetation, and attaches itself to the skin of the legs and to other parts of man by means of a sucker and its short teeth. It may give rise to painful ulcerations when removed. The *Hirudo vorax* is met with in parts of Europe and Africa. It gains access to the mucous membranes of the mouth, larynx, trachea, or nasal chambers, and leads to inflammatory troubles. It is not able to effect a lodgement upon the skin.

ARTHROPODIA.

A number of parasites belonging to the groups Arachnoidea and Insecta are met with in man. Most of these, however, are purely external parasites, and are fully described in works upon diseases of the skin. There are two forms, however, that merit brief description here: the *Pentastomum denticulatum*, the larval form of Pentastomum tænioides; and the larvæ of various flies, the presence of which in the gastro-intestinal tract and other parts of the body is termed *myiasis*.

PENTASTOMUM DENTICULATUM.

This parasite is occasionally found in the liver and rarely in the spleen, intestinal walls, lungs, and kidneys of man. It is discovered in small nodular lesions, which consist of the more or less degenerated parasite lying in a cheesy or semicalcified material, surrounded by a fibrous or calcareous capsule. The parasite is from 4 to 5 mm. in length and 1.5 mm. in breadth; has a rather rounded body, which is encircled by parallel rings armed with spicules; and is provided with two pairs of stout chitinous hooklets, one pair lying on either side of the mouth. The adult form, *Pentastomum tœnioides*, resembles its larva in structure, but is considerably larger, the male being from 16 to 18 mm. long, the female from 60 to 85 mm. This form lodges in the nasal cavities and frontal sinuses of the dog and other animals, and produces eggs containing the embryos, which escape with the nasal secretion and eventually gain access to the alimentary tract of other animals or of man.

MYIASIS.

A number of flies, of the orders Estridæ, Musca, Lucilia, and Sarcophaga, may deposit their eggs in wounds or in cavities of the body to which they gain access, such as the nasal or pharyngeal chambers and the communicating passages. The eggs so deposited are hatched, and the larval insects may be retained and may occasion intense irritation. Sometimes the larvæ are found in the gastro-intestinal tract, the eggs having been swallowed with food. Immense numbers may be discharged from the intestines, and in some cases the larvæ seem to occasion intestinal irritation. The term *myiasis* is given to the invasion of these larval insects.

PART II.

SPECIAL PATHOLOGY.

CHAPTER I.

DISEASES OF THE BLOOD.

ANATOMY.

THE blood is a liquid tissue composed of corpuscles or cells and a fluid intercellular substance. The cells are of three kinds: the red corpuscles, or *erythrocytes;* the white corpuscles, or *leukocytes;* and the *blood-plaques*, or *hematoblasts*. The fluid element of the blood, the *liquor sanguinis*, or *plasma*, is an albuminous and saline liquid of a slightly varying composition. The blood as a whole is red in color, rather viscid, and alkaline in reaction. The total quantity is about one-thirteenth of the body-weight.

The **erythrocytes,** or **red corpuscles,** are biconcave disks about 7 μ in diameter and having a yellowish or amber color. They are quite uniform in size and regularly rounded. Histologically they are composed essentially of an albuminous substance containing hemoglobin embedded in a delicate stroma. The hemoglobin is the important element, and constitutes 95 per cent. by weight of the corpuscles. In early fetal life most of the red corpuscles are nucleated, but the nucleated forms later decrease in number and are comparatively scanty at the time of birth. Within the first few months of post-fetal life all of them disappear, and in subsequent years nucleated corpuscles are present only in cases of disease.

There are about 5,000,000 corpuscles in the cubic millimeter of the blood of normal individuals. The figures vary slightly at different times in the same individual, and many influences contribute to the production of more lasting changes in number (see page 313). The volume of the red corpuscles in the blood is dependent upon the number of corpuscles and upon their size. Observers have reached varying results in studying the volume, but it may be placed at between 40 and 50 per cent. of the total bulk of the blood.

The **leukocytes,** or **white corpuscles,** are rounded or spherical bodies presenting a more or less granular appearance in

the fresh state. They vary in size from the diameter of the red corpuscles to several times the size of the latter. The leukocytes are identical with the lymph-corpuscles. They are of several more or less distinct varieties; the classification, however, is exceedingly difficult, as transitional forms are abundant. The classification most frequently adopted is that of Ehrlich and of his pupils, and while it is not entirely satisfactory, it has one advantage over others, viz., that of simplicity. Ehrlich distinguishes (Fig. 140):

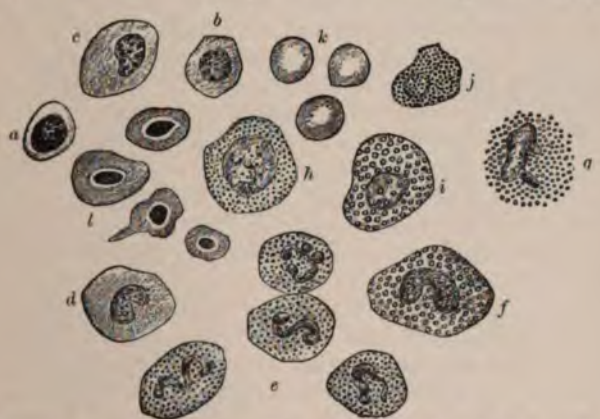

FIG. 140.—Various forms of blood-corpuscles: *a*, lymphocyte; *b*, lymphocyte approaching *c*; *c*, large mononuclear; *d*, transitional; *e*, polymorphonuclear neutrophile; *f*, polymorphonuclear eosinophile; *g*, broken eosinophile; *h*, neutrophilic myelocyte; *i*, eosinophilous myelocyte; *j*, basophile, mast-cell; *k*, red corpuscles; *l*, nucleated red corpuscles.

1. **Small mononuclear leukocytes, or lymphocytes.** These are smaller than the red corpuscles, or about the same size, are spherical, and contain a relatively large nucleus, the protoplasm often forming a scarcely visible band around the nucleus. The latter is rich in chromatin and stains deeply. Sometimes cells considerably larger than the typical lymphocyte may resemble them in other respects, and it may be difficult to determine whether these are lymphocytes or large mononuclear cells (Fig. 140, *b*). The protoplasm of lymphocytes normally contains no granular matter when stained by the ordinary methods. Deep staining with methylene-blue with the aid of heat does, however, frequently lead to the detection of a slightly granular character in the protoplasm.

2. **Large mononuclear leukocytes.** These forms are larger than the lymphocytes, being from two to three times the diameter of the red cells. They are often oval in outline, and the nucleus is poorer in chromatin than that of the lymphocyte, so that it appears comparatively pale in the stained blood. The protoplasm is usually free of granules, but it may show fine and very pale granules when stained with intense basic stains like methylene-blue.

3. **Transitional leukocytes.** These are similar to the last, but

differ in that the nucleus is often a little indented or horseshoe-shaped. It is very often impossible to determine satisfactorily whether a certain cell is a large mononuclear or a transitional form, and the two may be considered as practically the same. The protoplasm, as a rule, contains no granules, but neutrophilic granules (see page 301) have occasionally been detected, and eosinophile granules are more frequently present.

4. **Polymorphonuclear leukocytes; polynuclear leukocytes; neutrophiles.** These are the most numerous forms, and probably represent the fully developed white blood-cell. They are somewhat smaller than the large mononuclear elements, and are distinguished by a polymorphous nucleus which is richer in chromatin than that of the large mononuclear form, though perhaps less rich than that of the lymphocyte. The nuclei are elongated, and variously curved or distorted so as to resemble the letters S, U, V, Z, etc., and in some cases they are wreath-shaped. Frequently parts of the nucleus are so thin that they are scarcely visible, or actually become broken, and the term polynuclear was therefore applied. This name is, however, less appropriate than the term polymorphonuclear. The amount of chromatin in the nucleus varies greatly, and the size of the nucleus is correspondingly variable. The protoplasm usually contains fine granules, which are closely set and almost completely fill the cell. These granules have a strong affinity for neutral mixtures of anilin or other stains, and have therefore been called the neutrophilic granules (see page 301). A small proportion of the polymorphonuclear leukocytes of the blood contain eosinophile granules. These cells are usually larger than the neutrophilic forms, and the nucleus is more nearly like that of the typical transitional leukocyte.

5. **Myelocytes; mast-cells.** These are large cells identical with the large granular cells of the bone-marrow. They are often three or four times the size of the red corpuscles, and are distinguished by a large, pale, oval nucleus. The protoplasm usually contains neutrophilic granules, but occasionally contains eosinophile granules. The nucleus is frequently somewhat irregularly outlined and not rarely suffers degenerative change. Smaller cells, resembling the typical myelocyte in the character of the nucleus and protoplasm, are sometimes observed, and are difficult to classify. Myelocytes occur in exceedingly small numbers, if at all, in normal blood. They are abundant in certain forms of leukemia, and also occur in pernicious anemia and various infectious and systemic diseases.

The granules of the leukocytes are classified according to their behavior with the anilin stains. We may distinguish four important types of granules (Figs. 140 and 141):

1. *a*-**granules, eosinophile granules, or oxyphile granules.** These are coarse granules giving the appearance in the unstained blood

of minute fat-droplets; they are highly refractive, and have been shown to be composed of albuminous material. They are distinguished by their strong affinity for acid stains,[1] and in particular for eosin. This circumstance has given rise to the name eosinophile and oxyphile (Fig. 147).

The eosinophile granules in the normal blood occur only in polymorphonuclear leukocytes.

2. **γ-granules; mast-cell granules.** These are intensely baso-

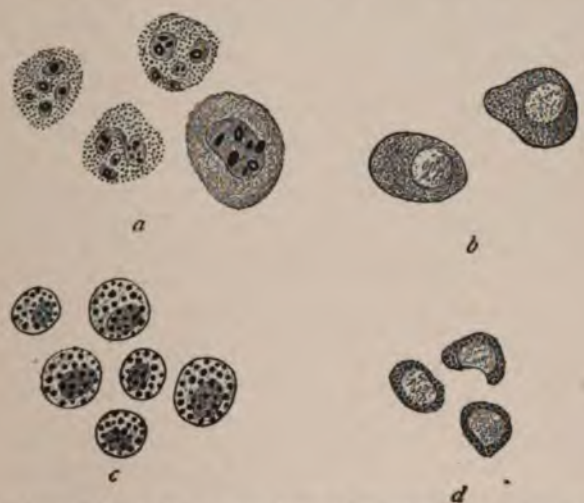

FIG. 141.—Leukocytes, showing various forms of granulations: *a*, Neusser's basophilic, perinuclear granules; *b*, large mononuclear cells with δ-granules; *c*, mast-cell granules; *d*, basophilic lymphocytes, δ-granules; the stain in *b*, *c*, and *d* was a mixture of eosin and hematoxylin, the cover-glass being kept in the stain several hours at 37° C. (98.6° F.).

philic, coarse granules, occurring in mononuclear cells. They are present in small proportions in the normal blood (Fig. 141).

3. **δ-granules** are fine basophilic granules occurring in the lymphocytes or large mononuclear cells (Fig. 141).

4. **ε-granules; neutrophilic granules.** These are the most abundant and the most important of all the forms. They occur as fine granulations filling up the protoplasm of the polymorphous cells, and they are occasionally present in transitional leukocytes. They are distinguished by their affinity for the neutral mixtures

[1] The term acid stain is here used in a sense somewhat different from that of the chemist. A stain in which the acidulous part of the compound carries the coloring-principle is known as an acid stain, while one in which the basic element is the staining-principle is called basic. For example: picrate of ammonium is an acid stain because the picric acid is the staining-element. Mixtures of certain acid with basic stains may be prepared so that tissue-elements having a strong acid affinity will select the acid stain, those having a basic affinity the basic stain, while other elements without such special affinity receive a mixed or neutral stain.

of Ehrlich (Fig. 147). It must be recognized, however, that these granules are in reality faintly oxyphilic, receiving the acid stains, such as eosin or acid fuchsin, more readily than basic stains. In a few instances I have found them distinctly basophilic.

The *nature of the granules* of the blood is still obscure. They are undoubtedly connected in some way with the specific function of the leukocytes, but whether they are of the nature of a secretion or not is unknown.

The chemical composition of the leukocytes is of considerable importance, but is difficult to determine from the impossibility of obtaining large numbers free from other elements. It is known, however, that these cells contain among other bodies leukonuclein, histon, lecithin, and cholesterin. They also contain more or less abundantly glycogen and fats; and saline constituents including potassium salts in particular. The leukonuclein is a combination of the phosphorus-containing nucleinic acid and an albumin. It is present in the nuclei of nucleated red corpuscles and in other nuclei, but especially in those of the leukocytes. It is more or less intimately combined with histon, a body resembling the albumoses.

The **number of leukocytes** in the normal blood varies considerably. The average number, however, is probably between 6000 and 10,000. Alterations in the number under various circumstances will be discussed below.

Proportions of the Different Forms.—The relative proportions of the different leukocytes are determined by counting large numbers and calculating the percentage proportion of each form. Approximately there are 25 per cent. lymphocytes, 65 to 75 per cent. polymorphonuclear forms (neutrophiles and eosinophiles), 5 to 8 per cent. transitional and large mononuclear. About 1 to 3 or 5 per cent. of all of the leukocytes contain eosinophile granules, and occasionally a larger proportion is met with in normal blood.

Blood-plaques.—These are small disks somewhat resembling the red corpuscles, though smaller and without the characteristic biconcavity of the latter. They rarely exceed 3 μ in diameter, and are often much less. They are viscid, and tend to adhere to the other corpuscles or to become agglutinated in clusters. The total number has been estimated at from 150,000 to 500,000 per cubic millimeter. The term hematoblast was applied by Hayem in the belief that the plaques are the progenitors of the red corpuscles.

The **plasma** of the blood is an albuminous liquid containing serum-albumin and serum-globulin and various saline compounds. The relative proportion of serum-globulin to serum-albumin is as 1 to 1 or 1½. Of the saline constituents sodium salts are most important, the phosphates, carbonates, sulphates, and chlorids being most abundant. Various other nitrogenous and non-nitro-

genous substances are present in small proportions. Reference will be made to some of these below.

BLOOD-FORMATION.

The process of blood-formation is still obscure in some particulars. In early fetal life blood-corpuscles are undoubtedly formed in the mesoblastic columns in which the blood-vessels are developed. At a later stage the liver is active in their production. Subsequently the spleen and the bone-marrow seem to assume the principal *rôle*. According to Neumann and Bizzozero, the red corpuscles are developed from nucleated hemoglobin-containing cells of the bone-marrow, which lose their nuclei by a process of gradual disintegration. Others have held that the nuclei are extruded from the nucleated cell. According to these views, all of the red corpuscles are derived from nucleated red cells, or *erythroblasts*. Other observers, however, hold that the red corpuscles and leukocytes originate from a common parent-cell free from hemoglobin. This parent-cell gives rise to two series of descendants, one series containing hemoglobin and leading to the formation of red corpuscles, while the other series is free from pigment and forms the leukocytes. The principal place of formation of the red corpuscles during adult life seems to be the bone-marrow, but the spleen and the lymphatic tissues probably also play a part. French writers, following Hayem, hold that the progenitor of the red corpuscle is the blood-plaque. This view, however, is not sustained by sufficient evidence.

The white corpuscles undoubtedly originate in the bone-marrow, lymphatic tissues, and spleen. The lymphocyte is the youngest form, and the other varieties probably are secondary developments from this, the completion of their development occurring in the blood-making organs, notably the marrow.

PATHOLOGIC CHANGES IN THE RED CORPUSCLES.

The **size** of the red corpuscles varies in diseases of different kinds. There may be dwarf corpuscles, 2 to 4 or 5 μ in diameter (*microcytes*); or, on the other hand, giant-cells (*megalocytes*), from 9 to 15 μ or even 20 μ in diameter. The small forms frequently have a spherical shape rather than the disk-like form of the normal corpuscle, and may be deeply pigmented. The large corpuscles are often irregular in shape, and are prone to be paler than normal corpuscles (Fig. 142). Some observers have found that the average size of the red corpuscle is greater in certain diseases than in health. This is probably the result of hydropic conditions.

The **shape** of the corpuscles often suffers great change, and many forms of irregularity may be observed. The term *poikilocytosis* is applied to this condition (Fig. 142). Some of the poikilo-

cytes may be exceedingly small and may present active movements. These have been termed pseudobacilli by Hayem. These changes of form in red corpuscles are regarded by many authorities to be

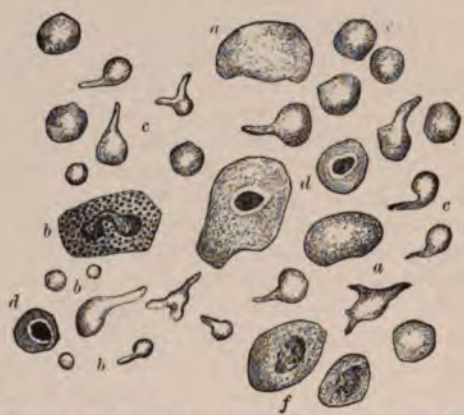

FIG. 142.—Blood from a case of pernicious anemia: *a*, megalocytes; *b*, microcytes; *c*, poikilocytes; *d*, nucleated erythrocytes; *e*, normal erythrocytes; *f*, leukocytes.

the result of degenerative changes in the protoplasm with consequent ameboid movement which occasions irregular projections. The small forms are doubtless in many cases the result of fragmentation. Ehrlich used the term schistocyte to indicate this fact.

Dust-corpuscles.—Müller recently described certain small spherical bodies somewhat resembling the leukocytic granules, but lying free in the plasma and often actively motile. These he termed *hemokoniæ*, or dust-corpuscles. They occur in normal blood as well as in that of various diseases. A number of theories have been offered regarding the nature of these bodies. My own belief is that they are fragments of red corpuscles, similar to those that may be produced by heating fresh blood under a cover-glass to destructive temperatures. Under these circumstances small, bud-like processes are formed on the periphery of the red corpuscles, and some of these may break off and float free in the plasma.

Visible ameboid movements may sometimes be observed under the microscope, especially in severe anemias, such as pernicious anemia.

Nucleated red corpuscles, or **erythroblasts,** occur in the severe anemias as in the fetal blood. They are more frequent in the severest cases, and in particular in the anemias of children. Some are exceedingly small (*microblasts*), some about the size of the normal red corpuscle (*normoblasts*), and some large and irregular (*megaloblasts*). The smaller forms appear first and in the more moderate anemias; occasionally they occur in great numbers or crops from time to time (*blood-crises*).

Karyokinetic figures are occasionally seen in the nuclei of erythroblasts, especially in certain anemias of children.

Shadow corpuscles are red corpuscles that have lost their color almost completely and are scarcely visible. They may be observed in severe anemias, and especially in cases of intoxication with blood-poisons.

Polychromatophilia.—The normal red corpuscle has a special affinity for acid stains. In diseased conditions it may develop an affinity for basic stains, and when colored with mixtures of acid and basic stains may present tints combining all the stains employed. Thus in staining with eosin and hematoxylin the degenerated corpuscles may present a purplish or violet color, instead of a pink.

Vacuolation and pigmentation of the red corpuscles are rare forms of degeneration. The pigmentation is due to separation of the hemoglobin in the form of irregular granules.

Alterations of Isotonicity.—All forms of cells have certain osmotic relations, in consequence of which they retain their constituent elements in the presence of surrounding liquids of certain kinds. If the osmotic relations vary or the surrounding liquids are altered, the constituents of the cell may be extruded. In the case of blood-corpuscles distilled water rapidly abstracts the hemoglobin and other substances, but saline solutions of certain strengths do not so affect the corpuscle. The exact strength of a certain saline solution may be determined which will preserve the corpuscle, and this is known as the isotonic strength of the corpuscle expressed in percentage-terms of the saline used. Degenerated corpuscles more readily yield their constituents, and the isotonic saline solution is therefore of higher percentage. In normal blood the isotonicity of the red corpuscle is generally 0.46 to 0.48 per cent. NaCl; that is, solutions of common salt of this strength do not affect the red corpuscles. In anemic diseases the isotonic solutions may be from 0.5 to 0.6 per cent.

PATHOLOGIC CHANGES IN THE LEUKOCYTES.

Very frequently degenerations of the nuclei of the leukocytes are observed in the form of fragmentations or karyolytic change. Attention has recently been called (Neusser) to the presence of basophilic granules about the nucleus in certain forms of disease, such as leukemia, gout, and lithemia in its widest sense. These granules are supposed to be significant of disintegration of the nuclei in the process of uric-acid formation. Their nature and significance, however, are unsettled. Occasionally vacuolization and fatty degeneration of leukocytes are observed, and glycogen may be found in abnormal quantities. In cover-glass preparations

the leukocytes are sometimes found broken or fragmented, and this doubtless occurs to some extent in the circulating blood.

PATHOLOGIC CHANGES IN THE PLASMA.

Various disorders of the plasma have been studied. These are mainly of a chemical sort, and consist of the presence of abnormal substances or of normal constituents in excessive quantity. Urea is present in large quantities in some cases of nephritis and uremia, and older authorities believed the symptoms of uremia due to the presence of this substance. This view is no longer held. Uric acid occurs in small quantities in health; but in large quantities in gout, leukemia, leukocytosis, and other disorders of the blood. The xanthin bases may be present in considerable quantities in the same cases. Glycogen or grape-sugar is found in excessive quantities in diabetes and, according to some observations, in cases of carcinoma. Levulose and other carbohydrates are rare constituents of the plasma. Fatty acids may be present in leukemia, diabetes, acute yellow atrophy of the liver, and some other diseases. The quantity of sodium in the plasma increases in anemic diseases.

Certain changes occur in the plasma or serum in anemic diseases, as a result of which the globulicidal character is increased. The nature of these changes is obscure. The presence of toxic substances the result of bacterial action is referred to in the discussion of bacteria.

Hypertonicity of the serum is a term indicating that the salinity of the plasma or serum is such that the blood may be somewhat diluted without destruction of the corpuscles. By graduated dilutions the degree of hypertonicity may be estimated, and is found less in certain diseases than in health (see Isotonicity of the Red Corpuscles).

Hyperinosis and *hypinosis* are terms designating increased and decreased capability for fibrin-formation. The former is met with at times in chlorosis, leukemia, or other anemic affections, and in certain infectious diseases. The latter is notably present in leukemia and some cases of hemolysis. There has been much theorizing in regard to these conditions, but very little knowledge of practical importance has been acquired.

PLETHORA.

Plethora is the name applied by the older writers to a condition in which the total quantity of blood was supposed to be excessive. It is now recognized that plethora is much less frequent and permanent than was formerly believed. Several varieties were described.

Plethora vera was the name given to the condition in which the quantity of the blood was supposed to be increased without

change in its quality. Persons supposed to have this condition are described as robust, with high color and vigorous circulation. They are generally individuals living in luxury. The term "full-blooded" is still applied, but it is recognized that the fulness of the superficial vessels is the result of peculiarities of the circulation rather than of increase in the quantity of blood.

Plethora apocoptica is the term given to conditions in which there is local increase in the blood.

Plethora hydremica is a condition in which the total quantity of the blood is increased by dilution. This was regarded as frequent in cases of cachexia after hemorrhages, etc.

Experimental evidence might be referred to to substantiate the view that plethora in the strict sense does not often occur as a lasting condition. Temporary plethora is produced by the drinking of large quantities of liquid, but the excretory organs soon dispose of this excess.

OLIGEMIA.

Oligemia is a term indicating reduction in the quantity of blood. This is met with temporarily after hemorrhage, but very soon serous liquid from the tissues enters the blood-vessels and restores the original quantity. At the time of the hemorrhage the quantity may be immediately reduced to a very great degree without causing death. Serious consequences are averted by the activity of the vasomotor system, the blood-vessels accommodating themselves by contraction to the reduced quantity of blood. Subsequently when liquid of the tissues is absorbed into the blood-vessels the latter dilate and their natural volume is soon restored. The blood, however, becomes hydremic, or watery. Oligemia or quantitative anemia may possibly occur in certain cachectic and anemic diseases, but this has not been proved, and the relative proportion between the mass of blood and the weight of the body is certainly not much disturbed in any case.

HYDREMIA AND ANHYDREMIA.

Hydremia, a diluted or watery condition of the blood, may occur from excessive consumption of water, but active excretion of liquid soon restores the blood to its previous condition. Hemorrhage leads to hydremia in the manner above described; and in the chronic anemias there is possibly some dilution of the serum. It has never been shown, however, in any of the many experiments made to determine this point, that the plasma in anemias is less rich in solid constituents than normal plasma. The reduction in solid matter in the blood as a whole is due to the diminution in the number of red corpuscles and changes in their composition.

Anhydremia is a condition in which the plasma of the blood

is thickened by the loss of watery elements. This may occur in consequence of excessive sweating or excessive discharge of water from the bowels, kidneys, etc. The number of red corpuscles in a given bulk of blood increases. The specific gravity and the solid residue of the plasma of the blood as a whole increase correspondingly.

LIPEMIA.

Lipemia is a pathologic condition in which fat occurs free in the blood-plasma. Fat is always present as a normal constituent of blood, and is in slight excess during the process of digestion. Lipemia occurs in cases of chronic nephritis, diabetes, pulmonary tuberculosis, alcoholism, and some other conditions, and may reach marked grades of severity. The blood may have a milky appear-



FIG. 143.—Blood from a case of lipemia, stained with osmic acid: upper half of field cleared with oil of turpentine; lower half shows the fat-droplets and granules stained with osmic acid between the blood-corpuscles; enlargement, 100 diameters (after Gumprecht: *Deutsch med Woch.*, Sept. 27, 1894).

ance to the naked eye, and under the microscope highly refractive droplets or granules are observed. The latter stain black with osmic acid (Fig. 143).

MELANEMIA.

This condition is distinguished by the occurrence of dark pigment or granular matter in the circulating blood. It occurs in cases of malaria and certain other fevers. The pigment may be

free in the plasma in the form of yellowish or blackish granules; or may be found as small particles in the leukocytes.

HEMOCYTOLYSIS—HEMOGLOBINEMIA.

Definition.—Hemocytolysis is the term applied to the conditions in which the red blood-corpuscles are destroyed. The name *hemolysis* is generally employed in the same sense, though it refers to destruction of all of the elements of the blood. In this condition hemoglobin is liberated and is dissolved in the plasma. To this the term hemoglobinemia is applicable, but the name methemoglobinemia is more appropriate, as the hemoglobin is usually present in the serum in this altered form.

Etiology.—Hemolysis constantly takes place in the liver, the coloring-matter of the blood being converted into bile-pigments. Pathologic hemolysis results from the action of various infectious and toxic agents. It occurs in the course of severe malaria, relapsing fever, pneumonia, and various hemorrhagic infections; and is occasioned by many poisons (see Blood-poisons). Excessive cold may be a contributing cause, as seems to be the case in some instances of paroxysmal hemoglobinuria (*q. v.*).

Pathologic Anatomy.—The blood may present striking morphologic changes in the red corpuscles, such as microcytosis, megalocytosis, poikilocytosis, fragmentation, and vacuolation. Shadow-corpuscles may be abundant, and in the later stages of the process beginning regeneration of the blood causes the presence of nucleated red corpuscles. The blood as a whole is often quite dark in color.

Associated changes are frequently met with in the liver, kidneys, and skin. The hepatic cells are often swollen and more or less degenerated and bile-stained. Excessive production of bile (polycholia) may occur. This over-production, with the swelling of the hepatic cells and the consequent obstruction of the biliary channels, occasions reabsorption of bile and consequent jaundice (so-called hematogenous jaundice). The excess of hemoglobin, which cannot be disposed of by the liver, may be excreted in the urine (hemoglobinuria). Sometimes hemoglobin-infarcts are met with in the renal tubules; and thrombosis of the renal or other blood-vessels is occasionally observed. Acute nephritis is a rare result.

Pathologic Physiology.—Hemocytolysis leads to more or less pronounced disturbance of the internal or tissue respiration, as the altered hemoglobin is incapable of carrying oxygen. Dyspnea and various nervous symptoms are the result. The liberation of cellular constituents (from destruction of the red and white corpuscles) occasions increased coagulability of the blood and the formation of thrombi (ferment-intoxication). Fever and other general symptoms may be due to the same cause.

POLYCYTHEMIA.

Polycythemia, or erythrocytosis, the condition in which the number of red corpuscles in a given bulk of blood is increased, may be *actual* or *relative*. Actual polycythemia is that in which there is over-production of red corpuscles; this is probably rare. Relative polycythemia is due to decrease in the quantity of the plasma. It is met with in a variety of conditions, including certain cardiac diseases, with slow failure of compensation, and especially in congenital cyanosis; in residents of high altitudes; in the new-born; and in cases of cholera or other diseases in which liquid discharges cause inspissation of the blood. The explanation of the increased number of corpuscles in some of these conditions has occasioned considerable controversy. Some have held that the number of corpuscles (at high altitudes, for example) increases actually rather than relatively, for the purpose of furnishing a greater oxidizing surface, but this has not been proved. It is more likely that the increased number of corpuscles is caused by changes in their distribution in the circulation. In evidence of this it may be pointed out that the number of corpuscles in dependent parts, such as the foot, is greater than normal. In cardiac disease and in persons living at high altitudes it is not improbable that similar stagnation of the corpuscles in the peripheral tissues takes place.

LEUKOCYTOSIS.

The term leukocytosis is given to a more or less transient increase in the number of leukocytes, the polymorphonuclear forms being usually in excess. Sometimes leukocytosis is continuous or chronic, and sometimes the excessive number of leukocytes is due to increase in the mononuclear elements rather than the polymorphonuclear.

Etiology.—The causes of leukocytosis are varied. It is generally observed as a normal condition in the new-born, the number of corpuscles remaining in slight excess during the first year of life. It also occurs in many cases of pregnancy; and is quite constant during the period of digestion in healthy persons, proteid food being more striking in the effect than a farinaceous or mixed diet. In some diseases of the stomach post-digestive leukocytosis seems not to occur.

Inflammatory and Infectious Leukocytosis.—Among the strictly pathologic forms of leukocytosis the most important are those due to inflammations and infections of various kinds. Croupous pneumonia occasions considerable increase of leukocytes in most cases, and this is continuous until the final decline of the fever. Suppurations of all kinds act in a similar manner. Inflammations of the serous membranes—peritonitis, pleurisy, meningitis—may

be attended by moderate or severe leukocytosis. Among the acute infectious fevers there are some in which leukocytosis occurs and others in which this is wanting, and this fact often proves valuable to the clinician. Among those in which the leukocytes do not increase in number are typhoid fever, influenza, malaria, and acute miliary tuberculosis.

Cachectic leukocytosis occurs in a variety of marantic conditions, and toward the end of life in any case of wasting disease there may be a great increase in the number of leukocytes. This agonal or terminal leukocytosis is either cachectic (toxic) in nature or it may be due to terminal infections.

Malignant tumors frequently cause leukocytosis.

Hemorrhage may occasion increase in number of the white corpuscles, more or less in accordance with the quantity of blood lost.

Mechanical and Thermal Causes.—Massage and cold baths frequently cause increase in the number of leukocytes for a time.

Medicinal leukocytosis, or that due to the introduction of various drugs, is probably allied to infectious and cachectic leukocytosis in the manner of its production.

Pathogenesis.—The nature of leukocytosis is still the subject of some controversy. Formerly it was held that the increased number of leukocytes is wholly due to overproduction; later, some investigators claimed that diminished destruction is the important cause. The explanation which seems most acceptable at the present day is that of Golscheider and Jakob. These observers hold that infectious and toxic leukocytosis is due to the attractive influence of the toxic substances upon the leukocytes in the blood-making organs, and to a certain extent to the stimulating influence upon those organs, leading to increased production of leukocytes. There are at all times large numbers of leukocytes in the lymphatic tissues and throughout the other tissues of the body which may be drawn into the circulation by chemotactic substances. When, however, leukocytosis is prolonged it is likely that new formation of leukocytes takes place, as the supply would otherwise soon become exhausted.

Character of the Blood.—The blood in leukocytosis varies considerably in character. The number of leukocytes may be only moderately increased (10,000 to 20,000) or may be excessive (50,000 to 100,000). The older writers distinguished between leukocytosis and leukemia by the number of leukocytes present. This distinction is no longer admitted, as there are cases of leukocytosis with very marked increase in the number of the leukocytes and cases of leukemia with leukocytosis temporarily or continuously of more moderate degree.

In the majority of cases of leukocytosis the polymorphonuclear elements are in relative as well as actual excess, the mononuclear elements being actually increased in number, but relatively defi-

cient (Fig. 144). The proportion of polymorphonuclear elements is frequently 80 to 85 per cent., and sometimes 90 or 95 per cent., instead of 65 to 70 per cent. In the leukocytosis of the new-born, in hemorrhagic leukocytosis, cachectic leukocytosis, and that due

FIG. 144.—Septic leukocytosis, showing marked increase of polymorphonuclear leukocytes.

to malignant tumors, the mononuclear elements frequently preponderate. Occasionally myelocytes have been observed, and karyokinetic figures may occur in the nuclei.

Pathologic Physiology.—Leukocytosis certainly exercises some profound influence upon the system, but the exact nature of this influence is unsettled. Those who contend in favor of the phagocytic theory of immunity claim, more or less directly, that the increase of leukocytes is a protective process, the purpose being the removal and destruction of irritants. Others believe that leukocytosis is part of the cellular processes concerned in the production of immunizing substances. There is certainly more active destruction of leukocytes in leukocytosis than in health, as is evidenced by the increase of xanthin bases and uric acid in the urine; and it may be that in this destruction protective substances are liberated.

HYPOLEUKOCYTOSIS.

Hypoleukocytosis, or leukopenia, is the condition in which there is deficiency in the number of leukocytes. This is met with in moderate degree in various diseases, such as tuberculosis, typhoid fever, some cases of pneumonia, cachexia, inanition, progressive pernicious anemia, etc. The nature of hypoleukocytosis is not always clear. Some have held that it is due to destruction of leukocytes (*leukolysis*), while others claim that it is the result of altered distribution of the leukocytes. It has been shown by experimenters that the injection of certain micro-organisms or toxic substances will produce, first, a decrease in the number of

leukocytes, and then an increase. The primary hypoleukocytosis is explained by some as the result of active destruction of leukocytes, but the conditions of the urine do not give evidence of such active destruction, and others have shown that the capillaries of the lungs, liver, and other organs are overfilled with leukocytes during this stage. The assumption is therefore warranted that hypoleukocytosis is the result of disturbance in the distribution of the leukocytes.

ANEMIA.

Definition.—This term includes a variety of conditions in which the blood is reduced in quality in one direction or another. The term *oligocythemia* indicates a reduction in the number of red corpuscles, while the name *oligochromemia* indicates a reduction in the coloring-matter of the corpuscles. Usually these conditions are associated.

Classification of Anemias.—It is not as yet possible to offer a strictly scientific classification, but for ordinary purposes the old division into *primary* and *secondary anemias* may be retained. The term primary anemia may be given to forms in which the anemia is the striking pathologic condition. The older writers used the name to indicate that the anemia was an essential disease and dependent upon no preceding affection, excepting possibly a disturbance of the hematopoietic organs. The term secondary anemia, or symptomatic anemia, may be used to designate anemic conditions in which some underlying disease that has occasioned the anemia is conspicuous. According to the classification here offered, all anemias are recognized as secondary in the strict sense, but those in which the underlying disease is not conspicuous are classified as primary, and those in which the original disease is conspicuous as secondary.

SECONDARY ANEMIA.

Etiology.—Various *unsanitary conditions* may influence the character of the blood by the constant disturbance of the organic functions. A cause of immediate anemia is *hemorrhage*. This first leads to reduction in the quantity of blood; and later by absorption of liquid from the tissues to dilution of the blood, or hydremia. Finally, after a variable period the character of the blood is restored by regeneration of corpuscles and of coloring-matter. *Parasites* of various sorts may lead to anemia. Among the more important are the intestinal worms, Anchylostoma duodenale, Bothriocephalus latus, and Anguillula intestinalis. The mode of action of these is not entirely clear. Some have held that they cause anemia by loss of blood through the intestine, and this is probably true in the case of Anguillula, but marked anemia

may occur from the presence of Bothriocephalus or Anchylostoma without much hemorrhage taking place. An explanation worthy of consideration in these cases is that the parasites generate poisons either in their ordinary life or by their death and decomposition, and that these poisons are the cause of the anemia. Other intestinal parasites may occasion more or less anemia directly or indirectly. The parasites occurring in the blood itself, notably the malarial organism, may cause extreme anemia. *Infectious diseases* frequently lead to impoverishment of the blood. In the acute febrile diseases, such as typhoid fever, rheumatism, and pneumonia, the anemia may not be conspicuous during the progress of the disease, but becomes apparent after the fever has subsided. This may be explained by the assumption that increased respiration and sweating cause inspissation of the blood and relative increase in the number of red corpuscles during the existence of fever, so that the anemia is unnoticed. In chronic infections, such as syphilis and tuberculosis, marked anemia may occur. Among the *poisons* capable of producing anemia are lead, arsenic, phosphorus, and the like, and experimentally pyrogallol, nitrobenzol, and similar substances have been used to produce anemia. The anemias of various infectious diseases are undoubtedly toxic in character, and very probably those occurring in gastro-intestinal and nutritional diseases are similarly the result of the action of poisons generated within the body. *Organic diseases* and *new growths* of various sorts may occasion anemia by the general disturbance of health, by toxic products generated in the course of disease, by hemorrhage, etc.

Pathologic Anatomy.—The condition of the blood in secondary anemias varies with the duration and grade of the anemia. In moderate cases the number of red corpuscles decreases slightly (4,000,000 to 3,000,000), and the hemoglobin is correspondingly reduced, though often somewhat more strikingly than the corpuscles. The fresh blood may show no visible changes under the microscope, and even in stained preparations the appearance may be normal. More marked anemia is distinguished by greater reduction, the number of corpuscles sinking to 2,500,000 or 2,000,000 per cu.mm. in extreme cases. The hemoglobin is usually reduced more markedly than the corpuscles. Examination of the fresh blood shows pallor of the corpuscles and various irregularities in size (microcytes and megalocytes) and shape (poikilocytes). Nucleated red corpuscles may be present in small numbers, the microblasts and normoblasts predominating. The stained blood may disclose degeneration of the corpuscles by the presence of polychromatophilic forms. The leukocytes do not play an essential part in this form of anemia. Their number may be normal or reduced; in other cases leukocytosis is present. The relative proportions of the different forms is usually about normal. In

severe cases the lymphocytes may increase relatively and actually, at the expense of the polymorphonuclear forms. Myelocytes are occasionally present.

Associated changes in various organs may be met with. Among these are parenchymatous and fatty degeneration of the heart, kidneys, and liver. These conditions have often been ascribed to reduced oxidation, which was supposed to be due to poverty in hemoglobin. Physiologic studies, however, do not establish the existence of a reduction in the respiratory exchange of gases. It is likely that toxic conditions of the blood occur in anemia, and that the poisons act directly upon the affected organs.

Pathologic Physiology.—The process of oxidation is of particular interest in anemia, and, as has been stated, recent investigations show that the consumption of oxygen and elimination of carbon dioxid are normal. To accomplish this result more active circulation and greater energy of the tissues are required. Partly in consequence of the latter, diseases of the organs named in the last paragraph result; and at the same time some of the characteristic symptoms (palpitations, dyspnea) are produced. In severe secondary anemias increased tissue-waste occurs, and nitrogen is discharged in excess of that ingested.

THE PRIMARY ANEMIAS.

The conditions included under this title are chlorosis, progressive pernicious anemia, leukemia, and Hodgkin's disease. The term *simple primary anemia* is sometimes used to designate a form of anemia without distinct cause, and characterized by moderate oligocythemia. There are, it is true, occasional cases of moderate anemia in which no definite precedent disease can be discovered; but these are exceptional cases, and are to be considered as secondary anemias in which the underlying disease is latent. Cases of this sort do not conform to a definite type, and cannot therefore be considered as illustrating a special form of anemia. Another term frequently used is *splenic anemia*. This is even less satisfactorily defined. Splenic enlargement may occur in any of the primary anemias, and may in some cases be excessive. Moreover, some of the distinctly secondary anemias (as those of rickets, syphilis, and malaria) are very often attended with splenic enlargement. It has not been proved that there is a special form of anemia with splenic enlargement as the conspicuous lesion, and cases of so-called splenic anemia are to be considered as secondary or primary anemias in which splenic enlargement happens to be marked.

CHLOROSIS.

Definition.—Chlorosis is a primary anemia due to retarded hemogenesis, characterized by a peculiar pallor and marked reduc-

tion in the percentage of hemoglobin, and occurring almost exclusively in young girls and women.

Etiology.—Chlorosis is most frequent at the time of beginning menstruation and during the years immediately following this. A form of *late chlorosis* has been described in women above thirty years of age and at the menopause; but the nature of this is doubtful. *Chlorosis in the male* is still more doubtful, though a few cases have been described by competent observers. Hereditary tendencies are of etiologic importance. The disease occurs more frequently in families in which tuberculosis is common than in those not so affected. Constitutional predisposition is also an important factor, poorly developed girls, and particularly those of delicate mould, being especially liable to the disease. Virchow found hypoplasia of the heart and great vessels, and Rokitansky the same condition in the generative organs, and pathologists have been inclined to regard these as important factors in the development of the disease.

Various exciting causes have been considered as of more or less importance. Emotional excitement was regarded as a prime cause by ancient authorities, and in consequence such terms as *icterus seu febris amantium* were applied. Home-sickness, grief, etc., are causes of moment. Intestinal auto-intoxication has been regarded as the essential factor by many, but physiologic chemists fail to find evidences of the existence of such intoxication. Menstrual disturbances are important as symptoms, and have often been regarded as causes. The hypoplasia of the genital organs adds some probability to this view, but more definite evidence is wanting.

At the present time it seems most likely that chlorosis is due to faulty development, and especially to a want of proper hemogenetic power.

Pathologic Anatomy.—The hypoplasia of the vascular and generative systems has been referred to. These are primary lesions, and possibly causal. Various secondary diseases may be encountered, as in other anemias. Among these, myocardiac degeneration and dilatation are most important, though they do not attain high grades of severity. The spleen is frequently a little enlarged. Peculiar yellowish or greenish pigmentation of the skin is a striking feature. The pigment is doubtless altered hemoglobin, but its exact nature is unknown.

The Blood.—The blood is paler than normal, and watery. The specific gravity decreases progressively, and the solid matter is deficient. Increased coagulability is sometimes observed. The number of red corpuscles may be normal, even in well-developed cases, but the proportion of hemoglobin sinks progressively. In prolonged cases the corpuscles become reduced in number, but the deficiency of hemoglobin continues to be excessive. Severe cases of chlorosis frequently show 3,000,000 or 2,000,000

red corpuscles per cu.mm. and 30 per cent. to 20 per cent. of hemoglobin. The red corpuscles may be little altered in appearance in the early stages; later, irregularities in size and shape are frequent, and nucleated red corpuscles (especially small forms) make their appearance. The latter sometimes occur in great numbers in crops (blood-crises). The leukocytes are usually normal in number and kind; but in some cases myelocytes have been met with.

During the process of recovery from chlorosis the red corpuscles increase in number before any change occurs in the percentage of hemoglobin.

Pathologic Physiology.—Chlorosis resembles the secondary anemias in most particulars, as far as its influence on the general health is concerned. Some of the symptoms (cardiac and menstrual) are doubtless due to primary abnormalities of structure. The preservation of the subcutaneous fat despite advancing anemia is a striking feature. It is explained by von Noorden by the assumption that the quiet and warmth which chlorotics find necessary to their comfort lead to accumulation of fat. Decreased oxidation is certainly not the cause.

PROGRESSIVE PERNICIOUS ANEMIA.

Definition.—Progressive pernicious anemia is a form of extreme anemia tending to increase in severity to a fatal end. It may be apparently causeless, or more or less adequate causes may be discovered. It is characterized by excessive oligocythemia and marked changes in the red corpuscles.

Etiology.—The disease was described by Addison as a wholly causeless anemia—that is, an anemia independent of precedent disease of any sort. In recent years, however, causes of various sorts have been discovered. Pernicious anemia may occur in childhood or old age, but is usually met with at or after middle age. Depressing emotions, fright, exposure, and unsanitary surroundings may act as contributing causes. Among the more definitely active influences are: pregnancy and lactation, gastro-intestinal diseases, and intestinal parasites. Pregnancy and lactation are frequent causes, but their manner of operation is obscure. Gastro-intestinal diseases of various sorts have been found in cases of pernicious anemia, including atrophy of the gastric and duodenal mucosa, ulcerations, carcinoma, etc. The manner of operation of these is obscure, though recent experimental work, tending to show that pernicious anemia is hemolytic in nature, suggests that poisons are generated in the gastro-intestinal tract, and, gaining access to the blood, cause its destruction. Among the evidences favoring this hemolytic theory, beside that furnished by direct experimental intoxication, are the peculiar pigmentation of

the liver and the excess of coloring-matter in the urine. Of the intestinal parasites that occasion a pernicious form of anemia, the Anchylostoma duodenale and Bothriocephalus latus are important. Other parasites occasionally cause severe anemia, but rarely, if ever, forms suggesting true pernicious anemia. The manner of production of anemia by parasites is still obscure. Some have held that the loss of blood (especially in the case of Anchylostoma) is the important cause; but there are instances in which but little blood is lost. Others believe that the parasites generate poisons in their life or by decomposition after their destruction, and that these poisons act as hemolytic agents.

In addition to the above, hemorrhages, systemic diseases (malaria, syphilis, and tuberculosis), and various kinds of infection have been considered as causes. Among the infectious agents various bacteria and protozoan organisms have been described. None of these seems to be of importance.

Pathologic Anatomy.—Various secondary changes are met with, those in the blood-making organs being most important. The bone-marrow of the long bones is red and softened and often quite hemorrhagic (for details, see Bone-marrow). This change was formerly regarded as a primary and causal one. At the present time it is looked upon as secondary and reactive to the severe anemia. It represents the effort of the bone-marrow to compensate for the active blood-destruction. The spleen is sometimes enlarged, and may be considerably so. (Pigmentation of the spleen will be referred to below.)

The liver, kidneys, and especially the heart suffer degenerative changes (fatty) in severe cases. Similar alterations in the blood-vessels may cause punctate hemorrhages (especially in the retina), or larger hemorrhages in various situations. The lesions of the gastro-intestinal tract have been referred to. Some of them are doubtless secondary to the anemia; others may be primary.

Degenerations of the posterior and lateral columns of the spinal cord are frequent. They seem to be due to a toxic agent rather than to hemorrhages.

Pigmentation of the liver, spleen, kidneys, and other organs is a significant condition in evidence of the active hemolysis supposed to occur in this disease. The pigmentation of the liver is most important, and seems to be characteristic. It occurs in the hepatic cells of the periphery of the lobules and in the endothelial cells of the lymphatic channels and capillaries in the same situation. The pigment is iron-containing, and may be well demonstrated by applying the iron reactions (sulphid of ammonium; hydrochloric acid and ferrocyanid of potassium—forming Prussian blue).

The Blood.—The color of the blood is often strikingly pale; though it may be dark in spite of marked anemia. The specific gravity is reduced. The marked feature of the disease is pro-

nounced oligocythemia. This progresses rapidly, and in ordinary cases the number of red corpuscles sinks to 1,000,000 or less per cu.mm.: at the same time changes in size (microcytes and megalocytes) and in shape (poikilocytes) make their appearance, and reach grades rarely attained in other diseases (see Fig. 145). Nu-

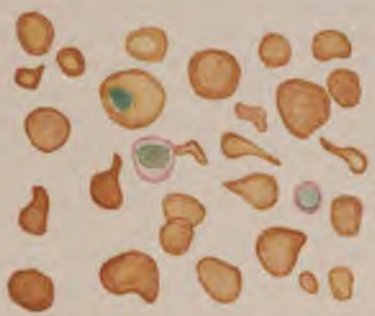

FIG. 145.—Blood in pernicious anemia, showing irregularity in the size and shape of the red corpuscles; one nucleated red corpuscle (megaloblast) and two leukocytes; stained with Ehrlich's triple mixture.

cleated red corpuscles are always present in some number and are usually abundant (Fig. 145). The larger forms (megaloblasts), as a rule, predominate; but in some cases the smaller forms are more abundant. Karyokinetic figures may be found in the nuclei. Polychromatophilia is generally present. The leukocytes may be decreased or normal in number; in the late stages leukocytosis is not uncommon, and it may become extreme. The larger mononuclear leukocytes are usually more abundant than in health, and myelocytes often occur in considerable numbers. In the terminal leukocytosis of pernicious anemia the lymphocytes often predominate.

The fibrin-factors have been found in increased quantity in chemical examinations, and albumoses (peptone ?) and excessive quantities of xanthin-bodies have been detected in some cases.

Pathologic Physiology.—Pernicious anemia has many characteristics of an intoxication, and there are undoubtedly toxic bodies in the blood, whether these be essential or incidental. Some investigators claim to have obtained putrescin and cadaverin from the urine. There is more active metabolic tissue-consumption than in health; but the relations of oxidation to some of the secondary lesions of the disease require further study.

Leukemia.

Definition.—Leukemia is a disease of hemogenesis, characterized by increase in the number of leukocytes in the circulating

blood and by pathologic changes in the bone-marrow, spleen, and lymphatic glands.

Etiology.—Various diseases (malaria, syphilis, rickets, etc.) have been regarded as predisposing causes. The same is true of pregnancy, lactation, traumatism, exposure, and other influences. Sometimes heredity seems to be an important element.

Infection has been suspected as the direct cause of leukemia by many observers, and various forms of bacteria have been discovered in the blood and tissues. There are certainly some very striking facts in favor of an infectious nature, the most important being the apparent contagiousness in a few cases. The various micro-organisms need not be enumerated, as none of them has been proved to be pathogenic. Bodies resembling protozoa have been found in the blood and in the organs (lymphatic glands), but the nature and significance of these are uncertain.

The relations of the lymphatic lesions to the condition of the blood requires consideration. Virchow held that active proliferative change in the lymphadenoid tissues is the pathologic foundation of the disease and the source of the increased numbers of leukocytes in the blood. This view was strongly supported by Flemming's discovery of karyokinetic changes in the cells of the lymphatic glands and spleen. Another school of pathologists maintained that the increased proportion of leukocytes results from retardation in leukocytic destruction, and that the peculiar lesions of the lymphadenoid tissues result from the deposit of the leukocytes from the blood. Most authorities agree that there is some deposition of this kind, but hold to the view of Virchow that the enlargement of the organs comes in the main from primary disease of the affected organs.

Pathologic Anatomy.—The lesions of the solid organs principally affect the spleen, the bone-marrow, and the lymphatic glands, and the terms lienal or splenic, medullary or myelogenous, and lymphatic leukemia are applied. In the majority of cases the spleen and bone-marrow are involved, and the name lienomedullary leukemia is used. Pure lymphatic leukemia is comparatively rare, but involvement of the lymphatic glands with the spleen and bone-marrow is common. A few cases of pure myelogenous leukemia have been described, but their nature was not certainly determined.

(The changes met with in the lymphatic structures are discussed in the appropriate sections and in the chapters on Tumors.)

In a few instances the primary lesion was lymphadenoma of the thymus gland or its remnant. Occasionally the primary disease is in the lymphadenoid tissues of the gastro-intestinal tract. Primary dermal leukemia has been described (lymphodermia perniciosa), but is not satisfactorily established.

Among the secondary lesions are lymphoid infiltrations of the

liver, kidneys, lungs, heart, and other tissues. The organs show areas of light color, or a streaked or mottled appearance, due to the deposition of masses of lymphoid cells (Fig. 146). Secondary

FIG. 146.—Lymphoid infiltrations between the renal tubules, from a case of leukemia.

degenerations of the heart, liver, and kidneys may result from the lymphomatous deposits, or from the impoverished state of the blood and the presence of toxic substances. Scleroses of the spinal cord may be met with, as in pernicious anemia.

The Blood.—The blood is often light in color and may be quite milky in appearance. The specific gravity is lowered. The alkaline reaction is less decided than normal, and in some cases the reaction has been found acid, probably from rapid change after removal from the body. Coagulation is slow. This has been attributed to the presence of albumoses in the blood.

The conspicuous feature in the blood is the increased number of leukocytes. In moderate cases there are from 100,000 to 300,000 white corpuscles per cu.mm. In severe cases the number is greater; while in mild or beginning cases, or in cases under active treatment, the number may for a time be normal or subnormal. I have at the present time under observation a case in which the leukocytes have fallen to 3,000 from 500,000 per cu.mm. Rapid fluctuations in number are very common.

The study of the blood led Virchow to distinguish two forms of leukemia: that in which small forms of leukocytes predominate (lymphemia), and that marked by the excessive number of large cells (splenemia). This distinction may still be made, but the significance attributed to it as an indication of the organs primarily affected cannot now be sustained. It is true that in lienomedullary leukemia large cells usually predominate, while lymphocytes are conspicuous in lymphatic forms of leukemia; but

transitional cases rob the distinction of its practical importance. It is here retained for the sake of convenience of description.

Lienomedullary Type.—The blood presents a great excess of white corpuscles and more or less decided poverty in red cells. The proportion of white to red corpuscles is often 1 : 3, 1 : 2, or even 1 : 1. The larger mononuclear leukocytes (including normal mononuclear and transitional elements and myelocytes) predominate over the lymphocytes and polymorphonuclear elements (Fig. 147). The latter two forms, however, are actually increased.

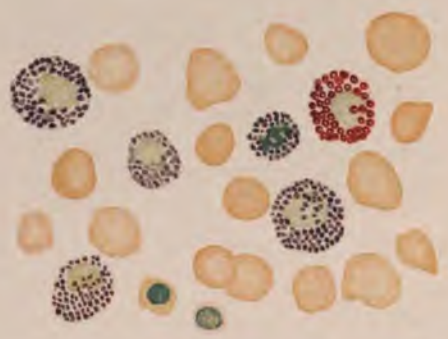

FIG. 147.—Blood in lienomedullary leukemia, showing several mononuclear neutrophiles (myelocytes), one polymorphonuclear neutrophile, and an eosinophile; a nucleated red corpuscle and a lymphocyte are seen in the lower part of the illustration; stained with Ehrlich's triple mixture.

Myelocytes are usually found in great numbers, and are an evidence of implication of the bone-marrow. There is usually an actual increase in the number of eosinophile elements, but the percentage-proportion is rarely increased. Basophilic leukocytes (mast-cells and finely basophilic forms) are present in numbers greatly in excess of those found in health. The red corpuscles present the usual features of anemic blood, and nucleated forms are particularly abundant. This is regarded as an evidence of disease of the bone-marrow.

A peculiar constituent of the blood are the Charcot-Neumann crystals. These are polyhedral, needle-shaped crystals of uncertain composition, met with in the blood after death or some time after removal from the body, and exceptionally in the fresh blood. They were first detected in the bone-marrow.

Lymphatic Type.—The leukocytosis is less marked than in the lienomedullary type. The lymphocytes predominate (Fig. 148), but actual excess of large mononuclear forms and polymorphonuclear leukocytes is observed. Myelocytes occur in small numbers; exceptionally in considerable proportion. The number of red corpuscles is decreased, and nucleated red cells may be present.

Pathologic Physiology.—Leukemia is usually a progressively destructive disease. The nature of the disturbances, however, is only partly known. The blood contains toxic substances generated by leukocytic destruction (xanthin-bodies) and acids (lactic, acetic, etc.). Albumoses are present in varying propor-

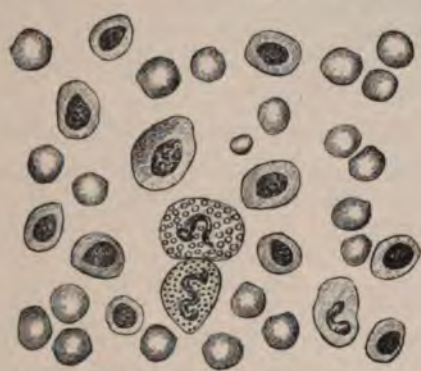

FIG. 148.—Lymphatic leukemia, showing excess of lymphocytes.

tions, and probably play an important part in the pathology. The urine frequently contains excess of xanthin-bases and uric acid.

Acute Leukemia.—In a certain number of cases leukemia seems to run an acute course, terminating in from a few weeks to a few months. The characters of the blood are much the same as in ordinary chronic leukemia (especially the lymphatic type), and the lesions are similar. Gastro-intestinal lesions (ulcers in the mouth, stomach, or intestines) and petechial hemorrhages (purpura) are frequent. In several instances distinct contagiousness was noted. The exact pathology of this condition remains obscure; it is very probable that there is some form of acute infection.

Hodgkin's Disease.

Pseudoleukemia, or Hodgkin's disease, resembles leukemia in the lesions of the solid organs, but differs in that the blood does not present increase in the number of leukocytes. The lymphatic glands enlarge more quickly than in leukemia and the spleen and marrow are less frequently involved, but otherwise no distinction can be made. Cases of Hodgkin's disease sometimes become converted into leukemia, and the reverse has been known to take place. It has been held by some that Hodgkin's disease represents an aleukemic stage of the same disease.

Pseudoleukemia Infantum.

Under this name von Jaksch described a form of leukocytosis, with enlargement of the spleen and liver, occurring in children.

There is rapid and excessive oligocythemia, and the leukocytosis is pronounced. Leukocytes of all types are present, and give to the blood a curiously variegated appearance. There is no striking difference, however, from the characters of the blood met with in other cases of leukocytosis in infancy. Rickets and congenital syphilis seem to be closely related to this form of disease.

The enlargement of the spleen and liver is not of the nature of that seen in leukemia or Hodgkin's disease, but is simply a chronic hyperplastic condition.

FOREIGN BODIES AND PARASITES.

Foreign Bodies in Blood.—Various kinds of particles may gain access to the blood-current and may be carried to peripheral parts of the circulation. In anthracosis a lymphatic gland may attach itself and, after softening, rupture into a vein. The particles of carbon are thus distributed in the blood. Small portions of tumors, of the heart-valves, calcareous particles from atheromatous plates, and portions of thrombi are frequently transported by the blood. Charcot crystals are met with in leukemia, and pigment-matter, due to disintegration of the blood itself, is seen in malaria.

Parasites in the Blood.—Among the animal parasites are the malarial plasmodium, which occurs within the red corpuscles or free in the plasma; the Distoma hæmatobium, which occupies the portal vein; and the embryos of the Filaria sanguinis hominis. (These are more fully described in the section on Parasites.) Portions of hydatid cysts or of cysticerci and trichinæ are occasionally conveyed in the circulation.

Vegetable Parasites.—Mould-fungi sometimes gain entrance into the circulation and lead to serious embolism, as does also the actinomyces. Of the pathogenic bacteria, the spirillum of relapsing fever and the bacillus of anthrax are most abundant in the blood. Other micro-organisms are more difficult of demonstration, though micrococci of suppuration, the bacillus of influenza, and even tubercle-bacilli have been detected.

METHODS OF EXAMINING THE BLOOD.

The purely clinical examinations, such as the enumeration of the corpuscles and the estimation of the percentage of hemoglobin, need not be here described. The microscopic examinations alone will be considered.

Examination of the Fresh Blood.—A drop of blood is obtained from a prick into the end of a finger or the lobe of the ear. The finger or ear is first cleansed, then pricked with a lancet, and the first few drops of blood wiped away. A small drop is then received upon a carefully cleansed thin cover-glass, and this is laid on an equally clean and slightly warm glass slide. The

blood spreads into a thin film from the weight of the cover-glass. If prolonged examination is to be made, a ring of vaselin around the edges preserves the specimen for some hours.

The examination should be made with an oil-immersion lens. Malarial parasites, the spirocheta of relapsing fever, and filariæ are quite readily detected in such specimens; and the size and shape of the red corpuscles and the ameboid movements of the leukocytes can be determined. For the last purpose a warming-stage is requisite if a prolonged examination is to be made.

Examination of Fixed Preparations.—Thin cover-glasses are carefully cleaned with soap-water, then with clear water, and finally with alcohol. A drop of blood is placed upon one of the glasses and a second glass is laid upon it. The blood spreads into a thin film, and the cover-glasses are then slid apart and allowed to dry in air.

Fixation of the blood may be accomplished by immersing the prepared cover-glass in a mixture of equal parts of absolute alcohol and ether for from five to thirty minutes. For certain stains (notably the neutrophilic mixture) a better method of fixation is the employment of heat. The most accurate method of heating is to place the cover-glass in an oven at 120° C. (248° F.) for an hour; but I find that drawing the cover-glass rapidly through a Bunsen flame three times accomplishes the purpose almost as well. Special methods of fixation, as with bichlorid of mercury, picric or osmic acid, etc., are rarely necessary.

Staining.—A useful stain to determine the morphology of the corpuscles is Gollasch's mixture:

Eosin crystals	0.5
Hematoxylin	2.0
Glycerin	
Distilled water	
Absolute alcohol	āā 100.0
Glacial acetic acid	10.0
Alum	slight excess.

The solution must be allowed to "ripen" by exposure for several weeks in a light place. The specimen is stained for two or three minutes, washed in water, and examined. The various pathologic conditions of the red corpuscles are brought out, and the morphology of the leukocytes is well shown. The oxyphilic granules stain sharply with the eosin.

Similar results are obtained with the following mixture:

Methylene-blue, saturated aqueous solution	40
Eosin, ½ per cent. solution in 75 per cent. alcohol	20
Distilled water	40

The specimen may be stained for from three to five minutes, but better results are obtained by placing the stain containing the

cover-glass preparation in an oven at 37° C. (98.6° F.) for an hour. The morphology and changes in the red corpuscles are clearly shown, and the oxyphilic and basophilic granules of the leukocytes are well stained—the former red, the latter blue. The basophilic granules of the leukocytes are especially distinct.

Neutrophilic granules are best stained with Ehrlich's triple stain:

Orange G, saturated aqueous solution	120 to 135
Acid fuchsin, saturated aqueous solution	80 to 165
Methyl-green, saturated aqueous solution	125
Distilled water	300
Absolute alcohol	200
Glycerin	100

The first two stains are mixed, and the third is added gradually, stirring constantly. The water, alcohol, and glycerin are then added. Very often less acid fuchsin and more methyl-green give better results. The fixed preparation is stained for three minutes and washed in water. The red corpuscles take the orange stain; the nuclei of white and red corpuscles and basophilic granules take the green; the oxyphilic granules take the red; and the neutrophilic granules take the violet or purple of the mixture.

Staining of Parasites.—The malarial parasites may be satisfactorily examined in unstained specimens, but it is sometimes desirable to study them after staining. Cover-glass preparations are made as before described, and fixed by heat or by immersion in the absolute alcohol-ether mixture for from thirty minutes to several hours. The staining may be accomplished with any of the various eosin-methylene-blue mixtures, but Plehn's solution has been specially recommended for the purpose:

Methylene-blue, saturated aqueous solution	60 c.c.
Eosin, ½ per cent. solution in 75 per cent. alcohol	20 c.c.
Distilled water	40 c.c.
Potassium hydrate, 20 per cent. solution	12 gtt.

This stains the malarial organisms blue, the red corpuscles red. Similar solutions stain filariæ satisfactorily, and are useful in demonstrating various bacteria in the blood.

CHAPTER II.

DISEASES OF THE LYMPHATIC TISSUES.

THE SPLEEN.

Anatomic Considerations.—The spleen is practically a complicated lymphatic gland with close relations to the circulation. It is enclosed in a fibrous capsule, from which trabeculæ

enter into the substance of the organ and give off subdivisions that unite and form a framework, in the meshes of which lymphoid tissue is embedded. The splenic artery enters at the hilum and subdivides into numerous branches which traverse the trabeculæ. Side branches are given off from the trabecular arterioles; these penetrate the splenic pulp and are surrounded by denser aggregations of lymph-cells, which are visible to the naked eye as the Malpighian bodies. All of the terminal arteries discharge their blood directly into the spaces of the splenic pulp, from which it is re-collected into the veins. The spaces contain, in addition to lymphoid cells and red blood-corpuscles, larger cells often containing pigment-granules or even small blood-corpuscles.

The weight of the spleen in the adult varies from 140 to 200 gm.

The splenic function remains in doubt. It seems to have some connection with the process of manufacture of leukocytes, and is one of the sources of red blood-corpuscles. It may also be the place of destruction of red corpuscles, and in cases of general hemolysis, or blood-destruction, the blood-pigment and fragmented corpuscles are especially arrested in this organ.

Pathologic Physiology.—The relations of diseases of the spleen to the general health are still obscure. It has been held by some pathologists that this organ plays an important part in the process of immunization or combating infectious diseases. The fact that bacteria and foreign bodies circulating in the blood are arrested in the spleen to such a large extent warrants the suspicion that this organ is important in arresting irritants, and thus preventing their gaining access to more vital parts. Experimenters, however, have found no uniform increase of susceptibility to micro-organismal inoculation on the part of desplenetized animals. For the present, therefore, we can only suspect that removal or disease of the spleen renders individuals more vulnerable to infections.

The effect of removal of the spleen in human beings is surprisingly slight. A certain amount of anemia and general deterioration of health follow the operation, but seem to be the result of the operation *per se*, rather than of removal of the organ. Subsequently, complete health is regained.

ABNORMAL DEVELOPMENT AND SITUATION.

Complete absence of the spleen has sometimes been noted in children that lived for several years. More commonly slighter defects, such as unusual smallness or excessive lobulation, occur. Very often small accessory spleens, the size of a pea or a marble, are found.

Movable Spleen.—The organ may be quite movable, either as a congenital condition or as the result of enlargement and resulting

traction upon its attachments. Downward displacement and movability are frequently found in cases of splanchnoptosis. Twisting of the pedicle of a movable spleen may lead to strangulation of the circulation and consequent necrosis.

CIRCULATORY DISTURBANCES.

Anemia may occur in cases of general anemia resulting from hemorrhage or inanition. The spleen presents a contracted appearance, the capsule being wrinkled, and on section the substance is found to be lighter in color and the fibrous stroma is more prominent than normal.

Hyperemia may be active or passive. *Active hyperemia* is a physiologic condition during digestion, when the spleen increases somewhat in size. Intense congestion occurs in a number of diseases, but so commonly passes into inflammation that it will be described under that heading. *Passive congestion* is most marked in cases of cirrhosis of the liver, but also occurs in association with hyperemia of other organs as the result of cardiac failure, of emphysema, or of other diseases obstructing the larger venous channels. The spleen is greatly enlarged and of a dark-red color, and the capsule is often tensely distended; the Malpighian bodies are less visible than normally. After long continuation of the process hyperplasia of the trabeculæ and the fibrous stroma generally takes place. The spleen may be greatly enlarged and very dense at this stage. Subsequently contraction of the newly-formed fibrous tissue may lead to atrophy of the proper splenic substance and increased induration of the organ (*cyanotic induration*). Considerable pigmentation is found in such cases from the destruction of the stagnated blood.

Hemorrhages in the spleen may be the result of traumatism, when large hematomata may form, especially just beneath the capsule. Small areas of hemorrhage are not infrequent in intense infections with splenitis, but it is difficult to draw a line between hemorrhage and the overfilling of the spaces by congestion, since the blood under normal conditions enters directly into the splenic pulp.

Embolism of the splenic artery is very common in cases of endocarditis or thrombosis in the left heart or aorta. As the spleen contains abundant "terminal arteries," infarction is the common result. The area may remain light colored, constituting an anemic infarct; or it may become overfilled with blood, when hemorrhagic infarction results. In either case there is a wedge-shaped lesion, with the base toward the surface of the organ and the apex within, harder than the surrounding tissue, and usually somewhat elevated. The swelling and elevation in the case of anemic infarction are partly due to a zone of hyperemia which

usually surrounds it. Complete resolution may occur, but more commonly the area involved undergoes coagulation-necrosis and softening, and as absorption takes place fibrous overgrowth gives rise to the formation of a scar. There may be numerous infarcts of small size, or a single large one sometimes occupying as much as half of the organ. (Septic infarction and its results are discussed under Abscess of the Spleen.)

Thrombosis of the splenic vein may occur in association with thrombosis of the portal vein. It causes intense passive hyperemia of the spleen. Occasionally calcification of thrombi gives rise to the formation of *splenic stones.*

INFLAMMATION OF THE SPLEEN, OR SPLENITIS.

Splenitis occurs in a variety of conditions, and may present itself in several forms, among which the acute enlargement of the spleen of infectious diseases and localized splenitis, or abscess of the spleen, are the principal.

Diffuse Splenitis.—The splenic enlargement of infection occurs particularly in typhoid fever, malaria, septicemia, typhus, and relapsing fevers; and less markedly in pneumonia, scarlet fever, small-pox, and influenza. In the earlier stage the spleen is simply congested and presents a dark-red color; is firm, and the capsule more or less distended. On section the Malpighian bodies are usually obscured, and there may be visible areas of hemorrhagic extravasation. Microscopically at this stage the blood-vessels are all found overdistended, and the spaces within the splenic pulp are filled with red and white blood-corpuscles. If the process has continued for some time, pigment-masses and degenerated corpuscles are visible, but there are as yet no evidences of inflammatory hyperplasia of the splenic pulp or stroma.

As the process advances the spleen may become softer and may be quite diffluent. On section the substance is now found to be lighter in color, the Malpighian bodies are distinct, and, particularly in violent septic cases, are decidedly prominent, presenting themselves as yellowish-gray punctæ, somewhat resembling miliary tubercles. The capsule of the organ may still be tensely distended, but in other cases is wrinkled, as if some shrinkage of the spleen had occurred in the change from the first stage of congestion to that of well-defined inflammation. Microscopically there are now apparent great increase of the cells of the splenic pulp, and particularly of those constituting the Malpighian bodies. That this increase is partly at least due to active proliferation is known from the abundance of mitoses. There is also hyperplasia of the stroma and trabeculæ, and of the endothelial cells of the spaces.

In still later stages signs of degeneration may become prominent. This is apparent in the increasing softening of the organ,

while under the microscope there are found cellular degenerations leading to the formation of detritus, to fragmentation of the nuclei of the cells, and to pigmentation by disintegration of red blood-corpuscles.

Terminations.—Most frequently complete resolution occurs. Sometimes, however, persistence of the inflammation is noted; and, when repeated attacks of the infection occasion repeated attacks of splenitis, chronic inflammatory hyperplasia is the result. This is especially marked in the "ague-cake" spleen of malaria. Spontaneous rupture or rupture from slight trauma may result from the softened and distended condition of the organ. Finally, suppuration may ensue, either in the form of a diffuse softening and purulent infiltration of the entire organ, or in the form of a localized abscess beginning at the point of greatest involvement.

Circumscribed Splenitis, or Abscess of the Spleen.—This may be the termination of an acute diffuse splenitis, particularly in septicemia and typhoid fever; or it may be caused by extension of diseases of neighboring structures, by septic embo-

FIG. 149.—Embolic abscess of the spleen (from a specimen in the Museum of the Philadelphia Hospital).

lism, or traumatic injuries. In the last case, the mechanical injury of the spleen merely furnishes suitable conditions for the action of bacteria conveyed to it through the circulation, or the spleen is actually penetrated and infected. Occasionally abscess may result from the perforation of gastric ulcers or from the extension of other inflammations in the vicinity. An important

group of cases is that in which the abscesses are embolic and metastatic (Fig. 149). Such cases are met with in malignant endocarditis or thrombosis of the heart or aorta, and in cases of pyemia following other infective conditions. The first effect of the embolism is an hemorrhagic or anemic infarction, but this soon undergoes suppurative softening, beginning at the apex of the infarct. Metastatic abscesses are most common near the surface of the organ and are usually multiple, though a single cavity occupying the greater part of the organ may occur. Small collections may become absorbed or inspissated, leaving a necrotic or cheesy collection as a residue. Larger collections may be discharged by perforation into the stomach or intestines, or they may break into the peritoneal or pleural cavity, causing septic peritonitis or pleuritis.

Chronic Inflammation or Chronic Hyperplasia of the Spleen.—Attention has already been called to the slow hyperplasia of the connective tissue and sometimes of the splenic pulp occurring in consequence of chronic passive congestion and of repeated attacks of acute splenitis. The spleen is large in size and firm. The capsule is often tensely distended and may be greatly thickened. The thickening is either diffuse or circumscribed, patches of almost cartilaginous hardness occurring in the latter case. Attachments by fibrous adhesions may fix the spleen to the diaphragm or the neighboring organs. On section the spleen is found dark in color from the presence of abundant pigment, and the excess of fibrous tissue may be visible to the naked eye. Microscopically, increased thickness of the fibrous trabeculæ and of the walls of the small blood-vessels and pigmentation with altered blood-pigment are the conspicuous features.

A somewhat different form of chronic hyperplasia is dependent upon syphilis, especially upon the congenital form. In this the appearances are much the same as in the cases following splenitis or congestion, but, as a rule, the color is somewhat lighter from the fact that the process is a slowly hyperplastic one without acute inflammatory or congestive manifestations. Somewhat similar appearances result from rickets.

ATROPHY AND DEGENERATIONS.

Atrophy of the spleen is very common in old age. The capsule is usually wrinkled and somewhat thickened, and on section the organ is more fibrous in appearance on account of atrophy of the splenic pulp and proliferation of the stroma. Thickening of the capsule sometimes appears in the form of white plates of cartilaginous hardness, which result from inflammatory overgrowth of the capsule (*perisplenitis cartilaginea*).

Amyloid degeneration occurs more frequently in the spleen

than in any other organ. The causes are those which lead to amyloid disease elsewhere. In most cases the degeneration begins in the Malpighian bodies, affecting the walls of the blood-vessels (Plate 2) and the lymphoid elements. On section in such a case there are seen small round areas about the size of a currant-seed, of gelatinous, translucent appearance. These have been likened to grains of boiled sago, and the term *sago-spleen* is not inappropriate. In other cases a more uniform involvement of the whole organ is noted, and the section presents the appearance of boiled ham or dried beef. Considerable enlargement of the organ is noted in such instances, and the tissue is much harder than normal. Beginning amyloid degeneration may be difficult to determine microscopically, but is readily demonstrated by the microscopic staining-reactions (see Amyloid Degeneration).

Hyaline degeneration has been observed in association with amyloid and independent of the latter. It affects the small blood-vessels and the reticulum more particularly.

Pigmentation is a very common result of chronic congestion as well as of repeated acute splenitis; the spleen in cases of cirrhosis of the liver and in chronic malaria is therefore habitually pigmented. The deposit occurs first in the walls of the blood-vessels and later throughout the splenic structure, either within the cells or lying free in the tissue. Occasionally pigment-particles derived from the external world are deposited in the spleen. This is especially true of dust-particles which have reached the circulation from softened bronchial glands. In cases of diseases of other kinds leading to discharge of foreign bodies or tissue-elements into the circulation, the arrest not rarely occurs in the spleen, and reactive congestion or inflammation with enlargement of the spleen may result (*spodogenous splenitis*). Pigmentation of the spleen is seen in progressive pernicious anemia and other conditions in which hemolysis occurs. The pigments resulting from the destruction of red corpuscles are deposited in the liver, spleen, and other organs.

Calcification occurs in the thickened capsule of chronic splenitis and in old infarcts, tubercular or syphilitic areas, and occasionally in thrombi of the splenic vein. Parasitic cysts may be surrounded by calcification.

TUMORS AND PARASITES.

Lymphadenoma of the spleen, as it occurs in the diseases leukemia and pseudoleukemia, like the alterations of the lymphatic glands occurring in the same diseases, may properly be included among the tumors rather than among simple hyperplasiæ. The disease is appropriately designated *lymphadenoma* or *lymphosarcoma*. The spleen may be affected primarily in leukemia (lienal

PLATE 2.

Amyloid degeneration of the spleen, showing a degenerated Malpighian body; specimen stained with hematoxylin and eosin.

or splenic leukemia), or it may be involved after the bone-marrow (myelogenous leukemia) or the lymphatic glands (lymphatic leukemia). The appearances of the organ in leukemia and in Hodgkin's disease are identical. In the earlier stages the spleen is enlarged and soft. On section there is evidence of intense congestion, while at the same time light-colored areas, representing enlarged Malpighian bodies, are visible throughout its structure. Subsequently the hyperplasia of the lymphoid structures increases and the organ becomes lighter-colored and harder than normal. The pressure exerted on the splenic pulp causes anemia, and granular or pigmentary degeneration of the cells, while anemic and hemorrhagic infarctions with subsequent necrosis are likely to form near the surface of the organ. The section of such a spleen presents a peculiarly variegated appearance, while the microscopic examination exhibits wide variations from the normal. The Malpighian bodies are found greatly enlarged, and are composed of aggregations of the ordinary lymphoid cells, together with larger round cells. Mitoses have frequently been demonstrated. The splenic pulp is degenerated, exhibiting large cells enclosing pigment-granules or red corpuscles and detritus.

Sarcoma and Carcinoma.—*Primary sarcoma* of the round-celled, or fibro-sarcomatous, variety has been observed. *Secondary sarcoma*, particularly melanotic sarcoma, and *secondary carcinoma* are more common than primary growths.

Cysts are occasionally discovered. They are small, and are probably due to dilatation of the lymphatic spaces or to atrophy and cystic degeneration of the Malpighian follicles.

Fibroma, angioma, and **lymphangioma** are very rare.

Parasites. — Pentastomum denticulatum, echinococcus cysts, and cysticerci have been observed.

FIG. 150.—Large caseous tubercles in the spleen of a child (Orth).

INFECTIOUS DISEASES.

Tuberculosis of the spleen may occur in the form of minute miliary tubercles, which have a grayish translucent appearance and are usually present in large numbers, especially near the capsule. They may be distinguished from enlarged Malpighian bodies by their greater opacity and their grayish rather than yellowish color. Tuberculosis also occurs in the form of larger caseous nodules, especially in children (Fig. 150). In these cases

there are seen nodular masses the size of a pea or cherry studding the surface and deeper structure of the spleen. This form is called *Affentuberculose* by the Germans, from the resemblance of the large nodules to tubercles met with in monkeys. Histologic examination proves the nodules to be composed of aggregations of tubercles undergoing caseation.

Primary tuberculosis of the spleen has never been observed.

Syphilis may present itself in the form of syphilitic gummata, which are usually multiple and may be either small or large. They are distinguished by their central degeneration or by the fibrous-tissue striations at the exterior.

Diffuse hyperplasia of the spleen is a frequent or almost constant lesion of congenital syphilis.

THE LYMPHATIC GLANDS.

Anatomic Considerations.—The lymphatic glands consist of accumulations of lymphadenoid tissue surrounded by a connective-tissue capsule. There may be distinguished an outer cortical and an inner medullary portion, the former consisting of spherical masses or follicles of lymphoid cells enclosed in a connective-tissue reticulum springing from the trabeculæ, the latter being composed of medullary cords similar to the former in structure, but of elongated form. The afferent lymphatics enter the glands at the hilum and discharge the lymph into the cortical spheres; the liquid filters slowly toward the medullary cords, where it eventually enters the efferent lymphatics. The medullary cords are surrounded by spaces lined with endothelial cells, the lymph-spaces.

ATROPHY.

Atrophy of the lymph-glands occurs in old age and in various marasmic conditions. The glands suffer considerable diminution in size, the cellular elements being particularly affected; they are therefore hard, dry, and often irregular in shape. Fatty infiltration may occur simultaneously with atrophy, the gland in such cases preserving its size and having a decidedly fatty appearance.

HYPERTROPHY.

This is so closely allied to the conditions designated by the name of lymphadenoma that it is difficult to separate the cases which might be considered as strictly hypertrophy.

DEGENERATIONS.

Fatty infiltration is sometimes seen in cases of general obesity and also, as before mentioned, in atrophy of the glands.

Amyloid degeneration is met with in cases of general amyl-

oid disease, and particularly in the cases in which the intestines are affected. The lymphatic glands may, however, be independently involved in cases of tuberculosis attended with suppuration. In such instances the adjacent lymphatic glands are most likely to suffer amyloid change. The morbid process rarely leads to marked alteration of the glands, but the amyloid material may be demonstrated by the staining-reactions peculiar to it. The connective tissue of the trabeculæ and around the blood-vessels is first affected; later, the endothelial cells.

Hyaline degeneration has been described. It affects the blood-vessels and connective tissue of the glands.

Calcification not infrequently forms the terminal condition in cases of necrosis or induration of the glands in consequence of tuberculous or simple inflammation. There may be small calcareous granules scattered through the gland, or the entire gland may be infiltrated.

Necrosis may occur in consequence of tuberculous or syphilitic affections, or of simple inflammation. In the former cases, particularly in tuberculosis, the center of the gland or the entire gland becomes cheesy and soft, often liquefying and discharging the contents by rupture of the capsule. In consequence of simple inflammation, as in certain infectious fevers (typhoid, diphtheria, scarlet fever), a different form of necrosis is met with, areas of the gland becoming soft, pultaceous, and sometimes putrid. The gland may rupture, discharging its contents, or absorption of the liquid with inspissation and a pseudocaseous form of degeneration may result. Finally, the degenerated area may become calcareous.

Pigmentation may follow acute inflammations or traumatic

FIG. 151.—Anthracosis of a bronchial lymph-gland (Orth).

injury of the glands, the extravasations of blood occurring in such conditions leading to hematogenous pigmentation. The blood-pigment occurs in granular masses within the cells of the stroma or within the lymphatic cells themselves. Blood-pigmentation

may also occur in the glands adjacent to areas of hemorrhagic extravasation, the pigment in such cases reaching the glands through the lymphatic vessels and being deposited in the lymph-sinuses, or even in the follicles and cords. Analogous pigmentation from external sources may result from tattooing, and occurs regularly in the bronchial glands as the result of the inhalation of various dust-particles which penetrate the walls of the bronchioles and alveoli and eventually find their way to the bronchial glands through the lymphatic stream (*anthracosis*) (Fig. 151). The glands may be completely black in such cases, and the lymphatic circulation through them may be obliterated. Secondary inflammatory changes result in most cases (see page 337).

INFLAMMATION; LYMPHADENITIS.

Acute lymphadenitis is commonly secondary to inflammations in the neighborhood, the irritants being carried by the afferent lymphatics. Sometimes direct extension of inflammation by contiguity of structure may lead to involvement of the lymphatic glands. Occasionally lymphadenitis is seemingly primary in cases in which the infective irritants have caused no lesion at the portal of entrance to the body.

Pathologic Anatomy.—The glands become enlarged, hyperemic, and considerably infiltrated with liquid. When the inflammation is intense there may be minute hemorrhages. Microscopically the lymph-sinuses are found distended with cells—leukocytes, red blood-cells, and proliferated and desquamated endothelial cells from the lining membrane of the sinuses. The follicles and cords are increased in size from infiltration and probably also from proliferation of the lymphoid cells. The process may become arrested and resolution to the normal condition may ensue. If mild inflammation of this character has continued for a great length of time, or if the condition is repeated, hyperplasia of the trabecular connective tissue, of the blood-vessels, and of the capsule of the gland may lead to a termination in chronic enlargement and induration of the glands.

In cases of greater intensity of the infective cause necrotic or suppurative changes may occur. In the cases of necrosis such as occur in typhoid fever and in diphtheria there may be noted small spots of yellowish-white color in the hyperemic glands, and subsequently these undergo well-marked necrosis. Complete necrotic softening and even rupture of the gland may ensue, or, if the necrosis remains limited in extent, inspissation and sometimes calcification may terminate the process.

Suppurative lymphadenitis is not uncommon. It is seen in the glands below Poupart's ligament in cases of infective wounds of the leg; in the inguinal glands as a result of chancroid or gon-

orrheal urethritis; in the glands of the neck in association with diphtheritic, scarlatinal, or other inflammations of the throat, or following erysipelas; in the axillary glands as a result of wounds of the arm; and in the internal lymphatics in various infective diseases. The term *bubo* is applied to suppurative lymphadenitis of superficial glands. Of particular interest is the tendency to this condition in the plague of the East, or the bubonic plague (*q. v.*).

Pathologic Anatomy.—The changes noted in the gland at the outset are similar to those in the simple inflammations, but under the microscope a greater accumulation of leukocytes is apparent, and the gland tends to soften, with the formation of more or less creamy pus. The capsule may prove resistant for a time, and reactive inflammation around may establish an additional wall. A single gland of a group may be affected, but more commonly the several glands are together involved. Eventually rupture may take place, but in instances in which the process has been circumscribed inspissation of the pus and finally calcification may occur.

In the most intense forms of lymphadenitis hemorrhagic or gangrenous conditions are developed.

Chronic Lymphadenitis leads to induration with enlargement. It occurs as the result of repeated acute attacks or in consequence of long-continued irritation by particles carried to the lymphatic glands from some focus of disease.

Pathologic Anatomy.—As a rule, the process affects the connective-tissue elements of the gland in particular, and there results a considerable amount of induration, sometimes associated with atrophy or necrosis of the proper lymphoid structure. Occasionally, however, the lymphoid elements themselves are hyperplastic, and the normal relation of fibrous tissue, follicles, and medullary cords is preserved.

Microscopically the overgrowth of the connective tissue springing from the trabeculæ, from the blood-vessels, and from the reticulum of the lymphoid portions, is apparent. This may consist of round cells and fibrous connective tissue, or there may be a tendency to the formation of epithelioid cells and even giant-cells.

Pathologic Physiology.—Inflammations of the lymphatic glands are the result of the arrest of irritants of various sorts carried to the glands in the lymphatic channels. This arrest not unlikely serves the purpose of a protection against general dissemination of irritants, and may be of great importance in this way. Complete occlusion of the lymph-sinuses by deposition of solid particles (as coal-dust), or by disease of the glands, may obstruct the lymphatic flow entirely, and a retrograde inflammatory process may result from the damming back of infected lymph or from extension of disease along the lymphatic channels.

INFECTIOUS DISEASES.

Tuberculosis of the lymphatic glands is due in nearly all cases to infection by bacilli reaching the gland through the afferent lymphatics, though occasionally it would seem that hematogenous infection occurs. Under the heading tuberculosis we must include what the older writers designated as scrofulous glands, for in the majority of such cases, if not in all, the disease is essentially tuberculosis, though the mode of infection is not always apparent.

Morbid Anatomy.—The first visible change is the formation of small grayish nodules in the gland, and sometimes the eruption of these is attended with hyperemia and inflammation. Later, these tubercles increase in size and undergo caseous changes (Fig. 152) as elsewhere, and eventually the entire gland may be converted into a cheesy mass, which may liquefy and not rarely discharges through the ruptured capsule. Microscopically, the first appearance is that of gray tubercles containing giant-cells and epithelioid cells, surrounded by a zone of round cells (Fig. 153). Later, the characteristic appearances of hyaline transformation and of caseation are observed. Sometimes the glands in tuberculosis become enlarged and harder than normal, and present areas of grayish color, but do not tend so markedly to

FIG. 152.—Cheesy lymph-gland (Orth).

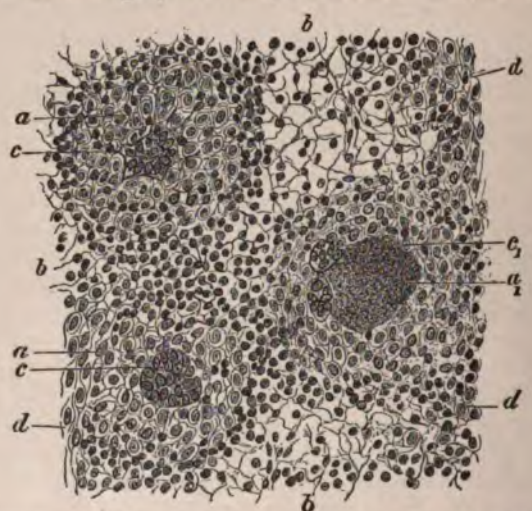

FIG. 153.—Tuberculous lymphatic gland: *a*, recent tubercle with giant-cell (*c*); a_1, inferior caseous tubercle with giant-cell (c_1); *b*, lymphadenoid tissue; *d*, epithelioid cell (Ziegler).

undergo necrosis. In these instances the microscopic examination presents foci composed for the most part of epithelioid cells, and

much less abundant in round cells than are tuberculous tissues as a rule (Fig. 154).

FIG. 154.—Tuberculous lymphatic gland: *a*, lymphadenoid tissue; *b*, large round cells (epithelioid); *c*, large spindle-cells (Ziegler).

Scrofula.—The tuberculous nature of scrofulous lymphadenitis was first demonstrated by the infectiousness of the softened

FIG. 155.—Tuberculous lymphadenitis of the cervical glands (from a case in the Children's Hospital).

glandular material when injected into animals. The micro-organisms themselves may be demonstrable in the earlier stages in the epithelioid or giant-cells, or lying between these; but when the process is at all advanced it is extremely difficult or impossible to demonstrate bacilli.

Individual Groups of Glands.—Among the more commonly affected groups of glands are the cervical (Fig. 155), the bronchial, and the mesenteric. Tuberculous cervical glands occasion considerable tumors in the neck, and it is these in particular that have been classified as scrofulous. Not rarely they advance to complete softening, and rupture on the surface. Sometimes, however, they penetrate deeply, and may rupture into the trachea or esophagus, or into the pleural cavity. The mode of infection is rarely apparent, but in many cases no doubt the micro-organisms enter through the mucosa of the mouth or pharynx, or the tonsils, where they may or may not first occasion specific lesions.

The bronchial glands are affected very frequently in cases in which the bacilli, entering through the lungs, have left no trace of tuberculous disease at the portal of entrance; while in cases of actual tuberculosis of the lungs the bronchial glands are quite constantly involved (Fig. 156). The glands are usually cheesy and

FIG. 156.—Tuberculous lymphatic glands at the bifurcation of the trachea (from a specimen in the Museum of the Philadelphia Hospital).

may become calcareous, but softening not rarely occurs. Perforation of one of the bronchi may lead to acute bronchogenetic tuber-

culosis of the lungs; or the softened gland may discharge into a large vein and thus occasion miliary tuberculosis.

The mesenteric glands are especially involved in children, this condition being known as *tabes mesenterica.* The infection occurs through the intestinal tract; and has sometimes been found due to the ingestion of infected milk or meat. The intestines may first suffer, or the bacilli may penetrate the intestinal mucosa without causing local lesions.

Syphilis.—Enlargement of the lymphatic glands may occur in the vicinity of the initial lesion during the primary period; and is habitually present in all parts of the body during the secondary period, the post-cervical, axillary, inguinal, and epitrochlear groups being most characteristically involved. The glands are hard, and do not tend to soften or suppurate. Microscopically there is found proliferation of the connective-tissue elements throughout the gland.

In the tertiary period *gummata* (*bubo tertiaris*) may be observed, especially in the lymphatic glands adjacent to the diseased viscera.

Leprosy, actinomycosis, and **other infections** occasionally involve the lymphatic glands (see General Pathology).

TUMORS.

Lymphadenoma; Lymphosarcoma.—The term lymphadenoma has been applied to certain enlargements of the lymphatic glands in which the appearance and structure resemble closely those of the normal gland. The nature of many of such cases is obscure, and very likely widely varying diseases have been included. In some instances repeated irritation has occasioned a functional hypertrophy or chronic inflammation of the gland, while in others, doubtless, infectious diseases (especially tuberculosis) may have been mistaken for tumors. We may restrict the term lymphadenoma to apparently causeless enlargements of the lymphatic glands in groups. In some cases the disease tends to involve the glands in all parts of the body, as well as to invade the spleen, the liver, the kidneys, and other organs. Enlargements of this sort occur in leukemia and Hodgkin's disease (Fig. 157). In cases of localized enlargements of the lymphatic glands it is likely that local irritation, as a rule, plays a prominent part in causation.

Pathologic Anatomy.—Two forms of lymphadenoma have been described, the hard and the soft. In the former the glands of the group are enlarged and hard, the capsule is thickened, and the trabeculæ increased. Microscopically there is evidence of excessive proliferation of connective tissue, though overproduction of lymphoid elements may occur at the same time. In soft lymph-

adenoma the gland has much of its natural appearance, although it is somewhat more opaque and grayish. There is no tendency to soften or suppurate, and the individual glands of a group, though closely held together, do not fuse entirely. The distinction of lymph-sinuses, follicles, and medullary cords is less marked than normally, and the appearance is that of a uniform lymphoid

FIG. 157.—Hodgkin's disease, showing marked enlargement of the glands of the right axilla, with consequent dropsy of the arm; less marked involvement of the submaxillary, cervical, and inguinal lymph-glands.

tissue composed of a cellular reticulum in which small round cells are embedded. From an anatomical standpoint the term lymphosarcoma is applicable, and still more from the fact that nodular infiltrations with enlargement are usually found in the spleen as well as in organs which do not normally contain lymphatic tissue, such as the liver, the kidneys, and the heart. In some cases of lymphosarcoma the blood contains excess of leukocytes. These cases are known as leukemia. In other cases, though anatomical differences are not detectable, the blood contains no excess of leukocytes. These cases may present the clinical features of a

progressive anemia, and are known as Hodgkin's disease, or pseudoleukemia. In occasional instances transformation of Hodgkin's disease into leukemia, or the reverse, takes place, and there seems to be no well-established dividing-line between the two conditions (see, also, Lymphadenoma, in Part I.).

Sarcoma.—Other forms of sarcoma are sometimes met with as primary localized new growths of the lymphatic glands. Such are not rarely seen in the mediastinum. In these instances the capsule of the gland is penetrated and local extension to neighboring glands and other surrounding structures is commonly observed, but the entire group of glands is not, as a rule, affected. General metastasis may occur, but affects the larger organs rather than the lymphoid tissues. Round-cell, spindle-cell, and alveolar sarcoma are the forms described. Secondary sarcoma occasionally involves the lymphatic glands.

Carcinoma is always secondary, the lymphatic glands being the most frequent seat of secondary cancer.

BONE-MARROW.

Anatomic Considerations.—The marrow of the bones is a lymphadenoid tissue consisting of a reticulum of connective-tissue cells, supporting a rich network of capillaries and venules of unusual width. The cells proper of the marrow are rounded and vary greatly in size. They contain a clear nucleus, and many of them neutrophilic granules. In addition to these *marrow-cells* there are occasional giant-cells lying near the bony trabeculæ; and more frequently cells containing pigment-granules; also nucleated red corpuscles, non-nucleated red corpuscles, and large cells enclosing corpuscles. After the first few years of life the marrow of the long bones loses its reddish color and becomes more or less yellow, and there is then found, microscopically, a great preponderance of fat-cells.

DEGENERATIONS.

Fatty Infiltration.—The fat which occurs normally in the marrow may be excessively developed in conditions of general obesity, but also at times in marantic individuals, or as a result of atrophy of the bony tissues.

Mucoid degeneration is occasionally seen, and **necrosis** may form a part of the processes of inflammation.

Pigmentation occurs in the bone-marrow in cases of destruction of blood, as in malaria or various hemolytic toxemias, as the bone-marrow is one of the filtering organs for the blood.

ATROPHY.

Atrophy of the bone-marrow is not infrequent in old age or in marasmic conditions.

HYPERTROPHY.

Hypertrophy of the bone-marrow occurs in various anemic diseases. Strictly speaking, there is atrophy or disappearance of the fat-cells of the yellow marrow of the long bones and hyperplasia of the true lymphoid elements. The bone-marrow, therefore, assumes more and more the appearance of the red or lymphoid marrow of early life. The highest grades of this transformation are met with in progressive pernicious anemia (Plate 3, Fig. 1) and in leukemia, but similar changes occur in cancer, tuberculosis, and various other cachectic conditions. The marrow becomes soft and red in color, and in extreme cases may be dark-red and liquid.

Microscopically the fat-cells are much reduced in number and may be wholly wanting. In their place are found marrow-cells of various sizes, many of them containing neutrophilic and eosinophilic granulations. Cells containing pigment-granules or red blood-corpuscles, and nucleated red blood-corpuscles of different sizes, are seen in varying numbers.

In leukemia the marrow often has a mottled appearance, light-colored areas composed largely of white corpuscles arrested in the marrow or formed *in loco* by active proliferation, alternating with darker areas of congestion or hemorrhagic extravasation (Plate 3, Fig. 2). The light-colored areas may predominate and may present a puriform appearance (pyoid marrow). More rarely the appearance of the marrow in leukemia is similar to that seen in the other anemic diseases. Microscopically a curious constituent is discovered—the Charcot-Neumann crystals (see Leukemia). It has been held that leukemia is dependent primarily upon the disease of the bone-marrow (myelogenous leukemia), but the marrow-changes, in some cases at least, are secondary.

INFLAMMATION.

Osteomyelitis, or inflammation of the marrow, is infectious in nature, and may occur in the course of various diseases, such as typhoid fever, relapsing fever, small-pox, septicemia, and the like; or as a result of traumatism and direct infection. The marrow-disease may be the only expression of an infection which has arisen in an obscure manner (infectious osteomyelitis). In the cases occurring in the course of infectious diseases, the changes are comparable to those which occur in the spleen under the same circumstances. The marrow assumes a redder color than normal, and it may be studded with punctate hemorrhages. In other

PLATE 3.

FIG. 1.—Bone-marrow in pernicious anemia. FIG. 2.—Bone-marrow in leukemia.
(Kast and Rumpel.)

cases areas of necrosis and granular degeneration of the cells may be present, and increased numbers of lymphoid cells or white blood-corpuscles may be discovered. Sometimes the marrow is quite purulent (see Diseases of Bone).

INFECTIOUS DISEASES AND TUMORS.

(These will be referred to in the discussion of Diseases of the Bones.)

THE THYMUS GLAND.

Anatomy and Development.—The thymus gland at its earliest period consists of endodermic epithelium arranged somewhat like that of an epithelial gland. Later, mesoblastic lymphoid cells and connective tissue infiltrate it; and at birth and for several years thereafter it is composed largely of lymphoid tissue arranged like the follicles of lymphatic glands. Here and there in the center of these may be seen concentric whorls (the corpuscles of Hassall), the remains of the original epithelial cells. After the second year of life retrogressive changes take place, and by the age of adolescence the gland is converted into a mass of fatty connective tissue.

Congenital Abnormalities.—Complete absence or various minor irregularities of the thymus may occur; at times it is found enormously hypertrophied. In the latter case the root of the great vessels, the pericardium, and heart may be covered over by the enlarged thymus, and sudden death seems at times due to this cause. *Thymic asthma*, so-called, is rarely, if ever, due to enlargement of the thymus.

Circulatory Disturbances.—Intense *congestion* and punctate *hemorrhages* may be found in cases in which death has occurred from asphyxia.

Inflammation of the thymus as a primary disease is of doubtful occurrence, but abscesses may occur in cases of general pyemia, or from extension of suppurative affections of adjacent parts.

Infectious Diseases.—*Syphilis* occurs in the form of gummata, especially in the new-born. Caseation and softening of the gumma may occur, and a resemblance to abscess is thus produced. *Miliary* or *caseous tuberculosis* occasionally invades the thymus gland.

Tumors.—The thymus or its remnant is not infrequently the place of origin of *lymphosarcoma* of the anterior mediastinum (see Fig. 47). Tumors having this origin may be recognized by their shape and by the regularity of their outlines, the lymphosarcomata (lymphadenomata) of the lymphatic glands of the anterior mediastinum having a more irregular lobulated appearance. *Ordinary round-celled sarcoma* has been described, and *epithelioma* springing from the corpuscles of Hassall has been seen in a few cases.

CHAPTER III.

DISEASES OF THE CIRCULATORY SYSTEM.

THE HEART.

Development of the Heart.—At the earliest period of fetal life the heart is represented by a hollow tube, lying toward the ventral aspect of the neck. Later this assumes an S-shape, and still later a transverse constriction marks the position which the auriculoventricular grooves subsequently occupy. Finally, vertical grooves divide the lateral halves into the respective auricles and ventricles; and the *truncus arteriosus*, which is at one of the ends of the primitive tube, becomes divided into two parts, forming the pulmonary artery and aorta. The separation of the cavities within is accomplished by the outgrowth of septa springing from the walls of the primary cavities. The septum dividing the ventricles is the first to appear, and springs forward from the posterior wall. Next a budding is seen in the position which is later occupied by the tissue between the auriculoventricular orifices of the two sides; still later the auricular cavity is divided into two parts by a process beginning at the lower and posterior part. The septum which divides the *truncus arteriosus* is essentially connected with or is a part of the septum which separates the ventricles. All of these changes begin from the seventh to the ninth or tenth week of fetal life.

Anatomic Considerations.—The heart consists of three layers, the endocardium, muscular layer, and pericardium. The endocardium is the inner lining of the organ, and is composed of a layer of endothelial cells resting upon a stratum of connective tissue. It is continuous with the lining membrane of the arteries, and by duplications forms the valves. The muscle of the heart is arranged in lamellæ. The fibers of the heart-muscle are peculiar in being branched and in being devoid of a sarcolemma. The pericardium resembles the endocardium in structure.

The blood-vessels supplying the heart-muscle are branches of the coronary arteries. They divide and subdivide, and afford abundance of blood proportionate to the needs of so active an organ. The lymphatic system is equally developed. The nervous system includes numerous ganglionic centers in the furrows between the ventricles and between the auricles and ventricles. Other ganglion-cells are found within the muscle itself.

Details regarding the gross structure of the organ need not be mentioned here. The weight of the heart in the adult male is about 300 g., in the adult female about 250 g. The volume of the entire organ in the adult male is about 290 to 310 cu.cm., in the adult female about 260 to 280 cu.cm.

CONGENITAL DISEASES AND DEFORMITIES.

Abnormalities of the heart may be discovered in the new-born, and are the result of developmental defects, or less commonly of

fetal endocarditis and myocarditis. The older pathologists attributed many of the conditions to inflammatory changes, which more accurate knowledge of the development of the heart clearly indicates are the result of defects in development.

Abnormality of Position.—The heart may retain its position high up toward the cervical region, and may even be entirely in the neck. Occasionally it is completely exposed, or, merely covered with pericardium, lies immediately beneath the skin, the sternum in such cases being divided in the middle line. Sometimes it lies beneath the skin of the abdomen.

Abnormality in Size.—Congenital smallness, or *hypoplasia*, of the heart and aorta is occasionally observed. Particular attention has been called to this condition in cases of chlorosis (see p. 368).

Defective Development.—There may be complete absence of the heart in acardiac monsters. Sometimes the septa dividing the auricles and ventricles are wholly wanting and a *bilocular heart* results; or the auricular septum alone is absent, when the organ is *trilocular*. More commonly than these conditions, the organ is completely reversed, lying on the right side of the body and having the blood-vessels entering it and leaving it reversed, so that the general venous blood enters the left auricle, the pulmonary blood the right auricle, while the aorta springs from the right ventricle and the pulmonary artery from the left. The abdominal viscera may be reversed at the same time, the liver being on the left, and the spleen on the right, side. This condition is spoken of as *dextrocardia*. Other abnormalities in the arrangement and origin of the great blood-vessels, such as an undivided truncus arteriosus, are rare.

Stenosis and atresia of the pulmonary artery result from abnormal situation of the septum which divides the truncus. Complete atresia is very rare. Stenosis is one of the commonest developmental defects of the heart, and in some cases is due to fetal myocarditis about the orifice. It may involve the root, the conus, or the trunk of the vessel. The septum of the ventricles is usually defective and the foramen ovale remains patulous. When the stenosis is considerable the pulmonary circulation is maintained by the persistence of the *ductus arteriosus Botalli;* and the right ventricle is greatly hypertrophied.

Stenosis and atresia of the aorta are less frequent than the same conditions affecting the pulmonary artery. They arise from the same cause, and are usually accompanied by the same defects of the septa and patency of the ductus arteriosus. Stenosis of the trunk of the aorta at the isthmus—*i. e.*, at a point between the left subclavian artery and the mouth of the ductus arteriosus—is not infrequent in moderate degree. More rarely there may be almost complete atresia, or the aorta may be entirely wanting at this point. The circulation is maintained by collateral anastomosis

of the branches of the subclavian with the descending aorta. In all of these cases hypertrophy of the left ventricle is usually present.

Defects of the ventricular septum may be unaccompanied by other abnormalities; but, as a rule, they are of secondary importance, occurring in cases of abnormality of the pulmonary artery or aorta. The septum may be completely wanting, or there may be partial defects, these latter usually lying anteriorly and above, in what is known as the membranous portion, or the undefended space. Very frequently a patulous condition of the foramen ovale is present.

Defects of the auricular septum are comparatively rare, but a patulous condition of the foramen ovale is one of the most frequent of congenital affections of the heart. It is due to the failure of the valve of the foramen to unite at the edges, as normally occurs some time after birth. Slit-like openings are seen very frequently in post-mortem examinations, while more decided patency is occasionally observed without other cardiac abnormalities. This is especially likely to occur when congenital atelectasis or some other pulmonary affection causes continuance of high blood-pressure in the right heart after birth.

Stenosis and atresia of the auriculoventricular orifices are rare congenital conditions; and in the former fetal endocarditis doubtless plays an important part. When there is complete atresia the auricular septum must remain widely open and the septum of the ventricle is usually deficient and the ductus Botalli patulous.

Patulous Ductus Botalli.—This condition is frequent in cases of stenosis of either the aorta or pulmonary artery, and serves to convey the blood from the patulous artery into that which is obstructed. Like the patulous foramen ovale, it may occur as an independent condition resulting from congenital atelectasis of the lung which leads to the continuance of the fetal conditions of circulation.

Valvular Defects.—Not rarely there may be but two semilunar valves at the aorta or pulmonary orifice, and, on the other hand, four may be observed, the latter being a relatively common condition. Similar numerical abnormalities occur at the auriculoventricular valves. Abnormal length or shortness of the leaflets may also be observed, or the segments may be united, forming a complete ring. The latter condition must not be mistaken for the agglutination of endocarditis.

Pathologic Physiology.—Congenital heart-diseases occasion serious disturbances of the circulation, leading to overfilling of the venous channels and often abnormal mixture of the arterial and venous blood. In consequence of these conditions blueness or cyanosis is a common symptom, and the terms *congenital cyanosis* and *morbus cœruleus* are applied. The imperfect oxidation of the blood doubtless causes profound effects, but these

have not as yet received accurate study. The imperfect circulation causes certain changes in the tissues, notable among which

FIG. 158.—Congenital cardiac disease, showing peculiar thickness of lips and nose (Eichhorst).

are thickness of the lips and nose, giving rise to a peculiar facial expression (Fig. 158) and "clubbing" of the finger-ends (Fig.

FIG. 159.—Clubbing of the fingers in congenital cardiac disease; from same case as Fig. 158 (Eichhorst).

159). The blood in congenital cyanosis often contains an excess of red blood-corpuscles (see Polycythemia).

CIRCULATORY DISTURBANCES.

Thrombosis of the cavities of the heart results from the causes which induce thrombosis elsewhere in the circulatory system. These are mainly slowing of the current of blood, some roughness or disease of the endocardial lining, and diseased conditions of the blood itself, which render it more liable to coagulation. Slowing of the circulation is the most frequent cause of intracardiac thrombosis, and leads to the formation of the clots found post-mortem in cases of gradual death. If the circulation has been slow for a considerable length of time, there may be found more or less grayish or white thrombi in the auricular appendages of the auricles or in the ventricles between the muscular trabeculæ, especially near the apex. The formation of these is explained by the gradually decreasing rapidity of the current of blood, which leads to the deposit of the leukocytes and blood-plaques upon the endocardium and their conversion into fibrin. The color may be almost completely white; but if the current is almost stagnated, admixture of red corpuscles occurs and pinkish or quite red clots (*currant-jelly clots*) are formed. Of this latter sort are the thrombi formed in the heart during the agonal period and post-mortem. They are further distinguished from the thrombi formed *intra vitam* by the fact that they are not closely attached to the endocardium and between the trabecular muscles.

Among the diseases in which the circulation is prone to be sluggish, and which are frequently accompanied by cardiac thrombosis, pneumonia, tuberculosis of the lungs, the asthenic fevers, and diseases of the muscle of the heart may be named. Dilatation of the chambers of the heart and cardiac aneurysm lead to thrombosis by their effect upon the rapidity of the circulation either in the general heart-cavity in the first, or in the aneurysmal dilatation in the second. Among the endocardial lesions which occasion thrombosis the most important is acute endocarditis. In this condition there is habitually deposited upon the affected part of the valves or mural endocardium a capping of fibrin deposited from the blood passing over the diseased area. In chronic endocarditis, especially when there are irregular calcareous deposits rendering the surface rough and uneven, considerable thrombotic deposit may occur.

Pathologic Anatomy.—Cardiac thrombi, formed some time before death, usually appear as deposits upon the heart-wall of a yellowish or whitish color and rather firmly attached between the muscular trabeculæ. Occasionally they have a stratified appearance, due to the fact that the circulation varied in rapidity during the formation of the thrombi. Secondary changes are not rare, the most striking being softening of the fibrinous mass in places, with

the formation of cyst-like cavities varying in size from a split pea to a cherry (Fig. 160). Sometimes thrombi project from the endocardial surface in a polypoid form, and these may present the appearance of fibroid tumors. A curious form occurs in the auricles, the thrombus presenting itself as a round mass attached to the endocardium by fine pedicles or lying entirely free (*ball-thrombi; globular thrombi*).

FIG. 160.—Thrombosis in cardiac chambers, showing cyst-like structure (Orth).

Lesions in Other Organs.—Thrombosis of the heart may occasion serious disturbance of the circulation by weakening the heart-muscle or by obstructing the valvular orifices. The latter is especially common in the case of the globular thrombi or the polypoid thrombi of the auricles. Passive congestion of the various organs and the secondary changes due to this condition follow. Thrombosis may lead to another and more serious danger, that of embolism. When portions of the thrombus are broken off they are carried into the circulation and lodge in the small arteries of the spleen, the kidney, the brain, the lungs, or elsewhere, causing infarctions, or, in case micro-organisms be present in the original thrombus, metastatic abscesses and pyemia.

Thrombosis and Embolism of the Coronary Artery.—The former condition is much the more common, as the coronary arteries are frequently the seat of advanced atheromatous contraction and roughening, which predispose strongly to thrombosis; and, on the other hand, the mouths of the coronary arteries are so placed that emboli are unlikely to enter. The lodgement of an embolus seriously compromises the heart's action, as has been shown experimentally in animals, and marked pathologic change is therefore unlikely to occur before death ensues. When a partially obstructing embolus lodges or a thrombus is formed there results almost complete anemia of the area supplied by the artery affected, and in consequence an anemic infarct. The muscle-fibers of the affected area become hyaline or granular, and do not take the stain when subjected to ordinary histologic examination. To the naked eye the diseased portion presents itself as a white, and later as a yellowish, area of softening, and the condition is spoken of as *myomalacia cordis*. It is found most frequently in the anterior or posterior wall of the left ventricle, near the apex, from the fact that the descending branch of the left coronary artery is most commonly involved. Next in frequency to these points the

anterior portion of the septum is found to be affected. Small areas may heal by absorption of the degenerated tissue, and by infiltration and proliferation of connective tissue. In this manner a scar is formed, which may remain, or may subsequently lead to aneurysmal dilatation. On the other hand, rupture of the heart may be occasioned either with or without the formation of an acute aneurysmal dilatation at the degenerated area.

DISEASES OF THE ENDOCARDIUM.

INFLAMMATION.

Inflammation of the endocardium, or endocarditis, may be acute or chronic, though the latter is in most cases merely a continuation of the former.

Acute endocarditis affects the endocardium of the valves in the great majority of cases, but it is sometimes found in the endocardium of the cavities of the heart, when it is spoken of as mural endocarditis.

Etiology.—Endocarditis is practically always a secondary process, and is in nearly all, if not all, cases due to the action of micro-organisms. Cold and traumatism, upon which the older writers insisted as causal factors, act merely as predisposing causes. Endocarditis occurs most frequently in association with acute articular rheumatism. Next to this cause scarlet fever, pneumonia, and puerperal sepsis are most important, but in any case of suppurative or infectious disease endocarditis is a possible complication. It occurs at times also in Bright's disease and in conditions of great malnutrition, such as carcinoma and certain nervous affections. These cases have been cited as opposing the view that endocarditis is always infectious and due to micro-organisms. It may be that toxic substances resulting from improper metabolism act upon the endocardium as do micro-organisms, or that portions of the endocardium suffer degeneration as a result of depressed nutrition, but it is also possible that terminal or intercurrent infection from some hidden source may occur in these chronic diseases, with resulting endocarditis.

As to the micro-organisms themselves, the most important are the *Staphylococcus pyogenes aureus*, the *Streptococcus pyogenes*, and the *Diplococcus pneumoniæ*. But there are many forms which have been less frequently detected. Among such are the Staphylococcus pyogenes albus, the Micrococcus endocarditidis capsulatus and rugatus, the Bacillus endocarditidis griseus and capsulatus, Bacillus pyogenes fœtidus or Bacillus coli communis, the Bacillus diphtheriæ, and the bacillus of typhoid fever. The tubercle-bacillus has been found in a few cases, but it is generally believed that its presence is explainable as a secondary deposit rather than

as the cause of the endocarditis. Recently the gonococcus has been recognized as one of the organisms capable of causing endocarditis.

The micro-organisms reach the point of disease from the blood passing over the endocardium, and not through the coronary circulation. This is proved by the fact that the aortic and pulmonary leaflets are frequently involved, and they are not supplied with blood-vessels, and also by the experimental production of endocarditis by injections of micro-organisms into the blood after the valve has been mechanically injured. In such cases there is a direct deposit of micro-organisms upon the heart-valves.

Pathologic Anatomy.—It was customary formerly to distinguish two varieties, a *simple or verrucose*, or benign endocarditis, and an *ulcerative, septic, mycotic, diphtheritic*, or malignant form; but it seems unnecessary at the present time to maintain strictly such a distinction. The cases vary in anatomical appearance and in malignancy, but there is no essential difference and no sharp dividing-line.

The most common seats, in order of frequency, are the mitral valve, the aortic valve, the pulmonary valve, and the endocardium of the left ventricle, the left auricle, and the right ventricle. The part of the valves first involved is a line running across the leaflet at about a distance of 2 mm. from the free edge. It is along this line that the valves impinge in closing, and it is probable that the mechanical injury sustained predisposes to endocarditis. In the cavities the lesions are frequently found upon the chordæ

FIG. 161.—Section through a segment of the aortic valve and adjacent parts of the aorta and heart, showing vegetations on the aortic valve (magnified): *b*, aortic valve segment; *c*, *c*, vegetations; *f*, calcareous particles in the base of the aortic valve (Bramwell).

tendineæ, and of the parts of the mural endocardium proper most apt to be affected may be mentioned the portion of the left ventricle near to the septum and the aortic valves, and the endocardium of the left auricle on the posterior and outer wall above the posterior mitral leaflet.

The first appearance of endocarditis is that of an area of opacity or slight roughness extending in a line across the valve or involving the endocardium elsewhere. Later, small nodular elevations, not unlike a row of small beads, may form; and finally there is a distinct, irregular, and wart-like fibrinous elevation (Fig. 161). To cases of this character the name *verrucose endocarditis* has been given; or from the usually benign character, the name simple endocarditis; or from its most frequent cause, rheumatic endocarditis. In other cases the mass of fibrinous deposit is more abundant (Fig. 162) and more irregular, while in still others the

FIG. 162.—Endocarditis of the aortic and mitral valves, showing vegetations (fibrin-deposits) of considerable size (Kast and Rumpel).

deposit of fibrin does not take place, or, if so, is soon detached, while necrotic changes occur in the endocardium, leading to the formation of irregular ulcers. Secondary deposits of fibrin may cover an ulcer after its formation, or its edges may be heaped with fibrin; and not rarely the active necrotic process in the endocardium is not visible until the fibrinous coating, which is usually considerable in such cases, is removed. These forms of endocarditis are those that have been termed *malignant*, *diphtheritic*, *septic*, *mycotic*, or *ulcerative*. They are especially frequent after puerperal sepsis or other septic diseases and in pneumonia, but there is no well-established dividing-line between the benign cases and the severe cases, either in etiology, in morbid anatomy, or in the clinical course and termination, so that I prefer to regard them as varying grades of the same general process.

Microscopically the endocardium beneath the coat of fibrin

shows desquamation of the endothelial cells, with frequently some hyaline degeneration or coagulation-necrosis of the latter. Below this there are round-cell infiltration and, as the process continues, proliferation of fibroblastic cells. The fibrinous covering of the valve itself consists of flakes or granular masses, or a fibrillar network. By the proper staining-methods masses of bacteria may frequently be demonstrated in the superficial layers of the endocardium or in the fibrinous deposit.

The simple differs from the malignant forms of endocarditis merely in the lesser activity of the necrotic changes in the endothelium and the greater prominence of reparative processes (round-cell infiltration, proliferation of connective tissue).

Results.—Simple endocarditis may be healed by the gradual absorption or breaking off of the fibrinous deposit and its dissemination in the circulation, with coincident thickening of the endocardium at the point of disease by the formation of fibroblastic cells and sclerotic connective tissue. When the process is very limited, and especially when the mural endocardium is affected, merely a white spot of thickening on the endocardium results. When the process is deep there may be

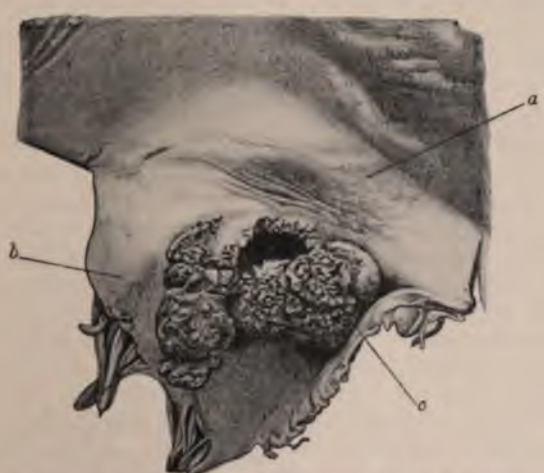

FIG. 163.—Aneurysm of the mitral valve, with rupture of the valve-cusp, seen from the auricular surface: *a*, wall of left auricle; *b*, anterior segment of the mitral valve, the chordæ tendineæ have been cut short; *c*, aneurysm with triangular opening (Bramwell).

decided distortion by contraction of the new-formed connective tissue. When the deposit of fibrin is large it frequently undergoes calcification, and remains as an irregular, calcareous mass attached to the valve. In the severer or malignant cases destruction of an entire valve or of one of the chordæ tendineæ may occur. When one of the layers of the valves alone is penetrated

acute valvular aneurysm may be formed by a pouching of the other layer of the valve (Fig. 163).

Mural endocarditis of malignant type may lead to myocarditis of a purulent character, and may even penetrate to the pericardium and set up a purulent pericarditis.

Lesions in Other Organs.—The most serious danger of endocarditis is embolism. Small fragments of the fibrinous deposits are liable to be carried off into the peripheral circulation, and in ulcerative cases fragments of the valves themselves may be so conveyed. They are prone to lodge in the arteries of the spleen, kidneys, and brain, forming hemorrhagic infarcts or metastatic abscesses, according to the non-infective or infective character of the embolus.

Chronic Endocarditis usually affects the valves of the heart and leads to the distortions of the valves constituting chronic valvular heart disease. Clinically, there are signs of disturbances, and eventually more or less complete failure of the circulation.

Etiology.—Chronic endocarditis may be merely the continuation of acute endocarditis, or it may occur as an insidious process, chronic from the outset. In the former group of cases the causes are, of course, those of acute endocarditis, and it is particularly the rheumatic form that is likely to pass on to a chronic condition. The severer grades, or those commonly spoken of as malignant endocarditis, are usually fatal, though occasionally they may terminate by reparative overgrowth of fibrous tissue. The group of cases in which the disease is chronic from the start has much in common with arteriosclerosis and atheroma, as far as etiology is concerned. These cases occur more frequently in persons of advanced years and in those whose occupation has been laborious. Chronic alcoholism, gout, lead-poisoning, syphilis, and diabetes are among the recognized causes. Not rarely the endocardial disease is secondary to the arteriosclerosis, and it may be directly due to it, resulting from the constant elevation of blood-pressure due to that disease. Laborious occupations act in a similar manner.

Pathologic Anatomy.—In brief, the changes that occur in the endocardium are overgrowth of fibrous tissue, causing thickening with subsequent contraction and distortion of the valves. The chordæ tendineæ are frequently involved and become converted into sclerotic cords of a whitish color, and less frequently white elevations are seen upon the mural endocardium.

Microscopically there are found the characteristic appearances of new-formed connective tissue with occasionally, in the earlier stages, the appearances of granulation-tissue. New-formed blood-vessels may be found within this tissue, though frequently these are degenerated (hyaline and obliterated). Subsequently other degenerations take place. The area of thickening becomes more translucent and hyaline, then opaque and soft; coagulation-necrosis

and fatty degeneration take place, and there may thus be formed beneath the endocardial surface a lesion somewhat resembling a minute abscess. This may rupture upon the endocardial surface, forming a so-called atheromatous ulcer, upon which fibrinous deposits may collect; or it may be slowly inspissated and converted into a calcareous patch. In cases in which acute endocarditis with thrombotic deposits passes into chronic endocarditis the fibrinous masses of the surface may be rendered calcareous at the same time that the sclerotic processes are taking place in the valve. Subsequently the same degenerative changes and calcification may occur in the tissue of the valve itself, as are seen in the atheromatous form of the disease. In the late stages it is often quite impossible to determine whether the case began as an acute endocarditis, or whether it was chronic from the first.

The segments of the valves are frequently greatly shortened and rounded, so that they become mere stumps, or they may be curled upon themselves or drawn back and firmly adherent to the wall of the aorta, pulmonary artery, or the ventricular cavity. The individual segments may be agglutinated and united as a ring or diaphragm projecting from the valvular orifice.

The valvular function is interfered with in two ways: first, obstruction may be offered to the outflow of blood by the rigid projecting valves, a condition to which the term *stenosis* is applied; or, on the other hand, the valves may be so distorted, shortened, or drawn backward that they are no longer able to close, and *insufficiency* results. The semilunar valves are particularly prone to be shortened and thickened and recurved, and insufficiency is therefore most likely to occur. The mitral valve is frequently thickened and converted into a funnel-like formation by agglutination of the edges of the anterior with those of the posterior segment. There may thus be merely a slit-like orifice (button-hole mitral), which occasions great obstruction to the outflow of blood from the auricle. Somewhat similar changes are met with at the tricuspid valve. The pulmonary valve is rarely affected in later life, but is sometimes the seat of fetal endocarditis, leading to permanent changes.

Resulting Changes in the Heart.—The valvular defects can be overcome in only one way—by increase of the power of the heart-muscle. Hypertrophy is therefore the natural result. This affects first the cavity upon which excessive work falls as the result of the regurgitation of blood in cases of insufficiency, or as the result of the excessive strain placed upon the heart-wall to force the blood through the narrowed orifice in stenosis. The amount of hypertrophy varies with the condition of the general health of the individual and with the seriousness of the heart-lesion itself. When the general health is good there is apt to be commensurately adequate hypertrophy, and when the lesion is not of sufficient gravity

to interfere with the circulation in the coronary arteries, and the heart is therefore constantly supplied with a sufficiency of blood, hypertrophy is well maintained. Eventually as the result of continued overwork and of continuously increasing embarrassment of the circulation or of intercurrent diseases, the heart-muscle suffers fatty or fibroid degeneration, the cavities dilate, and the circulation fails.

Changes in Other Organs.—The passive congestions resulting from failure of the muscle of the heart are often extreme, and may lead to profound changes in various organs, notably the lungs, liver, and kidneys. These are discussed in the appropriate sections. Embolism is a not infrequent accident in chronic endocarditis, the emboli being parts of the valvular deposits or parts of thrombi in the cavities of the heart.

Pathologic Physiology.—Endocarditis, acute and chronic, leads to various disturbances of the circulation and of the general health. In acute endocarditis the lesions may become the center of dissemination of infectious material, and the disease may run its course with all the manifestations of an obscure septicemia. This is particularly true of the cases usually designated as malignant. Serious disturbance of the heart-action occurring in acute cases is sometimes difficult to explain. The lesions upon the valves may be seemingly very insignificant, and yet the heart may be very irregular in action and exceedingly weak. In part this may be reflex and in part it is probably the result of associated disease of the myocardium. Some recent investigations, made according to modern methods, have shown the heart-muscle implicated more often than has been suspected. Acute myocarditis and diseases of the blood-vessels of the myocardium (thrombosis) have been discovered.

In chronic endocarditis the disturbances of health are largely the result of mechanical disorders of the circulation. In large part these are brought about by the valvular defects themselves, but in the later stages associated degenerations and weakness of the myocardium are of great importance. At any stage of the disease the state of the heart-muscle determines the seriousness of the disease; marked defects of the valves may be compensated for by a powerful myocardium, while, on the contrary, apparently trivial defects may occasion serious results when the heart-muscle is diseased. Metabolic disturbances of various sorts may occur in consequence of the imperfect circulation. The respiratory exchange of gases, in some cases at least, is reduced, though the degree of cyanosis cannot be taken as an index of the reduced oxidation. In man cyanosis is dependent upon stagnation of circulation rather than reduced oxidation. The products of metabolism excreted in the urine may indicate the reduction in oxygen in the tissues. The metabolic consumption of the proteids of the

body seems to be increased, but the explanation of this fact has not yet been satisfactorily determined. Some regard it as a consequence of molecular necrosis due to insufficiency of the supply of oxygen. The excretion of nitrogenous elements may, however, be reduced when transudates are forming. This is due to the storing up of metabolic products in the transudates. The urine may present albumin as a result of chronic congestion and secondary renal disease; the hepatic functions are disturbed by congestion and jaundice may result; and in the more severe instances hydrobilinuria occurs. The condition of the blood is of special interest. During periods of failing compensation the concentration of the blood is increased or normal, and the number of blood-corpuscles may be excessive. In part, at least, these conditions are explained by the assumption that the corpuscles are retained in the peripheral parts of the circulation in greater measure than the fluid elements (see Polycythemia). When the cardiac compensation is well maintained some anemia may be apparent, especially in cases of aortic disease.

CIRCULATORY DISTURBANCES.

Anemia of the heart-muscle may be part of a general anemia. It may occur in cases of narrowing or obstruction of the coronary arteries, and it may be the result of the pressure of pericardial effusions. When long continued it leads to fatty degeneration of the heart, but is itself of little consequence.

Hyperemia of the heart-muscle may occur when there is obstruction to the return of the blood to the right heart through its venous channels. It may be part of a general hyperemia in a failing compensation of valvular or muscular diseases of the heart. The heart-muscle assumes a dark-red color, and the veins are seen under the epicardium as dilated bluish vessels.

Hemorrhages in the heart-muscle may result from obstruction of the coronary arteries, when the hemorrhage assumes the form of an infarct. There may also be hemorrhages in cases of intense myocarditis or surrounding abscesses of the heart-muscle, and finally points or streaks of hemorrhagic infiltration may be seen between the muscle-fibers in persons who have died with some form of hemorrhagic diathesis, from sepsis, or from various intoxicants.

DEGENERATIONS.

Parenchymatous degeneration, or cloudy swelling of the heart, was designated by Virchow as parenchymatous myocarditis. It is essentially a degenerative process and should be so described, though it forms a not inconsiderable part of the pathologic changes occurring in the heart in acute myocarditis.

Etiology.—The immediate cause is infection. It is met with

in the course of diphtheria, typhoid fever, scarlet fever, rheumatism, and other infections. It may be that elevation of the temperature alone suffices to bring it about, and in these cases no doubt abnormal substances resulting from disordered metabolism are the direct toxic agent, but as a rule it is the specific toxins of the infections that occasion the myocardial disease. Localized parenchymatous degeneration may be found in the heart-fibers adjacent to areas of endocarditis or pericarditis, and doubtless the same etiologic factors are at work in this as in more generalized instances.

Pathologic Anatomy.—The changes are more marked in the left ventricle than elsewhere; though any part of the heart may be affected. As a rule, parenchymatous degeneration occurs as a diffuse process, but there may be only limited areas here and there. The myocardium becomes pale in color and often has a turbid appearance; it is softer than normal, the heart-walls are usually flabby, and the cavities somewhat dilated. Microscopically, the fibers are found to be filled with fine granules of albuminous nature, which may completely obscure the striations and even the nuclei, but which may be cleared up by the addition of acetic acid. Multiplication of the nuclei and round-cell infiltration of the intermuscular connective tissue may be observed, but these are inflammatory changes rather than degenerative, and are not, therefore, strictly a part of the disease in question. Parenchymatous degeneration may be complicated by a form of hyaline degeneration, the affected fibers becoming converted into cylinders of waxy appearance. When cloudy swelling persists fatty degeneration is often the terminal change.

Amyloid degeneration results from the causes which induce amyloid disease in other organs. It is not infrequently found in minute areas here and there, but only rarely has it been seen as a widespread process affecting the connective tissue between the muscle-fibers and beneath the endocardium and pericardium. In such cases the same wax-like appearance is seen as in the liver or spleen, and the characteristic reaction with iodin may be demonstrated.

Hyaline degeneration is sometimes associated with amyloid, and gives rise to a glassy or waxy transformation of the connective tissue. It is usually seen in small areas, but may be quite widespread. Zenker described a form of hyaline disease of the muscle-fibers themselves as occurring in typhoid and other infectious fevers, and affecting the heart-muscle as well as the muscles of the abdominal wall. This is usually associated with parenchymatous degeneration and occurs in limited areas. Microscopically there may be seen small hyaline masses or globular areas embedded in the muscle-fiber, the rest of the fiber showing the appearances of cloudy swelling.

Fatty infiltration, or **obesitas cordis,** is but an increase of the normal condition. In the normal heart there is a certain amount of fatty deposit beneath the epicardium, especially in the furrows and along the lines of the blood-vessels. In disease this may become enormously increased and there may be penetration of the adipose tissue into the wall of the heart between the muscle-fibers, sometimes as far as the subendocardial fibrous layer.

Etiology.—The causes are those which induce general obesity. Thus, it may be the consequence of an hereditary tendency or sedentary habits, with overeating and drinking; it is more common in advanced years than in early life. Very frequently it is met with in women who have grown stout at the menopause; sometimes, however, considerable deposit about the heart may occur in persons otherwise presenting no tendency to fatness.

Pathologic Anatomy.—The adipose tissue beneath the visceral pericardium may be slightly increased in amount, or the heart may be embedded within an enormous deposit of fat, which may involve not alone the epicardium, but the parietal layer and the mediastinum as well. On section through the heart-wall, trabeculæ of adipose tissue may be seen passing through the heart's substance, and sometimes subendocardial deposits may be seen as a uniform infiltration beneath the endocardium or as localized deposits projecting into the heart beneath the endocardium. Microscopically fatty infiltration presents the ordinary appearances of adipose cells lying between the heart-muscle fibers (Fig. 164). The fibers themselves are not involved; but they may become atrophic from

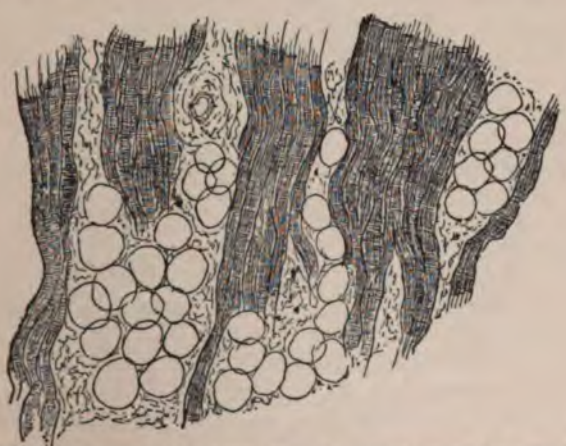

FIG. 164.—Fatty infiltration of the heart, from a section through the wall of the right auricle (Bramwell).

pressure, and in such instances present a more yellowish or brownish color than normal, and microscopically show an abundance of

granules. In other cases pronounced fatty degeneration is seen in the muscle-fibers.

Results.—Weakening of the heart-muscle must necessarily result from the mechanical impediment imposed upon the muscle. Circulatory disturbances are therefore met with as in valvular disease or fatty degeneration. Occasionally rupture of the heart occurs, and is due to the atrophic condition of the muscle proper and a want of resisting power of the infiltrating adipose tissue. It is especially prone to occur when the disease is localized.

Fatty degeneration affects the muscle-fibers themselves.

Etiology.—Fatty degeneration results from malnutrition or from toxic agencies. The most frequent cause is anemia, either local or general. Local anemia is due to sclerosis and narrowing of the coronary arteries; or it may be the consequence of improper circulation in the coronary vessels attending the final stages of valvular disease of the heart. Fatty degeneration is therefore a terminal condition in arterial sclerosis affecting the coronary vessels and in valvular disease. The remote or antecedent causes are those which bring about arteriosclerosis. We find it therefore in elderly persons of the male sex who have had syphilis, who have used alcohol excessively, or have gout or chronic Bright's disease. The fatty degeneration of the heart resulting from general anemia is most typically seen in pernicious anemia, in which the most extreme grades of fatty disease are sometimes witnessed. Of the cases which are due to toxic agents we may distinguish those resulting from specific infections and those occurring in various chemical intoxications. In the specific fevers, in which intense parenchymatous degeneration occurs, and among these diphtheria is most prominent, fatty degeneration is sometimes the terminal condition. Among the external poisons capable of producing the disease phosphorus and arsenic are important.

Pathologic Anatomy.—Fatty degeneration may be a localized or a diffuse process. As a rule, a considerable portion of the heart is affected, but only isolated fibers or groups of fibers are involved. There results a somewhat speckled or mottled condition, which is especially visible beneath the endocardium. Streaks or lines of a yellowish or whitish color alternate with the darker portions of normal muscle. When the process is uniform the entire muscle assumes a yellowish hue. It is softer than normal, the cavities tend to dilate, and the walls may be considerably thinner than normal.

Microscopically the muscle-fibers are found to be filled with small granules of a dark color or with small droplets of high refractive power (Fig. 165). These may completely obscure the nucleus, or they may be arranged in groups at the poles of the nucleus. Sometimes distinct vacuolization of the fibers is seen, especially in cases in which fibroid myocarditis accompanies the

fatty change. The nature of the granules and droplets within the fibers is well demonstrated by treating the section with osmic acid, when the fat-droplets become intensely black.

FIG. 165.—Fatty degeneration of the heart in a case of pernicious anemia; some of the fibers in the lower part of the illustration are normal (Birch-Hirschfeld).

Associated Conditions.—In cases of coronary sclerosis, or valvular heart disease with failure of compensation, fatty degeneration is rarely the sole pathologic condition. As a rule, fibroid myocarditis accompanies it, and the latter may be the more extensive and important condition of the two. Fatty infiltration is often met with as an associated condition, and may be the direct cause of the degeneration by the pressure exerted upon heart-muscle fibers by the infiltrating fat. Rupture of the heart may occur in cases in which fatty degeneration affects localized areas, as is often the case near the apex of the heart.

FIG. 166.—Marked general segmentation with great diastasis of the pieces; × 120 (from the *American Journal of the Medical Sciences*) (Hektoen).

Segmentation of the Fibers.—This is an interesting condition occasionally observed, especially in cases in which sudden

death has taken place. It consists in a transverse splitting of the fibers, by which they are converted into columns of varying length separated by transverse fissures (Fig. 166). It has been described under the name of *état ségmentaire*, or *myocardite ségmentaire*, by French writers. A considerable discussion as to its significance has arisen, some holding that it is a condition of clinical as well as pathologic importance; others, that it occurs during the death-agony or post-mortem. Whether the latter statement be true or not, the segmentation seems to indicate a degree of fragility of the fibers, and in particular of the cement-substance, wholly abnormal, though it may not be demonstrable by our present means of examination. This fragility may be due to digestive action of bacteria or bacterial products, as has been suggested.

Degeneration of the intracardiac ganglia has been noted by a number of observers in myocarditis and in cases of angina pectoris without gross cardiac alteration. The changes observed are swelling, or granular, fatty, and hyaline degeneration of the ganglion-cells, and infiltration of round cells with sclerotic formation between the nerve-cells. The importance of these changes has not been determined.

Pathologic Physiology.—The functional disorders in degenerations of the myocardium may be due to the direct injury of the fibers, or to disturbances of the nervous mechanism of the heart. The latter seems to be the case in instances in which marked cardiac irregularity, or arrhythmia, occurs. The disease of the fibers explains the weakness of the heart-action; and this is especially marked in cases (of fatty and fibroid disease) in which the circulation through the coronary arteries is insufficient. Sometimes the heart is arrested and sudden death occurs in cases of myocardial degeneration due to infectious fevers (diphtheria). This was formerly ascribed to heart-clots, but is now recognized as a form of sudden and complete asystole due to the myocardial disease or to associated nervous disorders, organic (in the intracardiac ganglia or in the cardiac nerves) or reflex. The disturbances of the general circulation in myocardial disease and their results are similar to those met with in valvular disease.

INFLAMMATION.

Inflammation of the heart-muscle, or myocarditis, may be either acute or chronic, diffuse or circumscribed.

Acute myocarditis was designated carditis by the older writers, though the same term was applied to endocardial and pericardial inflammations as well. It may be circumscribed or diffuse, the former appearing in the form of abscesses of the heart-muscle.

Acute circumscribed myocarditis, or abscess of the heart,

may occur in connection with penetrating endocardial lesions or in association with pericarditis. More frequently the infection takes place through the coronary circulation, and the metastatic abscesses of the heart are but a part of a general pyemic disease (Fig. 167).

FIG. 167.—Embolic abscess of the myocardium (Karg and Schmorl).

This occurs in cases of puerperal sepsis, in osteomyelitis, and other intensely septic diseases, but particularly in cases of malignant endocarditis.

Pathologic Anatomy.—When the infectious emboli are large a single abscess or a few abscesses result, while in cases of finely disseminated infectious particles the heart-substance may be studded with innumerable suppurating points. These are more common in the left ventricle and in the anterior wall than elsewhere. At first the lesion may present itself as a minute, hemorrhagic, or necrotic area, but soon the focus softens and forms a purulent collection. In size the abscesses vary from the merest points to cavities the size of a cherry, and as much as an ounce of pus has been removed from a single cavity. Perforation may take place into the heart itself, and acute cardiac aneurysm or even rupture of the heart may ensue. On the other hand, the abscess may discharge into the pericardial sac, or without such rupture may set up purulent pericarditis. Occasionally the pus becomes inspissated and fibrous overgrowth causes its complete encapsulation, or finally the area may be rendered calcareous. Such terminations, however, are rare, the patient usually perishing of the pyemic process, as a part of which the abscesses in the heart occur.

In suppurative myocarditis occurring from extension in consequence of malignant endocarditis communicating sinuses may be established between the chambers of the heart.

Acute diffuse myocarditis occurs in various forms of infec-

tious fevers. It was first recognized in typhoid fever, but is more common in diphtheria and scarlet fever, and is met with in acute rheumatism, puerperal septicemia, and various other infections. It is most likely that the toxins of the infectious diseases named are the immediate causes, and not the specific bacteria themselves. The process may be entirely diffuse, but in most cases the left ventricle is more seriously involved than other parts, and often there are merely localized areas of myocarditis scattered about in various parts of the ventricular wall.

Pathologic Anatomy.—The affected heart-muscle is soft and often distinctly friable. In the earlier stages there may be spots of hemorrhagic infiltration, but as a rule the color is rather lighter than that of the normal organ. It may be noticeable that the bundles of fibers easily separate from one another. The cavities of the heart are frequently dilated, particularly the left ventricle.

Microscopically the important changes are diffuse infiltration of round cells in the connective tissue between the muscle-fibers (Fig. 168), and proliferation of the connective tissue itself, with forma-

FIG. 168.—Acute diffuse myocarditis.

tion of rounded or spindle-shaped fibroblastic cells. There is no tendency to suppuration. The blood-vessels are usually somewhat distended with blood, and there may be distinct proliferative thickening of their walls. Degenerative changes of the muscle-fibers themselves are rarely, if ever, absent, and it is most probable that the first stage in the process is a toxic degeneration of the muscle-fibers, and that the intermuscular infiltration and proliferation are consequent upon the primary degeneration. The fibers become granular and opaque, the striations are indistinct; occasionally there may be vacuolization, and sometimes the segmentation to which so much attention has been directed of late. Proliferation or swelling of the nuclei of the muscle-fibers is frequent, and the hyaline transformation of Zenker is sometimes observed.

Results.—Under entirely favorable conditions acute, diffuse, and non-suppurative myocarditis usually terminates in complete resolution. It is, however, quite likely that the proliferative changes noted in the intermuscular connective tissue often advance to complete organization and formation of localized areas of sclerosis. Death from dilatation of the cavities and cardiac failure is not uncommon.

Chronic myocarditis, or fibrous myocarditis, like the acute form, may be diffuse or localized, though in this case the circumscribed form is the more common.

Etiology.—It is not unlikely that many cases are consequent upon acute diffuse myocarditis, as has been already suggested. In such cases the myocarditis may be looked upon as a primary affection. More commonly the process is secondary, and is dependent upon primary disease of the coronary arteries or disturbances of the circulation in the coronary arteries. It is therefore very common to find areas of sclerosis in cases of atheroma of the coronary arteries or in valvular disease of the heart in which the coronary circulation has finally become deficient. Among the remote antecedent causes are the conditions which are prone to occasion arteriosclerosis, such as old age, alcohol, gout, syphilis, and the like. The connection between the arterial disease and the resulting myocardial sclerosis has been the subject of considerable dispute. No doubt, in some instances, the circumscribed areas of fibrous overgrowth met with in the distribution of branches of the coronary artery represent the scars of healed infarctions. In other cases, however, it would seem more likely that a slow degenerative change with gradual overgrowth of the connective tissue occurs in consequence of the disturbed circulation through the damaged coronary vessels, and it has been urged that in these instances the fibroid disease of the heart is degenerative, and not in reality an inflammatory process at all. Diffuse sclerosis may be associated with hypertrophy in cases of valvular disease and other conditions causing cardiac enlargement.

Localized myocarditis with fibroid overgrowth is very commonly met with at the tips of the papillary muscles in association with chronic endocarditis and disease of the chordæ tendineæ.

Superficial myocarditis of a fibroid character may be seen beneath the pericardium or endocardium which has been thickened by chronic inflammation.

Pathologic Anatomy.—The characteristic change is the formation of sclerotic areas in the muscle-substance. These appear either as more or less irregular spots, or as streaks or lines running in the direction of the fibers of the heart. They are most common in the anterior wall of the left ventricle, near the apex, in the septum, and at the tips of the papillary muscles; but the entire substance of the heart may be involved and thickening of the walls

may result. The impediment offered to the muscle of the heart by the intermuscular sclerosis may lead to true hypertrophy, but more commonly there is degeneration of the fibers in consequence of the pressure of the new-formed tissue, and yellowish areas of fatty degeneration are frequently observed.

Microscopically the diseased areas are found to consist of more

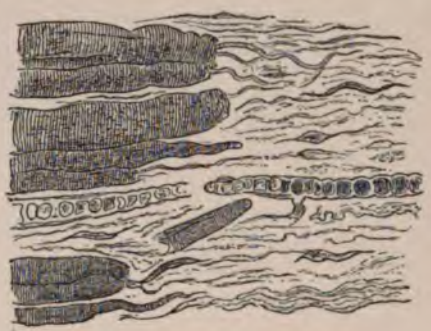

FIG. 169.—Edge of an area of fibrous myocarditis, showing replacement of the fibers by connective tissue (Orth).

or less well-organized connective tissue lying between the muscle-fibers and pressing them far apart, or taking the place of atrophic muscle-fibers (Figs. 169 and 170).

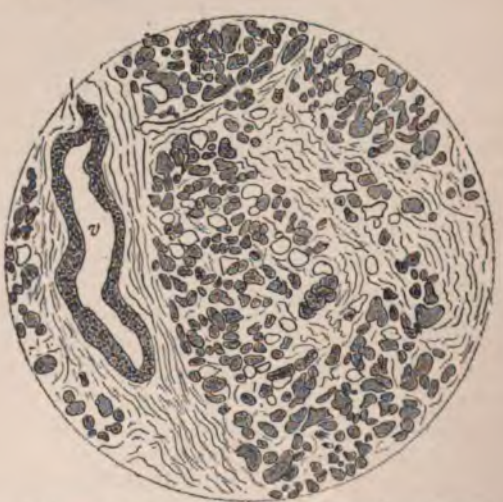

FIG. 170.—Chronic myocarditis, showing diffuse fibrous-tissue formation (Bramwell).

Sometimes certain portions show the earlier stages of the process, round-cell infiltration and proliferation of the connective

tissue being the important features (Fig. 171). As a rule, however, the diseased areas are found in a completely organized con-

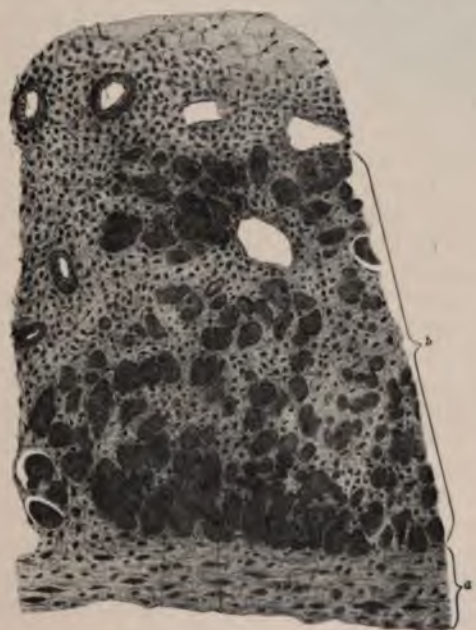

FIG. 171.—Endomyocarditis, showing, *a*, thickened endocardium ; *b*, bands of muscle-fibers with interstitial infiltration of round cells and proliferated connective tissue (Bramwell).

dition. The muscle-fibers themselves suffer granular and fatty degeneration, and not infrequently distinct vacuolization is observed.

Results.—In cases in which a considerable area of chronic myocarditis is developed, as is not uncommonly observed at the apex in consequence of thrombotic or embolic obstruction of the anterior coronary artery, an aneurysm of the heart may result from gradual stretching of the fibroid area. In cases in which the process is diffuse the heart-muscle may at first undergo hypertrophy in consequence of the excessive labor imposed upon it, but eventually degeneration from pressure upon the fibers gains the ascendency, dilatation of the cavities ensues, and general failure of the circulation is the terminal result.

It is not unusual to find diffuse arteriosclerosis and fibroid disease of other organs associated with chronic myocarditis. In such cases the antecedent cause is the arterial disease, which in turn may be dependent upon some systemic disorder.

HYPOPLASIA AND ATROPHY.

Hypoplasia of the heart is a congenital condition in which the heart is insufficiently developed and remains undersized throughout life. This condition is frequently associated with hypoplasia of the aorta and other large vessels, and sometimes with a similar condition of the generative organs. Persons having a predisposition to tuberculosis and women who develop chlorosis not rarely present the conditions referred to. These individuals are often of delicate structure, with feeble or unstable circulation, and, in the case of males, of effeminate nature and appearance. The heart is small in size, and, as a rule, uniformly affected in all parts. The epicardium may be somewhat wrinkled, and this condition, no doubt, has often led to the description of cases of this sort as instances of atrophy.

Atrophy of the heart is usually described as occurring in two varieties, *simple* and *brown atrophy*. It is very doubtful, however, if simple atrophy ever occurs. Many of the cases so designated were doubtless hypoplasiæ, and other cases probably brown atrophies.

Etiology.—Atrophy of the heart usually occurs in persons of advanced age; but is occasionally met with in the young. It results from simple senility, or from various cachectic or wasting diseases, such as tuberculosis, carcinoma, and the like.

Pathologic Anatomy.—The heart is small in size, sometimes weighing but a third or fourth of its normal weight. The capsule, or epicardium, is wrinkled, and may be somewhat thickened by fibrous-tissue overgrowth or by fatty or mucoid change.

FIG. 172.—Atrophy of the heart, seen from the front (two-thirds natural size) (Bramwell).

FIG. 173.—Brown atrophy of the heart-muscle.

The vessels are conspicuously tortuous (Fig. 172). The muscle is flabby and often quite dark in color.

Microscopically the fibers are found smaller than normal, and contain excess of pigment. The latter is brownish or black, and at first situated at the poles of the muscle-nuclei (Fig. 173). Later the whole fiber may be uniformly pigmented. Sometimes the muscle-fiber is converted into a hollow sheath, containing scattered pigment-granules and more or less fragmented nuclei. Complete destruction of the fiber may lead to the apparent occurrence of pigment between the muscle-fibers. The pigment does not contain iron, and seems to be a derivative of the albuminous constituents of the fibers.

Localized atrophy of the fibers may occur around areas of disease of the heart-muscle, such as foci of myocarditis, tubercles, gummata, etc. The fibers present the same appearances as those just described.

Pathologic Physiology.—Atrophy of the heart-muscle does not often occasion striking results or symptoms, as the process is in most cases commensurate with the general emaciation and decreased demand. Occasionally irregular action of the heart is noted, and sudden death has sometimes occurred.

HYPERTROPHY AND DILATATION.

Hypertrophy and dilatation are usually associated and result from the same causes, the degree of hypertrophy or of dilatation present in a given case depending upon the suddenness of action or the intensity of the cause, and upon the state of the heart itself. A sudden strain may cause immediate dilatation; repeated strains of less severity cause hypertrophy in a well-nourished heart, or increasing dilatation in one the seat of myocardial weakness or degeneration.

Etiology.—The influence of valvular diseases (*q. v.*) of the heart in developing hypertrophy has been sufficiently discussed. Various other causes may lead to overwork or cardiac strain, and occasion hypertrophy or dilatation. We may classify the causes in accordance with their operation upon one or the other, or both ventricles.

Causes Acting on the Left Ventricle.—All forms of arterial disease, but especially diffuse arteriosclerosis, increase the work of the left ventricle notably, and may cause marked changes in it. Aneurysms of the aorta, however, have surprisingly little effect. Chronic Bright's disease, especially the interstitial form, is a well-known cause. It probably acts in several ways: partly by the associated arterial disease, partly by vascular contraction due to toxic products, and partly by the direct stimulation of cardiac action by the same causes. Excessive exercise or laborious occupations (mining, blacksmithing, etc.) may act upon the whole heart, but especially upon the left ventricle.

Causes Acting on the Right Ventricle.—Diseases of the lungs and pleura, such as emphysema, fibroid phthisis, and pleural synechiæ, are frequent causes of hypertrophy and dilatation of the right ventricle.

Causes Acting on the Heart as a Whole.—General functional overstimulation may cause uniform enlargement of the organ. This may be seen in cases of hysteria, exophthalmic goiter, and other diseases in which the overaction is due to nervous influences. Excessive eating and drinking affect the left more than the right ventricle, but influence both sides to some extent. Habitual, excessive beer-drinking is most striking in its effects, and doubtless acts through the constantly recurring overdistention of the blood-vessels, as well as through the excess of nutriment and direct stimulus conveyed to the organ. Pericardial adhesions may occasion continuous overaction of both ventricles.

Any of the causes named may occasion hypertrophy or dilatation, or both. The degree of hypertrophy is dependent upon the previous integrity of the heart-muscle, the state of the general health, and the manner of action of the cause. Sudden strains are more likely to cause dilatation, and pure dilatation may result if the muscle of the heart is degenerated. This is illustrated by cases of *acute dilatation* of the heart in the course of infectious fevers.

Pathologic Anatomy.—Four forms of enlargement of the heart may be distinguished. First, the walls are thickened, and the cavities are smaller than normal; this is known as *concentric hypertrophy*, but it is likely that the decreased size of the cavities is due to post-mortem contraction; second, hypertrophy of the walls with normal cavities is spoken of as *simple hypertrophy;* third, hypertrophy with cavities of increased size is known as *eccentric hypertrophy*, or *hypertrophy with dilatation;* and, fourth, there may be *pure dilatation* without hypertrophy. In hypertrophy the muscle-substance is darker than normal and is increased in consistency. Microscopically the fibers are increased in thickness, and there is probably also increase in the number of the fibers. The nuclei of the muscle are swollen and multiply; myocardial degeneration (fibro-fatty) is often associated. When dilatation is present the heart-muscle is usually softer, more flabby, and generally somewhat lighter in color, due to associated degeneration.

The shape of the heart varies from the normal. When the left ventricle is hypertrophied the organ is increased in length and extends further to the left than normal (Fig. 174). When the right ventricle is hypertrophied the organ assumes a rounded shape; its apex is less sharp, and the transverse measurement of the organ is greatly increased. The weight and size of the heart may increase enormously, and the term *cor bovinum* is often highly

appropriate. Weights of from 500 to 800 g. are not infrequent, and may be greatly exceeded. Stokes recorded a case in which the weight was 1980 g.

Pathologic Physiology and Results.—Hypertrophy is a relative process which serves to counterbalance the valvular or

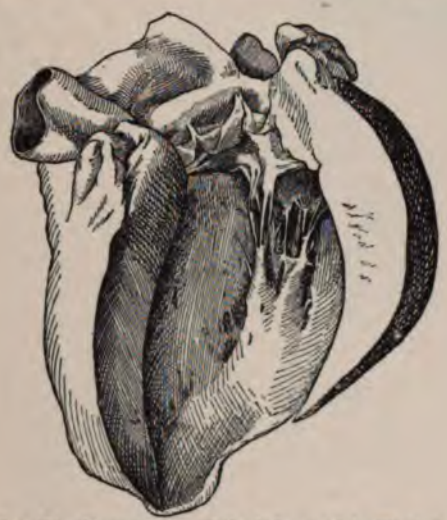

FIG. 174.—Hypertrophy of the left ventricle (Ziegler).

other impediments to the circulation. Occasionally there may be excessive hypertrophy, but, as a rule, it is merely sufficient to maintain the circulation under ordinary conditions with less reserve power than is met with in health. In consequence valvular lesions or arteriosclerosis may occasion no symptoms for a long time, provided the individual leads a quiet life. Eventually, however, when intercurrent diseases have determined cardiac weakness, or when the impediment to the circulation has grown progressively to an excessive degree, dilatation ensues and failure of the circulation is the consequence. When the left ventricle is at fault congestion of the pulmonary system occurs, and edema, hemorrhage from the lungs, or thrombosis with infarction of the lungs may take place. When the right ventricle fails general systemic congestion, cyanosis, and dropsy are the consequence.

Great hypertrophy, while it results from arterial disease, very frequently reacts upon the arteries and increases existing arterial disease, or occasions arterial disease when it has not previously existed. This is due to the increased force with which the blood is projected from the ventricular cavity and the increased distention which the arteries suffer in consequence.

ANEURYSM.

Aneurysm of the heart is a rare condition. It is usually found in the anterior wall of the left ventricle, near the apex, but may affect any part of the auricles or ventricles. Sometimes it is diffi-

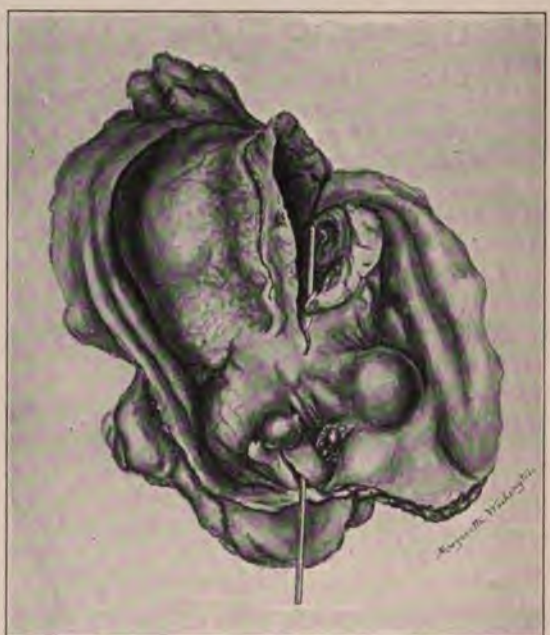

FIG. 175.—Aneurysms of the left ventricle: the sac through which the probe was passed was situated posteriorly; the unopened aneurysm on the right was anterior; the heart is somewhat twisted out of its usual shape to show both sacs in the illustration (Sailer).

cult to distinguish simple dilatation from aneurysm. The usual cause of aneurysm is coronary obstruction, with resulting degeneration of localized areas of the wall of the heart. First, there is softening (myomalacia), and this may occasion acute aneurysmal dilatation and even rupture of the heart. In other cases the degenerated area becomes fibrous and subsequently dilates. Acute aneurysm of the heart-wall may similarly occur in cases of mural endocarditis. Rupture in such chronic cases is a rare termination.

WOUNDS AND RUPTURE OF THE HEART.

Non-penetrating and even penetrating wounds of the heart-wall are sometimes recovered from, the injury being repaired by scar-tissue or fibrous myocarditis. As a rule, penetrating injuries occasion rapid death by hemorrhage into the pericardium. Spontaneous rupture of the heart may be occasionally the result of

severe strain of a normal heart, but, as a rule, it occurs when there is myocardial disease. Myomalacia cordis, fatty degeneration, malignant endocarditis, and abscess are the conditions most likely to occasion rupture.

INFECTIOUS DISEASES.

Tuberculosis may occur in the form of acute miliary tuberculosis, affecting either the endocardium, myocardium, or pericardium; while caseous tubercles result from extension of tubercular adenitis from the anterior or middle mediastinum.

Syphilis is rare, but may occur in the form of gumma or of diffuse infiltration. Gummata may lie immediately beneath the pericardium or endocardium, and after softening by degeneration may rupture on the surface.

Actinomycosis may involve the heart by extension from the mediastinum or by embolism. White or grayish nodules are formed, and subsequently degenerate.

NEW GROWTHS AND PARASITES.

Primary tumors of the heart are extremely rare. *Sarcoma, fibroma, lipoma, myxoma,* and *myoma* have been met with, and usually occur in the form of wart-like growths projecting into the cavities beneath the endocardium. Organized pediculated thrombi have frequently been mistaken for tumors.

Secondary tumors are more common. Sarcomata of the mediastinum may involve the pericardium, or even the heart-wall, by direct extension, while secondary carcinomata and sarcomata may affect the myocardium by metastasis. In the latter instances nodular formations are seen embedded in the heart-muscle.

Parasites.—Echinococcus cysts are occasionally seen beneath the endocardium or pericardium, and may rupture into the cavities of the heart, with resulting embolism. The cysticerci of Tænia solium and of Tænia saginata have occurred in man, but are more common in animals. The larval Pentastomum denticulatum is a rare parasite of the heart.

THE PERICARDIUM.

The pericardium is a membranous sac enclosing the heart and the root of the great blood-vessels. It is composed of a fibrous outer layer, and is lined within by flat endothelial cells. Normally it contains from 5 to 50 cc. of clear serous liquid.

Partial or complete absence of the pericardium is sometimes seen, especially in cases of ectopia of the heart. Occasionally diverticula are present congenitally.

CIRCULATORY DISTURBANCES.

Hyperemia of the pericardium may occur in valvular heart-disease or in cases of tumor or aneurysm causing intrathoracic pressure.

Hemorrhages.—Extreme passive congestion with ecchymotic hemorrhages is found post-mortem in cases of death from asphyxia. Small punctate hemorrhages are also occasioned by various infectious diseases and by certain poisons, as phosphorus. They are also seen in pernicious anemia, scurvy, purpura, and other blood diseases.

Hemopericardium is a term applied to accumulation of blood in the pericardial sac. It may result from rupture of the heart or of aneurysms of the aorta, pulmonary artery, or coronary arteries. The serous effusion of inflammatory conditions of the pericardium may sometimes contain considerable blood which has escaped from the small blood-vessels in the inflammatory tissue. This is more common in inflammatory effusions of the pericardium than of other serous membranes, and is particularly true of tuberculous and cancerous cases.

Hydropericardium, or dropsy of the pericardium, may occur when passive congestion is continued, or as a part of a general anasarca. Occasionally the liquid is milky (*chylous hydropericardium*).

INFLAMMATION.

Inflammation of the pericardium, or **pericarditis,** is the most important pathologic process affecting this part of the body.

Etiology.—Pericardial inflammations may be *primary* or *secondary*. In the former the irritants are conveyed to the pericardium through the blood, while in the latter the inflammation results from extension. Primary pericarditis occurs in association with various infectious diseases, notably acute rheumatism, scarlet fever, small-pox, influenza, and intense septic infections. It is also met with in the course of nephritis, either acute or chronic. Secondary pericarditis may result from extension of inflammation from the pleura, the lung, the mediastinal glands, the sternum, the esophagus, and stomach, or from the heart itself.

In many instances, even where the pericarditis has occurred in the course of an infectious disease, micro-organisms are not discovered in the exudate; this may be due to the arrest of the micro-organisms in the pericardial tissues; staphylococci, streptococci, pneumococci, and tubercle-bacilli have all been found.

Pathologic Anatomy.—Several varieties may be distinguished, though one form may merge into another.

Fibrinous or Dry Pericarditis.—The first change noted in

pericarditis is a dulness or lusterless condition of the surface of the membrane. Somewhat later distinct granulations, or a thin coating of fibrin, appear upon the surface, and this may increase until the deposit has a notable thickness. The movements of the heart may give the latter a marked roughness or rugosity, and the term applied by older writers, *cor villosum*, is not inappropriate

FIG. 176.—Acute pericarditis (Bramwell).

(Fig. 176). Microscopically there is seen a deposit of granular or fibrillar fibrin upon the surface, whilst the endothelial cells are loosened and partly degenerated, and the subendothelial tissues are infiltrated with round cells. The blood-vessels are generally widely dilated, and punctiform hemorrhages may be observed.

Serofibrinous Pericarditis.—The pericardial exudate rarely remains purely fibrinous in character. Usually there is seen some serous outpouring, and the sac becomes distended with more or

less abundant turbid, serous liquid, in which flakes of fibrin are suspended. In such cases the fibrinous deposit is generally slight. Later the fluid may be reabsorbed, leaving a simple fibrinous pericarditis.

Purulent pericarditis, or **pyopericardium,** may begin as a fibrinous or serofibrinous process, or it may assume the suppurative form from the very start. In these cases the cause of the pericarditis is usually some intense general infection, as in puerperal pyemia and septicemia, or it may be a local infection, as in cases in which an esophageal or gastric ulceration has ruptured into the pericardium, or in which a caseous tubercular focus or purulent pleurisy has found a similar discharge. The pericardial sac is filled with more or less purulent or seropurulent liquid, and the pericardium itself is covered with fibrinopurulent exudate. The superficial layers of the myocardium are frequently involved by inflammatory edema, myocarditis, or fatty degeneration.

Hemorrhagic pericarditis is met with in individuals of low vitality and in persons suffering from scurvy, purpura, and similar affections. Pericarditis accompanying tuberculosis or cancer of the pericardium is specially prone to assume a hemorrhagic type. Usually the exudate is serous, but distinctly colored with blood; sometimes it is almost completely hemorrhagic.

Terminations of Acute Pericarditis.—Any of the forms described may persist for a considerable length of time without change, but usually certain alterations are noted. In the fibrinous variety, or in the serofibrinous form, after the liquid has been reabsorbed, the visceral and the parietal pericardium lie in contact and are agglutinated by the exudate. Gradually the inflammatory processes beneath the fibrinous exudate extend into the fibrinous coating; connective-tissue hyperplasia and new formation of blood-vessels follow, and granulation-tissue unites the adjacent layers of pericardium. At the same time the fibrinous exudate is reabsorbed and subsequently organization of the granulation-tissues is completed. Fibrous adhesions binding the two layers of the pericardium together ensue, and at times complete obliteration of the sac is the consequence (Figs. 177 and 178). In cases in which the inflammation is slight, or in which the layers are kept apart by persistent serous exudate, the areas of inflammation gradually become thickened by new-formed fibrous tissue, and there remain upon the surface of the pericardium sclerotic spots, often spoken of as "milk spots." Occasionally portions of the fibrinous exudate remain unabsorbed, and together with the thickened membrane itself and the adhesions suffer calcareous infiltration. The heart may thus be encased in calcareous plates of considerable thickness.

Purulent pericarditis may terminate by discharge of the exudate into the esophagus, stomach, pleura, or even into the bronchi,

and by the subsequent adhesion of the two layers of the sac. In other cases gradual inspissation of the pus takes place and the cheesy residue may remain or eventually become calcareous.

FIG. 177.—Adhesive pericarditis, showing fibrin-deposit, with new blood-vessels extending upward into it (Perls).

Associated Conditions.—While, on the one hand, pericarditis often follows inflammatory processes in the surrounding parts, it,

FIG. 178.—New blood-vessels and fibroblastic cells in a beginning adhesion of the pericardial layers.

on the other hand, not infrequently occasions disease of the adjacent structures. In most cases of severe acute pericarditis there

is some associated inflammation of the mediastinal structures and of the pleura contiguous to the pericardium. Cases which terminate with the formation of fibrous adhesions within the pericardial sac usually present, also, mediastinal and pleural adhesions with the external surface of the pericardium (*pericarditis interna et externa*). Myocarditis extending to a depth of 1 or 2 mm. is seen in nearly every case of pericarditis. In cases in which considerable pericardial exudate is present the heart-muscle is pressed upon and impeded in function, so that venous congestions are commonly observed. Adhesive pericarditis leads to hypertrophy and, later, dilatation of the chambers of the heart.

INFECTIOUS DISEASES.

Tuberculosis of the pericardium may result from the extension of pulmonary or pleural tuberculosis, or of tubercular affections of the mediastinal glands. More rarely direct infection may occur through the medium of the circulation. Miliary tubercles are formed in the subserous and serous layers of the membrane, while the surface is covered with fibrinous exudation. The attendant pericarditis may be entirely fibrinous and the tubercles may be hidden from view by a thick deposit. In other cases there is serous or hemorrhagic or purulent exudation, the latter especially in cases in which caseous vomicæ have ruptured into the pericardial sac. Tuberculous pericarditis may terminate by gradual absorption of the exudate and fibrous adhesion, sometimes with calcareous infiltration. In other cases the necrotic and destructive changes characteristic of tuberculous processes elsewhere gain the ascendency, and the disease proves fatal by the seriousness of the cardiac involvement.

Syphilis is an extremely rare condition. Certain indurative changes in the pericardium have, however, been met with in association with syphilis of the heart.

Actinomycosis may result from extension of actinomycosis of the mediastinum or of the lungs.

TUMORS AND PARASITES.

Primary tumors, such as lipoma and fibroma, are extremely rare. Secondary carcinoma and sarcoma are more frequent. They result from similar growths in neighboring structures. Hydatid cysts and cysticerci are occasionally met with.

PNEUMOPERICARDIUM.

Pneumopericardium (air in the pericardium) may result from perforation of the sac in cases of fracture of the ribs or from penetration of foreign bodies through the esophagus into the pericar-

dium. It also results from rupture of gastric or esophageal ulcers, and a certain amount of gaseous accumulation complicates purulent pericarditis when the exudate undergoes decomposition. The association of air and pus (*pneumopyopericardium*) more often results from secondary purulent inflammation after the development of pneumopericardium.

THE ARTERIES.

Anatomic Considerations.—The arteries and veins consist of three coats, called, respectively, the *intima*, or inner coat, the *media*, or middle coat, and the *adventitia*, or external coat. The intima consists of a layer of endothelial lining-cells, below which there is a thick fibrous layer and then an elastic membrane. The middle coat consists of smooth muscle-fibers, while the outer coat is composed of the fibro-elastic tissue. Small blood-vessels, the *vasa vasorum*, ramify through the adventitia and media, but the intima is avascular.

CONGENITAL DEFECTS.

Certain defects of distribution and of origin of the larger trunks have been referred to in the discussion of congenital defects of the heart. Very commonly there are anomalies in the arrangement of the peripheral branches, but these are of merely anatomical interest.

Hypoplasia.—A condition of importance is congenital smallness, or hypoplasia. This may affect the aorta and larger vessels together with the heart, or it may be confined to the blood-vessels, the heart being normal. Vascular hypoplasia has been especially met with in chlorotic girls, and also occurs in persons of tuberculous habit. The aorta is sometimes so small that it barely admits the little finger, and the walls are usually correspondingly decreased in thickness. Decided elasticity of the coats of the vessels may be observed.

HYPERTROPHY.

This occurs when a collateral circulation is established in consequence of obstruction of an artery. Similarly in the new formation of tissue the blood-vessels first formed are delicate vascular channels, which subsequently hypertrophy and are converted into well-developed arterioles. In this case there is a uniform overgrowth of each of the component parts of the blood-vessel, and not a mere hyperplasia of one or another coat.

ATROPHY.

Atrophy may occur in a part which is undergoing general atrophy, or in consequence of pressure and anemia of certain

areas. Degeneration of the walls usually takes place in such cases, and the conditions are therefore more properly considered among degenerations.

DEGENERATIONS.

Fatty Degeneration.—Any one of the coats may be affected, but the process is most common in the intima. Fatty degeneration is one of the important factors in atheroma; more rarely it occurs as an independent affection of the blood-vessels. In the latter case disturbances of circulation and toxic agencies in the blood are the immediate causes. Small white or yellowish spots or streaks may be seen in the endothelium, and microscopically the endothelial cells may be found granular or filled with oil-drops. In cases of greater severity there may be actual erosion of the endothelial surface. In cases in which the media is affected the muscle-cells undergo fatty degeneration. Fatty degeneration may occasion rupture of the blood-vessels, or calcareous infiltration may ensue.

Calcareous infiltration is the common termination of atheroma, but sometimes calcification of the intima or media, or even of the entire wall of the vessel, may be observed without arteriosclerosis. The process is most common in the intima and media, and, aside from the instances in which it is a part of atheroma, it may occur in consequence of circulatory disturbances, or as the result of bone-disease, with destruction of osseous tissue and surcharge of the blood with earthy salts.

Hyaline degeneration is a condition, the nature and uniform character of which remain in doubt. A form of hyaline degeneration is very common in the hyperplastic tissue of arteriosclerosis, and is generally the first evidence of beginning degeneration. It is met with in small blood-vessels which are obstructed by thrombi, or which are subjected to destructive pressure by inflammatory new growths or other causes. Not infrequently it is due to infectious fevers or intoxications, and in these cases the small arteries and the capillaries are prone to be affected. Hyaline degeneration of the blood-vessels is the striking feature of certain cylindromata (see Fig. 54). The artery may show a uniform or a more nodular glass-like thickening, and under the microscope the subendothelial tissue or the adventitia, or the entire wall of the blood-vessel may be found converted into vitreous substance. Rupture of the affected vessel is a not infrequent result.

Amyloid degeneration commonly begins in the blood-vessels of the parts of the body in which this disease is found. In the kidneys the capillary tufts of the Malpighian bodies and in the spleen the capillaries within the lymphoid nodes are first affected. In these cases the entire wall of the vessel is involved, and pre-

sents the characteristic appearances of the disease. Amyloid disease is sometimes found in the intima of the larger blood-vessels, occurring in small linear or punctate areas, and scarcely to be recognized excepting by chemical tests.

INFLAMMATION.

Inflammation of the arteries may affect the inner, the middle, or the outer coat, and in a strict anatomical sense the terms endarteritis, mesarteritis, and peri-arteritis are justified; but, as a rule, all three coats are more or less involved at the same time, and no practical distinction can be drawn. There may be acute or chronic inflammation.

Acute Arteritis.

Acute arteritis may be of two kinds: a suppurative, or necrotic, form, and a productive form.

Acute suppurative arteritis occurs in the arteries traversing areas of suppurative inflammation, and results from the extension of the suppurative process. It may also occur in consequence of the lodgement of infected emboli or as a result of infection of thrombi within the vessels.

When the process extends from without, the adventitia and then the media are infiltrated with round cells, and in cases of some of the larger vessels there may be visible points or collections of pus. The process may extend as deeply as the intima, and may completely perforate the wall of the vessel, leading to hemorrhage. The intima itself is not directly involved by the suppurative process from the lack of independent blood-supply, but the emigrated leukocytes may infiltrate it, and degenerative changes are common in the endothelium. Where the process begins by infection within, as through softened thrombi or infectious emboli, there is first necrotic or degenerative destruction of the intima, and subsequently infiltration of the media and adventitia with emigrated round cells.

A form of infectious arteritis resembling malignant endocarditis has been observed in association with that condition in a few instances. Ulcerated patches are seen in the intima of the aorta, and acute aneurysmal dilatation or even perforation has been met with.

Acute productive arteritis is most commonly the result of tissue-changes surrounding the arteries, and is therefore constantly met with in diseases of organs leading to overgrowth of connective tissue. The condition is chronic rather than acute in such instances. Acute productive arteritis occurs as a consequence of thrombosis within the blood-vessels when the latter are

not infected. The term *thrombo-arteritis* has been applied to these cases. It is by thrombo-arteritis that wounds of vessels are closed and the lumen of the blood-vessels at the point of ligation permanently obliterated.

The changes affect mainly the intima and the adventitia, both of which coats are densely infiltrated with round cells. The thrombus, which was the original cause of the arteritis, or which has resulted from the arteritis, becomes similarly infiltrated with round cells, and as the process advances is found to be penetrated by fibroblastic cells, which probably take origin from proliferation of the endothelial-lining cells or from other connective-tissue cells in the walls of the vessels. New blood-vessels spring from the *vasa vasorum* and penetrate the thrombus, and a lesser number of new vessels may enter the thrombus directly from the lumen of the occluded vessel itself (see Fig. 7). The process of organization takes place as in the serous surfaces generally, and, as new connective tissue is formed, the thrombus is gradually removed and the lumen of the vessel may become completely obliterated. Less extensive involvement of the vessel may lead to the formation of bands of adhesion passing from one side of the vessel to the other, and causing considerable deformity and distortion. In other cases there may be merely thickening of the intima as a final result, the thrombus having been washed away or absorbed. The media usually takes very little part in the process, being merely infiltrated with round cells, but the entire wall of the vessel may become fibroid in the terminal stages and the separate coats may be indistinguishable.

Peri-arteritis Nodosa.—Under this name has been described a form of productive inflammation of the adventitia leading to the formation of fibrous nodules. In some of these cases there is no doubt a different pathology, as in the instances in which the intima has been found to protrude in a hernious manner through defects in the media, but in most cases the disease is a productive peri-arteritis (see also under Aneurysm).

Arteriosclerosis.

Arteriosclerosis, or **endarteritis chronica deformans,** is a chronic degenerative and inflammatory disease of the arterial system. It may be confined to the arteries, or may be more extensive, involving the capillaries as well, when the term *arterio-capillary fibrosis* (Gull and Sutton) is applicable. Sometimes the veins also are involved, and for this condition the name *angio-sclerosis* has been proposed.

Etiology.—Arteriosclerosis is a physiologic process of old age, and probably begins as early as middle life in most persons. The earlier occurrence of the disease or the more extreme grades of its severity are dependent upon a variety of causes, among which certain chronic intoxications, viz., syphilis, gout, chronic alcoholism,

and chronic nephritis, are prominent. An important cause is muscular exertion, and it is not uncommon to find marked instances in persons whose life or occupation has subjected them to unusual muscular strain. Cachectic conditions of various kinds may play a part, as in cases of carcinoma, tuberculosis, or inanition; and sometimes the chronic arterial disease follows after acute infections, such as rheumatism, scarlet fever, typhoid fever, and the like.

Pathogenesis.—Not a little difference of opinion has existed in regard to the manner in which the recognized causes of arteriosclerosis operate. At first it was generally maintained that the infectious and toxic agencies directly irritate the inner lining of the blood-vessels and produce inflammatory thickening. This view has, however, been quite generally abandoned, and it now seems established that degenerative changes and loss of elasticity in the vessel-wall are the result of the primitive causes, and that the hyperplastic processes in the intima and other parts of the arterial wall are the ultimate result.

In cases of arteriosclerosis occurring in old age, for example, the first disturbance of the blood-vessel consists in the loss of elasticity in the muscularis and the overdilatation of the blood-vessels. Secondarily, in consequence of this loss of elasticity, there is a hyperplasia of the intima, which serves in some measure to contract the lumen of the vessels and thus restore the vascular channels to their normal condition. In cases of purely pathologic arteriosclerosis similar functional weakness of the muscularis or more pronounced and demonstrable degenerative changes may be the primary conditions, which in the end lead to arteriosclerosis. In all cases the direct effect of elevations of blood-pressure may play an important part, and in cases of muscular overwork or of hypertrophy of the heart the increased vascular tension may be the all-important cause.

Pathologic Anatomy.—Arteriosclerosis may be a *diffuse* process, affecting more or less uniformly a large part of the arterial system, or it may be a *circumscribed* or *nodular* condition. In the latter instances, which are most common in the aorta and large vessels, there are seen on the inner lining of the vessel nodular elevations, varying in size from the merest points to that of a small coin. These are raised a millimeter or two above the surface, and in their earlier stages have a translucent grayish color; they are covered with smooth, unaltered endothelium. Later, degenerative changes ensue and the nodule becomes dull white or yellowish in color, and finally calcification may render it extremely hard (*atheromatous plate*). The focus may, on the other hand, soften completely by degeneration and may discharge into the lumen of the vessel, leaving a necrotic, ulcerated patch (*atheromatous ulcer*). Calcareous change may now occur, and the surface may be covered

with thrombotic fibrinous deposits. These circumscribed areas of arteriosclerosis may be few in number and widely separated. In such cases the openings into the coronary arteries and the other branches of the aorta are the favorite seats. In other cases the plates may be so numerous and thickly set that the aorta is completely transformed.

Diffuse arteriosclerosis is especially frequent in elderly persons, and is more common in the small vessels than in the aorta. Sometimes it is associated with the nodular form; sometimes the nodular change is completely wanting.

Microscopically the nodular elevations are found to consist of dense sclerotic tissue in which deeply staining cells of elongated character may be visible, the hyperplasia affecting the subendothelial part of the intima in the earliest stages (Fig. 179). Sub-

FIG. 179.—Transverse section of a cerebral vessel, in a case of *endarteritis nodosa* (Birch-Hirschfeld).

sequently degeneration of the nodule becomes manifest. At first the intercellular material assumes a hyaline character and becomes glassy in appearance. The cells themselves may suffer fatty degeneration from pressure. Later the whole area undergoes myxomatous or more particularly fatty degeneration, and breaks down, forming a pultaceous detritus in which fat-drops and cholesterin-plates are prominent (Fig. 180). Eventually calcareous granules are deposited.

Fatty degeneration and calcification may also be apparent in the media, and more or less hyperplastic connective-tissue overgrowth may be seen in the adventitia. In cases of diffuse arteriosclerosis the media, as a rule, is thickened by hypertrophy of the muscle-fibers as well as by sclerosis; but in the nodular forms the media is usually distinctly thinner than normal. Köster pointed out that round-cell infiltration surrounding the small branches of

the *vasa vasorum* in the media is the earliest change in some instances. Considerable round-cell infiltration may be seen in the deeper layers of the intima and in the media, and new formation

FIG. 180.—Atheromatous degeneration of a cerebral artery (Karg and Schmorl).

of blood-vessels may be quite pronounced. Such changes, however, are not usual and not characteristic.

Results.—In the smaller blood-vessels, particularly in those of the brain, the hyperplastic process in the intima may proceed to such a degree that the lumen of the vessels is almost completely obliterated (*endarteritis obliterans*). Complete obliteration may take place by direct union of the opposite walls of the vessel, or there may be first thrombosis, with subsequent organization of the thrombus. In the aorta and in some of its larger branches the loss of elasticity consequent upon the formation of fibrous tissue and subsequent degenerations leads to gradual dilatation of the blood-vessel walls, either in the form of diffuse ectasia or of localized aneurysmal sacs. Sometimes the degeneration of the diseased area occasions spontaneous rupture of the vessel.

Portions of the thrombotic deposits upon the roughened lining of the vessels, or portions of the degenerative tissue itself, may be discharged into the circulation, and may be carried to the peripheral parts as emboli.

Changes in Other Organs.—Diffuse arteriosclerosis places an impediment upon the heart which leads to hypertrophy of its walls, and in particular of the walls of the left ventricle.

When the process affects the small blood-vessels in the substance of the various organs, degenerative changes due to anemia and reactive hyperplasia of connective tissue are common results.

Thus, in cases of sclerosis affecting the cerebral vessels, cerebral softening is commonly met with, while in cases in which the branches of the coronary or of the renal arteries are affected, degeneration and fibroid changes are seen in the heart and kidneys.

INFECTIOUS DISEASES.

Syphilis may involve the blood-vessels in a variety of ways. No doubt, syphilitic infection is the most potent cause in the production of arteriosclerosis, but more specific involvement of the vessels occurs. Thus in areas of syphilitic infiltration and induration or adjoining gummata, the blood-vessels present noteworthy changes. The intima and the adventitia, but particularly the former, undergo great hyperplasia, and the lumen of the vessel may be almost obliterated. The changes are first noted in the intima, where large numbers of epithelioidal cells are formed, while, later, infiltration of round cells is observed. The adventitia is similarly, but less extensively, affected. There is no histologic or macroscopic feature by which the syphilitic nature of the disease can be positively asserted.

Tuberculosis.—The arteries may become involved in areas of tuberculosis, though, as a rule, they prove resistant for a long time. Typical caseous degeneration may be seen in the walls of the blood-vessels, beginning in the adventitia and gradually advancing toward the interior. In the lungs these changes are not infrequently seen in the walls of tuberculous cavities, and as a result there may be small aneurysmal dilatations at the points where the wall of the vessel has become eroded and weakened. It is from such vessels that the severe hemorrhages of the late stages of phthisis take place. Sometimes the blood-vessels of the tuberculous area present productive change leading to great thickening of the adventitia and of the intima, and there may be considerable narrowing of the lumen of the vessel. This, however, is less common than the degenerative changes before alluded to.

ANEURYSM.

Definition.—By aneurysm is meant a more or less localized dilatation of the arterial walls. The term has, however, been applied also to collections of blood outside of an artery enclosed by an adventitious wall and consequent upon a rupture of the vessel. The name *false* or *spurious aneurysm* has been specially applied to such cases, while the term *true aneurysm* is reserved for such as conform to the first definition. It is preferable to confine the single word aneurysm to the latter.

Etiology.—Aneurysms are always due to some weakness of the walls of the blood-vessel and to the distending force of the

blood within. It is therefore most common to find the disease in persons beyond the age of forty or forty-five years, and particularly in those who have acquired arteriosclerosis. Among the remote causes, therefore, are the causes of arterial disease—syphilis, gout, alcoholism, lead-poisoning, and other chronic intoxications. Sometimes it would seem that there is an hereditary weakness of the arterial coats, and instances of aneurysm occurring in successive generations have been recorded. Even congenital aneurysms have been observed. As contributing causes may be ranked all conditions which increase the blood-pressure. Thus laborious occupations, hypertrophy of the heart, and diseases which occasion constant excess of blood-pressure give rise to arterial degeneration and also to dilatation of the vessel in a purely mechanical way. Sudden aneurysmal dilatation of the weakened vessel may occur after severe straining efforts, as in coughing, during labor, in the straining of obstinate constipation, etc. Of all the causes, syphilis is most important.

More acute degenerative changes in the blood-vessels may lead to aneurysmal dilatations. Thus in the rare instances of acute aortitis in association with malignant endocarditis, small aneurysmal dilatations and even rupture of the aorta may occur. Embolism plays a part in a similar manner. Sometimes a calcareous embolus from a diseased valve of the heart, or from an atheromatous plate in the aorta, may lacerate the walls of the peripheral vessel, leading to the formation of a dilatation. In other cases infected emboli (as in malignant endocarditis or thrombosis with secondary degeneration of the clot) lodge in the peripheral vessels and occasion acute inflammatory or degenerative lesions of the walls, and eventually aneurysmal dilatation. These cases are analogous to the aneurysms of lower animals, caused by animal parasites (Fig. 181).

FIG. 181.—Worm-aneurysm of the horse (Leuckart).

The artery most commonly affected is the aorta, and in particular the thoracic portion. A majority of the aneurysms affecting the thoracic part of this vessel arise from the ascending limb, and not rarely it is one of the sinuses of Valsalva that first suffers dilatation. Next

to the aorta in point of frequency, the popliteal, femoral, carotid, subclavian, innominate, axillary, and iliac vessels are affected.

An interesting form, and one of great frequency and clinical significance, is that which affects the small blood-vessels of the brain, particularly the branches supplying the lenticulostriate body. This is the so-called *miliary aneurysm*, which is commonly the cause of cerebral hemorrhage (Fig. 182). It is simply a small saccular aneurysm due to weakening of the blood-vessel walls by sclerosis or degeneration.

In some cases of the condition described as *peri-arteritis nodosa* (see page 384) there has been discovered a hernious projection of the intima through defects of the media. These have been recorded as instances of congenital aneurysm; but this explanation does not suffice for all cases (see Arteritis).

In phthisical lungs there are often found somewhat similar hernious aneurysms, due to erosion of the adventitia and media by the tuberculous process; and it is from these that the severe hemorrhages of the late stages of phthisis occur.

FIG. 182.—Miliary aneurysm of the brain.

FIG. 183.—Cylindrical and somewhat cirsoid aneurysm of the abdominal aorta; an opening has been made to show the clot within (from a specimen in the Museum of the Philadelphia Hospital).

Pathologic Anatomy.—Aneurysms may be of three kinds: (1) those in which there is quite general dilatation of all of the coats of the vessel, and which therefore present themselves in the form of a more or less uniform dilatation (*ectatic aneurysm*); (2) those in which a local weakening leads to the formation of a saccular pouch, often communicating with the artery by a narrowed orifice (*saccular aneurysm*); and (3) those in which a rupture of the intima, and usually of portions of the media as well, has led to infiltration of blood between the tunics of the vessel-wall (*dissecting aneurysm*).

1. **Ectatic Aneurysm.**—There is more or less uniform dilatation in these cases, and there may be distinguished *fusiform* or *spindle-*

shaped and *cylindrical* varieties, according to the shape assumed (Fig. 183). In some instances the vessel is rendered tortuous by the unequal involvement of different portions, and to this form the term *cirsoid aneurysm* may be applied. The same term, as well as the name *anastomotic aneurysm*, is given to certain conditions of the arteries of the scalp and other parts which lead to the formation of tortuous vessels standing out prominently beneath the skin; but these are instances rather of hypertrophy of the coats, with increase of length and thickness of the walls, without in reality any aneurysmal dilatation at all.

In ectatic aneurysms the intima and adventitia are usually thickened, and there are generally atheromatous patches in the former. The media is generally thinner than normal, and may be actually deficient in places. Ectatic aneurysms may show a certain amount of thrombosis in the form of laminated clots, when there are pouchings or inequalities in the dilatation; but very frequently there is no thrombosis.

2. **Saccular Aneurysm.**—This is the most important variety. According to Thoma and others, the first step in the process is the

FIG. 184.—Saccular aneurysm of the arch of the aorta, projecting forward and attached to the ribs (Ziegler).

weakening or giving way of the media, followed by gradual dilatation of the intima and adventitia. There results a saccular dilatation communicating with an artery, from which it arises by a more or less narrow orifice (Fig. 184). The aneurysmal sac

grows larger and larger, and may eventually rupture; but even then a secondary retaining wall may be formed by condensation and reactive hyperplasia of the surrounding tissues. The wall of the aneurysmal sac consists of thickened adventitia and intima, the media being usually thinned and often completely wanting. The intima is generally covered with atheromatous plates, and the cavity, as a rule, contains more or less abundant laminated clots, which tend to contract and organize, or to suffer subsequent

FIG. 185.—Saccular and partly ectatic aneurysm of the descending part of the arch of the aorta (from a specimen in the Museum of the Philadelphia Hospital).

degeneration. The aneurysm, if small, may be completely healed by the organization of the clots within.

The tissues surrounding the aneurysm are pushed aside or compressed, and may suffer extensive necrosis. In cases of aneurysm of the thoracic aorta the sternum and ribs may be eroded, and the aneurysm may project beneath the skin anteriorly and eventually rupture (Fig. 187). In other cases the trachea, bronchial tubes, or lungs are compressed, and rupture takes place through the trachea or bronchi (Fig. 188). In still others the sac projects posteriorly, erodes the bodies of the vertebræ and ribs, and may compress the spinal cord or may project beneath the

tissues of the back. Occasionally communication is established with the large venous trunks, particularly the descending vena cava. Complete arrest or cure of an aneurysm may take place by organization of the clots contained, but such a result is rare.

3. **Dissecting-aneurysm** is most common in the aorta. As the result of degenerative lesions or of mechanical injury, rupture of the intima occurs, and the blood finds its way between the coats of the artery, often burrowing to considerable distances. In a case under my observation the walls of the aorta were dissected

FIG. 186.—Saccular aneurysm of the ascending part of the arch of the aorta (from a specimen in the Museum of the Philadelphia Hospital).

as far as the bifurcation, where secondary ruptures had occurred in the intima (Fig. 189). Usually the dissection takes place in the media, which is thus separated into two parts. Subsequently the adventitious canal may become lined with endothelium, and in my case atheromatous plates had formed in the latter.

Associated Conditions in Other Parts.—Some hypertrophy of the heart may occur when an aneurysm is situated near the root of the aorta, and particularly in instances in which direct pressure is brought to bear upon the heart. As a rule, however, the

amount of hypertrophy is much less than might be expected. Pressure upon the venous channels is an early manifestation, and

FIG. 187.—Aneurysm of the aorta: erosion of the sternum and projection of the sac beneath the skin.

leads to passive congestion and often to dropsy and cyanosis. Necrosis of the parts which are directly compressed has already

FIG. 188.—The trachea, showing perforation of an aneurysm of the aorta (from a specimen in the Museum of the Philadelphia Hospital).

been alluded to. Portions of the clot within the aneurysmal cavity not rarely become separated, and are carried as emboli to the peripheral parts of the circulation.

False or spurious aneurysms most commonly result from traumatism, though sometimes spontaneous rupture of the vessel is the immediate cause. The blood may find its way from the ruptured artery into the surrounding tissues, forming a blood-tumor, or *hematoma*, which becomes encapsulated by condensation of the surrounding tissues and by reactive overgrowth of connective tissue. The retaining wall thus formed may in some cases be lined with endothelial cells, and secondary inflammatory thickening or atheromatous plates may form. When an artery and vein

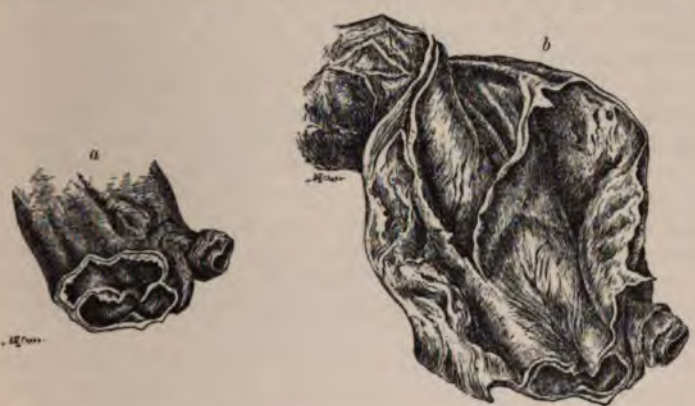

FIG. 189.—Dissecting-aneurysm of the aorta: the aneurysm began near the aortic valves and extended to the iliac branches, converting the aorta into a double tube: *a*, transverse, *b*, longitudinal section.

are both injured, as is sometimes the case in phlebotomy, the blood may enter the vein and distend this markedly. The term *aneurysmal varix* is applied to such cases. In other instances the artery and vein communicate by an intermediate sac formed by the condensation of the intervening tissues, and for such the name *varicose aneurysm* is used.

THE VEINS.

Anatomical Considerations.—The veins resemble the arteries, excepting that the muscular coat is less well developed and that most of the veins are supplied with endothelial reduplications or folds, which act as valves and prevent the backward flow of the blood.

CIRCULATORY DISTURBANCES.

Thrombosis of the veins is the most important condition. This, however, is sufficiently considered under Thrombosis (p. 55).

DEGENERATIONS.

Fatty degeneration of the intima and media may occur, as in the arteries, but it is comparatively rare and unimportant.

Calcification is met with in veins which have become dilated or varicose, or otherwise diseased.

INFLAMMATION, OR PHLEBITIS.

Acute phlebitis is a comparatively common affection. It may occur as the result of inflammation, particularly infectious inflammation, in the neighborhood of the vein. In such cases the outer coat is first involved, and the term periphlebitis is properly applied. This condition is met with in association with infected wounds and phlegmonous inflammations of the subcutaneous tissues. The veins beneath the skin may be distinctly visible as blue streaks running in various directions. Microscopically there is found to be an invasion of the adventitia with round cells, and actual foci of suppuration are not uncommon. The cellular infiltration may extend to the media and sometimes to the intima, and not rarely thrombosis occurs within. The thrombi thus formed may secondarily become infected, soften, and occasion septic embolism.

In another group of cases phlebitis begins from within, and is the consequence of primary thrombosis of the vein (Figs. 190 and 191). To such the name *thrombophlebitis* is applicable. The

FIG. 190.—Thrombophlebitis of the femoral vein (from a specimen in the Museum of the Philadelphia Hospital).

histologic changes are similar in these to those which occur in thrombo-arteritis, and as terminal results localized thickening of the venous wall or irregular contractions by the formation of fibrous adhesions and even complete obliteration of the venous channel may result. When the thrombus is thus organized or partially organized calcification may eventually occur, and in this manner *phleboliths*, or vein-stones, are formed.

Chronic phlebitis, or **phlebosclerosis,** corresponds to chronic arteritis or arteriosclerosis. A certain amount of chronic inflammatory thickening of the vein ensues as a consequence of thrombophlebitis. Phlebosclerosis may also be due to overdis-

tention of a vein resulting from thrombosis or other forms of obstruction, and thus plays a secondary part in dilatation of the veins, or phlebectasia.

Phlebosclerosis may, however, occur as a widespread affection in association with arteriosclerosis, though rarely in equal degree, in consequence of certain systemic conditions—syphilis, alcohol, gout, etc. The changes occurring in the vein are practically the

FIG. 191.—Phlebitis and periphlebitis of the umbilical vein of the new-born: purulent infiltration of the intima and adventitia; calcareous particles in the media (Birch-Hirschfeld).

same as those in the artery, but the new-formed fibrous tissue in the intima less commonly undergoes degenerative changes and calcification than in arterial sclerosis.

In cases of congenital syphilis an interesting form of thickening of the intima, leading to stenosis or even complete obstruction, has been found in the veins of the umbilical cord, and less frequently in the portal vein. Similar hyperplastic endophlebitis has been found in the veins of the extremities in syphilis of adults.

DILATATION OF THE VEINS; PHLEBECTASIA; VARICOSITY.

Etiology.—Dilatation of the veins occurs from mechanical obstruction to the circulation or from weakness of their walls. It presents itself more commonly in dependent portions of the

body, and is particularly frequent in the veins of the legs, of the rectum, of the neck of the bladder, of the spermatic cord, of the scrotum, and of the vagina.

Mechanical causes are most important. Thus in cases of cirrhosis of the liver, of obstinate constipation, and of pelvic tumors, dilatation of the veins of the rectum, causing hemorrhoids, is frequent. In cases of abdominal tumors, repeated pregnancy, or other causes of obstruction to the venous return of the blood from the lower extremities, varicosity of the veins of the legs is frequently observed. Always, however, local disease of the veins themselves tends to make the dilatations more pronounced, and in addition systemic depression, and particularly cardiac weakness, are contributing causes which operate by aiding in the stagnation of the blood, which otherwise might pass by collateral channels to its proper destination.

Pathologic Anatomy.—The veins in phlebectasia become dilated and also elongated, so that they soon assume a tortuous character. Not rarely masses of much-dilated veins lie closely aggregated in groups or clumps beneath the surface of the skin; and communications may be established between the adjoining pouches of dilatation, and thus a cavernous tissue is formed. The walls of the dilated veins are usually considerably thickened (phlebosclerosis), and even calcification may occur in the intima.

Results.—The circulation of the blood is slowed and thrombosis is therefore frequent. The thrombi may undergo organization or calcification, or in other cases may soften and occasion embolism. When varicosities are established in the veins of any submucous tissue, catarrhal inflammation of the overlying mucosa is occasioned and generally proves obstinate. At the same time a certain amount of hyperplasia of the connective tissue between the dilated veins takes place and thickening of the mucous membrane results. When the subcutaneous veins are involved the skin is prone to become thickened and to present eczematous inflammation, while the subcutaneous tissue may be greatly increased in thickness and density (phlebectatic elephantiasis, or pachydermia). Not rarely ulcerations of the skin of the lower extremity owe their origin to varicosity of the veins, and such ulcers are prone to prove indolent and obstinate. Hemorrhage may occur from varicosities of the submucous veins, particularly in case of hemorrhoids and in the esophageal varicosities of drunkards.

TUMORS.

Tumors rarely begin in the walls of the veins, though myoma and sarcoma have been described. More commonly the walls of the veins are secondarily involved in cases of tumors surrounding them.

INFECTIOUS DISEASES.

Tuberculosis not rarely attacks the veins, particularly those of the lungs. Perforation of the wall may take place, and miliary tuberculosis is a frequent consequence.

Syphilis of the veins has already been referred to.

THE LYMPHATIC CHANNELS.

Anatomic Considerations.—The lymphatic system begins in the lymph-spaces, which are the spaces between the tissue-elements in all parts of the body. These lymph-spaces unite to form definite lymphatic capillaries, which are channels having walls composed of a single layer of endothelial cells. The lymphatic capillaries unite to form larger vessels, and in these connective-tissue coats support the endothelial lining.

INFLAMMATION.

Inflammation of the lymphatic vessels, or **lymphangitis,** is always secondary to inflammatory affections of the parts surrounding the lymphatics, or of those parts from which the lymphatics take their origin. In cases of infective lesions of the extremities red lines, indicating the position and course of the inflamed lymphatics, may not infrequently be seen beneath the skin, extending upward to the nearest lymphatic glands. Histologically the first change in such cases is swelling and ofttimes multiplication of the endothelial cells of the lymphatic vessel; later, there may be accumulation of leukocytes within, and the lymphatic channel may be uniformly filled with pus or distended at different points. Usually a certain amount of perilymphangitis accompanies the process, and in cases of violent septic infection the surrounding tissues may become extensively involved in phlegmonous inflammation. Thrombosis may take place within the lymphatic channel in cases of moderate severity, and obstruction ensue. The termination is either in resolution or suppuration, with more or less widespread involvement of the surrounding tissues. Resolution may be only partial, the inflammatory changes going on to the formation of connective tissue, which may obliterate the channels, or the restitution of the wall of the lymphatic vessel may be imperfect, and subsequent dilatation results.

DILATATION OF THE LYMPHATICS, OR LYMPHANGIECTASIA.

This condition may be an acquired or a congenital affection.

Acquired dilatation of the lymphatics results from obstruction to the larger channels, as in cases of pressure upon or thrombosis of the thoracic duct, or of obstruction of the lym-

phatic channels by filariæ. In other cases it is due to inflammations surrounding the lymphatics and leading to weakness of their walls. It is very commonly observed in the subcutaneous lymphatics, and constitutes the endemic elephantiasis of warmer countries. This condition is particularly common in the lower extremities, scrotum, and labia, but may affect other parts. The skin is greatly thickened and the surface often of irregularly lobulated character. On incision into it there is found an abundant exudation from the subcutaneous tissue of serous or of milky liquid.

Obstructive dilatation of the intra-abdominal lymphatics is not unusual. Rupture of dilated branches in the genito-urinary tract may lead to chyluria.

Congenital lymphangiectasia may take the form of a diffuse condition affecting the lymphatics more or less regularly in certain parts of the body, or it may appear in circumscribed areas, often in situations in which the ordinary lymphatic supply is not abundant. The diffuse form occasionally presents itself in the new-born in the form of edematous or semicystic swellings of the subcutaneous tissue, resembling those of elephantiasis. In the same group of cases belong the instances of congenital enlargement of the tongue (*macroglossia*) and of the lips (*macrocheilia*). In some of these instances the development of the condition does not occur until some time after birth, though the process is in reality congenital. Localized lymphatic dilatations constitute the form of new growth known as lymphangioma (see General Pathology).

INFECTIOUS DISEASES.

Tuberculosis.—The lymphatics play an important part in the dissemination of tuberculosis within the organs, and they may themselves be involved in the disease. This is beautifully illustrated in cases of intestinal tuberculosis with ulceration. In such cases the lymphatic channels in the serous coat may be seen radiating from a point opposite the ulceration toward the mesentery, and small miliary nodules are seen in their course.

Syphilis.—The lymphatics may be involved in syphilitic processes in their vicinity, but the changes are not characteristic.

TUMORS.

In addition to the lymphangiomata referred to, the lymphatic vessels are the primary seat of tumors resulting from multiplication of the lining endothelial cells, which are known as *endotheliomata*. These tumors are especially common in the serous surfaces, but may also be met with in the skin and elsewhere. The lymphatics bear an important relation to the metastasis of malignant tumors, particularly of carcinomata. The carcinoma-cells enter

the lymphatics and are carried by the stream to distant parts of the body; sometimes the lymphatics near carcinomata are found densely packed with cancer-cells.

PARASITES.

The adult of the Filaria sanguinis hominis resides in the lymphatic vessels, and the embryos may be present in large numbers (see General Pathology).

THE THORACIC DUCT.

Pathologic processes involving the thoracic duct resemble in general character those of the other lymphatic vessels, but the size of the duct and its anatomical relations make the diseases affecting it of somewhat greater significance than the same diseases when occurring in the smaller lymphatics.

Thrombosis may occur in association with inflammation of the duct or without such, and there may be a permanent occlusion in consequence. Dilatation of the lower parts of the duct, as well as of the lymphatic vessels of the abdomen, may ensue, and sometimes the receptaculum or other portions of the duct may become cystic. Chylous ascites may likewise result. More commonly collateral circulation re-establishes circulation and serious consequences are not observed.

Dilatation of the thoracic duct may also result directly from cardiac failure with engorgement of the greater veins. The outflow of lymph is impeded, and in some cases the backward pressure of the blood through the superior cava may fill and distend the upper part of the thoracic duct with blood.

Inflammation occurs in consequence of various inflammatory diseases of the abdomen or of the pelvis, by the invasion of irritants through the lymph received from the affected areas. There may also be direct extension of inflammation in cases of abdominal disease, or in pleurisy or other intrathoracic affections.

Tuberculosis affecting the abdominal portion of the duct is sometimes observed in cases of intestinal or mesenteric tuberculosis, and may occasion secondary miliary tuberculosis, particularly the form in which the disease is subacute or chronic in its course (Weigert).

Tumors.—Primary tumors are sometimes observed, and secondary carcinoma is more commonly met with.

CHAPTER IV.

DISEASES OF THE RESPIRATORY SYSTEM.

THE NASAL CAVITIES.

Anatomic Considerations.—The mucous membrane of the nose is unusually prominent, especially over the lower turbinated bone, where it is 4 mm. thick. In the lower, or respiratory, parts of the nose the epithelium is stratified ciliated columnar. The submucosa is replete with a venous network, giving it, particularly over the inferior turbinated bone, the appearance of erectile tissue. In the olfactory regions non-ciliated columnar cells, which become attenuated at the inner end, line the surface. Between the filiform prolongations within lie round and tapering *olfactory cells*. Small tubular and racemose serous and mucous glands are freely distributed in the mucosa.

CONGENITAL ABNORMALITIES.

Deviations of the septum and other slight anomalies are common. Atresia, absence of the septum or other parts, or complete absence of the nose, are rare defects. Harelip and cleft palate frequently involve the nasal cavities.

CIRCULATORY DISTURBANCES.

Active congestion occurs in consequence of exposure to great heat or cold, or of ascending elevations; and when the heart is overstimulated.

Passive congestion may be due to cardiac weakness, obstructive diseases of the lungs, and local pressure on veins.

Hemorrhage.—In either passive or active congestion hemorrhage (*epistaxis*) may occur. Bleeding may, however, result from blood-diseases (hemophilia, pernicious anemia, leukemia), from disease of the blood-vessels (arteriosclerosis), or in a paroxysmal form from obscure causes. Epistaxis is a frequent prodromal symptom of typhoid fever; less frequently it occurs in influenza and other infections.

Edema of the mucous membrane may be associated with inflammation.

INFLAMMATIONS.

Acute nasal catarrh (acute rhinitis; coryza) commonly results from exposure to cold. Irritant fumes may cause it; often it seems infectious and contagious. It may occur as an associated

condition in various infections, as grip, typhoid fever, measles, etc. The mucosa is at first intensely red and dry; then an irritating serous, followed by mucous and finally mucopurulent, exudation is discharged. Herpes or eczematous eruptions of the lip are common. Considerable inflammatory edema of the mucous membrane of the nose and accessory cavities may occur.

Chronic rhinitis follows repeated acute attacks, especially in scrofulous, tuberculous, or syphilitic persons. The mucosa, especially over the inferior turbinated bone, becomes thickened (hypertrophic rhinitis) and may remain so, or undergo atrophy (*rhinitis atrophica*). In the latter the exudate is scanty and appears as dry, greenish crusts, which sometimes occasion extensive ulcerations and become horribly offensive. To such cases the term *ozena* is applied. Various forms of bacilli and micrococci have been discovered, the most frequent being an organism resembling the bacillus of Friedländer. Fetid discharges may also occur in syphilitic or tuberculous diseases of the nose (ozœna syphilitica s. tuberculosa).

INFECTIOUS DISEASES.

Diphtheritic rhinitis is usually secondary to pharyngeal diphtheria. Non-specific pseudo-membranous rhinitis is a very rare condition.

Syphilis in the secondary stage and in congenital cases sometimes occasions simple catarrhal rhinitis. Mucous patches may occur, or gummata springing from the mucous membrane or from the periosteum or perichondrium. The latter tend to ulcerate and cause destruction. The purulent discharge may be fetid.

Tuberculosis may occur as disseminated or aggregated tubercles of the mucous membrane, or as ulcers and carious processes. These are all rare, but "scrofulous catarrhs" of children, probably often tuberculous, are common. *Lupus* of the face may extend to the nose.

Glanders occasions intense purulent and hemorrhagic rhinitis, or nodular growths with ulceration. Nodules and ulcers in *lepra*, and irregular swelling and induration of the mucous membrane of the nose and the adjoining skin in *rhinoscleroma* are rare conditions.

TUMORS.

The commonest form of tumors is the *polyp*, which is sometimes distinctly the result of hypertrophic rhinitis, at other times obscure in origin. Polyps present the ordinary structure of the nasal mucosa, with a tendency to cystic change from occlusion of the glands, or to adenomatous appearances from proliferation of the glandular elements. Fibroid, myxomatous, and sarcomatous polyps also occur. In all cases there is a tendency to recurrence

after removal. A rare form of *hairy polyp* has been recently described. Chondromata, osteomata, sarcomata, and epithelial or glandular cancers may be found.

PARASITES AND FOREIGN BODIES.

Larvæ of various flies may occur in the nasal chambers and set up serious inflammatory lesions. Foreign bodies may become incrusted with lime-salts and lead to the formation of *rhinoliths*.

THE LARYNX.

Anatomic Considerations.—The lining epithelium of the larynx is stratified squamous as far as the false vocal cords. Below these and throughout the ventricles it is stratified ciliated columnar, and thus continues into the trachea and bronchi, excepting over the true vocal cords, which are covered with stratified squamous epithelium. The tunica propria contains much yellow elastic fiber, and the submucosa is quite loose, especially over the base of the epiglottis and the aryepiglottic folds.

CONGENITAL ABNORMALITIES.

Minor defects in shape of the constituent parts of the larynx are not rare. Congenital fistulæ communicating with the exterior, and dilatation of the ventricles similar to the normal pouching found in certain monkeys, are occasionally met with. Abnormal largeness and smallness, the latter especially in persons having poorly developed sexual organs and those castrated early in life, are more frequent conditions.

CIRCULATORY DISTURBANCES.

Anemia may occur in general anemia, and is sometimes found in tuberculous and chlorotic subjects in pronounced degrees.

Active hyperemia follows exposure, overuse of the voice, and irritation by gases, dust, and the like.

Passive hyperemia occurs in heart-diseases, intrathoracic tumor, and other conditions obstructing the venous circulation. In active congestion the larynx is bright red; in passive congestion it is dark red in color, and distended veins may be prominent.

Hemorrhages are seen in the mucosa after death from asphyxia, in cases of purpura or other hemorrhagic conditions, as well as in intense inflammation of the larynx. Large hemorrhages may occur in cases of cancer.

Edema of the epiglottis, the aryepiglottic folds, and other parts of the larynx may be part of a general anasarca in Bright's

disease or heart-disease, or may result from local pressure upon the veins. The parts become greatly swollen, and of an anemic, translucent appearance. Great stenosis of the larynx commonly results. Generally "edema of the larynx" is inflammatory in nature (see below).

INFLAMMATIONS.

Acute catarrhal laryngitis results from chemical or mechanical irritation; it accompanies whooping-cough, measles, small-pox, typhoid fever, and other infections. The mucous membrane is bright red and swollen. A scanty mucous or muco-purulent exudate is usually noted. Intense laryngitis is attended with small hemorrhagic ecchymoses or erosions; true ulcers are rare. Follicular ulcers are sometimes seen, and rarely small vesicles arise upon the surface (*herpetic laryngitis*).

Acute laryngitis may cause considerable disturbance of breathing by the swelling of the mucous membrane, and in children often leads to spasmodic contraction of the laryngeal muscles, with paroxysmal dyspnea (*false croup*).

Chronic catarrhal laryngitis may follow the acute form, or begin gradually. Overuse of the voice and exposure to cold or irritating gases or dust are the common causes. The mucous membrane is usually thickened and somewhat granular, or even papillomatous. There is a tendency for the epithelium to assume a squamous or epidermoid character, especially on the vocal cords (*pachydermia laryngis*). In the later stages atrophic changes may ensue.

Edematous laryngitis is generally known as edema of the larynx. Nearly always it is a true inflammatory edema, due to violent irritation, general or local infection, or severe local lesions of a chronic nature, such as tuberculous or syphilitic ulceration and perichondritis. The looser submucous tissues at the base of the epiglottis and over the aryepiglottic folds become greatly swollen, and the surface is more or less translucent. Sometimes the edematous infiltration is yellowish, or even quite purulent, especially in cases in which phlegmonous suppurations have extended from neighboring parts (retropharyngeal abscess; erysipelas). When circumscribed areas are affected *abscess* results.

Perichondritis, inflammation of the perichondrium of the cartilages of the larynx, is usually secondary to serious laryngeal diseases, as syphilitic or tuberculous ulcers, carcinoma, etc. It may be primary in typhoid fever or other infections. Frequently suppuration and necrosis of the cartilage result; but merely localized induration and swelling may occur.

INFECTIOUS DISEASES.

Diphtheritic and **croupous inflammations** may be part of the anatomical changes in diphtheria, but may also occur in typhoid fever, scarlet fever, small-pox, or other infectious diseases, or from violent irritation by steam or the like. The surface of the larynx is covered with a more or less adherent, grayish or yellowish pseudomembrane, which consists of a network or masses of fibrin entangling degenerated round cells and epithelium. The membrane is most adherent where the epithelium is squamous. Diphtheritic laryngitis usually follows a similar process in the pharynx (see Diphtheria, Part I.).

FIG. 192.—Tuberculous erosion and ulceration of the larynx, causing extensive destruction of the vocal cords (from a specimen in the Museum of the Philadelphia Hospital).

Tuberculosis is nearly always secondary to pulmonary tuberculosis. Small localized tuberculous masses, or more diffuse tuberculous infiltration, are found in the mucosa and submucosa, especially on the posterior wall of the larynx. Early caseation and ulceration are further characteristics (Fig. 192). Simple catarrhal inflammation, or hypertrophic conditions of the mucous membrane between the tuberculous masses, or edematous laryngitis and perichondritis, may complicate the tuberculous lesions. *Lupus* of the nose and pharynx may extend to the larynx, where it occasions nodular thickenings and ulceration.

Syphilis may occasion simple catarrh of the larynx, or infiltration and erosion of the mucous membrane secondary to pharyngeal involvement. The latter conditions are most frequent in the epiglottis, the posterior wall of the larynx, and the vocal cords. Gummata may occur in the same situations independent of pharyngeal syphilis, and lead to deeper ulcers. In the healing of syphilitic ulcers irregular papillomatous elevations of the healthy mucosa, or extreme contractions and deformities of the larynx, may occur.

Lepra and **glanders** sometimes occur in the form of nodular swellings and ulcers.

Swelling and ulceration of the lymphatic follicles analogous to the lesions in the intestines may occur in *typhoid fever;* and in *small-pox* there may be small areas of infiltration and epithelial degeneration, or even pseudomembranes.

TUMORS.

Papilloma.—Over half of all tumors of the larynx belong to the group of *papillomata* or *papillomatous fibromata.* These are simply hypertrophied papillæ covered with a thick mantle of squamous epithelium (Fig. 193). The stroma may be insignificant and the epithelium considerable (hard papilloma), or the stroma may be excessive, highly vascular, and infiltrated with round cells, while the epithelial covering is thin (soft papilloma). Papillomata are most frequent on the false vocal cords or on the other parts of the larynx lined with squamous epithelium. They usually occur in numbers, but may be solitary. Chronic inflammation often determines their occurrence; and they are not infrequent around chronic ulcers or carcinoma of the larynx. Simple hyperplasia of mucous membrane, of normal structure, occurs in various chronic inflammatory conditions of the larynx.

FIG. 193.—Papillomata of the vocal cords (from a specimen in the Museum of the Philadelphia Hospital).

Fibroma.—Nodular, sessile, or polypoid fibromata constitute one-third of all tumors. They are most frequent on the vocal cords and in the upper part of the larynx.

Cystic dilatation of the glands may occasion *mucous polyps.* Adenoma, lipoma, myxoma, sarcoma, and chondroma are rare tumors. Tumor-like masses of heterotopic thyroid gland tissue have been found in the larynx.

Carcinoma may be primary, or less frequently secondary. Primary carcinoma is usually of the squamous variety and occurs about the vocal cords. Nodular thickening with ulceration results. Papillomatous thickening of the mucous membrane frequently surrounds the growth. Secondary involvement of the cervical glands and esophagus may occur.

Of 1100 tumors of the larynx, collected by Bruns, 602 were papillomata, 346 fibromata, 73 mucous polyps, and 27 cysts. Seventy-six per cent. occupied the true cords, or the anterior commissure of the cords. Mackenzie found 67 per cent. papillomata and 16 per cent. fibromata.

PARASITES AND FOREIGN BODIES.

The larval *Trichina spiralis* may infest the laryngeal muscles; and *lumbricoids* occasionally enter from the pharynx. *Echinococcus* cysts are very rare.

Large foreign bodies may cause death by suffocation. Smaller bodies may rest in the larynx, especially the ventricles, for years, becoming surrounded by hyperplastic mucous membrane or a capsule of fibrous tissue. Calcareous concretions may form around small foreign bodies, or spontaneously in the ventricles.

THE TRACHEA.

MALFORMATIONS.

Congenital Malformations.—Complete absence of the trachea occurs in acephalic monsters. Congenital decrease in length or diameter, in the number or completeness of the cartilages, and like minor deformities, are more common. An adventitious bronchus is occasionally seen, especially on the right side, and fistulous communications with the exterior or with the esophagus are rare congenital defects. Diverticula may be due to a rudimentary condition of a supernumerary bronchus. Congenital cysts may occur between the trachea and esophagus when fistulous communications between them become closed at either end.

Acquired Malformations.—Dilatations of the trachea may be diffuse or localized. They depend for their occurrence upon weakness of the walls and some impediment to expiration. Saccular dilatations are usually on the posterior wall. Narrowing of the lumen may be due to pressure of tumors or aneurysms; to new growths or cicatricial contractions (especially syphilitic) or to foreign bodies within.

CIRCULATORY DISTURBANCES.

Anemia and active and passive congestion result from the same causes as in the larynx; and the pathologic anatomy is the same.

INFLAMMATIONS.

Inflammations are usually associated with laryngitis or bronchitis, and are due to the same causes. Simple catarrhal and pseudomembranous inflammations are met with. Foreign bodies may cause extensive and deep inflammation, leading to ulceration and sometimes perforation. Chronic inflammation assumes a proliferative, and later an atrophic, character. Proliferative (polypoid) inflammation is not infrequent after tracheotomy, and may occasion serious obstruction. Ozena of the trachea may be associated with nasal ozena.

INFECTIOUS DISEASES.

Tuberculosis and **syphilis** occur under the same circumstances as in the larynx. Syphilis may, however, affect the trachea and bronchi independent of disease of the pharynx or larynx.

TUMORS.

Primary tumors are rare. Secondary involvement by *cancer*, extending from the esophagus or thyroid gland, or by *sarcoma*, from the surrounding lymphatic structures or thymus gland, is more frequent. Ecchondroses and osteomata may spring from the cartilages, and multiple chondromata have been found in the mucous membrane. Retention-cysts of the mucous glands are occasionally seen on the posterior wall, protruding outside the trachea.

THE BRONCHI.

Anatomic Considerations.—The larger bronchi correspond very closely to the trachea in structure. The smaller divisions have thinner walls, being less provided with cartilaginous rings, but having instead small cartilage-plates and greater abundance of muscle-fibers. The tubes having a diameter less than 1 mm. are called the *terminal bronchioles*, and lead into yet smaller tubes, the *alveolar passages*, which open into dilated *infundibula*, and the last named are finally surrounded by *air-sacs*. The lining epithelium is stratified columnar ciliated down to the terminal bronchioles, where it becomes simple columnar. In the alveolar passages there is first polygonal, then flat, epithelium; while in the infundibula and air-sacs there are practically only flat epithelial cells.

CONGENITAL MALFORMATIONS.

These are rare and unimportant. Dilatations or narrowing and anomalous division of the tubes have been noted (see Trachea).

CIRCULATORY DISTURBANCES.

Anemia and **hyperemia** occur under the same circumstances as in the trachea and larynx.

Hemorrhage.—Intense congestion may occasion hemorrhages into the mucous membrane or into the bronchi themselves. More frequently hemorrhage is due to catarrhal inflammation, tuberculous ulceration, or a general hemorrhagic tendency. Aneurysms of the aorta (see Fig. 188) and the small aneurysms of the pulmonary arterioles in tuberculosis of the lungs not infrequently rupture through the bronchi.

INFLAMMATIONS.

Both acute and chronic bronchitis are common conditions, and there are a variety of forms.

Acute catarrhal bronchitis results from exposure, from inhalation of irritating gases, and from downward extension of tracheal catarrhs. The terminal bronchioles are frequently affected secondarily in pulmonary diseases. Bronchitis is constantly associated with some of the infectious fevers—typhoid fever, measles, whooping-cough, etc. Various micro-organisms have been found in bronchitis. Among these are the pyogenic micrococci, the diplococcus of Fränkel, the bacillus of Friedländer, and latterly the Bacillus influenzæ, the Bacilli coli, with many others. The mucous membrane presents an intensely red color; at first it is dry, but later a mucous or mucopurulent exudate is formed

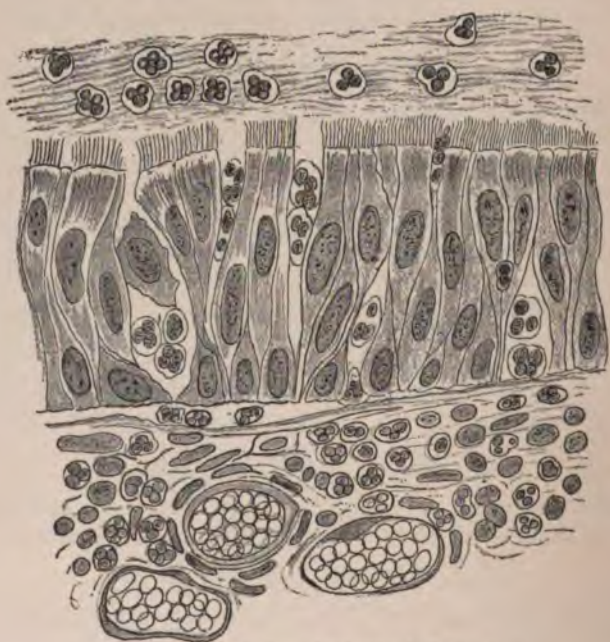

FIG. 194.—Acute bronchial catarrh (Thoma).

(Fig. 194). The exudation may be excessive in quantity, in which case the condition is called *bronchorrhea*. This may be serous or purulent, and is sometimes very offensive in odor (*fetid bronchitis*). Microscopically the bronchial mucous membrane is infiltrated with round cells, especially in the purulent cases; the epithelial cells are degenerated, many being converted into goblet-cells; and the mucous glands are distended with mucus. The inflammatory conditions may extend outward as far as the peribronchial tissue, and occasionally there is some perichondritis.

Chronic catarrhal bronchitis occurs after repeated attacks

of the acute form, and especially in old persons or in those who have some cardiac weakness which tends to cause congestion of the bronchi. Chronic bronchitis is frequently associated with chronic diseases of the lungs. In chronic cases the mucous membrane may undergo considerable alteration. Frequently the ciliated cells disappear entirely and are replaced by columnar or polygonal epithelium; and hypertrophic conditions of the mucous membrane are sometimes present. More frequently the bronchus is uniformly thickened by cellular infiltration and overgrowth of fibrous tissue.

FIG. 195.—Large bronchial coagulum; chronic fibrinous bronchitis (Vierordt).

Fibrinous bronchitis occurs under a variety of conditions. It is most frequent in association with laryngeal and tracheal diphtheria, but may also be due to inhalation of powerful irritants. Croupous inflammation of the

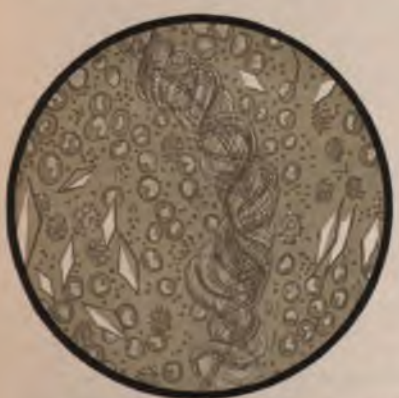

FIG. 196.—Sputum from a case of asthma, showing Curschmann spirals, Charcot-Leyden crystals, leukocytes, and numerous free eosinophile granules; unstained specimen (Jakob).

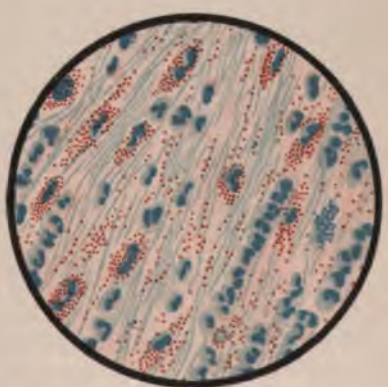

FIG. 197.—Sputum from a case of asthma, showing leukocytes, some containing eosinophile granules; free eosinophile granules; and micrococci; stained with eosin and methylene-blue (Jakob).

finer bronchi occurs in both croupous and catarrhal pneumonia. Finally, there is a form of chronic or essential fibrinous bronchitis,

characterized by periodical attacks, in which fibrinous casts of the bronchi are formed and discharged (Fig. 195). In all forms of fibrinous bronchitis there are often found in the sputa, on microscopic examination, fine spirals wound about a central fiber (*Curschmann's spirals*); and within these or associated with them the small octahedral crystals described by *Charcot* and *Leyden*.

Bronchiolitis Exudativa.—This term was given by Curschmann to the condition of the terminal bronchioles he assumed to be present in cases of asthma. The sputa contain the spirals that bear his name, and Charcot-Leyden crystals. The sputa in these cases are further characterized by the abundance of eosinophile cells (Figs. 196 and 197).

Ulcers of the bronchi are met with in severe catarrhal inflammations, but more frequently are tuberculous, syphilitic, or due to extension of ulcerative processes from neighboring parts. It is not unusual to find ulceration in the main bronchus opposite the point of pressure of an aneurysm.

Peribronchitis may occur from direct extension of inflammation from within, or it may be due to extension along the lymphatic channels from the pleura or interlobular septa of the lung. It is found most frequently as a part of pulmonary tuberculosis, and may be fibrous, caseous, or purulent.

STENOSIS AND OBSTRUCTION OF THE BRONCHI.

The smaller bronchial tubes may be considerably occluded by catarrhal swelling of the mucosa and accumulation of exudate within. Clinically this is often so marked in bronchitis affecting the terminal bronchioles as to have suggested the name suffocative catarrh. (This capillary bronchitis is always merely a part of bronchopneumonia, and will be considered under that head.) More serious obstructions of the bronchi occur when old ulcers have healed, leaving cicatrices; or in cases of tumors of the bronchi or pressure upon the outside. Foreign bodies are usually coughed up, but may remain for long periods and occasion obstruction.

BRONCHIECTASIS, OR DILATATION OF THE BRONCHI.

This is due to increased pressure within the bronchi or to some weakness of the walls, or to both. The weakening of the walls is most frequently due to chronic bronchitis. If it is extreme, simply the force of the inspired air may suffice to cause dilatation, but the increased expiratory efforts of coughing may aid materially. When a part of the lung is collapsed (atelectasis) the impediment to the entrance of air leads to dilatations of the bronchi above the collapsed area. This is especially noted in children. The weight of accumulating secretions in the tubes is rarely the cause of bronchiectasis. Finally, in fibrous pneumonia the traction of the connective tissue, attaching itself, on the one hand, to the outer wall of the bronchus, and, on the other hand, to the pleura, may bring about considerable dilatations.

The enlargement of the bronchus may be localized, when it

is termed *saccular bronchiectasis;* or more uniform, when the names *cylindrical* and *fusiform* are applied, according to the shape of the bronchus (Fig. 198). The mucous membrane may be almost normal in appearance in small dilatations, but more commonly is thickened and irregular on the surface. There may even

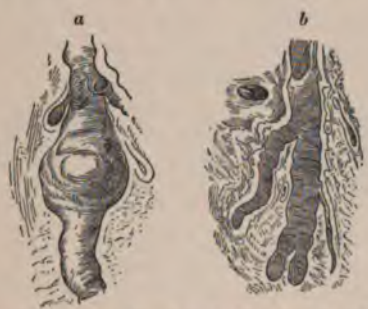

FIG. 198.—Bronchiectasis: *a*, saccular; *b*, cylindrical; one-half natural size (Orth).

be actual polypoid outgrowths, and ulcerations may occur when the secretions are specially abundant and irritating. Microscopically the epithelium is found to approach the squamous type; while the wall of the bronchus is generally infiltrated and cirrhotic. The exudation is generally purulent and copious, and may be very fetid. Occasionally it is thick and cheesy.

INFECTIOUS DISEASES.

Tuberculosis of the bronchi is usually associated with pulmonary tuberculosis, and appears in the form of miliary or larger nodules in the mucosa or submucosa, which tend to break down to form ulcers.

Syphilis sometimes occurs in the form of eruptions and ulcers. There may be dense scar-formation and deformity in consequence of the healing of such ulcers.

TUMORS.

Polypoid conditions of the mucosa occur in cases of chronic bronchitis. Fibroma, chondroma, and lipoma are rare forms of tumors. Primary cancers may spring from the mucous glands, or from the surface-epithelium, but are very rare. Leukemic nodules are seen in the bronchi at times, and lymphosarcomata are not rarely found to spring from the peribronchial lymphatic tissues.

PARASITES AND FOREIGN BODIES.

Bronchiectatic cavities may contain a growth of aspergillus—*Mycosis aspergillina.* Round worms may enter by migration, and hydatid cysts are met with.

Foreign bodies from the exterior usually enter the right bronchus. They often lead to serious inflammation and suppuration, unless they are coughed up. Bronchial concretions sometimes form by inspissation of the secretions, especially in bronchiectatic cavities. Very rarely cartilaginous or bony masses, derived by outgrowth and later separation from the bronchial cartilages, are observed.

THE LUNGS.

Anatomic Considerations.—The structure of the lungs in their unexpanded condition is very similar to that of an epithelial gland, consisting of ducts, the bronchi; and glandular tissue, the pulmonary parenchyma. The terminal bronchioles divide into several alveolar passages, which open into infundibula, and these in turn are surrounded by air-sacs. The groups of infundibula connected with a terminal bronchiole constitute an acinus. Neighboring acini unite to form lobules, and the lobules unite to form lobes. The epithelial lining-cells of the air-sacs are large, flat plates, which resemble endothelial cells very closely. Beneath these cells is a layer of elastic tissue, which gives the lungs their characteristic elasticity, and in which is embedded a rich network of capillaries, that carry on the proper respiratory function of the lungs. These capillaries are the terminal ends of the pulmonary artery. Another set of blood-vessels, the bronchial arteries, serve only to nourish the walls of the bronchi and the structure of the lungs themselves. The return circulation is mainly carried on by the pulmonary veins, which receive the blood of the pulmonary arteries and much of that of the bronchial arteries. The distribution of the lymphatic vessels in the lungs is of the greatest significance in pathologic anatomy, especially with regard to the dissemination of infectious diseases in the lung itself. One system of lymphatics begins in the lymph-spaces between the cells of the intervesicular septa. These lymph-spaces deliver their contents to lymphatic capillaries in the same region, and these in turn follow the alveolar passages, surrounding the latter on all sides. Where the several alveolar passages unite to form a terminal bronchiole the smaller lymphatic capillaries also unite to form larger branches, which follow the bronchioles. Other lymphatic vessels surround the pulmonary veins, constituting a perivascular system. Still another system begins in small subpleural capillaries, which unite and enlarge and penetrate the lung along the interlobular septa. A portion of them also pass at once to the peribronchial and perivesicular tissues. All of the lymphatic trunks leave the lung at the root and eventually discharge into the thoracic duct.

Collections of lymphoid cells are found in various places along

the lymphatics in the tissue of the lung. Near the root these are of considerable size, and merit the name of lymphatic nodes or glands. Still larger and more important ones are found surrounding the bronchi just outside the lungs, and around the end of the trachea.

CONGENITAL DEFECTS.

Complete absence of the lungs has been noted in certain monsters. One lung may be absent, or its parenchyma may be undeveloped, while the bronchi are dilated even to a cystic condition. The opposite lung is compensatorily enlarged. Minor abnormalities in the division of the lobes and the like are not rare; and in a few instances accessory lobes, wholly disconnected from the rest of the lung, have been observed.

CIRCULATORY DISTURBANCES.

Anemia of the lung occurs as a part of general anemia, from pressure upon the lung, or from obstruction or obliteration of the blood-vessels. The last is the cause of the great pulmonary anemia in emphysema of the lungs. The lungs are pale in color or of a mottled appearance in elderly persons, in whose organs considerable pigment is usually present.

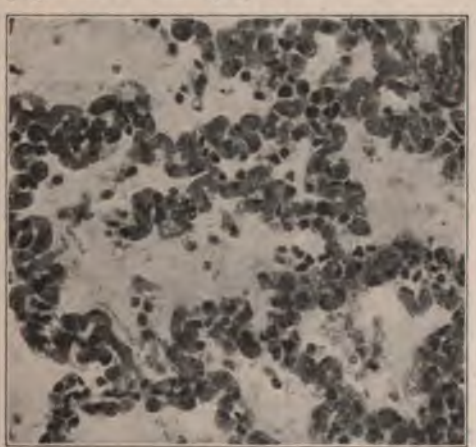

FIG. 199.—Acute congestion of the lung (Karg and Schmorl).

Active Hyperemia or Congestion.—Exercise constantly leads to increased flow of blood to the lungs, and this may be extreme, causing rapid death (*apoplexia pulmonum vascularis*). In cases of irritation of the lungs by the inhalation of heated or cold air, or of irritating gases, and in certain lesions of the base of the brain, there may be more or less active congestion of the lungs (Fig. 199). *Collateral hyperemia* occurs when the opposite lung

or some other part of the body becomes anemic. The lung in active hyperemia has a dark-red color, and on section blood flows from the surface of section. The alveoli may contain free blood, and in marked cases there is blood in the sputa during life.

Passive hyperemia is for the most part a chronic condition, due to causes which prevent the outflow of blood from the lungs. The most frequent cause is valvular disease, particularly mitral stenosis and regurgitation; but weakness of the left ventricle from fatty disease or fibroid degeneration acts in a similar manner. Any local cause of hindrance to the outflow of the blood in the veins leads to similar passive congestion. It is often found in the dependent parts of the lungs in cases of great asthenia, as in typhoid fever. This is called *hypostatic congestion;* not infrequently it leads to hypostatic pneumonia when irritants are inspired or descend through the bronchi to the parts of the lung affected. Post-mortem there is often a similar hypostatic congestion, but without any evidences of catarrhal inflammation of the bronchi, such as always occurs in the cases developed during life.

FIG. 200.—Phagocytic cells of the sputum, containing blood pigment, from a case of cardiac congestion of the lungs (Jakob).

The lung in passive hyperemia is dark-red in color and heavy. In the more acute cases it is moist on section, being infiltrated with serous exudate and blood; in chronic cases, as in slow heart-failure, the tissue is dry and indurated. Microscopically the blood-vessels in the alveolar walls are seen to be greatly distended, and project into the alveoli. Red and white blood-corpuscles are seen within the alveoli and in the interstitial tissues. In the later stages the red corpuscles either re-enter the circulation or break down to form dark pigment-granules within the alveolar epithelial cells, the leukocytes, or lying free in the tissues of the alveolar walls. In such cases there are at the same time considerable hyperplasia and indu-

ration of the connective tissue of the lung; and the whole process is called *cyanotic induration*. In cases of heart-disease with congestion of the lungs there are very commonly found in the sputa pigmented epithelial cells and leukocytes, such as those described above (Fig. 200). They are of somewhat diagnostic importance.

Edema occurs most frequently as a result of passive hyperemia. In other cases the edema is the consequence of general septic conditions which lead to unusual permeability of the blood-vessels. Similar edema, not dependent on passive congestion, occurs in the parts of the lung surrounding inflammatory areas, and in some cases sudden pulmonary edema seems dependent on vasomotor relaxation. In the cases of edema due to passive congestion the lungs are dark-red in color, and on section more or less serous fluid, rendered frothy by admixture of air, exudes from the cut surface. In the other forms of edema the lung may be quite light in color, generally grayish, but on section the same frothy serum exudes from the surface.

Hemorrhage.—Small punctate hemorrhages occur in cases of severe congestion or inflammation, in the hemorrhagic or infectious diseases, and in consequence of high blood-pressure, as in death from asphyxia or in whooping-cough. When hemorrhage from congestion is combined with serous effusion the lung assumes an appearance not unlike that of a hyperemic spleen (splenization). A form of apparent hemorrhage is seen in cases in which the blood is aspirated from the bronchi. In such cases, lobular spots of hemorrhagic infiltration are found at the bases. Large hemorrhages into the substance of the lungs may be traumatic, or they may be due to rupture of an adjacent aneurysm into the lung. Small or large pulmonary hemorrhages are at times due to lesions of the nervous system, especially of the base of the brain.

Hemorrhage from the lungs, discharging externally through the bronchial tubes, is most commonly due to tuberculosis, and is particularly frequent in the late stages, when cavities have formed. The immediate source of the bleeding is generally an eroded vessel in the wall of the cavity, and a small miliary aneurysm is commonly found at the point of erosion. Hemoptysis may be the first indication of the existence of pulmonary tuberculosis, but the old belief that hemorrhages cause phthisis is ill-founded. A hemorrhage or any other lesion of the lungs may, of course, add to the liability to infection; but, as a rule, the cases in question are instances of hemorrhage occurring before the other evidences of the pulmonary disease have become marked. Occasionally hemoptysis is due to congestion of the lungs, to erosion of small blood-vessels from gangrene, abscess, or the like, or to vicarious menstruation.

Hemorrhagic infarcts may occur in the lungs, as in other places, from obstruction of the arteries by emboli. The latter

come from the right heart or from the general venous system, and lodge in the smaller branches of the pulmonary artery, frequently at their points of subdivision. Very often, however, emboli are not found, or, if so, are so small as to have been unable to cause obstruction without the associated thrombosis, or there may be purely thrombotic occlusion. Valvular lesions and muscular weakness of the heart aid greatly in the production of infarctions by causing a sluggish circulation in the pulmonary vessels, and thus encouraging thrombosis. Infarctions are occasionally due to thrombosis of the pulmonary veins without obstruction of the arteries; more rarely they are caused by occlusion of one of the bronchial tubes. The latter condition leads to collapse (*atelectasis*) of the part of the lung associated with that tube, to consequent congestion (see Atelectasis), and, sometimes, when the congestion is severe, to hemorrhage. In addition, it is to be remembered that hemorrhages into the lungs are likely to have the shape and appearances of ordinary infarcts, because they occupy the area supplied by the bronchus into which the blood finds its way. Infarctions are most frequently found in the lower lobes and in the right lung; they

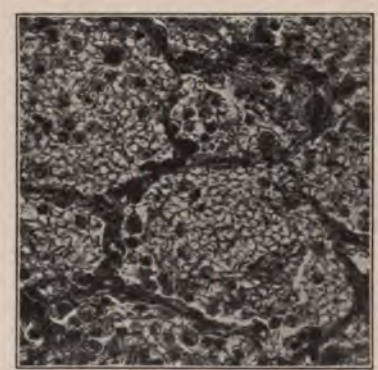

FIG. 201.—Hemorrhagic infarction of the lung (from a photograph by Dr. Wm. M. Gray).

are usually multiple. They have the characteristic wedge-shape, the base of the wedge directed toward the pleural surface. They are hard, airless, dark-colored, and project above the other parts on section and on the pleural surface. Microscopically there is seen a uniform hemorrhagic infiltration of the tissues (Fig. 201), and not infrequently hyaline thrombosis of the smaller blood-vessels. Toward the apex of the infarct there is more fibrin in the blood-vessels, and the main vessel may be found obstructed by an embolus or thrombus. Small infarcts may be wholly removed through the vascular and lymphatic channels after liquefaction and granular degeneration of the blood-clot. More commonly a pigmented scar is left. Softening and cyst-formation may occur, or in cases

in which the original embolus was infected by micro-organisms, or in which the infarct becomes infected through the bronchial tubes, abscess or gangrene may result.

Embolism without infarction is not infrequent in the lungs. An interesting form is fat-embolism, resulting from fracture of a bone with disorganization of the marrow, and less frequently from traumatic disturbances of other fat-tissues. When large branches of the pulmonary artery are occluded in this way, or when numerous vessels are obstructed, sudden death may result. In other cases there are merely great dyspnea and oppression. Air-embolism, embolism of hydatid cysts, and embolism of portions of tumors are rare. Attention has been called to the embolism of placental cells in certain cases of eclampsia.

HYPERTROPHY AND ATROPHY.

Hypertrophy.—True hypertrophy, in the sense of increase of all the constituents of the lung-tissue, is extremely rare, and probably only occurs when areas of the pulmonary tissue have been rendered useless early in infancy or in fetal life. Cases have been observed, however, in which a single lung occupied the entire side of the thorax to which it belonged, and also a part of the other side, where complete atrophy of the other lung had existed. It may be that limited areas of hypertrophy occur more frequently than we at present believe, but evidence is wanting.

Partial Hypertrophy.—The muscular tissue of the intervesicular septa and of the smaller bronchioles not infrequently undergoes proliferation or hyperplasia when there has been obstruction in the air-passages, so that greater expiratory force was required. Similarly the elastic tissues may become increased; but these are not instances of true hypertrophy.

Atrophy.—Aside from that which occurs as a part of emphysema, atrophy does not take place.

EMPHYSEMA.

By this term is indicated an increase of the air contained within the lungs, either in the normal tubes and alveoli, or in the interstitial connective tissue. Two varieties of emphysema may be distinguished by their essentially different nature. These are the *interstitial* and the *vesicular*.

Interstitial emphysema of the lungs is similar to the emphysema of the subcutaneous tissues—*i. e.*, the term refers to the existence of air within the fibrous tissue of the lung. This occurs in the course of affections in which there is some obstruction to the expiration, combined with severe coughing or forcible expiratory efforts, leading to rupture of the intervesicular septa and extravasation of air. Degenerative or inflammatory weakness of any part

of the pulmonary structure would, of course, act as a primary cause. Interstitial emphysema is most commonly observed in such diseases as whooping-cough and membranous croup; it may also result simply from straining efforts, as in women during labor, or from forcibly blowing wind-instruments, etc. The air from the ruptured air-vesicle finds its way into the interalveolar and intervesicular septa, and, passing along these, eventually reaches the subpleural connective tissue, where it is seen in the form of small blebs, movable from place to place. The process may extend to the roots of the lungs and even to the mediastinal tissues, or to the subcutaneous tissues of the neck. When an air-vesicle near the pleural surface ruptures pneumothorax may result.

Vesicular emphysema is the term used to designate overdistention of the alveoli and air-sacs of the lung. Two factors play a part in the causation of this condition: first, increase of the pressure under which the air exists in the lung; and, secondly, degenerative or inflammatory weakness, with loss of elasticity of the lung-structure itself. There are several varieties, and the causes vary somewhat in each.

(*a*) **Acute vesicular emphysema** results simply from excessive air-pressure within the alveoli, and may be more or less widespread. It occurs in cases in which inflammatory swelling or mucous secretions within the bronchi obstruct the expiration of air, but are not sufficient to impede the more vigorous inspiratory force. There results overdistention of the alveoli and air-vesicles. Somewhat similar conditions are present when the entrance of air into certain parts is impeded by obstruction or disease of the bronchi or by consolidations of the pulmonary tissue. Localized emphysema of other parts results (Fig. 203); the term *vicarious emphysema* is applied to such cases. This is not unusual in the lobules of the lung surrounding areas of pneumonic or tuberculous consolidation, and may affect an entire lobe or lung when the entrance of air into the other lobes or the other lung is prevented.

Pathologic Anatomy.—In these cases of acute and vicarious emphysema there is simply overdistention of the alveoli, and the tissue presents a paler color than normal and a cotton-like sensation when grasped in the fingers. Microscopically nothing beyond overstretching of the septa and some anemia of the vessels is apparent. If the causes continue to operate, changes similar to those found in chronic vesicular emphysema ensue.

(*b*) **Chronic vesicular emphysema** is the ordinary form of emphysema, and is sometimes spoken of as *substantial emphysema*.

Etiology.—Chronic vesicular emphysema commonly occurs in elderly persons, and is predisposed to by attacks of bronchopneumonia and by the existence of other inflammatory and congestive conditions of the lungs. These conditions lead to weakness and loss of elasticity of the pulmonary tissue. Heredity

plays a part in the same direction, and it is supposed by some that there is an abnormal lack of development of the elastic tissue in the lungs of such persons, rendering them more susceptible to this disease. The direct exciting cause of emphysema is increase of the air-pressure within the alveoli, and much speculation has been indulged in to discover whether inspiration or expiration plays the more important part in increasing the pressure. It seems likely that the expiratory force is the more important one, as in the case of constant coughing in chronic bronchitis, the blowing of wind-instruments, and the constant straining in certain pelvic disorders, all of which may lead to emphysema.

Pathologic Anatomy.—The lung increases in size, and very often remains distended when the thorax is opened post-mortem. The edges are rounded; the organ is light in color, and has a cotton-

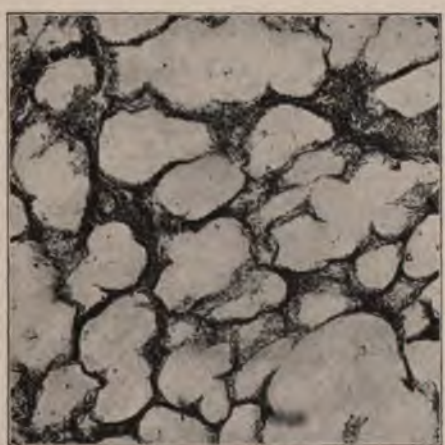

FIG. 202.—Emphysema of the lungs (Karg and Schmorl).

like feeling when squeezed between the fingers. On section into it the alveoli may be seen to be distended, and there may be cavities of quite considerable size, often as large as a pea, and sometimes even that of a cherry or plum (Fig. 202). Large spaces of this kind are not unusual near the pleural surface; the term *bullous emphysema* has been used in reference to such cases. The pigment-matter of the lung is very much lessened, and may be distributed in radiating or parallel lines. This lessening of the pigment is not alone due to its distribution over a greater space, but there is also actual disappearance by removal through the lymphatic channels and through expectoration.

Chronic emphysema may be a general process affecting all parts of both lungs, or it may be localized. In the latter case it is the apex and anterior edges that are most commonly involved,

but spots of emphysema may be seen here and there in other parts of the lung, interspersed with normal tissue. The involvement of the apex and anterior portions is due to the fact that the expiratory force is more apt to distend these portions of the lung than the lateral and basal portions, which receive the uniform support of the sides of the chest and the diaphragm as they contract against the lung.

Microscopically emphysema is found to consist in enlargement of the vesicles and alveoli by distention and by atrophy and disappearance of the intervesicular and interalveolar septa. Studied from the earliest stage, there will be found, first, overdistention of the air-sacs, then a gradual thinning, and finally vacuolization of the intervesicular septa at their thinnest parts. Coincidentally the small capillaries are compressed, and are finally converted into hyaline cords. The anemia consequent upon this determines additional atrophy and degeneration of the septa and fatty degeneration of the loosened epithelium, so that eventually the whole of the septum disappears. Later, adjacent alveoli intercommunicate and large spaces are thus formed.

The obstruction to the pulmonary circulation due to the obliteration of the capillaries leads to collateral hyperemia of the larger branches supplying the bronchi, and thus prolongs the chronic bronchitis, which in the first instance may have been the cause of the emphysema. Subsequently collateral anastomosis between the pulmonary arteries and the bronchial system of blood-vessels is established.

Associated Conditions in Other Organs.—The shape of the thorax in emphysema is characteristic. The chest is in a constant state of extreme inspiration, the clavicles elevated, the sternum protruded, the back arched. It has a shape well likened to that of a barrel. The diaphragm is usually depressed, and the liver is below its normal position; the heart is almost or completely covered over in front and usually pressed somewhat backward from the chest-wall.

Pathologic Physiology.—The effect of emphysema upon the circulation is important. The obstruction of the pulmonary capillaries leads to increase of pulmonary pressure, and eventually hypertrophy of the right heart; later, dilatation of the right ventricle ensues, and characteristic cardiac dropsy with general cyanosis may result.

(*c*) **Senile emphysema** is due to erosion of the intervesicular septa, the result of the atrophic processes to which old age predisposes. There is not necessarily any element of increased air-pressure in the causation of this form of emphysema, and the volume of the lung may not be notably increased, though the tissue is lighter and the air-spaces are found to be increased. The lung is light in color and often collapses readily.

ATELECTASIS.

The term atelectasis is applied to two distinct conditions, one occurring as a congenital affection, in which the lung has never been properly expanded by air; the other occurring in after-life, in which the lung is compressed or collapsed, so that the alveoli and air-vesicles are rendered airless.

Congenital atelectasis is found in new-born babes in whom the inspiratory power has been so deficient, as the result of general weakness or compression of the thorax, or of compression of the brain by cerebral hemorrhage, that the lungs, or parts of them, have never been expanded. It may also take place in a purely mechanical way by obstruction to the air-passages by meconium or other foreign matter.

Pathologic Anatomy.—Congenital atelectasis commonly affects the bases and posterior portions of the lung. The area of disease is of a dark-reddish color; it is rather tough, and on section presents a smooth appearance; pressure gives no sign of crepitation. If a portion be thrown into water, it sinks. Usually a considerable part of the lung is involved, but sometimes merely lobular areas are affected. By inserting a blowpipe into the bronchi the lung may be inflated, and resumes its normal appearance, provided the condition has not persisted for any length of time. If the child does not perish, secondary changes take place. The epithelium of the alveoli degenerates, more or less proliferation of the connective tissues of the septa occurs, and the pleura over the diseased area is prone to become thickened. The atelectatic portion of the lung in such cases remains collapsed; it is smooth on section, free of pigment, and can no longer be inflated. Secondary dilatation of the bronchioles and bronchi may ensue.

It is of interest, in a medicolegal sense, to recognize that atelectasis resembling the congenital form may be met with in the bodies of infants that have lived, breathed, and even cried lustily. The explanation of this is that the collapse ensued some time after birth, and that as the lung had practically still its fetal characteristics, the resulting atelectasis is the exact counterpart of the congenital form.

Atelectasis in later life occurs under a variety of conditions. It may simply be the result of compression of the lung by pleural effusions, by deformities of the chest, by tumors, aneurysms, and the like. It may also be met with in cases in which the bronchial tubes have become obstructed. The larger bronchi may be occluded by the pressure of tumors or aneurysms, or by foreign bodies, and the resulting atelectasis is of considerable extent; the smaller bronchi and bronchioles are frequently obstructed by intense catarrhal thickening of their mucosa, and in consequence lobular areas of atelectasis are developed. The latter

is especially frequent as one of the pathologic features of bronchopneumonia (*q. v.*).

The explanation of atelectasis as the result of bronchial obstruction has occasioned much discussion, and several theories have been proposed. In some cases it is not unlikely that mucous secretions within the bronchi may prevent inspiratory entrance of air into the lungs without opposing any obstacle to expiration, so that collapse is gradually developed. In other cases it is likely that both inspiration and expiration are prevented, while the air contained within the air-vesicles is gradually absorbed. It is claimed that first the oxygen, later the carbonic acid, and finally the nitrogen, are absorbed; the collapse of the alveoli then becomes complete. It is possible, also, that atelectasis may be developed as the result of the failure of respiratory motions on one side, or affecting a certain part of the lung. As a result of this, the elasticity of the pulmonary tissue would gradually press the air out of the affected area, while new air was not supplied by inspiration. Such a condition, however, must be rare.

FIG. 203.—Atelectasis due to bronchial obstruction: acute emphysema of the unaffected portions of the lung (Orth).

Pathologic Anatomy.—The part affected by atelectasis is dark in color, and is much reduced in size, so that when lobular areas are affected the pleural surface may be considerably depressed (Fig. 203). On section the surface is smooth and generally dry, though in some instances passive hyperemia, which is generally present to some extent, reaches such a grade that bloody liquid flows freely from the surface of section. The term *splenization* is properly applied to such cases, whereas the instances in which the surface is dry are often spoken of as *carnification*. The lung does not crepitate, and sinks when placed in water. In the earlier stages the diseased portion may be inflated through the bronchial tubes; but when the condition has persisted, connective-tissue overgrowth springing from the septa causes permanent induration and permanent collapse. The lung in such cases is hard and of a dark color, due to the deposit of hematogenous pigment, the result of disintegration of the blood present. The bronchi may be compressed, but sometimes atelectatic bronchiectasis results.

INFLAMMATION, OR PNEUMONIA.

Classification.—Inflammation of the lungs, pneumonia, or pneumonitis, may arise in a variety of ways, and present itself in a number of widely varying forms, both as to the distribution and the nature of the pathologic changes in the pulmonary structure. In all cases some irritant is conveyed to the lung either (*a*) from the upper air-passages or external world through the bronchi; (*b*) from some other part of the body through the blood (hematogenic pneumonia); or (*c*) from the pleura by direct extension or through the lymph-channels (pleurogenic pneumonia).

Anatomically pneumonia is classified according to the nature of the inflammatory products, and there are thus distinguished: *fibrinous pneumonia*, in which the air-vesicles and terminal bronchioles contain an exudate especially rich in fibrin; *catarrhal*, or *bronchopneumonia*, in which the exudate is composed of an albuminous liquid containing numerous epithelial cells and blood-corpuscles; *purulent pneumonia*, in which pus-cells are the noteworthy element in the exudate; *cheesy pneumonia*, in which cellular desquamation and cheesy necrosis are prominent; and *productive*, or *fibrous pneumonia*, in which there is overgrowth of fibrous connective tissue. It is to be remembered, however, that mixed cases are of frequent occurrence. Thus in many instances localized areas of decided fibrinous pneumonia are found in the midst of larger areas of catarrhal pneumonia; some distinctly purulent exudation may be met with in many instances of fibrinous or catarrhal pneumonia; and more or less productive inflammation and fibrous overgrowth may be seen in any of the other varieties. Typical cases, however, present little mixture of the lesions.

The terms parenchymatous and interstitial pneumonia are sometimes employed, but are of doubtful significance. The proper parenchyma of the lungs, the alveolar septa, and their contained blood-vessels, are never the sole seat of inflammation, and the term parenchymatous pneumonia, as usually applied to inflammations of the lining epithelium of the air-vesicles, is therefore misused. It is more proper to call the fibrous variety interstitial pneumonia.

Fibrinous Pneumonia.

Definition.—Fibrinous, or croupous, or lobar pneumonia is an acute infectious form of pneumonia, generally caused by the Diplococcus pneumoniæ, and usually involving an entire lobe or more of one or both lungs. Pathologically it is characterized by an exudation within the air-vesicles and terminal bronchioles, mainly composed of fibrin; and clinically the disease is marked by a definite and characteristic course.

Etiology.—The important factor in the causation of fibrinous

pneumonia is the Diplococcus pneumoniæ (Fränkel-Weichselbaum). This micro-organism is found in the sputa and in the lungs of the great majority of cases, and is undoubtedly the cause of the pneumonia; but occasionally other micro-organisms seem to occasion typical fibrinous pneumonia. Among these are the pneumococcus of Friedländer, streptococci, staphylococci, the bacillus of typhoid fever, the bacillus of influenza, and the Bacillus coli communis. In some cases in which bacteria other than the diplococcus are supposed to be the cause, there is doubtless mixed infection; but it must be accepted at the present time that a number of micro-organisms are capable of causing the disease. The fibrinous pneumonia which occurs in the course of tuberculosis is certainly due to secondary infection, and the same thing frequently happens in the course of typhoid fever and influenza, though the specific bacilli of these diseases may alone cause pneumonia.

The micro-organisms usually gain access to the lungs through the bronchi. In the case of the Diplococcus pneumoniæ the frequent occurrence of this organism in the mouth and upper respiratory passages furnishes a ready explanation of one source of infection. More rarely the bacteria may be directly inspired from without, or, exceptionally, they may reach the lungs through the circulation.

There are certain predisposing factors which have long been recognized clinically as causes of pneumonia. These probably act by rendering the pulmonary tissues less resisting, or by increasing the virulence of the diplococci of the mouth. Among these causes are exposure to cold, injury of the lungs by traumatism, fatigue, and systemic depression.

(For the description of the Diplococcus, see page 207.)

Pathologic Anatomy.—The lesions most frequently involve the lower lobe of the right lung; next in order is the lower lobe of the left lung; the apices alone are least frequently involved. In all cases there is a tendency to the involvement of a whole lobe, and, as a rule, the entire area of disease is affected uniformly and simultaneously. There are wide variations, however; for, on the one hand, typical fibrinous pneumonia may occasionally appear as a more or less lobular disease (particularly in influenza), and, on the other hand, the process may spread from one part of the lung to another (*pneumonia migrans*). In typical cases, not only is the process uniformly distributed, but it passes through distinct stages: first, of congestion, then of consolidation, and finally of resolution.

Stage of Congestion or Engorgement.—The affected area is dark-red in color; it is swollen and heavy, and on pressure crepitates less than a healthy lung. The pleura over the diseased part is dull and lusterless. On section through the lung bloody liquid exudes, and when the part is compressed with the fingers this

liquid shows few air-bubbles. The condition is simply one of intense congestion, with exudation into the alveoli and terminal bronchioles of serous liquid and blood-corpuscles (see Fig. 199). Microscopically the small blood-vessels of the septa are seen to be greatly distended and project inward toward the alveoli. Within the latter may be found many red corpuscles, a lesser number of leukocytes, and some detached epithelial cells.

Stage of Consolidation, or Hepatization.—The diseased lung is

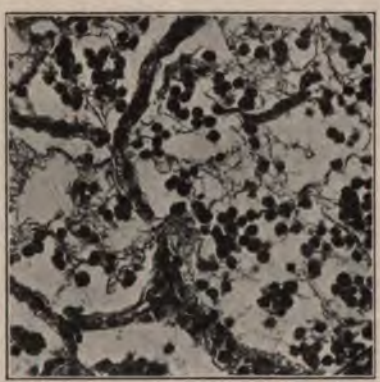

FIG. 204.—Red hepatization of the lung (from a photograph by Dr. Wm. M. Gray).

now completely solid and liver-like in consistency (hepatization). It is swollen, and marked on the surface by indentations of the

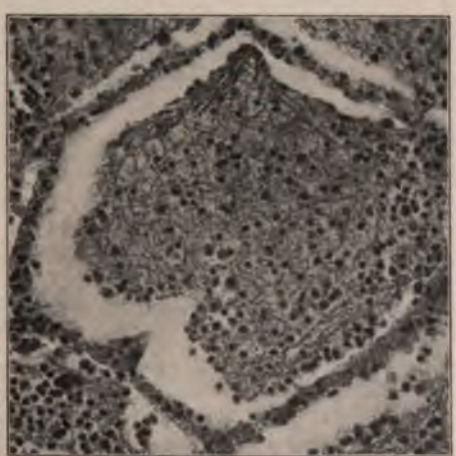

FIG. 205.—Croupous pneumonia: beginning gray hepatization (Karg and Schmorl).

ribs. The surface of section is at first red in color (red hepatization, Plate 4), but later becomes white or gray, or in elderly

persons (in whom the lungs are usually darkly pigmented from inhalation of dust) of a variegated appearance, resembling granite (gray hepatization, Plate 5). The cut surface is entirely dry, and is finely granular on account of the projection of small plugs of fibrin from the alveoli and bronchioles. The pleura is generally covered with fibrinous exudation. Microscopically the alveoli are found distended with a network or particles of fibrin, in which the same cellular constituents as occur in the stage of congestion are embedded. The fibrinous network is beautifully demonstrated by staining the sections after the method of Weigert (Fig. 204). The blood-vessels are less prominent than

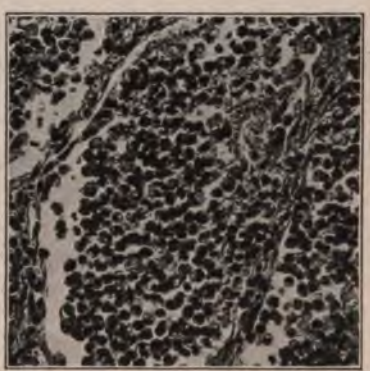

FIG. 206.—Advanced gray hepatization (from a photograph by Dr. Wm. M. Gray).

in the first stage. As the disease advances to the period of gray hepatization the number of leukocytes within the exudate increases and the blood-vessels become still less prominent (Figs. 205 and 206).

Stage of Resolution.—Gradually softening of the exudate occurs and the lung becomes more moist. Puriform liquid may be squeezed from the surface of section, or may be seen in the bronchioles and bronchi. Crepitation is re-established. Microscopically fatty degeneration of the cells of the exudate is apparent. Softening is further contributed to by simple liquefaction. The result of these processes is emulsification of the exudate, which is finally carried off by the lymphatics or expectorated.

Before the process of resolution is completed the epithelial cells of the alveoli and bronchioles proliferate, so as to repair the diseased portions. At the same time proliferative changes may be seen in the tissues of the septa. These conditions exist throughout the disease to a slight extent, but become more apparent in the stage of resolution. Eventually the lung is restored to its previous condition.

Unusual Characters.—In some cases the pathologic changes

PLATE 4.

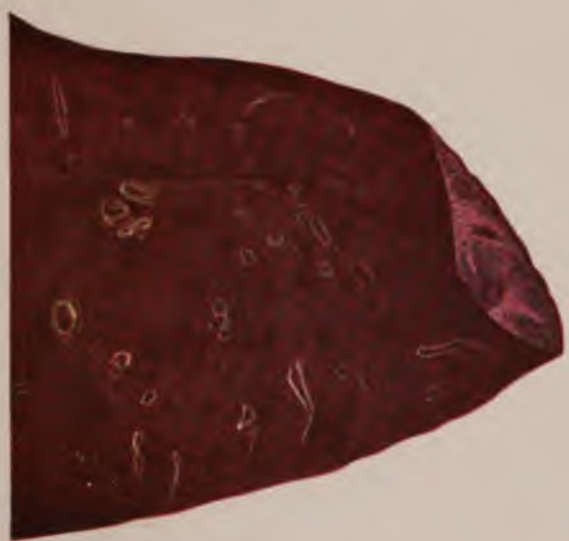

Croupous pneumonia, stage of red hepatization (Bollinger).

PLATE 5.

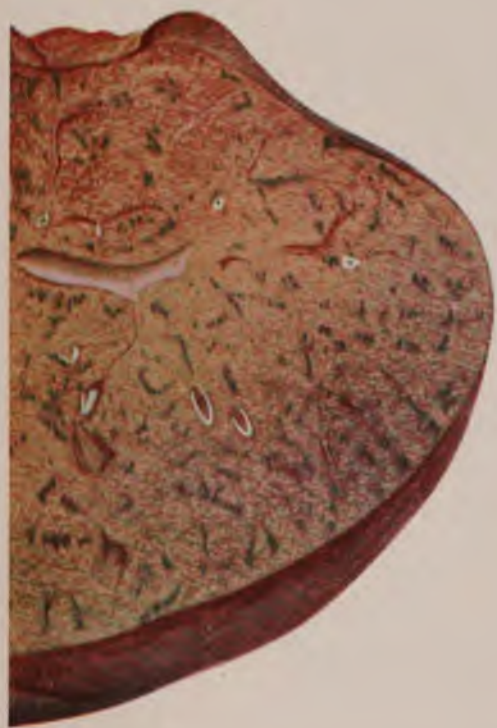

Croupous pneumonia, stage of gray hepatization (Bollinger).

vary somewhat from the typical form described. Not rarely there are considerable congestion and even edema of the lung throughout the disease; in drunkards or cachectic individuals the exudate is more markedly hemorrhagic than is usually the case; and sometimes, particularly in instances accompanied by streptococcous infection, the exudate is more cellular than customary. In still other cases proliferative changes in the septa are prominent.

Associated Lesions and Pathologic Physiology.—The portions of the lung not involved by the pneumonic process are usually somewhat emphysematous and congested; and edema may develop. The latter is, however, not so common as has often been assumed. The larger bronchial tubes, as a rule, remain normal, or at most become congested. The finer bronchi are more frequently hyperemic, and excess of mucus coats the surface. In practically every case there is a certain degree of fibrinous pleurisy, either on the external surface of the pleura or between the lobes. Extensive pleurisy is rare and serous exudation is uncommon. The pleurisy is directly attributable to the micro-organism which has caused the underlying pneumonia.

Though fibrinous pneumonia is frequently an entirely local infection, systemic intoxication is usually present, and general infection may further aid to develop widespread pathologic changes. Leukocytosis is present in the great majority of cases; its absence is generally significant of unusually intense systemic intoxication. White clots are often detected in fatal cases in the chambers of the heart and in the large blood-vessels leaving the heart. Cardiac and respiratory embarrassment, often ascribed to mechanical causes, such as heart-clot or extensive consolidation, is probably in many cases due to the action upon the nervous system of the toxins of the disease. Myocardial degenerations aid in producing circulatory weakness. The heart-muscle and the kidneys may suffer parenchymatous degeneration, as in other febrile infections, and acute exudative inflammation (myocarditis, nephritis) may occur in either of these organs. Albuminuria is not infrequent, and albumoses may be found in the urine, especially during the stage of resolution. The chlorids of the urine are usually diminished. The spleen is enlarged and soft.

Pericarditis is frequent, and endocarditis, either of the simple or of the malignant type, is more common than in any other acute infection, excepting rheumatism. Meningitis is occasionally noted.

Fibrinous or pseudomembranous bronchitis, laryngitis, gastritis, colitis, and cystitis are sometimes met with. Inflammations of the joints and abscesses in various organs may occur.

Unusual Terminations.—Secondary infection with pyogenic micro-organisms may lead to termination in abscess; or this result may be due to the fact that the pneumonia was primarily caused by such micro-organisms. The affected area may suffer gangrene

even more commonly than suppuration. Gangrene is especially prone to occur when the exudation is distinctly hemorrhagic and in cases in which the circulation is specially weak. Finally resolution may be delayed and productive changes may occur in the

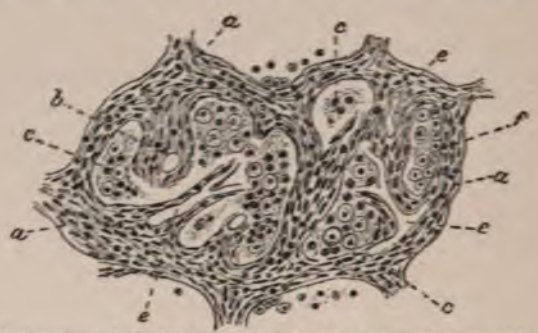

FIG. 207.—Induration of the lung (carnification) in a case of pneumonia of five weeks' duration: *a*, new connective tissue of the septa; *b*, intra-alveolar proliferation of connective tissue; *c*, desquamated epithelium in the alveoli; *e*, new blood-vessels; *f*, lining epithelium of the alveoli (Kaufmann).

septa and even within the alveoli. There results a solidification (carnification) of the lungs, or, as it is termed, *fibrous pneumonia* (Fig. 207).

Catarrhal Bronchopneumonia.

Definition.—Catarrhal bronchopneumonia, or lobular pneumonia, is an acute inflammatory affection of the pulmonary tissue, occurring in localized areas and consequent upon inflammation of the terminal bronchioles. In most, if not all, cases some species of bacterium is the immediate cause. Pathologically it is characterized by inflammation of the terminal bronchioles and by exudation into the alveoli of albuminous liquid containing desquamated epithelial cells, together with more or less red blood-corpuscles and leukocytes; clinically the disease is marked by an indefinite and irregular course.

Etiology.—Catarrhal pneumonia may be produced experimentally in animals by causing them to inhale steam or various irritating vapors. Still more characteristic lesions are produced when the vapors inhaled hold decomposing organic matter in suspension. The same result is accomplished by cutting the vagus nerves, as a consequence of which the vocal bands and esophagus are paralyzed and irritating secretions and particles of food are conveyed into the lung by inspiration. In man tumors, enlargements of the thyroid gland, or inflammatory exudation, may compress the vagi and lead to forms of pneumonia similar to the experimental pneumonia of dogs. Somewhat analogously,

in the late stages of various diseases particles of food and mucous secretions may sink to the dependent parts of the lungs, or may be drawn in by the inspiratory air and set up catarrhal pneumonia in the parts already predisposed to inflammation by hypostatic congestion (*hypostatic pneumonia*). Of the same etiologic sort are the catarrhal pneumonias which occur in diphtheria, epithelioma of the larynx, and inflammatory conditions of the mouth and pharynx, in which irritating particles are carried to the finer bronchi by inspiration (*aspiration-pneumonia; deglutition-pneumonia*). Catarrhal pneumonia of this kind is not infrequent in the new-born as a result of vigorous inspiratory efforts made while the head is descending through the vagina.

Most frequent, however, of all forms of catarrhal bronchopneumonia is that which occurs in the course of measles, whooping-cough, influenza, or other infectious fevers attended with bronchitis. The manner of involvement of the alveolar structures will presently be described; for the present it may be said that the inflammatory process extends from the bronchi by continuity and contiguity, or by aspiration of irritating bronchial secretions.

The immediate cause of catarrhal pneumonia is, in the majority of cases, some bacterium. The most frequent is the Diplococcus pneumoniæ, which occurs in over 50 per cent. of all cases, either alone or in combination with the Streptococcus pyogenes, staphylococci, the pneumococcus of Friedländer, the bacillus of influenza or of typhoid fever, or the Bacillus coli communis. Any of the other forms named, and especially the pyogenic micrococci, may cause catarrhal pneumonia without the diplococcus of Fränkel; but in the case of fevers (typhoid fever, influenza) in which the specific micro-organisms are found, there is usually mixed infection with the Diplococcus pneumoniæ.

Pathologic Anatomy.—The lesions vary somewhat in different cases, and we may distinguish three important types, the simple, or ordinary catarrhal bronchopneumonia, the hypostatic form, and aspiration-pneumonia.

1. **Simple Catarrhal Bronchopneumonia.**—The lung in such cases presents more or less distinct external appearances. On the pleural surface may be seen lobular areas of dark- or light-red or grayish color, which are somewhat elevated and harder than the normal lung. Surrounding these the pulmonary tissue is emphysematous, while here and there may be seen dark-red or lead-colored and somewhat depressed areas of pulmonary collapse (atelectasis). The lung as a whole is crepitant, while the pneumonic and atelectatic areas are consolidated and airless, and sink in water. On section through the lungs the same general appearances are visible, though the consolidated patches are most abundant near the surface. Both lungs are, as a rule, involved, and any portion is liable to the disease. The smaller and medium-sized bronchi and

the bronchioles contain mucopurulent secretion, which may be squeezed out; the areas of pneumonic consolidation are smooth and moist on the surface of section, or exceptionally somewhat granular as a result of admixture of some fibrinous pneumonia. Occasionally there may be puriform liquid or small purulent collections around the bronchiole in the center of the lobule. The area of collapse (atelectasis) is dark-red, as a rule, and on pressure bloody liquid exudes.

In the very earliest stages of the disease the lobules of consolidation and collapse may be inflated by inserting a tube into the bronchus supplying the part and by blowing gently into it. Later this is not possible, as the consolidation increases. At the same time it is noted that the consolidated areas become lighter in color, until at last they are grayish-yellow; while the areas of collapse become pneumonic and present a similar change of color.

Microscopically the terminal bronchioles and alveolar passages present somewhat swollen walls and contain variable amounts of mucous exudate containing desquamated cells. In the areas

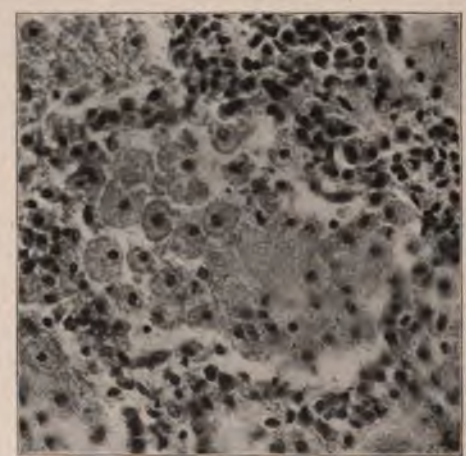

FIG. 208.—Catarrhal pneumonia (Karg and Schmorl).

of consolidation the alveoli and the air-sacs are filled with liquid and variable numbers of epithelial cells, red corpuscles, and leukocytes (Fig. 208). The liquid is albuminous in nature, as may be readily demonstrated by boiling a portion of the tissue. The epithelial cells are desquamated from the lining membrane either singly or in groups, and there is evidence that active proliferation is taking place as well. In most cases the number of red corpuscles and leukocytes is small, but in some instances, particularly in cases in which streptococci and staphylococci are operative, the exudation may be quite hemorrhagic, or later purulent. The alve-

olar septa regularly present considerable round-cell infiltration, and the blood-vessels are surrounded by emigrated leukocytes. The blood-vessels in the septa are distended and tortuous.

The atelectatic areas present even greater congestion of the blood-vessels, and the alveolar cavities are obliterated by the collapse of the walls, or contain at most a little hemorrhagic exudate. The epithelial cells tend to lose their characteristic shape and become cuboidal.

As resolution advances, the cellular exudate becomes lighter in color as a result of fatty degeneration, and eventually it is absorbed or expectorated. Coincidently the round-cell infiltration disappears from the septa, and the pulmonary tissue returns to the normal, excepting that the epithelial cells of the alveoli tend to remain more or less cuboidal for a time.

Pathogenesis.—The manner of development of the lesions is of considerable interest. In the ordinary catarrhal bronchopneumonia now under discussion there is always a primary bronchitis of the terminal bronchioles, a *bronchiolitis*, or *capillary bronchitis*, as it is termed. This may be spread to the alveolar structure in several ways. In most instances, no doubt, the inflammation travels downward along the bronchioles to their termination by continuity, or outward through their walls to the surrounding alveoli by contiguity. In either case there results a patch of catarrhal pneumonia surrounding a terminal bronchiole. Less commonly the affected lobule first becomes atelectatic and then pneumonic. The atelectasis results from the obstruction of the bronchioles by mucus or by their swollen walls, and is due to the gradual absorption of the air contained within the alveoli and the inability of more to enter (see Atelectasis). Subsequently the collapsed area becomes inflamed by the entrance of micro-organisms from the bronchioles or by extension of surrounding inflammation.

Unusual Characters.—Marked variations are seen in the nature of the process and in its distribution. In some instances there is but little pneumonic consolidation, while the bronchiolitis, or capillary bronchitis, is a striking feature. In other cases the exudate is decidedly hemorrhagic or purulent, and it may in certain areas be quite fibrinous. Regarding the distribution, the most striking variation is the tendency in some cases to lobar involvement by confluence of the lobular areas (*pseudolobar form*).

Associated Lesions.—The constant association of bronchitis has been sufficiently noted. Pleurisy is less common than in fibrinous pneumonia, but the patches near the surface are regularly covered with fresh pleural exudation. It has long been recognized that purulent pleurisy is more apt to occur after pneumonia in children than in adults, and in many of these cases the antecedent pneumonia is catarrhal. Widespread toxic and infective lesions may occur, as in fibrinous pneumonia.

Unusual Terminations.—In cases in which micro-organisms, more virulent than usual, cause the pneumonia, suppuration and gangrene may result. Fetid and pultaceous foci, or purulent collections surrounded by considerable areas of congestion and inflammatory edema, result. In other instances the process of resolution is slow, and fibroid overgrowth of the septa and proliferation of connective tissue within the alveoli ensue, with the production of more or less extensive sclerotic hardening and contraction of the lung-structure. Within such areas the alveolar exudate may lie for a long time as a fatty mass; but this is very unusual; and true caseation, of which so much was formerly said, does not occur. The instances in which this was supposed to have occurred were cases of subsequent infection with tubercle-bacilli, or cases of tuberculous pneumonia *ab initio.*

2. **Hypostatic Pneumonia.**—The bases and posterior portions of the lungs are commonly involved in these cases. The process occurs as a terminal affection in many diseases. It begins as an intense hypostatic congestion and hemorrhagic edema of the dependent parts of the lungs. Subsequently the irritants which make their way to the congested area through the bronchi set up a form of inflammation of the terminal bronchioles and air-vesicles which is largely catarrhal, but more fibrinous than ordinary bronchopneumonia. The inflammatory process is also more diffuse, and is at the most insignificant compared with the antecedent and associated congestion and edema.

3. **Aspiration-pneumonia.**—Of the dust which we constantly inhale, the greatest part is arrested in the upper air-passages or in the larger bronchi, and is expectorated. A part, however, reaches the finer bronchi and bronchioles, and sets up a certain amount of local irritation and congestion, with desquamation of epithelial cells and emigration of leukocytes. Ordinarily these processes are exceedingly trivial and can rarely be demonstrated. In persons, however, whose occupations (*e. g.*, steel-grinding, coal-mining, marble-cutting, etc.) subject them to excessive dust-inhalation the pulmonary changes are extensive and severe. This is one form of aspiration-bronchopneumonia, but the irritation rarely stops at the point of catarrhal inflammation; on the contrary, the irritant particles penetrate the walls of the bronchioles and are distributed by the lymphatics, causing fibroid changes of greater or less extent. The pneumonia thus produced is therefore more properly considered as a form of fibrous pneumonia (*q. v.*).

In the course of various affections of the pharynx, larynx, trachea, and bronchi, as well as in cases in which through palsy of the larynx, or through general depression, particles of food or secretions of the mouth enter the air-passages, irritating matters may be inspired or "aspirated" into the finer divisions of the bronchial system. There results intense local irritation, with

catarrhal inflammation and consolidation. The exudate is largely epithelial, but more often serous, hemorrhagic, or purulent than in simple catarrhal pneumonia. The condition may be circumscribed to small patches, but if large particles are aspirated and the larger bronchial tubes are obstructed, widespread consolidation, of the character described, results. The inflammatory process in these cases of aspiration-pneumonia are habitually intense, and often terminate in suppuration or necrosis, with considerable surrounding hyperemia and edema.

Cheesy or Tuberculous Pneumonia.

Definition.—Cheesy or tuberculous pneumonia is an acute or subacute form of pneumonia caused by the tubercle-bacillus, and involving lobular areas or, by confluence of such, an entire lobe or lung. Pathologically it is characterized by proliferation and desquamation of epithelial cells, infiltration of the alveolar septa, and finally by cheesy necrosis of the area of disease. Clinically the disease presents itself as a more or less acute pneumonic tuberculosis. Caseous pneumonia is frequently associated with miliary or peribronchial tubercles, affecting the alveoli adjacent to the tubercles.

Etiology.—Cheesy pneumonia as an independent condition is more common in children than in adults. The immediate cause is the tubercle-bacillus. Infection occurs by rupture of a tuberculous gland or cavity into one of the bronchi and dissemination of the infective material throughout the lung. Likewise, bacilli may be inhaled from outside, or from tuberculous foci in the bronchi, larynx, or nose. In cases of disseminated tuberculosis of the lungs areas of caseous pneumonia are habitually encountered in the pulmonary structure between the tubercles. Finally, infection may take place through the blood, but the occurrence of caseous pneumonia rather than miliary tuberculosis in such cases is assuredly rare.

Mixed infection with Diplococci pneumoniæ is not infrequent, but it is not, as some investigators have maintained, essential to the disease.

Pathologic Anatomy.—In its most typical form caseous pneumonia is a lobular process beginning around the terminal ends of the bronchioles, where the infective material lodges. The lung presents on section areas of consolidation not unlike those seen in catarrhal bronchopneumonia. At first these are congested and red in color, but very soon degenerative changes cause a grayish or yellowish color. The surface of section is usually smooth, but often somewhat granular from associated fibrinous exudation. When abundant infection has occurred the areas may be thickly set, and a lobar form is thus established (Plate 6); or

there may be a gradual involvement of new areas, receiving their infection from those first formed, with a similar, but less uniform, lobar pneumonia as the result.

Caseous pneumonia shows no tendency to resolution, but, on the contrary, tends to progressive cheesy degeneration, and at last to the formation of cavities. The entire lung may be riddled with small excavations, presenting ragged, cheesy walls. Usually the cavities are small, even though there be few; exceptionally, large ones are seen. Though resolution does not occur, limited areas may be healed by reactive fibrous overgrowth springing from the alveolar septa and encapsulating the diseased area, or penetrating it, and transforming the whole into a fibrous mass.

Microscopically the exudation has many of the characters seen in catarrhal bronchopneumonia. Essentially the exudate is cellu-

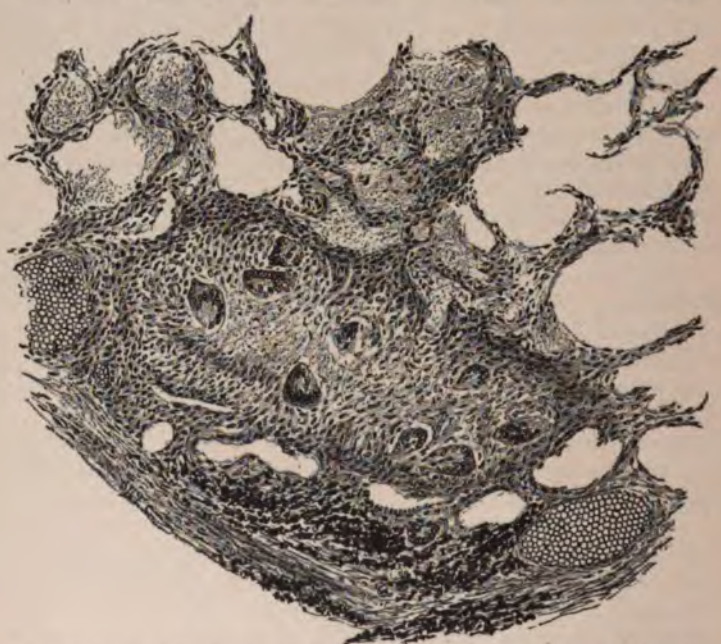

FIG. 209.—Peribronchial tubercle of the lung and caseous pneumonia of the adjacent alveoli.

lar, and is principally composed of large epithelial cells. These are the desquamated and proliferated lining-cells of the alveoli. A smaller number of red blood-corpuscles and leukocytes is noted, but they are unessential. Sometimes a fibrinous network may be seen in the alveoli, but quite as often this is wholly wanting. The blood-vessels are engorged at first, and the septa are infiltrated with round cells and spindle-cells. The walls of the blood-

PLATE 6.

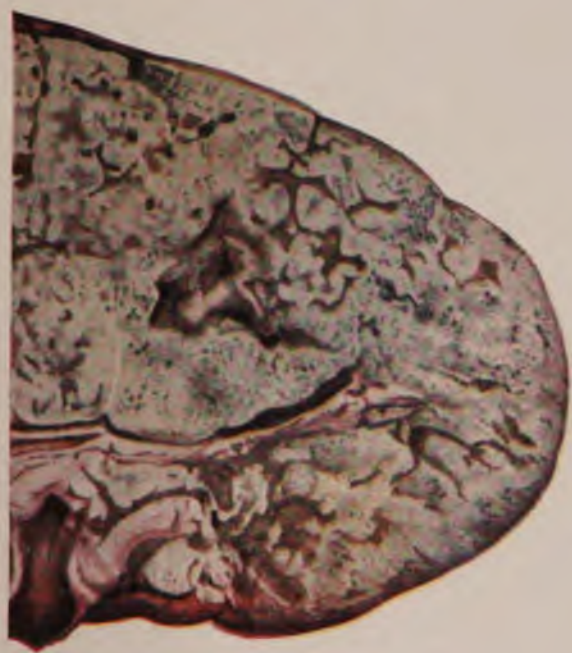

Subacute caseous (tuberculous) pneumonia (Bollinger).

vessels themselves may be thickened by proliferation of the connective tissue. As the process advances, the cellular exudate and the alveolar walls as well undergo cheesy degeneration, and present a granular appearance under the microscope (Fig. 209).

Associated Lesions.—Cases of typical caseous pneumonia, as above described, are rare; as a rule, more specific tubercular lesions are associated. These may result subsequent to the pneumonic process from the penetration of infective material into the lymphatics and its dissemination along these channels; or the specific tubercles may antedate the associated caseous pneumonia. The smaller bronchi are commonly attacked, and tubercular bronchitis and peribronchitis tending to cheesy change result. The pleura may be covered with inflammatory exudation, or may present miliary tubercles over the area of disease. Associated pleural involvement is especially common between the lobes. The lymphatic glands of the anterior mediastinum and around the bronchi are frequently enlarged, and may be cheesy in the later stages.

Fibrous Pneumonia.

Definition.—Fibrous, or productive, pneumonia is a chronic process resulting from continued irritation, and involving small or large areas of the pulmonary structure. Pathologically it is characterized by overgrowth of connective tissue, and clinically it is marked by signs of more or less extensive mechanical impairment of the pulmonary functions.

Classification.—Several quite distinct forms, depending upon different modes of causation, may be described. The principal varieties are: (1) the pneumonokonioses, or fibrous pneumonias, due to dust-inhalation; (2) the secondary indurative pneumonias, such as sometimes follow croupous, catarrhal, or caseous pneumonia, or more frequently chronic congestion of the lungs or atelectasis; (3) pleurogenetic fibrous pneumonia, in which the process arises by extension of chronic pleural disease; and (4) peribronchial and perivascular fibrous pneumonia, in which the process follows the bronchi and pulmonary arteries.

1. **Pneumonokoniosis.**—Of the dust we constantly inhale, but a small part reaches the finer divisions of the bronchial tree. Most of it adheres to the walls of the upper respiratory tract and is discharged with the sputa, either free or enclosed in leukocytes or epithelial cells (*dust-cells; staubzellen*). When fine particles reach the terminal bronchioles they occasion catarrhal inflammation, marked by proliferation of the epithelium and exudation of leukocytes. These cells may envelop the irritant particles and remove them through the expectoration. When, however, the dust has sharp edges (as in coal-dust, iron-dust, marble-dust, etc.), and especially when the quantity inhaled is considerable, removal

by expectoration becomes more difficult. In such cases the foreign particles penetrate the walls of the bronchioles and alveoli, passing between the epithelial cells. They may be arrested in the alveolar septa and in the tissue surrounding the bronchioles by the formation of a zone of inflammatory exudation, which eventually organizes, forming a fibrous capsule. Some of the particles, however, move along the lymph-spaces into the lymphatic vessels, being carried by leukocytes or floating free in the liquid. These particles may be arrested at various points along the lymphatics, and may occasion fibrous thickening of the vessels or of the perilymphatic tissue. The greater portion, however, passes to the lymphatic glands at the root of the lung and surrounding the bronchi, and indurative enlargement of these structures results. In exceptional instances the irritant particles may be conveyed still further, being deposited in the glands about the smaller curvature of the stomach and beneath the fissure of the liver. This unusual distribution in a direction opposite the usual lymphatic current is explained by the assumption that obstruction of the larger pulmonary lymphatics causes a reversal of the current. Metastatic distribution of dust-particles may also be due to rupture of one of the affected lymphatic glands into a vein.

Pathologic Anatomy.—The appearance of the lung varies with the amount of dust inhaled and with its nature. In cases of moderate degree small areas of fibrous thickening, with puckering, are the only abnormality. On section these are found to be hard and of grayish color; often, however, darkly pigmented, owing to the character of the particles inhaled as well as on account of the formation of hemorrhagic pigmentation. The fibrous tissue may be arranged in a stellate fashion, or concentrically around a nucleus of foreign matter. Secondary changes are not uncommon; calcification is frequently observed, and true bone-formation is occasionally noted. Such areas of localized pneumonokoniosis are very commonly met with near the apices.

More extensive induration is rare, and is rather more frequent at the bases. Large areas of induration may completely destroy the vesicular character of the lung-structure. Firm bands of connective tissue may follow the bronchi and radiate into the peripheral portions of the lung, or thickened trabeculæ may pass from the pleural surface toward the anterior, or, again, a more uniform sclerosis may exist throughout the organ. The organ is contracted; the pleura, as a rule, is thickened and drawn inward; and the bronchi may be widely dilated as a result of the traction of the contracting connective tissue and as a consequence of accumulating secretions within. Extensive adhesions to the chest-wall often cause deformities of the chest, and the pericardium, heart, and other mediastinal structures may be drawn from their normal positions.

In rare cases the epithelium of the alveoli and finer bronchioles proliferates, and later undergoes a certain amount of fatty degeneration, giving rise to an appearance not unlike caseation. In still other cases necrosis and suppuration and cavities (non-tubercular) are observed.

Microscopically.—In the beginning stages round-cell infiltration and connective-tissue proliferation may be seen around the foreign particles in the septa, and a certain amount of catarrhal inflammation may be present in the alveoli. Sharp-edged particles often occasion small hemorrhages. In the later stages dense sclerotic tissue characterizes the process. Proliferative inflammation of the epithelium of the alveoli may be present, but more often the cells undergo atrophy and disappear.

Varieties.—Certain varieties, dependent upon the kind of dust inhaled, have been described. The term *anthracosis* is applied to those instances in which coal-dust is the irritant. To a moderate extent this is seen at every autopsy on persons of adult age, but the cases in which conspicuous sclerosis has occurred from this cause are met with only in coal-miners and others of similar occupation. The lung is of a marble-like or slate-like appearance, and the lymphatic glands around the bronchi are intensely pigmented. *Siderosis* is the designation of the cases of pneumonokoniosis due to iron-dust, as seen in grinders, founders, etc. *Chalicosis* is the term applied to the form due to stone-dust, as seen in potters, marble-cutters, etc.

2. **Secondary fibrous pneumonia** sometimes occurs after croupous or catarrhal pneumonia, or atelectasis, and in these cases appears in the form of uniform or localized induration of the pulmonary structure. It is due to reactive inflammation of the septa, causing thickening of the latter, as well as proliferation within the alveolar exudate. Similar reactive fibrous change is seen in some cases of caseous pneumonia, and in chronic phthisis the cavities are quite generally walled by fibrous tissue. Finally, chronic congestion of the lung, such as occurs in valvular diseases of the heart, particularly mitral disease, frequently leads to diffuse sclerosis of the lung. Such cases are distinguished by dilatation of the veins and by hemorrhagic pigmentation.

3. **Pleurogenic fibrous pneumonia** is an occasional consequence of chronic pleurisy. The lung presents on section dense trabeculæ of fibrous tissue, which extend from the thickened and sclerotic pleura deep into the pulmonary structure (Fig. 210).

4. **Peribronchial and perivascular fibrous pneumonia** may be associated with the pleurogenic form, or the overgrowth of connective tissue around the bronchi and vessels may start at the root of the lung and extend toward the periphery. The latter form has been described by some observers as especially liable to result from syphilis. More moderate peribronchial and perivas-

cular fibrous pneumonia occurs in association with other forms, as the pneumonokonioses and secondary fibrous pneumonias, but in these cases it is but a minor part of the process.

FIG. 210.—Fibrous pneumonia secondary to chronic pleurisy (Kaufmann).

Congenital Syphilitic Pneumonia.—A form of *productive pneumonia*, as distinguished from fibrous pneumonia in the strict sense that the latter is characterized by formation of sclerotic fibrous tissue, is met with in congenital syphilis. This is the *pneumonia alba* of some writers. It is characterized by great proliferation of round and irregular connective-tissue cells, with more or less multiplication and degeneration of epithelial cells in the alveoli and bronchioles. The lung is solid, airless, and white in color. Gummata may be associated.

Purulent Pneumonia.

Definition.—Purulent pneumonia is an acute form of pneumonia caused by pyogenic micro-organisms. Pathologically it is characterized by purulent and hemorrhagic exudation in the connective tissue, lymphatic channels, or terminal bronchioles and alveoli; and clinically it is marked by evidences of intense septic infection as well as of great pulmonary embarrassment.

The infection in purulent pneumonia may reach the lungs through the bronchi (bronchogenic), the blood-vessels (hematogenic), or the subpleural lymphatics (pleurogenic or lymphogenic).

Bronchogenic purulent pneumonia has already been referred to in the description of fibrinous pneumonia and catarrhal bronchopneumonia. It is particularly frequent in the latter, in some cases of which considerable purulent exudation may be seen in the alveoli or, in the form of small purulent collections, in the

intervesicular septa. These are instances of intense infection, and the majority of such cases are due to the Streptococcus pyogenes or to staphylococci. The pneumococcus may, however, be found alone. The most decided purulent bronchopneumonia is seen in instances of aspiration-pneumonia secondary to a suppurative process in the upper respiratory passages, in which particles of infective material are inspired and lodge in the bronchioles.

Purulent pneumonia is rarely met in the course of fibrinous pneumonia, but sometimes occurs as a terminal condition. Abscesses of considerable size may be formed.

Hematogenic purulent pneumonia is secondary to suppurative or gangrenous processes in other parts of the body, and is a manifestation of pyemic infection. It is frequent in puerperal septicemia, in suppurative osteomyelitis, and like conditions. The micro-organisms are carried by the veins to the right heart, and may first set up malignant endocarditis, from which embolism takes place, or they may pass directly through the right heart to the lungs. As a rule the micro-organisms in question are either streptococci or staphylococci; but in certain specific infections (as typhoid fever) the specific organisms may alone occasion purulent pneumonia.

When large embolic masses reach the lungs occlusion of larger branches of the pulmonary artery occurs and hemorrhagic infarcts are formed. In the earliest stages these appear as more or less well-circumscribed areas of hemorrhagic infiltration of dark-red color. Very soon change of color occurs, and the foci alter to a grayish, then a yellowish, color, and finally liquefy, forming suppurative cavities, with irregular walls. The tissue around is intensely engorged and edematous, and not rarely quite hemorrhagic. Microscopically it presents the appearances of a catarrhal and hemorrhagic pneumonia. The abscesses frequently break into the bronchi and discharge their contents; more rarely rupture into the pleural sacs occurs. The pleura itself is intensely inflamed over the embolic areas, and, as a rule, is covered with fibrino-purulent exudate. Extensive purulent pleurisy (*empyema*) may occur.

When the micro-organisms reach the lung in a more disseminated manner they pass at once to the smaller arterioles and capillaries. Embolic infarcts are wanting in such cases, but there is diffuse serous, hemorrhagic, catarrhal, and purulent exudation, which causes consolidation of a somewhat gelatinous character. Small foci of suppuration may be seen, and the purulent process may visibly extend to neighboring parts of the lung along the lymphatic vessels.

Terminations.—In either of the above forms, the localized embolic or the diffuse, necrosis or gangrene of the pulmonary tissue may occur. Occasionally recovery takes place by absorption of

the purulent exudate or by its discharge. As a rule, the disease is fatal.

Pleurogenic purulent pneumonia follows intense pleurisy, usually of purulent type. Infection of the subpleural lymphatics first ensues, and later the purulent process extends into the lung within and around these vessels (*purulent lymphangitis* and *peri-lymphangitis*), in the form of yellowish streaks or bands, which surround the veins and bronchi and follow the interlobular fibrous tissue in various directions. The lobules of the lung may be so pushed apart that the term *pneumonia desiccans* is quite applicable. The proper substance of the lung adjoining the paths of purulent invasion, and under the pleura, frequently shows the same form of hemorrhagic and purulent pneumonia as occurs in the diffuse hematogenic form.

Associated Lesions.—Widespread pyemic and toxic lesions are often found in association with purulent pneumonia, but they are often merely coincident results of the same primary disease to which the pneumonia owed its origin, rather than the consequences of the purulent pneumonia itself. Secondary infections may, however, occur, such as malignant endocarditis of the left side of the heart, septic nephritis, and the like.

GANGRENE.

Gangrene of the lung results from the action of putrefactive micro-organisms in necrotic areas of the lung-tissue. It may be the consequence of direct extension of carious conditions of the ribs or other adjacent bony structures through the pleura into the lung, or of the extension of necrotic processes from ulcers or cancerous disease of the esophagus or stomach. In other cases the infective materials reach the lung through the inspired air, coming from ulcerative processes in the upper air-passages, or from without. When foreign bodies lodge in the bronchi, or the latter are obstructed by the pressure of tumors or aneurysms, there may be, first, more or less congestion and pneumonic consolidation, followed by secondary infection and gangrene. In still other instances the infective material reaches the lung through the blood, and, finally, gangrene is sometimes a terminal process in pneumonia, tuberculosis, and hemorrhagic infarction of the lungs. Certain general conditions predispose more or less to it. Thus in diabetic individuals congestions or pneumonia are prone to terminate in this way, and engorgement of the veins or passive hyperemia always renders the lung more liable.

Pathologic Anatomy.—Gangrene may appear as a circumscribed or diffuse process. In the former instances more or less extensive areas of lung present a dark, reddish, brownish, or even greenish appearance, and are surrounded by a zone of intense con-

gestion or of pneumonic consolidation, often of purulent or hemorrhagic type. The diseased part is soft, pultaceous, and foul in odor. Later it may break down into a putrid mass, and may discharge through the bronchial tubes, severe pulmonary hemorrhages sometimes occurring at the same time. The bronchi and the blood-vessels often escape the process, and may pass through the gangrenous area without being themselves materially affected; but usually the bronchi are penetrated, and the blood-vessels, after they become occluded by thrombosis, suffer the fate of the other tissues. The process may extend widely from a single focus, or reactive inflammation may establish a fibrous capsule, and after discharge of the gangrenous material through the bronchi, healing by the formation of a scar may terminate the disease.

Diffuse gangrene does not differ much in its general appearances, but is less intense and in general more widespread. The affected area is of a dark-red or greenish-black color, soft, and edematous, or sometimes dry, and has a somewhat fetid odor, as in the circumscribed form. Spots of hemorrhagic infiltration and of softening, with formation of cavities, may be noted.

The sputa in gangrene are mucopurulent, of a yellowish-gray or brownish color, and intensely fetid. When placed in a conical vessel they separate into three layers: the upper frothy, the lower puriform and brownish in color, and the middle layer more fluid and yellowish.

INFECTIOUS DISEASES.

Tuberculosis.

Tuberculosis of the lungs is generally a local disease, but may be only part of a general tuberculosis. The specific cause, the tubercle-bacillus, gains access to the lungs through the same channels as the irritants that occasion pneumonia. The most frequent method of infection is through the air-passages (*bronchogenic tuberculosis*), the bacilli in such cases coming directly from the outside world or from a tuberculous lesion of the nose, mouth, pharynx, larynx, or bronchi. The latter lesions in turn are frequently caused by bacilli inhaled from without, the bacilli owing their presence in the inspired air to the desiccation and dissemination of sputa of phthisical patients (see Tuberculosis, in Part I.). A second method of infection is that through the blood (*hematogenic tuberculosis*). The pulmonary disease in such cases is usually secondary to a tuberculous lesion elsewhere which has perforated a vein and discharged its contents into the blood. In such cases general tuberculosis results, and the lungs are affected in common with other vulnerable structures. The infected material may reach the blood in a more roundabout way, when a tuberculous gland or other focus breaks into a lymphatic

vessel (commonly the thoracic ducts in cases of tuberculosis of the abdominal or posterior thoracic lymphatic glands). Hematogenic tuberculosis may in rare instances be limited to the lung, and be secondary to an older tuberculous lesion of the lung itself. This happens when a caseating nodule perforates a branch of the pulmonary artery and the infective matter is carried to the peripheral distribution of the artery. The third and last method of implication of the lungs is through the lymphatic vessels (*lymphogenic tuberculosis*). This may be secondary to tuberculous pleurisy or to caseous tuberculosis of the peribronchial lymphatic glands or of the thoracic vertebræ.

Bronchogenic Tuberculosis.

The action of the tubercle-bacillus when inhaled may be likened to the action of dust-particles entering the lungs in a similar manner. Larger masses of infective material may lodge in the bronchi or larger bronchioles and set up tuberculous ulcerations, from which smaller particles may be secondarily aspirated into the finer divisions of the bronchial tree. Such an occurrence, however, is extremely rare. More commonly the tubercle-bacilli are inhaled in a state of extreme dissemination, and are not arrested until they reach the point of division of the terminal bronchioles into the alveolar passages. One of two results may occur at this point: either there is set up a limited area (miliary nodule) of caseous or tuberculous pneumonia, or the bacillus penetrates between the epithelial cells and occasions more specific tubercular changes in the peri-alveolar and peribronchial connective tissues (miliary tubercles). It has been the occasion of some dispute among pathologists to decide which of these processes is most apt to arise when the infection occurs through the bronchial tubes. Undoubtedly both kinds of change may take place, and it seems likely that in nearly every instance there is a mixture of the two forms. When the infective material is in great abundance and is particularly virulent, and in cases in which the individual is especially vulnerable, caseous pneumonia predominates over the formation of tubercular nodules. On the other hand, a less abundant infection or greater resisting power on the part of the individual determines the greater liability to the formation of nodules and the less likelihood of extensive caseous pneumonia. In case of either manner of onset, however, there is soon added the other form of disease. Thus in the instances in which caseous pneumonia first occurs, the peribronchial involvement characteristic of that condition leads to dissemination of the bacilli along the lymphatic channels, and there are formed in the neighborhood, or to considerable distances around, miliary nodules, which in turn spread the infection to the alveolar structures in their vicinity.

In a similar manner, when the primary lesion is a tubercular nodule surrounding the alveolar passages, the alveoli soon become involved by caseous pneumonia.

At the same time that these processes are taking place and spreading, degenerative and reparative changes are set on foot. The areas of pneumonia, which began as grayish miliary nodules or as larger areas of lobular tuberculous pneumonia, change their color to a yellowish and become completely caseated; while the secondary tubercles in the neighborhood, or those which were primarily formed, similarly become opaque and lusterless, and finally yellowish by caseation. This tendency to caseous necrosis is one of the most prominent and characteristic features of tuberculous tissues, and has occasioned no little investigation and controversy to establish its causation. Little doubt now exists that two factors play a part: first, the lack of adequate blood-supply, and, second, the specific action of the tubercle-bacillus. The blood-vessels in caseous pneumonia or in the tubercles are inadequate to supply sufficient nourishment to the tissue. In the pneumonic areas this is due to proliferative changes in the intima and to direct pressure of the exudate, while in the tubercles it is due to hyaline and other forms of degeneration with collapse of the walls.

Coincidently with the process just described round-cell infiltration and proliferative changes are manifest in the structures surrounding the diseased areas. In the case of the areas of caseous pneumonia infiltration and proliferation of the connective tissue of the septa, as well as proliferative changes in the blood-vessels of these parts, are observed. There is a wide variation in particular instances in the degree of these reparative processes, and in general it may be said that the more acute the disease the more apt is degenerative caseation to take place and the less likely regeneration to occur. Similar overgrowth and infiltration may be seen around the tubercles, and in favorable instances the latter may be completely encapsulated or converted into a fibrous nodule. In instances in which the reparative processes are very extensive there may eventually be a preponderance of connective tissue over caseous pneumonia or miliary tubercles.

Varieties.—We may distinguish all of the forms of bronchogenic tuberculosis by the name of *pneumonic tuberculosis*, from the fact that the element of caseous pneumonia is always an important one, and separates them sharply from hematogenic and lymphogenic tuberculosis, in both of which the formation of miliary tubercles predominates over other processes.

Three forms of pneumonic tuberculosis are met with: the acute, which is frequently spoken of as *acute caseous phthisis*, or *galloping consumption;* the chronic, which is also known as *chronic ulcerative phthisis;* and the form in which fibrous overgrowth predominates, and which is therefore known as *fibrous* or

fibroid phthisis. While typical instances of these forms are quite distinct, there is no sharp dividing-line separating the groups, and individual forms merge insensibly one into the other.

Acute pneumonic tuberculosis is more common in children than in adults. Two elements play a part in its occurrence: first, a high degree of susceptibility, and, second, abundant infection with virulent bacilli. The latter may be derived from without the body by direct inhalation, or may come from the discharge of older caseous areas in the lungs, which have broken into the bronchial tubes, or from some focus of tuberculosis in the upper air-passages.

Pathologic Anatomy.—This form of tuberculosis is lobular, but very frequently by confluence of the affected areas an entire lobe may be involved. Either the base or the apex may be first affected. On section the lung presents a more or less variegated appearance in the earlier stages, due to the formation of miliary patches and lobular areas of caseous pneumonia having a grayish appearance, and the coincident congestion of surrounding portions of the lung-tissue. Sections through the lung which cut a terminal bronchiole in a longitudinal direction show it surrounded by peribronchial caseation and more or less filled with cheesy exudate

FIG. 211.—Bronchogenic tuberculosis of the lung, showing the involvement of the tissues surrounding the terminal bronchioles (Birch-Hirschfeld).

(Fig. 211). Transverse sections give the appearance of a section through a large tubercle, but the lumen of the bronchiole may usually be discovered in the center or to one or the other side. Small miliary tubercles may be apparent in the edges of the pneumonic patches, and even for some distance around them, but the tuberculous tissue is more apt to appear as diffuse infiltration along the peribronchial and perivascular lymphatics than as distinct tubercles. As the process increases the lung-tissue may be completely involved and uniformly gray or yellowish and consolidated

(Fig. 212). The cut section is generally somewhat granular in the earlier stages from admixture of fibrinous exudation in the alveoli; but later progressively increasing caseation and softening render the surface of section smooth and moist. Not infrequently complete destruction takes place and cavities are formed. These are usually small and present no marked tendency to the formation of an organized wall, but appear simply as necrotic excavations with irregular, ragged outlines. The pleura over the surface of such a lung is usually inflamed and covered with more or less fibrinous or fibrinopurulent exudation, and not rarely with an abundant crop of tubercles. Occasionally a vomica may rupture and cause pneumothorax or pyopneumothorax.

FIG. 212.—Extensive bronchogenic tuberculosis (caseous pneumonia) of the base of the lung (Orth).

When the process is less active and the infection less abundant confluence of the lobular areas is less likely to occur, and there are seen merely disseminated patches of caseous pneumonia scattered through various parts of the lung, which is itself more or less congested. In such instances, too, the evidences of reparative change are more decided. Complete encapsulation with subsequent calcification may ensue, or fibrous overgrowth may convert the entire area into a cicatricial mass. If the cheesy area is simply enclosed with fibrous tissue, it may remain quiescent for a time, possibly for years, and subsequently penetrate the enclosing wall and occasion a fresh extension of the whole process.

Chronic pneumonic tuberculosis is the ordinary form of pulmonary phthisis. It begins in the apices of the lungs in the great majority of cases, though children are as likely to be first affected at the bases as at the apices. While there is no doubt that chronic phthisis is usually due to infection through the inspired air, it must be admitted that occasionally the onset of the process is due to infection through the blood or lymphatic channels. In the in-

stances of the latter kind there is first established a localized lesion which caseates and penetrates a bronchial tube, discharging its contents, and thus leading to widespread bronchogenic infection. The further development of the disease takes place in several distinct ways (see below).

Pathologic Anatomy.—When there has been an existing bronchitis, adhesion of the bacilli may occasion tuberculous bronchitis with ulceration and secondary involvement of the surrounding tissues. More commonly the bacilli lodge in the finer bronchioles, as in acute pneumonic phthisis, and give rise to lobular areas of caseous pneumonia, surrounded by tubercles which are formed along the course of the lymphatic vessels leading out from the first-formed caseous areas. There is a tendency to a constant increase of the area of disease by the discharge of caseous material into the bronchi and its aspiration into other parts of the lung, and also by dissemination of the infection along the lymphatic vessels traversing the connective tissue around the blood-vessels and bronchi. Section through the lung discloses more or less consolidated tissue of an opaque, grayish or yellowish appearance, in which the bronchi may be seen as open spaces or filled with mucopurulent liquid. Little distinction between caseous pneumonia and the tubercles can be made in the center of such an area, but at the edges, where the process is seen in the earlier stages, such distinction may be possible.

The same tendencies to degeneration and softening, on the one hand, and to the processes of repair, on the other hand, are seen in chronic pneumonic phthisis as are apparent in the acute form. There is the difference, however, that these changes are less rapid, and that, as a rule, proliferation of connective tissue with the formation of fibrous tissue is more pronounced than in the acute disease.

The degenerative and necrotic processes lead to a most characteristic lesion of tuberculous lungs—*the cavity*. Cavities are formed either through the dilatation of the bronchioles (bronchiectasis), due to their ulcerated and weakened condition and to the pressure of retained secretions, with subsequent ulceration and breaking down of the surrounding caseous tissue; or, on the other hand, to liquefaction of caseous areas not in connection with the bronchial tube. In the latter case, however, communication with the bronchi is frequently established by extension. A single cavity may grow larger and larger by constant ulcerative processes, in which not alone the caseous tuberculous degeneration takes a part, but also active ulcerative changes dependent upon mixed infection through inspiration of pyogenic organisms. As a rule, however, larger cavities are formed by the confluence of separate smaller ones, and there may be found a series of excavations communicating more or less extensively with each

other. The cavity, or vomica, contains a variable amount of ill-smelling, putrid secretion, consisting of broken-down cheesy matter, pus-cells, degenerated epithelial cells, and fibers of elastic tissue, and containing tubercle-bacilli, pyogenic organisms, and occasionally mould-fungi. The walls of the cavity are generally formed by reparative fibrous proliferation, and are covered with a pyogenic membrane, usually darkly pigmented. The inner surface is very rough and ribbed by projecting bands. The latter represent the trabeculæ and blood-vessels of the lung-tissue, which have resisted ulceration more obstinately than the surrounding structure of the lung. This resistance may continue to such an extent that the blood-vessel is left as a cord passing directly through the center of the cavity; but, as a rule, the lumen of the vessel is soon obliterated by thrombosis and the vessel itself destroyed. Not infrequently examination of the blood-vessels in the wall of the cavity or passing through it show small aneurysmal dilatations which result from the weakening of the wall by the surrounding necrotic process and from the pressure of the blood within. It is from aneurysms of this character that the large and often fatal hemorrhages of the later stages of tuberculosis take place, though hemorrhage may also occur directly from the eroded blood-vessel. The smaller hemorrhages of the early stages of phthisis, which occasion only a streaking of the sputa with blood, are due to early erosion of small vessels of the bronchioles or to capillary ruptures dependent upon congestion.

Fibroid Phthisis.—The reparative or fibrous processes which tend to counteract caseation and destruction may begin before cavity-formation or after it. When beginning in the earlier stages the caseous areas will be found to present a capsule of more or less well-developed fibrous tissue, which may completely surround and separate them from the neighboring tissue of the lung. The capsule tends to contract and shrink, and the caseous material within may become completely calcareous. In this manner a limited focus of tuberculosis of the lungs not infrequently becomes completely arrested. When the capsule is not so firm, after a period of quiescence or latency extending over even a number of years, fresh extension may begin, the capsule may be perforated, and acute pneumonic phthisis may be established, or the tuberculous process may extend more slowly through the contiguous areas as chronic ulcerative phthisis.

The fibrous capsules surrounding the cavities, which have already been alluded to, may be of varying prominence. In case of small vomicæ with pronounced fibrous walls the contraction of the latter may almost obliterate the cavities, leaving only narrow and distorted spaces containing a small amount of putrid material (*cicatrices fistuleuse* of Laennec). Complete healing of a cavity of notable size probably never occurs. When the excava-

tions are of large size the reparative processes consist simply in the formation of a thick wall of fibrous tissue, which prevents the further extension, for a time, at least, of the tuberculous process.

Complications in Bronchogenic Pneumonia.—Of first importance in tuberculosis of the lung is the condition of the pleura. In the acute pneumonic form the pleura adjoining the diseased areas is generally more or less inflamed and may present considerable fibrinopurulent exudation, as in croupous pneumonia. Serous or seropurulent exudation may likewise be present, and eruption of miliary tubercles in the pleura is not unusual. The same processes may occur in chronic pneumonic tuberculosis or chronic phthisis. More commonly there are found simply fibrous adhesions binding the one surface of the pleura to the other, especially at the apex.

Extension of the tuberculous process may also take place directly upward along the air-passages, and is due for the most part to direct infection by the sputa. There may thus occur tuberculous ulceration of the larger bronchi, of the trachea, of the larynx, or of the pharynx. When the sputa are swallowed, as is especially likely to happen in children, or in adults during sleep, intestinal tuberculosis is apt to occur.

Finally, dissemination of the tuberculous disease through the blood is frequent. A caseous area in connection with one of the veins may penetrate the lumen of the vessel and discharge its contents into the circulating blood, or may first occasion tuberculous proliferation in the intima of the vein or infectious thrombosis, from which the blood is secondarily infected. There results general miliary tuberculosis, the tubercles occurring especially in the spleen, the liver, the kidneys, the choroid coat of the eye, or in the membranes of the brain or other serous membranes.

Acute pneumonia may accompany either acute or chronic pneumonic tuberculosis, and certain authors insist that in practically all cases there is more or less mixed infection. This is probably not the case, but complicating pneumonia is undoubtedly frequent. In most of such cases localized patches of catarrhal bronchopneumonia are seen between the caseous lobules; but sometimes a frank fibrinous consolidation may occupy the lower lobe of a lung in which the upper lobe presents beginning tuberculosis. Quite frequently there are small areas of pneumonic consolidation of fibrinous character in the lobe which is itself the seat of tuberculous involvement. Toward the end of life there is usually extensive edema of the bases and posterior portions of the lungs.

The heart has interesting relations with tuberculosis of the lungs. Early writers called attention especially to the fact that phthisical subjects frequently present unusual smallness (hypoplasia) of this organ, and more recently attention has been directed

to the fact that congenital stenosis of the pulmonary orifice strongly predisposes to tuberculosis of the lungs. Some have claimed that there is an antagonism between cardiac disease and tuberculosis. This view is not well founded, though it is probable that the chronic congestion of cardiac disease renders the lung somewhat less vulnerable to tuberculous infection than the normal lung. Where there is a long-standing tuberculous consolidation hypertrophy, especially of the right ventricle, is likely to occur. Tuberculous pericarditis may be found in association with tuberculous pleurisy; and tubercles may also, though much more rarely, be found upon the endocardial lining. The latter are due to infection through the blood.

Hematogenic Tuberculosis.

This form occurs when a focus of tuberculous disease ruptures into a blood-vessel and the infective materials are disseminated in the circulation. As a rule, hematogenic tuberculosis of the lungs is only a part of a general tuberculosis of the entire body. The points from which the primary infection may take place are, of course, numerous, but caseous lymph-glands of the cervical or peribronchial group, or old foci of tuberculosis at the apex of the lung, are perhaps the most frequent. The organs and structures of the body likely to be infected by general miliary tuberculosis are the spleen, the liver, the kidney, the choroid coat of the eye, the meninges, and, more prominently than any other organ, the lungs. In the rare cases in which rupture of the vomica has occurred into one of the branches of the pulmonary artery within the lung, only one lung, or but a part of a lung, may be involved.

Pathologic Anatomy.—The pathologic feature of importance in hematogenic tuberculosis is the formation of miliary tubercles. These appear as gray or translucent areas, the size of millet-seeds, around and involving the terminal arterioles or capillaries in the intervesicular septa. At first they may be so small that the naked eye scarcely discovers them, and they are so translucent that oblique light is necessary to make them appear to view. Later they increase in size and become more grayish and opaque. Microscopically there are the well-known characteristics of the miliary tubercle embedded in the perivascular connective tissue (see Tuberculosis, Part I.). These tubercles, however, are prone to distinguish themselves from the characteristic tubercles seen elsewhere by their more irregular outline and the more irregular arrangement of their component histologic elements. When the tuberculous process is particularly rapid and virulent giant-cells are few in number, and the tubercle is composed mainly of proliferated connective-tissue cells of the ordinary type, some epithelioidal cells, and round infiltration-cells, all of them more or less granu-

lar, and the entire nodule surrounded by a zone of caseous, catarrhal, or even hemorrhagic pneumonia of the contiguous alveoli of the lung (Fig. 213). The tubercles are rarely seen

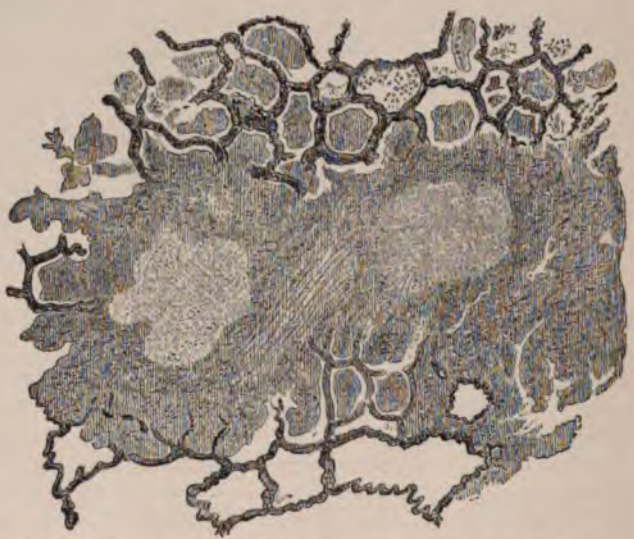

FIG. 213.—Miliary tuberculosis of the lung, showing two tubercles with degenerated centers, and caseous pneumonia of the alveoli adjacent to the tubercles (Orth).

in the stage of advanced necrosis, but this may take place in instances of a more chronic course in which the bacteria are admitted to the lungs slowly and perhaps in a state of lesser virulence than common. In those instances of what may be termed chronic miliary tuberculosis there may be a considerable amount of caseation of the tubercles, and the patches, as a rule, become decidedly larger than in the ordinary acute form (Fig. 214). An explanation of this form of chronic miliary tuberculosis has been offered by certain authors, who hold that these are instances of infection through the thoracic duct and blood-vessels. The infective material enters the thoracic duct from caseous lymphatic glands in the abdomen or thorax, and is discharged with the lymph into the veins in a gradual manner, only a little being allowed to pass at a time.

The ordinary and typical acute miliary tuberculosis presents itself clinically as an acute infectious disease, running its course rapidly and causing early dissolution. The disease is rather a general toxemia than a local process, and toxemic changes may be present in various organs, such as occur in other infectious and toxemic diseases. The heart, liver, the kidneys, and, in general, the parenchymatous structures are prone to become degenerated, and when the febrile infection continues there may be extensive

fatty degeneration. In addition to the eruption of miliary tubercles in other organs, to which allusion has already been made, there is also involvement of the pleura which belongs more prop-

FIG. 214.—Hematogenic tuberculosis, showing many scattered miliary tubercles and several clusters (modified from Bollinger).

erly to the pulmonary process itself, and is simply a continuation of the same infection which gave rise to the pulmonary involvement.

Lymphogenic Tuberculosis.

It is possible for tuberculous infection of the lungs to occur through the lymphatic channels in several ways. In speaking of acute miliary tuberculosis, particularly of the more gradual type, reference was made to the fact that infective material is sometimes carried by the thoracic duct from the lymphatic glands of the abdomen and posterior mediastinum, as well as possibly from carious thoracic vertebræ to the blood-vessels, and thence distributed through the blood to the lungs as a hematogenic infection. Direct infection, however, through the lymphatic channels may take place. Thus tuberculous pleuritis, either primary or secondary to tuberculous disease of the vertebræ or ribs, sometimes spreads directly into the lung through the lymphatic vessels traversing the interlobular connective tissue; and in cases of caseous tuberculosis of the peribronchial glands the infective material may be conveyed into the lungs either by a reversal of the current of

lymph in the vessels running to these glands or by direct extension along the lymphatic walls. A form of lymphogenic tuberculosis of the lungs may also be referred to in which caseous lymph-glands directly perforate the lung-tissue, but the actual dissemination of the process in the lungs in these cases is usually through the bronchial tubes into which the bacilli gain entrance.

Pathologic Anatomy.—It is characteristic of lymphogenic tuberculosis to find small nodular areas which microscopically are seen to be more or less characteristic tubercles. These are scattered along the lymphatic vessels running in the interlobular septa or surrounding the blood-vessels and bronchi. In the instances of lymphogenic tuberculosis secondary to pleuritis suppurative lymphangitis and perilymphangitis (see Pneumonia) are not infrequently associated.

SYPHILIS.

It has been the occasion of much dispute whether the many forms of disease attributed to this cause can be really so classified. Undoubtedly some of the conditions attributed to syphilis are cases of tuberculosis, or of some other form of pulmonary disease. But there are other varieties which can unquestionably be spoken of as syphilitic. Among these are the diffuse infiltration of the new-born and the tertiary gummata.

Diffuse syphilitic infiltration of the lungs is occasionally met with in the new-born. As a rule, infants showing this are stillborn. It manifests itself as a more or less lobar consolidation and induration of the lung-tissue. On section the lung is light gray or almost white in color, and completely airless, so that the name *pneumonia alba*, given by older writers, was highly significant. Microscopically there are seen widespread round-cell and spindle-cell infiltration and proliferation in the interalveolar and interlobular connective tissues, with more or less compression of the bronchioles and alveoli. The epithelium of the latter may be somewhat proliferated and desquamated, and shows a tendency to fatty degeneration and necrosis. In some instances the degenerative changes do not take place, and the proliferated epithelium of the alveoli is massed within the alveolar lumen, and is for the most part of a cuboidal character. The blood-vessels commonly show proliferation of the adventitia as well as of the intima, and may be completely obliterated. According to Birch-Hirschfeld, syphilitic fetuses of the sixth or seventh month sometimes present limited disease of this nature and of such distribution that it is recognized to begin as a peribronchial and peri-alveolar infiltration of lobular distribution.

Syphilitic gummata may be associated with the diffuse form of congenital syphilis, or may be present in the new-born

without the latter. Gummata are occasionally seen in adults. They are present most frequently near the root of the lung beneath the pleura, but may be scattered through other parts of the organ. As a rule, the number is limited. They appear as more or less rounded nodules of a grayish to yellowish color, with more or less fibrous overgrowth surrounding them and often radiating from them into the surrounding lung-tissue. Central necrosis may proceed to such extent that cavities are formed.

Occasionally the contents of a gumma may be discharged through the bronchial tubes, or they may be absorbed and a cicatricial puckering of the lung-tissue may mark the place of the former disease. Microscopically there are seen in the earlier stages the ordinary appearances of gummata (see Syphilis, Part I.), with more or less diffuse infiltration surrounding them and with thickening and hyaline degeneration of the blood-vessels.

Syphilitic fibrous induration of the lung, so-called, has been described, and it seems likely that some of the cases embraced

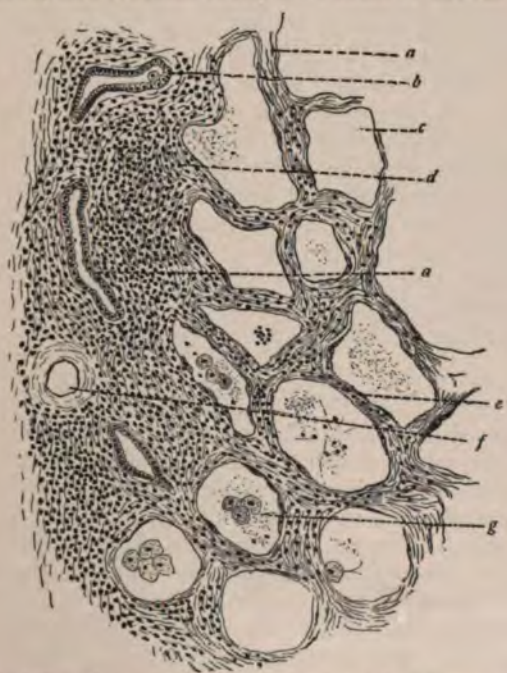

FIG. 215.—Syphilis of lungs: *a*, thickened alveolar walls or stroma; *b*, partly longitudinal section of bronchus; *c*, uninfiltrated alveoli; *d*, new connective tissue infiltrated with small round cells; *e*, cells lining alveoli; *f*, artery showing thickened walls; *g*, desquamated lining cells (Linsley).

in the description are really syphilitic in nature. The process begins, as a rule, at the root of the lungs, from which it radiates

through the tissue toward the pleura. The fibrous tissue, for the most part, surrounds the bronchi and blood-vessels (Fig. 215). In another group of cases the process spreads from the pleura and occasions the formation of dense bands of fibrous tissue passing inward into the lung-structure. In still other cases the fibroid overgrowth is so diffuse that the appearance presented resembles so closely that of pneumonokoniosis, that it is practically indistinguishable. It is quite probable that many instances, in which appearances such as these are met with, are not at all syphilitic; but the occurrence of changes of this description in association with gummata, and, again, the occurrence of such changes without gummata in undoubtedly syphilitic individuals, make it likely that some at least are of this origin and nature.

GLANDERS.

Glanders occasionally affects the pulmonary tissue, the infection taking place either by inhalation from ulcerated lesions in the nose or other portions of the upper air-passages, or more rarely by distribution of the bacilli through the blood. The lesions are of two kinds. There may be merely a grayish or purulent infiltration of a diffuse character, with the formation of abscesses and often with associated hemorrhagic infiltration. Considerable areas of the lung may be consolidated in this manner, or the process may be localized and lobular. In other cases nodular patches varying from the size of a hemp-seed to that of a pea are seen in various parts of the lung. These consist of masses of round cells, and show an early tendency to degeneration. More or less hemorrhagic and catarrhal inflammation of the alveoli surrounding these nodules may be present.

ACTINOMYCOSIS.

Actinomycosis is a rare affection of the lungs. It may result from the direct extension of actinomycosis of the lymphatic tissues and cellular structures in the anterior or posterior mediastinum, when there are formed in the pulmonary tissue fistulous necrotic tracts containing more or less cheesy and purulent material, in which the characteristic yellowish actinomycosis-granules are found. The latter on microscopic study show the actinomyces. The infection may also take place by a gradual descent of the process from the mouth or upper respiratory passages along the trachea and bronchi to the lung; or, more commonly still, by aspiration of the infective agents. In the latter cases nodules consisting of round cells are formed, and present themselves as grayish or grayish-red patches varying in size from that of a pea to that of a cherry, and showing a decided tendency to fatty degeneration and purulent softening. The surrounding lung-tissue

is commonly consolidated, and presents the appearances of purulent and catarrhal or even hemorrhagic pneumonia. In many cases there is also a manifest tendency to productive changes, which lead eventually to the formation of more or less fibrous tissue within the alveoli and in the interalveolar and interlobular connective tissues. Not rarely this indurative process completely surrounds areas of degeneration and softening.

TUMORS.

The lungs are, comparatively speaking, a rare seat of tumors, though a variety of both primary and secondary growths occur.

Connective-tissue Tumors.—Small nodular *fibromata* have occasionally been observed scattered through the lungs in the peribronchial connective tissue, and a few instances of similar nodules of *lipoma* are recorded. *Chondroma* is more common than either of these, and doubtless takes origin from the peribronchial cartilages. Secondary chondromata have been observed in cases of chondroma elsewhere. True *osteoma* is rare, but more frequently ossification of sclerotic areas is met with in instances of pneumonokoniosis.

Sarcoma is the most frequent connective-tissue tumor of the lungs. It may originate in the lymphatic glands surrounding the bronchi in the roots of the lungs, from the lymphatic nodes surrounding the smaller bronchi within the lungs, from the lymphatic vessels themselves, or from the subpleural or other connective tissue of the lung itself. Primary sarcoma is less common than secondary. In one form it presents itself as rounded masses of grayish or yellowish color lying around the bronchi in the root of the lung (Fig. 216). On section through this it is seen to consist of more or less enlarged and transformed lymphatic glands, and there may be secondary nodules scattered through the lung. This form of sarcoma is particularly common in pneumonokoniosis, as seen in the fibroid lungs of the cobalt-miners of Schneeberg. Primary sarcoma may also be of the form called *endothelioma*. The lymphatic vessels in the peribronchial tissue become filled with proliferated cells, and their ramification may be distinctly visible on section as a network traversing the pulmonary tissue. Primary sarcoma of the spindle-cell or round-cell variety may spring from the subpleural connective tissue. Giant-cell sarcoma has been observed.

Secondary sarcoma is extremely common. It is seen in nearly all instances in which metastasis has occurred from a primary growth in any part of the body. In these cases there are found well-defined nodules of varying size, situated for the most part near the surface of the lung (Fig. 217). They are whitish in color and tend to soften. The lung-tissue between may be congested, and there may even be pneumonic consolidation. Secondary sar-

coma of the lung may also occur from direct extension of mediastinal sarcoma or of sarcoma in other of the surrounding structures. An interesting type of secondary sarcomatous involvement of the lungs occurs in what is termed malignant lymphoma or lymphadenoma, either with or without leukemia. These may be considered as instances of generalized lymphosarcoma. The lungs are found to contain small nodules, consisting of round cells embedded in a more or less reticular matrix of stellate and spindle-cells.

Epithelial Tumors.—*Carcinoma* is practically the only form to be considered, though *adenoma* of the lung has been described. Carcinoma of the lung is certainly less frequent than was formerly believed, sarcoma having been confused with it. Massive cancer may start from the mucous glands of the larger bronchi near the root of the lung. The tumor is irregular, soft, and tends to ulcer-

FIG. 216.—Lymphosarcoma of the post-bronchial glands, invading the lung; the lung is divided by a long incision and the halves laid open.

ate in the center, forming cavities. Secondary nodules within the lung-tissue are seen along the lymphatic vessels surrounding the bronchi. Primary carcinoma may also start from the epithelium of the finer bronchial tubes. The proliferation soon penetrates the wall of the bronchus and extends along the lymphatic vessels in the peribronchial connective tissue. In this manner bands of new growth are seen traversing the lung. Occasionally squamous-celled carcinoma may originate in the epithelium of the terminal bronchioles and alveoli.

Secondary carcinoma of the lungs is less frequent than second-

ary sarcoma. It may occur by metastasis from cancer elsewhere, and in these instances the appearance of the nodules is much the same as that of sarcoma. Secondary cancer of the lung may also result from extension of esophageal carcinoma or of cancer of the

FIG. 217.—Secondary sarcomata of the lung: the primary growth was attached to the pleura.

breast penetrating the thoracic walls and pleura. Finally, in carcinoma of the upper respiratory passages or of the mouth inhalation of cancerous particles may lead to secondary nodules in the lungs, associated at times with areas of broncho-pneumonia.

Cysts.—Congenital cysts have been described, but they are probably merely dilatations of the bronchi. Adenomatous proliferation of the epithelial lining of such dilatations may take place. Dermoid cysts are rarely encountered. They may discharge through the bronchial tubes.

PARASITES.

Besides the specific and pathogenic micro-organisms that have been referred to as occurring in tuberculosis, pneumonia, and other infectious diseases, various forms of bacteria and mould-fungi are met with as accidental and non-specific parasites. Such

micro-organismal collections are most frequent in areas of gangrene, in degenerated infarcts, and in dilated bronchi or tubercular cavities. Sarcinæ, a form of leptothrix resembling that seen so frequently in the mouth, and several varieties of aspergillus, have been noted. The general term *Pneumonomycosis aspergillina* is applied to the occurrence of the last-named mould-fungi in the lungs. Sometimes they are so abundant that they are readily discovered in the sputa; and it is likely that certain inflammatory conditions of the lungs are directly due to such organisms. The clinical course may suggest tuberculosis, and pathologically diffuse or irregular consolidation of the lungs may characterize such cases.

Animal Parasites.—Of the lowest forms of animal life or protozoa, the Monas lens, cercomonas, and paramecium have been observed. These are entirely accidental, occurring in cases of gangrene, putrid bronchitis, and similar conditions. The class of vermes furnishes the more important parasitic affections of the lungs. The *Distoma pulmonale* is not infrequent in parts of Asia. It occasions serious hemoptysis. The *Strongylus longevaginatus, echinococcus-cysts,* and *Cysticercus cellulosæ* are occasionally seen. *Pentastomum denticulatum* has been observed.

THE PLEURA.

Anatomic Considerations.—The pleura is a membrane composed of fibrillar connective tissue and elastic fibers, containing a rather abundant network of capillaries. It is lined on the surface with a single layer of flat endothelial cells, between which there are openings from the pleural cavity into the subpleural lymphatics. The latter form a rich network in the subpleural connective tissue and play an important part in the pathologic processes affecting the pleura.

CIRCULATORY DISTURBANCES.

Passive hyperemia occurs in various diseases interfering with the respiration, and still more intensely in cases in which there is pressure upon the azygos veins or diffuse intrathoracic pressure.

Petechial hemorrhages may occur when the congestion is intense. They are particularly frequent and prominent in cases of death from suffocation, but are also seen in various disorders of the blood and hemorrhagic diatheses, such as pernicious anemia, purpura, and intoxications of various kinds.

Hemothorax is the term applied to the presence of free blood in the pleural cavity. It may be due to wounds of the chest-wall, causing rupture of blood-vessels, to fracture of the ribs, and to rupture of aneurysms into the pleural sac. If the pleura is in a

healthy condition and secondary infection does not take place, more or less rapid absorption of the blood ensues. When infection occurs, secondary inflammations of the pleura and disorganization of the blood result.

Hydrothorax, or dropsy of the pleural cavity, may be but a part of a general edema occurring in chronic kidney-disease or heart-disease. It is usually bilateral, and the fluid presents the ordinary characteristics of a serous effusion. Unilateral hydrothorax is, however, not infrequent in cardiac disease attended with great enlargement of the organ. The hydrothorax in such cases is generally right-sided, and is probably due to pressure upon the azygos veins and the root of the right lung. The pleura itself is not particularly disordered, but very frequently some opacity and loss of luster is noted, and there may be edema of the subpleural fibrous tissue. The lungs are pressed backward toward the root and against the spinal column, and may be considerably compressed. Unilateral hydrothorax may be due to pressure upon the veins of one side by tumors or aneurysm. A small amount of serous outpouring into the pleural sacs occurs quite commonly just prior to death.

Hydrothorax causes compression of the lungs and displacement of the other adjacent viscera. The seriousness of the results are in proportion to the amount of effusion.

Pneumothorax designates the presence of air in the pleural cavities. It may result from rupture of tuberculous vomicæ, gangrenous areas, softened hemorrhagic infarcts, or abscesses of the lungs, or rupture of emphysematous air-vesicles beneath the pleura, allowing egress of air into the pleural sac. It may also occur after an empyema has ruptured into the lung and established a fistulous communication between the pleural sac and the bronchioles. Very rarely it is due to a penetrating wound of the chest. The pleural sac may be more or less tensely distended with air; the lung is pushed backward against the spine, is more or less grayish or brownish in color, indurated and airless. The pleura itself may present no abnormality, and the air may be absorbed; but very frequently infection takes place, and purulent exudation from the pleura collects in the sac. The condition is then spoken of as *pyopneumothorax.* The neighboring organs are often greatly displaced, particularly the heart, the diaphragm, and the liver. In left-sided pneumothorax the heart may be pushed far to the right of the sternum, and when the right side is affected the liver may be pushed downward considerably below the ribs.

INFLAMMATION.

Inflammation of the pleura, or **pleuritis,** is designated by the clinical name *pleurisy.*

Etiology.—It may result from local or from general causes. Among the local causes the most important are extension of inflammation from the lungs in the various forms of pneumonia, in gangrene and tuberculosis; extension from pericarditis or mediastinal diseases, and extension from inflammatory affections of the spine, of the ribs, or of the chest-walls. Less directly peritonitis, hepatic abscess, and other abdominal affections may occasion pleuritis by extension, and in rare cases perforation of esophageal or gastric ulcers, or abscess of the spleen or liver, may be the cause.

In the group of cases due to general causes the pleural inflammation is the result of infection or intoxication involving the pleura through the blood. Thus in pyemia and septicemia, in rheumatism, and in other acute infectious diseases, and in Bright's disease, acute inflammation of the pleura is not uncommon. Cold and traumatism have long been regarded as important causes, but their action is doubtless only a predisposing one, the immediate cause being some infection for which the traumatism or the exposure to cold has paved the way.

The micro-organisms found in pleurisy are quite numerous. In the cases secondary to ordinary pneumonia, pneumococci are frequently discovered, and these micro-organisms may be present even though there be no pneumonia at all. In the instances secondary to tuberculosis of the lungs, as well as sometimes in cases of primary pleurisy without affection of the lungs, tubercle-bacilli are discovered. In the purulent cases, as well as in some instances of simple fibrinous or serofibrinous pleurisy, staphylococci and streptococci are detected. When there is abundant liquid it is always difficult to discover the micro-organisms, and in many instances in which bacteria have not been found, it is probable that the difficulty of their demonstration, even by animal experimentation, accounts for the failure to demonstrate them, rather than their absence. A number of forms have occasionally been seen, such as the Bacillus coli communis, the typhoid bacillus, the bacillus of anthrax, and others.

Pathologic Anatomy.—Several forms of pleuritis may be recognized, though one of these merges into the other, and a single case may pass from one into another form at its various stages. It is well, however, to separate these stages as distinct forms, since many cases maintain a uniform character throughout. The forms are the *fibrinous*, *serofibrinous*, *purulent*, and *hemorrhagic;* after any of these forms there may be left chronic pleural thickening or adhesions of a fibroid character.

Fibrinous pleuritis begins with congestion and loss of luster of the pleural surface, after which there soon follows exudation of a fibrinous character, forming a thin, whitish pellicle on the surface. This may become yellowish and increase in thickness, so

that the pleural surfaces become agglutinated, and when separated present an appearance likened to the appearance of two pieces of buttered bread separated after having been pressed together (*bread-and-butter pleurisy*). This process may be confined to small areas of the pleura, or it may be quite universal. Sometimes it is limited to the reflections of the pleura separating the lobes of the lung.

Microscopically the exudate consists of fibrils or flakes or granular masses of fibrin more or less infiltrated with round cells. Beneath this the endothelium of the pleura is found to be somewhat thickened by proliferation and some of the cells are detached. The connective tissue beneath the endothelium and the subpleural connective tissue are infiltrated with round cells and the blood-vessels are hyperemic. In favorable cases and when the process has been slight a gradual reabsorption of the exudate takes place, and the integrity of the pleura may be restored completely. When the exudate has been more extensive and the agglutination of the pleural surfaces has been considerable, new blood-vessels from the capillaries of the pleura penetrate the fibrinous exudate, fibroblastic cells develop from the older connective-tissue cells, and gradually organization takes place, so that the adjacent layers of pleura are bound together by connective tissue, the fibrinous exudate gradually undergoing absorption and disappearing. The adhesions thus formed are at first delicate and quite cellular, but are later converted into dense, sclerotic bands. When fibrinous pleurisy occurs repeatedly, as in tuberculosis of the lungs, and is not sufficiently extensive to cause adhesions, the surface of the pleura may become thickened and opaque in spots from proliferation of the connective tissue. In this way considerable chronic thickening of the pleura may ensue.

Serofibrinous pleuritis may be simply a further stage of the foregoing form, though in many instances it begins almost at once as a serous exudation into the pleural sac. The liquid is heavier than dropsical fluid and contains flakes and shreds of fibrin. Microscopically it is found to contain white and red blood-corpuscles in small numbers, and occasionally detached endothelial cells. Sometimes the number of red corpuscles increases considerably, and there may be a gradual transition to the hemorrhagic form of pleuritis. The amount of liquid varies from a few cubic centimeters to several liters; and the pleura itself shows a more or less extensive coating of fibrinous exudate. The lung is pressed backward, as in pneumothorax or hydrothorax, and the adjacent organs are similarly displaced.

Purulent pleuritis, or **empyema**, or **pyothorax**, is always the result of micro-organismal infection. The process may begin as a purulent pleuritis, or as a primary serofibrinous pleurisy, second-

ary infection occurring either from within the body or through infected aspirating-instruments from without the body. When a transition of the latter kind occurs the exudate is seen to become more and more turbid; the number of pus-corpuscles gradually increases until the liquid is quite purulent. Spontaneous discharge of empyema most frequently takes place through the lung and bronchi. More rarely rupture occurs through the chest-walls anteriorly between the ribs. When rupture has occurred through the lung and bronchi the fistulous communication may remain open and pneumothorax may ensue.

The pleura in empyema shows more or less abundant granulations, which in case of discharge of the liquid serve eventually to unite the costal and pulmonary pleura by firm fibrous adhesions. Occasionally the pus may be completely absorbed, or it may undergo gradual inspissation, remaining as a more or less cheesy detritus, which may finally become calcareous. Such terminations, however, are rare.

Hemorrhagic pleuritis is generally the result of tuberculous infection or of malignant disease of the lungs and pleura. Pleuritis may also take a hemorrhagic form in old and cachectic individuals, or in persons suffering from scurvy, purpura, and similar diseases. As a rule, the liquid is serous, with considerable admixture of blood, but in tuberculous and malignant pleuritis it is sometimes well nigh pure blood.

Associated Lesions in Other Parts.—Though pleuritis is frequently the result of acute or chronic affections of the lung, it often occasions secondary disorders in the latter organ. The subpleural lymphatics are commonly distended with cells, and the inflammatory process may extend for considerable distances along these channels into the interlobular septa of the lung. In empyema the resulting purulent lymphangitis and perilymphangitis lead to striking pathologic appearances (see Pneumonia). The lung also suffers from direct pressure in serous and purulent pleuritis. If the compression to which it is subjected is not relieved by absorption of the liquid, or by its removal by aspiration, the alveolar epithelium degenerates and proliferative inflammation takes place in the connective tissue, so that a permanent contraction of the lung results. The removal of the liquid at this stage is not followed by the return of the lung to its proper size and function. On the contrary, the removal or absorption of the liquid in these cases, especially when they occur in young children, causes a sinking in of the ribs and curvature of the spinal column, and the heart and other adjacent organs may be permanently displaced. Most remarkable deformities of the chest may occur. Less extensive contraction of one side of the chest, or displacement of the heart, may result from the contraction of bands of adhesions, without marked collapse of the lung.

INFECTIOUS DISEASES.

Tuberculosis of the pleura, or tuberculous pleuritis, may be either primary or secondary. Cases of the former are comparatively rare. In most instances the pleural disease is secondary to tuberculosis of the lungs, or to tuberculosis of other adjoining parts. Hematogenic infection may occur under the same conditions as hematogenic infection of the lungs, and frequently the lungs and pleuræ are studded with miliary tubercles at the same time.

When the pleural disease is secondary to tuberculosis of the lungs the appearances vary considerably. In many cases small gray or yellow tubercles are found in the subpleural connective tissue and in the pleura, and the surface may be coated with fibrinous exudate, while the cavity of the pleura may be more or less distended with serofibrinous, hemorrhagic, or purulent liquid. Not rarely the liquid effusions are reabsorbed and dense adhesions are formed, or great thickening of the pleura results. Sometimes considerable calcification of the thickened pleura and of the inspissated exudate is the terminal result. The tubercle-bacilli are often difficult to demonstrate in the liquid, even by injections into animals, though they may be present in the pleura itself.

Syphilis of the pleura is a doubtful condition. Fresh pleuritis may be found in the neighborhood of a syphilitic gumma; and there are cases of considerable pleural thickening in syphilitic persons in which the disease may possibly be syphilitic, though in these cases, as in similar indurative conditions in the lungs, there is considerable doubt as to the essential nature of the disease.

TUMORS AND PARASITES.

Tumors of the pleura are comparatively rare. *Fibromata* and *lipomata* are occasionally seen as small nodular masses in the serous or subserous coat of the costal or visceral pleura. *Chondromata* and even *osteomata* have been observed. More frequently calcification and ossification of portions of the thickened pleura take place after pleuritis.

Primary *sarcoma* may spring from the subpleural connective tissue, and, according to Coats, is especially common in children, and is most frequently of the spindle-cell variety. Primary *endothelioma* of the pleura has been studied by a number of investigators. In a case under my observation it presented itself as a more or less uniform thickening of the pleura of one side, involving the diaphragmatic reflection in particular. The cavity was filled with hemorrhagic fluid, and there were some nodular enlargements on the surface (Figs. 218 and 219). This is the usual appearance presented. Metastasis may occur in the lung beneath the diseased pleura, or even in more distant parts.

FIG. 218.—Endothelioma of pleura: the pleural cavity was distended with effusion, and the lung was compressed and invaded by secondary nodules.

FIG. 219.—Microscopic section from the preceding illustration.

Secondary tumors of the pleura may occur by metastasis or by direct extension. In the former manner *sarcomata* and *carcinomata* sometimes involve this structure; by the latter method of

involvement mammary tumors and new growths of the mediastinum, the ribs, or other adjacent structures may extend to the pleura.

Parasites.—Echinococcus cysts may originate in the subserous connective tissue of the costal or the visceral pleura, and may rupture into the pleural cavity. Psorospermiæ have been found in pleural effusions. The Amœba coli has been found in the pus of empyema following hepatic abscess.

CHAPTER V.

DISEASES OF THE GASTRO-INTESTINAL TRACT.

THE MOUTH.

CONGENITAL ABNORMALITIES.

THE most frequent defects in the development of the mouth are *cleft palate* and *harelip*. In the former of these the entire hard palate may be divided, generally to one side of the middle line; and there may be associated harelip and fissure of the soft palate. Anteriorly the division occurs between the superior maxillary bone and the intermaxillary bone, the fissure of the lip being also to one side and often extending into the nostril. The soft palate is divided along the middle line, and the uvula may be separated into lateral halves. The lip may be cleft on both sides, so that there is a small central portion connected with the septum of the nose and separated from the lateral portions of the lip. Harelip is more frequently unassociated with cleft palate.

Complete absence of the lips; or unusual shortness, especially of the upper lip; excessive largeness of the mouth by extension of the fissure outward toward the ear; and imperfect development of the lower jaw-bone, are rare congenital conditions.

CIRCULATORY DISTURBANCES.

Anemia of the mucous membranes of the mouth is seen in cases of general anemia, and is often one of the most striking evidences of that condition. It is particularly noticeable in the lips.

Hyperemia.—*Active hyperemia* occurs in the early period of various inflammations, while *passive congestion* is met with as the result of obstruction of the circulation in pulmonary and cardiac diseases.

Hemorrhages in the form of small petechiæ occur in purpura and other hemorrhagic diseases, and sometimes in infectious fevers.

INFLAMMATION.

Inflammation of the mucous membrane of the mouth is termed *stomatitis;* inflammation of the tongue is designated by the name *glossitis.*

Stomatitis may be of varying character and intensity.

Catarrhal stomatitis may result from direct irritation by hot liquids or chemical substances, or may occur in depressed conditions of the general system, possibly as a consequence of infection. It is more common in children than in adults. The mucous membrane of the mouth is red and usually covered with considerable liquid exudation. When the inflammation is intense small vesicular cysts may form from distention of the mucous glands, and even localized erosions may appear. When the inflammation has continued for a long time, or has been repeated, there may form upon the surface silvery-white, slightly elevated spots, which result from a hyperplasia of the epithelium, a form of *keratosis.* This condition has been designated by the name of *leukoplakia.*

Mild catarrhal conditions of the mucous membrane of the mouth are especially common on the tongue, the epithelium of which constantly desquamates. In the course of gastro-intestinal and other diseases the desquamation may be more active, the cells, however, being retained upon the surface. Portions of food and bacteria cling to the masses of desquamated cells, and in this manner the whitish or brownish *furring of the tongue* so commonly met with in various diseases is formed. Sometimes the heaping of epithelial cells takes place in localized areas, and extends in peculiarly irregular patches, which, from their resemblance to maps, have given rise to the term "geographical tongue." In chronic cases the whitish spots of leukoplakia alluded to above are formed. Psoriasis of the tongue presents lesions analogous to those of the skin.

Aphthous stomatitis occurs in children under conditions of malhygiene and debility, or as a result of gastro-intestinal and other diseases. Local irritation often plays an important part. There appear in the mucous membrane, especially of the lower lip and gums, small whitish spots lying upon an inflamed base. Usually these are separated, but sometimes confluence occurs, though there is rarely extensive spreading. The whitish membrane covering or constituting the spots is composed of degenerated epithelium; and sometimes of fibrin, so that the term croupous stomatitis may in some cases be applied. The lesions are superficial and rarely lead to actual ulceration. It has been held

that the preliminary lesion is a vesicle; this, however, does not appear to be frequent, and is certainly not essential.

Foot-and-mouth Disease.—A similar affection occurs in animals, particularly in cows, sheep, and goats, and is designated foot-and-mouth disease. This condition is contagious, and considerable epidemics have occurred among persons drinking the milk of infected animals. The specific cause is unknown, though several micro-organisms have been described.

Bednar's aphthæ are small ulcers found in the mouths of sucking infants and situated at the lateral portions of the palate over the ends of the pterygoid processes, on other parts of the hard palate, or occasionally on the soft palate. They are probably caused by traumatism occurring in the act of sucking.

Ulcerative stomatitis may be met with in various parts of the mouth, especially in the gums. In young children it is frequently the result of malnutrition and lack of cleanliness of the mouth. In various cachectic diseases, particularly in scurvy, the gums become soft and spongy and tend to ulcerate. Mercuric and other forms of poisoning may lead to extensive ulcerations. Deeper ulcerations are found upon the sides of the tongue or the inner part of the lip in cases of injury due to the sharp edges of broken or carious teeth. Ulcerative stomatitis may be secondary to necrotic conditions of the bones or suppurative inflammations about the roots of teeth. Ulceration beneath the tongue is met with in many cases of whooping-cough, and is due to the irritation of the teeth in the paroxysms of coughing.

In ordinary cases of ulcerative stomatitis the gums at the junction with the teeth become reddened and soft, and may present hemorrhagic infiltration. Later the epithelium of the surface is destroyed and open ulcers result. Considerable suppuration may occur, and the teeth may be loosened and dislodged.

Pseudomembranous stomatitis is most frequently due to the action of the bacillus of diphtheria, and is therefore, strictly speaking, diphtheria of the mouth. It is usually secondary to pharyngeal diphtheria, but may occur primarily upon the lips or other parts of the mouth. In some cases of aphthous stomatitis the lesion is in reality a pseudomembranous one.

Phlegmonous stomatitis is more common in the lips than in other parts of the mouth, and may be the result of traumatic injuries with intense infection, or a secondary condition after facial erysipelas or other cellular inflammations of the face. The lips and cheeks may be greatly swollen, and suppuration may occur, forming abscesses which tend to rupture into the mouth. A chronic form of inflammation of the deeper tissues of the lips may lead to hypertrophy. This is especially common in the upper lip as the result of long-standing coryza or eczema.

Gangrenous stomatitis, or **noma,** affects the mucous membrane

of the cheeks, and occurs in ill-nourished children, especially after measles and other infectious fevers. There is formed a sloughing ulcer on the inner side of the cheek, and inflammatory induration involving the entire thickness of the cheek. The skin at first presents a dark-red or bluish discoloration, and later extensive destruction (gangrene) may occur (Fig. 220). The pathologic

FIG. 220.—Case of noma (Children's Hospital).

changes are those of a rapid necrosis of all the tissues, and micro-organisms of suppuration or other saprophytes are usually present. Putrefactive changes cause a fetid odor. Intense septic infection and intoxication generally attend.

Associated Conditions in Stomatitis.—In many cases the inflammation may extend from the mucous membrane of the mouth posteriorly to the pharynx. Very commonly the lymphatic glands of the neighborhood are involved, and enlargement of the submaxillary or even the cervical glands is commonly observed. In some cases, especially in mercurial stomatitis, the salivary glands are coincidently or consecutively swollen and inflamed. Increased flow of saliva (ptyalism or sialorrhea) is a frequent symptom. In intense cases, especially in gangrenous stomatitis, parenchymatous degenerations of other organs may result from general toxemia.

Glossitis.—Superficial catarrhal inflammations have been referred to. More extensive inflammations of the tongue, leading

to *parenchymatous glossitis*, may result from injuries, especially when accompanied by infection. The entire organ may in these cases be swollen, and there is round-cell infiltration with a tendency to suppuration. Localized parenchymatous glossitis with ulceration may occur from injury by carious teeth.

Hemilateral glossitis, sometimes attended with the formation of herpetic vesicles, is occasionally observed, and is probably dependent upon diseases of the chorda tympani nerve.

ATROPHY AND DEGENERATIONS.

Atrophy of the muscles of the tongue and cheeks may occur in association with nervous diseases (bulbar palsy). Physiologic atrophy of the gums follows loss of the teeth in old age.

Degenerations of the mucous membrane usually accompany inflammations.

Under the name of *nigrities*, or *black-tongue*, is described a form of hypertrophy of the papillæ of the tongue with pigmentation. The dorsum of the tongue may be covered with a hair-like coating of dark-brown or blackish color. The cause of this affection is obscure.

INFECTIOUS DISEASES.

Thrush, or **parasitic stomatitis,** is met with in young children, and is due to the action of a micro-organism now generally known as *Saccharomyces albicans*. There are formed upon the mucous membrane white patches resembling curdled milk, and varying in size from mere points to large areas. These tend to coalesce and to spread. The mucous membrane is reddish and inflamed. The back and sides of the tongue and the inner parts of the cheeks are favorite seats. Microscopically the white coating is composed largely of mycelial threads of the parasite, with which are mingled degenerated epithelial cells and generally also other micro-organisms, notably micrococci. The process may extend to the pharynx, and sometimes as far as the bronchi or the stomach, through the larynx and esophagus.

Tuberculosis of the mouth may be primary or secondary. The latter is especially frequent on the root of the tongue, and is secondary to tuberculosis of the larynx or pharynx (Fig. 221). Small nodular masses of tubercle are formed, and tend to undergo cheesy desquamation, forming ulcerated areas. Primary tuberculosis leading to ulceration may occur upon the lips or upon the tongue as a result of direct inoculation, as in the kissing of a tuberculous person. Nodular masses are formed, which at first present themselves as papillary elevations, but subsequently undergo characteristic necrosis. The injury of the tongue by the

teeth, and the favorable soil offered for the retention and multiplication of the micro-organisms in carious teeth, may play a part in the causation.

Syphilis is most frequently secondary, occurring in the form

FIG. 221.—Tubercle of the tongue (Karg and Schmorl).

of mucous patches upon the lips or tongue. Gummatous infiltration may appear in a localized form, or as an irregular involvement. Fissuration and deformity of the tongue may result. The primary

FIG. 222.—Actinomycosis of the cheek (Illich).

syphilitic lesion (chancre) resulting from direct inoculation is rarely observed.

Actinomycosis affects the tongue, gums, and jaw-bone, and is characterized by a slowly infiltrating process with a tendency to necrosis and suppuration, in which the alveolar processes of the jaw-bone are generally attacked. The lesion in the mouth may be insignificant, while the secondary involvement of the cheeks, or of the lymphatic glands below the jaw and in the neck may be extensive (Fig. 222).

TUMORS.

Cystic formations, due to agglutination of the mouths of the mucous glands, are met with upon the tongue and lips. *Papillomatous growths* of the mucous membrane are also occasionally observed. *Fibroma*, *lipoma*, *myxoma*, and even *chondroma* are rare forms of tumors of the submucous tissue of the tongue or other parts of the mouth. Not rarely they are congenital. *Lymphadenoma* or *lymphosarcoma* may occur at the root of the tongue, where it takes origin from the lymphatic follicles or the lingual tonsil. *Sarcoma* of other parts of the mouth is rare, excepting as an extension from sarcoma of the jaw-bone and other parts.

Carcinoma is the most important new growth of the mouth, and in nearly all cases is of the squamous-celled variety. The favorite seats are the lower lip, usually toward one side of the mouth, and the tongue. It appears as an irregular nodular elevation which tends to ulcerate upon the surface and spreads to adjacent structures. Metastasis usually occurs to the submaxillary and cervical lymphatic glands.

Nodular masses having the structure of the normal thyroid gland may be found at the base of the tongue.

Cysts are especially frequent beneath the tongue, at the sides of the frenum. These have been termed *ranula*, and are formed by the dilatation of the ducts of the small mucous glands. At times ranula may be a cystic dilatation of a duct of the sublingual salivary gland or that of a submaxillary gland. Ranula is usually found as a rounded or elliptical tumor which may fill the floor of the mouth and displace the tongue backward and upward. The contents consist of somewhat gelatinous albuminous liquid.

Hemangioma, both of the teleangiectatic and cavernous varieties, is occasionally seen, but a more important tumor is *lymphangioma* affecting the tongue and lips, and giving rise to the conditions known as macroglossia and macrocheleia. In these conditions there is a uniform enlargement of the tongue or lips, and on section distended lymphatic spaces more or less filled with liquid and round cells are detected. Such enlargements are usually congenital, and are especially met with in cretins.

THE TEETH.

Anomalous Development.—Unnatural largeness, or, on the contrary, lack of development, is frequently observed. Complete absence of the teeth has been noted. Numerical increase or decrease is frequent. Delay in the eruption of the teeth and irregularity in their formation occur in rachitis; and a form of maldevelopment of the upper central incisor teeth of the permanent set is observed in cases of congenital syphilis (*Hutchinson's teeth*). The characteristics of this condition are the wedge-shape of the teeth, the cutting-edge being smaller than the crown, and the concave notching of the cutting-edge (see Fig. 106). Hutchinson's teeth are not entirely peculiar to congenital syphilis.

Caries of the teeth results from malnutrition, digestive disturbances, and lack of cleanliness. Micro-organisms which lead to acid fermentation contribute in the causation by forming acids which soften the enamel and occasion fissures through which other bacteria (bacilli and micrococci) may gain entrance into the channels of the dentin. The *Leptothrix buccalis* is commonly found in the deposit upon the teeth, but is probably non-specific.

The carious process consists in a gradual disintegration of the enamel and dentin, with the formation of more or less granular detritus in which bacteria are abundant. The process may penetrate to the pulp of the teeth and set up a secondary inflammation, or pulpitis. Occasionally caries of the teeth begins within.

Inflammation of the pulp of the teeth may occur in association with caries, or sometimes independently. The pulp becomes reddened and swollen, and may present hemorrhages and, later, suppuration. The inflammatory process tends to spread through the roots of the teeth to the tissues surrounding the roots and to the alveolar periosteum. Abscesses may thus be formed about the teeth, and may spread to the tissue of the gums (*alveolar abscesses*), eventually rupturing upon the surface.

Tumors composed of tissue resembling the normal dentin are spoken of as *odontomata*. They arise from the pulp during the process of development and form irregular outgrowths of the crown or roots. Similar outgrowths, resembling the enamel or dentin, or cement-substance, are more frequent in later life, and have been designated as *odontinoids*.

Sarcomata and *fibromata* may spring from the pulp during the development of teeth or from the connective tissue about the roots; and *polypoid outgrowths* (hypertrophied granulations) from the pulp may be met with in association with caries of the teeth and pulpitis.

The most important tumor is the *giant-celled sarcoma* of the alveolar process of the jaw. This is known by the name of epulis, though strictly speaking the term is applied rather to the

situation than to the kind of tumor. Extensive enlargements of the jaw-bone and destruction of the surrounding tissues may ensue.

Cysts are met with in the alveolar processes, and arise from the primary follicles in which the teeth are developed.

THE PHARYNX AND TONSILS.

CIRCULATORY DISTURBANCES.

Anemia of the soft palate and other portions of the pharynx occurs in general anemia and in cases of phthisis or other wasting diseases. The mucous membrane may be decidedly pallid.

Active hyperemia or congestion occurs in the beginning stages of inflammation and when irritants have been in direct contact with the mucous membranes.

Passive hyperemia is seen in heart-disease, emphysema, phthisis, and other chronic pulmonary affections. In these cases the mucous membrane is dark red, and not rarely becomes somewhat edematous.

Edema of the pharyngeal tissues is found in association with inflammatory affections, and may occasion considerable stenosis.

Hemorrhages may be the result of direct injury, as in the swallowing of fish-bones and the like, or may occur in the form of petechiæ in purpura and other hemorrhagic diseases and in intense infections (small-pox, septicemia).

INFLAMMATIONS.

Catarrhal pharyngitis, or **angina,** may affect the entire lining membrane of the pharynx, or may be limited to the tonsils or other parts. It results from direct irritation by hot liquids or chemical substances, from exposure to cold, and particularly from infections. Angina, or sore-throat, is met with in many of the infectious fevers, or may appear as an independent infection.

The mucous membrane presents a bright-red color, is somewhat swollen, and covered with tenacious exudation composed of mucus and desquamated cells. Small vesicular elevations may form, and after the rupture of these erosions or even superficial ulcers are sometimes seen. Occasionally there are hemorrhagic extravasations.

A form of catarrhal pharyngitis, known as *herpetic angina*, is analogous to herpes of the skin, and may accompany facial or labial herpes.

Chronic catarrhal pharyngitis is met with in persons who use the voice excessively, especially in the open air. It may also result from the abuse of tobacco or alcohol. The posterior wall of the pharynx and the pillars of the soft palate are particularly involved. The mucous membrane is swollen in the earlier stages,

but later becomes atrophic, and is marked by slight granular elevations, which are either hyperplastic lymph-follicles or distended mucous glands. The veins in the submucous tissue are enlarged, and are visible through the atrophic mucous membrane as tortuous channels. Chronic hyperplasia of the tonsils and chronic laryngitis are frequently associated.

Phlegmonous pharyngitis may result from wounds of the pharynx, or may be associated with intense infections, such as pseudomembranous tonsillitis and pharyngitis, particularly the forms due to streptococci. It may result from pustular pharyngitis in smallpox, or from glanders of the pharynx. Phlegmonous tonsillitis sometimes extends to the peritonsillar tissues as far as the retropharyngeal wall.

The soft palate, uvula, arches, or other parts affected are swollen and tensely distended. There may be congestion or deep cyanosis and edematous exudation. The usual termination is suppuration, but sometimes gangrenous necrosis ensues. General septicemia is frequently the result.

Retropharyngeal Abscess.—Phlegmonous pharyngitis primarily affecting the retropharyngeal tissues may be due to caries of the cervical vertebræ; occasionally it occurs in the infectious fevers in consequence of embolism.

Pseudomembranous pharyngitis may be caused by the *Bacillus diphtheriæ* and be truly diphtheritic, or it may be due to a variety of other micro-organisms, or to irritating gases, steam, and like causes. Non-diphtheritic pseudomembranous pharyngitis is especially common as a complication of scarlatina, measles, and other infectious diseases, and seems in these cases to be caused by the Streptococcus pyogenes. The appearance of the throat may be identical with that observed in diphtheria, but extensive necrosis is more common, while typical pseudomembranes are less frequent.

The mucous membrane and the underlying parts, especially the tonsils, become greatly swollen and edematous; and subsequently suffer necrotic changes.

There is formed upon the surface of the throat a whitish or yellowish patch, or several patches, which tend to coalesce and extend from the region of the tonsils to the pillars of the fauces and the uvula, or to the mouth, nose, or larynx. The pseudomembrane is quite firmly attached to the mucous membrane, and cannot be removed without tearing away part of the underlying tissues. Microscopically the deposit is found to consist of granular or fibrillar fibrin entangling more or less degenerated leukocytes and epithelial cells. In the deeper layers intense congestion and round-cell infiltration are observed; in the superficial strata degenerated cells and detritus, together with masses of bacteria, are conspicuous.

The neighboring lymphatic glands, notably those below the angle of the jaw, enlarge and may suppurate, and sometimes extensive cellulitis and suppuration of the floor of the mouth (Ludwig's angina) occur. There are intense systemic intoxication and infection, and secondary lesions are frequently developed in various organs (nephritis, myocarditis, etc.). The non-diphtheritic forms of pseudomembranous pharyngitis may be distinguished from the diphtheritic forms, in typical cases, by the greater intensity of the local (necrotic) processes, the earlier and more marked involvement of the local lymphatic glands, and by the greater tendency to nephritis; but unfortunately atypical cases are very common, and an absolute diagnosis can be made by bacteriologic study alone.

Tonsillitis may be a part of a general pharyngitis, or it may occur as an independent affection. Several varieties are described.

Catarrhal tonsillitis results from the same causes as catarrhal pharyngitis in general, and presents similar appearances. The tonsils are usually somewhat enlarged.

Lacunar or **follicular tonsillitis** occurs from similar causes, and may involve the normal tonsil or one affected by chronic hypertrophy. The surface of the tonsil is marked with small white or yellowish spots, into which the end of a probe may be inserted. These are the lacunæ or crypts distended with epithelial cells more or less degenerated. Bacteria of various kinds may be found in the contents of the lacunæ, and doubtless play an important part in the etiology. Staphylococci, streptococci, pneumococci, tubercle-bacilli, and the bacillus of diphtheria have all been observed. The latter two forms may be present merely as accidental associations, but may possibly play an etiologic part,

FIG. 223.—Crypts in cases of tonsillitis: A, acute lacunar; B, chronic hypertrophic: *a*, surface-epithelium; *b*, accumulated contents of crypt; *c*, lymphoid follicles surrounding crypt (Kaufmann).

especially the Bacillus diphtheriæ. Ulceration may occur in the walls of the lacunæ, and the surface of the tonsil may be considerably broken down. In other cases the bacteria may penetrate the tonsil at the bottom of the lacunæ, and *phlegmonous tonsillitis*, or *quinsy*, may result (see below). The contents of the lacunæ may be discharged upon the surface, and may adhere for a time as a yellowish-white caseous pellicle, resembling diphtheritic pseudo-

membranes in appearance. In other cases the contents of the crypts are retained, undergo inspissation, and may even calcify. A certain amount of catarrhal pharyngitis may be associated, but the follicular ulcers are rarely seen beyond the tonsils.

Enlargement of the submaxillary and cervical lymphatic glands is commonly observed. General septicemia of mild type is not infrequent; myocarditis, endocarditis, and nephritis may result. The association of tonsillitis and rheumatism has occasioned much discussion. It is very probable that rheumatism frequently results from tonsillitis, the latter being the first effect of micro-organismal invasion, which eventually causes rheumatism.

Chronic tonsillar hypertrophy may result from repeated attacks of simple catarrhal or of follicular tonsillitis. The tonsils are enlarged, usually irregularly so, and are harder than normal. On section the connective-tissue reticulum and septa are found increased, and the lymphoid follicles are likewise hyperplastic. Pressure upon the orifices of the lacunæ not rarely causes obstruction and repeated attacks of lacunar tonsillitis. Retention and calcification of the contents of the crypts are particularly common in the lacunar tonsillitis of hypertrophic tonsils. Chronic hypertrophy of the tonsils very often occurs in rachitic or badly nourished children in association with hyperplasia of the lingual tonsil and nasopharyngeal adenoid tissues. Distinct evidences of inflammation are wanting in such cases, and the condition seems rather a form of simple hyperplasia of the lymphoid structures.

Phlegmonous tonsillitis, abscess of the tonsil, or **quinsy,** may be the result of simple catarrhal or of follicular tonsillitis, or may be associated with phlegmonous inflammation of other parts of the pharynx. One or both of the tonsils may be affected. Redness and swelling are noted in the earlier stages, but later the mucous membrane is pallid or even yellowish. Microscopically diffuse round-cell infiltration and eventually focal collections leading to abscess-formation are detected. The peritonsillar tissues may be involved, and spreading phlegmonous inflammation results. Rupture may take place into the pharynx, or the ulceration may extend outward, causing discharge upon the neck at the angle of the jaw. The internal carotid artery may be perforated.

PRESSURE-NECROSIS.

This condition occurs upon the anterior and posterior walls of the pharynx, opposite the cricoid cartilage. It is met with in marantic persons occupying a dorsal decubitus, and is caused by the backward pressure of the cricoid cartilage against the opposite vertebra. The mucosa becomes necrotic, and more or less extensive ulcerations are formed. Complete perforation of the pharyngeal wall sometimes occurs.

INFECTIOUS DISEASES.

Diphtheria of the pharynx usually begins in the mucous membrane covering the tonsils, and spreads to the pillars of the fauces, to the uvula, the posterior wall of the pharynx, the cheeks and tongue, the posterior nares, or to the larynx. It rarely invades the esophagus, but may sometimes extend along this structure as far as the stomach.

The specific cause is the Bacillus diphtheriæ (see Diphtheria, Part I.). The characteristic lesion is a pseudomembrane, which is formed on the surface and within the mucous membrane. This first appears as a grayish or yellowish-white pellicle, more or less firmly attached to the mucosa; it spreads rapidly, and may cover the whole of the pharynx in a day or two. In other cases the disease progresses slowly, or remains quite limited. The underlying tissues become swollen by inflammatory infiltration (cellular and edematous), and swallowing and breathing may then be greatly obstructed. When the pseudomembrane is removed from the surface a raw and more or less necrotic base is exposed. Microscopically the surface of the pseudomembrane is found to consist of a mass of débris, often containing micrococci and other bacteria, as well as the specific organisms, in great numbers. Somewhat more deeply the membrane is composed of a fibrinous reticulum or masses of fibrin entangling degenerated epithelial cells and leukocytes. Still more deeply the tissues of the pharynx

FIG. 224.—Pseudomembranous inflammation of the uvula: *a*, masses of micrococci; *b*, necrotic cells; *c*, round-cell infiltration; *d*, fibrin network (Ziegler).

are found intensely congested and infiltrated with round cells (Fig. 224). In the late stages of the disease extensive necrosis of the mucosa and submucosa may occur.

In some cases diphtheria may undoubtedly present the lesions of an ordinary lacunar tonsillitis, and the clinician may be unable to determine the nature of the disease.

Associated Conditions.—Some enlargement of the lymphatic glands at the angle of the jaw is usual, and exceptionally this may terminate in suppuration. Lesions of the internal organs, especially the heart and kidneys, are not infrequent, and disease of the peripheral nerves is a common sequel (see Diphtheria, Part I.).

Pharyngomycosis Leptothricia.—This condition is met with on the tonsils, and less frequently the pillars of the fauces, uvula, and other parts of the pharynx. It occurs in persons of lowered vitality, and seems to be caused by the *Leptothrix buccalis*, a form of bacterium very commonly met with in the collections around the necks of the teeth. The lesions present themselves as milky-white and somewhat chalk-like outgrowths arising from the tonsillar crypts and the mucous glands. These are often tightly adherent, but occasion very little inflammation of the surrounding tissues. Microscopically the thread-like parasite is found in abundance.

Tuberculosis may occur in the pharynx in the form of subepithelial tubercles, which break down and occasion more or less extensive ulcerations.

Tuberculosis of the tonsils may be primary or secondary. In the former case infection probably occurs from the invasion of the crypts by tubercle-bacilli; this condition is doubtless more common than has generally been supposed. Secondary tonsillar tuberculosis usually follows tuberculosis of the lungs or larynx. In either case there are formed in the tonsils small tubercles which rapidly increase in size, fuse, and subsequently undergo caseous change. Discharge of the caseous matter upon the mucous surface is not unusual, and occasions ulcer-like formations. Secondary infection of the cervical and submaxillar lymphatic glands is not infrequent.

Syphilis may occur in the pharynx in the form of the primary lesion or chancre, as mucous patches, or as gummata. The last are prone to undergo ulceration with secondary cicatrization. Extensive distortion of the pharyngeal structures may be the result of the scar-formation.

Glanders and **lepra** sometimes invade the pharynx.

Typhoid ulcers are occasionally met with.

TUMORS.

Among the tumors of the pharynx, fibroma, lipoma, chondroma, and papillomata are occasionally found on the soft palate, uvula, or tonsils. Of the malignant tumors, sarcoma of the tonsils is most important. It is usually of the lymphosarcomatous variety,

and is rapid in growth and highly destructive. Epithelioma may occur at the base of the tongue, in the soft palate, or tonsils. Other varieties of cancer are rare.

Polypoid tumors of the nasopharynx and hyperplastic adenoid growths of the same situation frequently extend downward into the pharynx proper.

THE SALIVARY GLANDS.

Inflammation of the salivary glands affects the parotid most frequently.

Parotitis may be the expression of an independent infection (mumps); or may be secondary to various infectious diseases, such as typhoid fever, typhus fever, or pyemia.

The specific cause of mumps has not been isolated (see Part I.). The infection probably occurs through the parotid duct, and in some instances inflammations of the mucous membrane of this duct have been found to precede the parotitis. The gland is swollen and tensely distends its capsule. The inflammatory exudate is probably largely serous, as it may be absorbed and removed in the course of a very short time. The disease scarcely ever terminates in suppuration. Orchitis is an occasional complication.

The secondary parotitis occurring in the course of various infectious diseases is characterized by a marked tendency to abscess-formation, and at all stages of the affection round-cell infiltration is conspicuous. After the formation of an abscess perforation may take place upon the cheek or into the mouth, and sometimes salivary fistulæ (see below) are established. Chronic induration of the gland may remain after attacks of inflammation.

The submaxillary gland is occasionally affected with the parotid, or independently, in mumps. The sublingual gland rarely becomes inflamed.

Angina Ludovici, or **Ludwig's angina,** is a septic inflammation of the tissues of the floor of the mouth surrounding the submaxillary gland. It may result from carious processes at the roots of the teeth, or from infection of the submaxillary lymphatic glands in the course of various infectious diseases, particularly scarlet fever. The most frequent termination is abscess-formation, with perforation externally or into the mouth. Occasionally rapid necrosis or gangrene results.

Tumors.—The parotid gland is more frequently the seat of tumors than the other salivary glands. Benign tumors, such as fibroma, lipoma, or chondroma, are rare. The most common new growth is the so-called "mixed tumor," which is essentially sarcomatous, with the addition of fibroma, chondroma, or myxoma, and at times of all these. Epithelioma is rare.

Diseases of the Salivary Ducts.—*Salivary fistulæ* may

result from traumatic injuries or from the perforation of abscesses. They most frequently affect the duct of the parotid.

Concretions composed of phosphate and carbonate of calcium are occasionally observed, and may lead to obstruction of the ducts.

Cystic dilatation of Steno's or Wharton's duct, or of those of the sublingual glands, may be due to concretions or to inflammatory processes at the mouths of the ducts. Oval or elliptical tumors are formed, and contain transparent, viscid liquid. Such cysts belong to the group of conditions designated as *ranula*, but more frequently this is due to obstruction of the small mucous glands beneath the tongue.

THE ESOPHAGUS.

CONGENITAL DEFECTS.

Occasionally the esophagus is double, being divided into two parts by a septum. Complete absence of the esophagus may occur in certain monstrosities; more frequently there is partial absence of the lumen about the middle of the tube. The lower end of the esophagus in such cases communicates with the trachea, while the upper end terminates as a blind pouch. The intermediate defective portion may be represented by a fibromuscular cord, or may be entirely wanting. Fistulous communications may pass from the side of the neck to the upper end of the esophagus or pharynx. They are due to incomplete closure of the branchial clefts.

CIRCULATORY DISTURBANCES.

Anemia may be due to general anemia, and **active hyperemia,** to the irritation of hot liquids or chemicals.

Passive congestion results from diseases of the heart or lungs, or from cirrhosis of the liver. In the latter condition large *varicosities* may be established in the lower end of the esophagus, due to the communications between the left coronary vein of the stomach and the esophageal veins.

INFLAMMATIONS.

Catarrhal esophagitis is characterized by hyperemia and desquamation of epithelium, with very little liquid secretion. It may be due to the ingestion of irritating acid or alkaline liquids, to scalding, or occasionally to direct traumatic irritation. Superficial erosions are sometimes met with.

Chronic catarrhal esophagitis is found in cases of passive congestion continued for a long time, and particularly in alcoholics. The mucous membrane is thickened and dark in color. Occasionally erosions are met with, and more commonly areas of hypertrophy of the mucosa.

Pseudomembranous esophagitis may result from exten-

sion of pharyngeal diphtheria or pseudomembranous pharyngitis, or it may be primary in rare instances.

Ulcerative esophagitis may occur as the result of pustular eruption in small-pox, or in consequence of irritation of foreign bodies. It is not unusual to find small or even large ulcers in the mucosa of esophageal diverticula. These are occasioned by the retention of food. Peptic ulcers similar to those occurring in the stomach are occasionally found in the lower end of the esophagus.

Phlegmonous esophagitis is rare. It may result from the extension of intense inflammation of the mucous membrane into the submucous tissue, or to penetration of the mucosa by sharp points of fish-bones and the like.

STENOSIS.

Stenosis of the esophagus may be due to the pressure of tumors or aneurysms upon the esophagus, to the lodgement of foreign bodies, to the growth of tumors in the esophageal walls, or to stricture of the esophagus. The last most frequently results from the healing of ulcerations caused by the swallowing of corrosive liquids. Syphilitic strictures are rare. Carcinoma of the esophagus may obstruct by the growth within or by the attendant contraction of the walls.

DILATATION.

Dilatation of the esophagus may occur in the form of a *simple dilatation* or ectasia, or in the form of *diverticula*. The former variety is common at the lower end of the esophagus, and is occasioned by obstructions at the cardiac end of the stomach, or at the point where the esophagus passes through the diaphragm. The dilatation may reach considerable size. The mucous membrane is usually thin and often ulcerated.

FIG. 225.—Traction-diverticulum of the esophagus (modified from Birch-Hirschfeld).

Diverticula may be of two kinds, those due to pressure from within (*pulsion-diverticula*) and those due to traction from without (*traction-diverticula*) (Fig. 225). The former are more commonly found in the upper portion of the esophagus or the lower part of the pharynx, and arise from the posterior wall of the esophagus. They are due to thinning of the muscular coat and to hernious protrusion of the mucous membrane. They may reach considerable size by gradual distention. The traction-diverticula are most fre-

quently found near the lower end, opposite the bifurcation of the trachea. They are caused by adhesion of diseased bronchial glands and subsequent contraction of the attachments. They occupy the anterior wall of the esophagus and have a somewhat funnel-shape. Perforation may occur, with the development of septic infection of the pleura, pericardium, or lungs. Perforation of the pulmonary arteries may lead to fatal hemorrhage.

PERFORATION AND RUPTURE.

The esophagus may be perforated by necrotic or suppurative processes surrounding it, or as the result of ulcers proceeding from within. Aneurysms of the thoracic aorta occasionally rupture into the esophagus. Retropharyngeal abscesses and phlegmonous inflammations of the deep cervical tissues may likewise discharge into the esophagus. Perforation by ulcers beginning within may be due to the lodgement of foreign bodies, or to the pressure of the cricoid cartilage in cases of great asthenia (see Pharynx). Perforation of the lower end of the esophagus may result from peptic ulcers or esophagomalacia due to regurgitation of gastric liquid either before or after death. Spontaneous rupture of the esophagus occasionally takes place. In these cases there is doubtless always some antecedent weakness of the walls.

INFECTIOUS DISEASES.

Tuberculosis of the esophagus is extremely rare, and most frequently results from extension of tuberculous adenitis of the bronchial glands.

Syphilis occasionally occurs in the form of ulceration and cicatrization, leading to stenosis.

Thrush may extend from the mucous membrane of the mouth and pharynx.

TUMORS.

Fibroma, myoma, lipoma, or even *sarcoma* may occur as somewhat polypoid submucous tumors, but are rare. *Papillomata,* in the form of outgrowths of the mucous membrane, are more common.

The most important tumor is *carcinoma,* which is usually found in the lower third, generally at the position where the left bronchus crosses the esophagus. It may, however, be found at any part. The squamous variety is the most common, though a few instances of glandular carcinoma are recorded. The tumor usually involves the entire lumen of the esophagus, projecting inward and forming irregular elevations of the mucous membrane. Later, the growth extends outward through the muscular coat to the fibrous outer layer, and even to the surrounding tissues. Dilatation occurs

above the tumor, and occasionally perforation results from ulcerations caused by retained food. Local or more distant metastasis may take place.

THE STOMACH.

CONGENITAL DEFECTS.

Complete absence of the stomach has been found in certain monstrosities; but stenosis or atresia of the pylorus, division by the formation of septa, and hour-glass contractions have been more frequently observed. In cases of transposition of the viscera the stomach may be reversed in its position, the pylorus being on the left side, the cardiac end to the right.

CIRCULATORY DISTURBANCES.

Anemia of the mucous membrane is found in cases of general anemia, particularly in pernicious anemia. The mucosa has an extremely pallid appearance, and is prone to undergo fatty degeneration and atrophy.

Hyperemia.—*Active congestion* occurs in the beginning stages of inflammation of the mucous membrane of the stomach, and results from irritating mechanical or chemical agents. The mucosa is bright-red in color and may present minute hemorrhages. Moderate hyperemia is functional during the period of digestion.

Passive hyperemia occurs as a result of obstructive heart-disease, or more particularly from obstruction of the portal circulation by cirrhosis or other diseases of the liver. Pulmonary affections, by interfering with the outflow of blood from the right side of the heart, may also occasion congestion of the stomach. The mucosa is dark-red in color, swollen, and often edematous. Minute hemorrhages may occur, and small erosions may appear upon the surface. The changes are more marked near the pyloric end of the stomach. When the congestion has persisted for some time dark-reddish or bluish pigmentation, usually occurring in punctate form, is developed and chronic gastritis results.

Hemorrhage in the mucous membrane or from the mucous membrane of the stomach results from a variety of causes. Small petechiæ are met with in active or passive congestion and in acute inflammations. They are also present in various infectious or hemorrhagic diseases, such as purpura, scurvy, septicemia, and the like, and in anemic affections like pernicious anemia. In many cases punctiform hemorrhages are developed just before death.

Larger hemorrhages, and particularly hemorrhages into the cavity of the stomach, result from intense passive congestion in cardiac disease or cirrhosis of the liver, and from gastric ulceration or carcinoma. When large vessels have not been eroded the

blood escapes gradually, and may be vomited in a semidigested and disorganized condition (coffee-ground vomit). This is peculiarly significant of carcinoma. When one of the larger vessels has been eroded large quantities of fresh blood may be vomited and rapid death may occur.

Melæna neonatorum, the vomiting of blood by the new-born, results from disturbances of circulation due to insufficient respiration, and possibly in other cases is a variety of infectious hemorrhagic disease.

INFLAMMATION.

Acute inflammation of the mucosa, or **acute gastritis,** results from irritation by chemical, mechanical, or thermal agents. Some cases are doubtless due to infection. The mucous membrane is bright-red and covered with more or less viscid mucous exudate. Punctate hemorrhages may occur. Microscopically there are found: marked mucous degeneration of the cylindrical cells of the tubules, and desquamation and granular degeneration of the cuboidal cells in the fundus of the glands. The mucous membrane between the tubules is infiltrated with round cells, and not rarely the same process occurs in the submucosa. The collections of lymphatic tissue (follicles) in the mucous membrane are often hyperplastic. Acute gastritis is more frequently found near the pyloric end than elsewhere.

Pseudomembranous gastritis may result from the ingestion of corrosive poisons, and is occasionally seen in small-pox, typhus fever, and various forms of septicemia. It may be met with in diphtheria, and may be due to direct extension of the process along the esophagus. The surface of the mucosa is covered with an irregular membrane, and necrosis and ulceration are not rarely observed, especially in cases due to corrosive poisons.

Ulcerative Gastritis.—Small erosions may be found in cases of extreme congestion or petechial hemorrhage, as well as in acute gastritis. Actual ulceration is seen in pseudomembranous gastritis, and occasionally as a result of septic embolism in the mucosa in cases of malignant endocarditis. Infectious ulcerations occur in gastro-intestinal tuberculosis and anthrax, and in typhoid fever, but are very rare.

Chronic gastritis may result from repeated attacks of acute gastritis, and is especially prone to occur from improper habits of eating, or from the abuse of alcohol. Chronic congestion, such as occurs in heart-disease, strongly predisposes.

Pathologic Anatomy.—The appearance of the mucous membrane varies greatly. In the milder cases the surface is more or less irregular and granular, and is covered with mucous exudate. The color may be grayish, but in cases in which passive congestion

has preceded the development of gastritis it is often slate-colored from pigmentation.

Microscopically there may be found mucous degeneration of the cylindrical epithelium of the tubules, and desquamation and not rarely proliferation of the secretory epithelium in the fundus of the glands. The glands may be considerably dilated and filled with mucous exudate and desquamated cells. The interglandular tissues are infiltrated, and may be thickened by the formation of new connective tissue; the same process may involve the submucous coat. The blood-vessels of the latter are often greatly dilated and their walls may be thickened. In the later stages the glands may undergo progressive atrophy, the epithelium disappearing almost entirely and the lumen of the gland becoming less and less distinct. Coincidently with these changes, and to some extent causing them, there is fibrous overgrowth of the interglandular tissues.

In some instances the contraction of the new-formed connective tissue causes protrusions of the mucous membrane or polypoid

FIG. 226.—Chronic gastritis, showing polypoid projections of the mucosa.

elevations (Fig. 226). These may still further enlarge by proliferation and cystic distention of their glandular elements. In other cases the proliferative changes in the interglandular tissues may be more diffuse and the mucous membrane more regularly thickened. To both of these forms the name *hypertrophic gastritis* may be applied. In still other cases the formation of fibrous tissue causes pressure-atrophy of the glands; the surface in these cases becomes smooth and the mucosa greatly thinned

The sclerotic process may involve not only the mucous membrane, but also the submucous and even the muscular coat. In

such cases the thickness of the wall of the stomach may increase greatly, and the size of the organ greatly diminish by contraction. The term *interstitial gastritis*, or *gastrophthisis*, may be applied to such cases.

Pathologic Physiology in Gastritis.—All forms of gastritis cause disturbances of the functions of the stomach, designated by the terms *dyspepsia* and *indigestion*. These disturbances are due to abnormal secretion of the gastric glands, reduced motor power of the walls of the stomach, and altered conditions of the nervous mechanism. The most important alteration of secretion is reduction of the amount of hydrochloric acid. This is almost constant in uncomplicated gastritis; in some cases there is practically no hydrochloric-acid secretion. The ferments, pepsin and curdling ferment, may be produced in insufficient amount, but are very rarely absent. In cases in which certain general conditions or nervous affections coexist with moderate gastritis, excess of hydrochloric-acid secretion occurs. Reduction in the amount of hydrochloric acid causes delay and inadequacy of digestion of proteids. When the acid is wholly wanting decomposition of the proteids may occur, and sulphuretted hydrogen and other products of decomposition result. Excess of hydrochloric acid interferes with salivary digestion in the stomach, and in consequence fermentation of carbohydrates, with production of lactic, butyric, or acetic acid and of various gases, takes place. Such fermentation, however, is not, as a rule, observed unless the motor power of the stomach is deficient and the food is retained in the stomach beyond the usual time. It is not improbable that toxic substances are produced in some cases by proteid decomposition, but accurate observations are wanting.

The motor power is usually deficient in proportion to the intensity of the gastric disease. In some cases the food is retained many hours longer than the usual periods, and fermentation and decomposition are thus greatly favored. Dilatation of the stomach may be brought about by the retention of food and the accumulation of gases of decomposition, and the dilatation in turn increases the motor insufficiency of the stomach.

Altered conditions of the nervous mechanism of the stomach manifest themselves in a variety of ways. Sometimes there is excessive irritability of the mucosa, causing vomiting; in other cases a feeling of heaviness, or pain. Alterations of appetite and of gastric motility are other results probably brought about, in part at least, through nervous disturbances.

The general metabolism suffers profoundly in gastric disease—mainly in consequence of the insufficient food eaten or digested. Emaciation and systemic depression are the clinical consequences. It is probable that toxic substances produced in the stomach contribute to the metabolic disturbances, but this remains to be proved.

PEPTIC ULCER.

Peptic or **round ulcers** of the stomach are most frequently found in anemic young women, and are probably due to the digestive action of the gastric juice. Similar lesions may occur in the upper end of the duodenum and in the lower end of the esophagus.

Etiology.—The great majority of the cases occur in young women, and particularly in those suffering with chlorosis or anemia and general malnutrition. The pathogenesis of these ulcers has occasioned much dispute. It is admitted that they are due to the action of the gastric juice upon parts of lowered vitality, and the term *ulcus ex digestione* is therefore appropriate. The increased acidity of the gastric juice in chlorosis is an important factor. The lowered vitality which localizes the ulceration has been ascribed to many causes. Embolism or thrombosis with infarction was suggested by the shape of the ulcers, and may be the explanation for some cases. Spasm of the blood-vessels in



FIG. 227.—Peptic ulcer, showing erosion into a blood-vessel in the floor of the ulcer (Bollinger).

localized areas, and thickening of the walls of the vessels, leading to anemia, have been suggested, as have also direct traumatic injuries of the mucous membrane and external traumatism, causing rents of the mucous surface. Circulatory disturbances due to tight lacing are supposed by some to be important.

Pathologic Anatomy.—Peptic ulcers may be single, but are more often multiple. They are commonly situated in the lesser curvature and the posterior wall of the stomach, near the pylorus; occasionally they are found at the fundus or at the cardiac end. They vary in diameter from a few millimeters to three or

five centimeters. Their shape is characteristic in that they have sloping edges, giving them a funnel-form, with the apex toward the muscular coat. The edges may be irregular and rough, but are often, especially in older ulcers, quite smooth and rounded.



FIG. 228.—Peptic ulcer with perforation (Bollinger).

Two dangers are always imminent, hemorrhage and perforation. Constant oozing of blood may be due to erosion of the surface, and larger hemorrhages may result from ulceration of one of the larger arterial branches of the stomach (Fig. 227). Perforation

FIG. 229.—Stellate scar of a healed ulcer of the stomach (Bollinger).

is less common than hemorrhage. When the ulcer is situated posteriorly perforation is prevented by adhesions attaching the stomach to the head of the pancreas or other structures. When the ulcer is in the anterior wall perforation is more liable to take

place (Fig. 228). The rupture may occur into the peritoneal cavity or into any of the surrounding structures, and fistulous communications may be established with the pleural or pericardial cavities, or even with the exterior through the abdominal walls. Abscesses of the liver, spleen, or pancreas may result from perforation into these organs.

In the healing of the ulcers scars are formed in the wall of the stomach. These have usually a rather characteristic stellate shape (Fig. 229). In case of large ulcers extensive scars and considerable contraction of portions of the walls of the stomach result. Hour-glass contraction of the organ, or pyloric stenosis, may follow, and secondary changes, such as gastric dilatation, may ensue. Carcinomatous transformation is a not infrequent result of long-standing ulceration.

ATROPHY AND DEGENERATIONS.

Atrophy of the glands or gastric tubules is frequently seen in chronic gastritis. The same condition occurs as a senile change and in association with various chronic diseases, especially pernicious anemia. A certain amount of atrophy of the entire mucous membrane results in a purely mechanical way from gastric dilatation.

Decrease in the size of the stomach as a whole may be the result of chronic gastritis, when the new-formed connective tissue contracts. In such cases the stomach may become quite small, the walls, however, increasing in thickness. Somewhat similar shrinkage in the size of the stomach occurs in some instances of infiltrating cancer of the stomach. The tumor may involve all parts of the organ equally, and cause more or less thickening of its walls, but the size of the organ is diminished by contraction of the connective tissues.

A form of true atrophy is sometimes caused by obstruction of the cardiac orifice ; it is probably due, in part at least, to the insufficiency of food admitted to the stomach.

Degenerations of the mucous membrane of the stomach are met with in association with inflammation or as independent affections.

Fatty degeneration of the epithelial cells of the glands may be the result of intoxications (phosphorus, arsenic), or of conditions such as those which lead to simple atrophy. The occurrence of atrophy and fatty degeneration of the gastric tubules in cases of pernicious anemia is of great importance, though it remains unsettled whether these conditions are the cause or result of the anemia. Recent investigations would indicate that frequently they are the cause.

Pigmentation is met with as a result of chronic congestion or

hemorrhage into the mucous membrane. The mucosa has a dark-red or often a slaty discoloration, which is prone to be distributed in lines or in circumscribed patches. Bluish pigmentation of the stomach sometimes occurs from the ingestion of silver.

Amyloid degeneration may be found around the blood-vessels of the submucosa, or more rarely of the mucosa itself, in cases of general amyloid disease. Amyloid ulcerations may occur.

Calcification has been met with in cases of bone-disease with surcharge of the blood with earthy salts. It appears in the form of scales or plates of calcification upon the mucosa.

Gastromalacia, or simple softening of the walls of the stomach, is usually a post-mortem condition, and is due to the action of the gastric juice. The nature of this process has occasioned much discussion, but it is now recognized as a post-mortem condition, or as a condition occurring during life only in the agonal period. It affects the fundus or posterior part of the stomach. The mucous membrane becomes soft and more or less gelatinous, and is grayish or yellowish in color if the mucosa was anemic, or brownish in cases in which there was congestion before death. Rupture and discharge of the contents of the stomach into the peritoneal cavity, spleen, or other adjacent organs may occur. The walls of the stomach in the affected area show granular degeneration of the component cells, but no evidences of inflammatory reaction, and when rupture has occurred there are no reactive inflammatory lesions of the peritoneum, showing that the perforation occurred after death.

ALTERATIONS IN POSITION AND SIZE.

Alterations in Position.—The stomach may be displaced into the thoracic cavity in cases of perforation or rupture of the diaphragm (*diaphragmatic hernia*). It may be displaced anteriorly as a congenital malposition in consequence of defects of the anterior abdominal walls, and may in such cases be quite exposed. Downward dislocation, or *gastroptosis*, is either congenital or acquired. The acquired form may be due to diseases of the stomach, particularly dilatation, to the traction of inflammatory adhesions, to enlargement of the spleen, and possibly to tight lacing. Occasionally in anemic and relaxed women all of the abdominal viscera tend to descend (*splanchnoptosis*).

Dilatation, or **gastrectasia,** most frequently results from obstruction of the pylorus. The latter may be due to cicatrization the result of the healing of ulcers, to fibroid overgrowth and contraction the result of chronic gastritis, or to pyloric carcinoma. The pressure of tumors, of a movable kidney, or of aneurysms may act similarly. At first, pyloric stenosis may be compensated by hypertrophy of the muscular layer of the stomach,

but soon dilatation occurs; food stagnates, fermentation takes place, and the dilatation is increased. The mucosa becomes thin and ofttimes degenerated and atrophic.

A second group of cases (*atonic dilatation*) is independent of stenosis of the pylorus, but due to weakness of the walls of the stomach. The latter may be the result of chronic gastritis, or of a general atonic state. Constant overeating may play an important part in some cases. Finally, dilatation may result mechanically from abnormal adhesions of the stomach.

Dilatation of the stomach occasions great stagnation of food, and in consequence imperfect digestion and decomposition of the food. When hydrochloric acid is absent (as in cancerous stenosis of the pylorus and marked atonic dilatation) lactic-acid fermentation is pronounced; when hydrochloric acid is present lactic acid is less abundant. Sulphuretted hydrogen and inflammable gases are occasionally formed, especially in cases in which hydrochloric acid is present. The mucous membrane of dilated stomachs loses its absorptive power to a large degree. This, together with the retention of ingested liquid in the stomach and the consequent cessation of intestinal absorption, leads to great emaciation, and especially to desiccation of the tissues.

Among the micro-organisms met with in the gastric contents the *Sarcinæ ventriculi* are of interest. These occur in bundles of peculiar square form. The sarcina is more frequent in non-cancerous than in cancerous dilatation.

INFECTIOUS DISEASES.

A few cases of *tuberculous ulceration* have been recorded, and *syphilitic gummata* may occur. Diffuse cirrhosis and ordinary gastritis may be dependent upon syphilis, but the etiologic connection is uncertain. *Anthrax* may lead to necrotic and hemorrhagic ulcers of the mucosa. *Thrush* is rarely met with, though the spores of saccharomyces are frequently present in the stomach when the mouth is affected.

TUMORS.

Connective-tissue Tumors.—*Fibroma, myoma,* and *lipoma* are occasionally met with as submucous or subserous polypoidal tumors. *Sarcoma* is rare. It affects the lymphoid tissues of the deeper parts of the mucosa, and rapidly spreads to the submucosa (Fig. 230). Most cases are of the round-cell variety. Lymphosarcoma of the adenoid tissues of the stomach may be one of the lesions of leukemia or Hodgkin's disease.

Epithelial Tumors.—*Polypoid elevations,* sometimes with cystic enlargement of the glands, occur as a result of chronic inflammation, and may be large enough to be regarded as tumors

in a clinical sense. *Adenomatous proliferation* of the glands is met with in the form of irregular, flat tumors, but these so rapidly become carcinomatous that pure adenoma scarcely exists.



FIG. 230.—Sarcoma of the stomach, involving all of the coats; the original growth probably occurred in the mucosa and submucosa.

Carcinoma is the most frequent tumor of the stomach. It occurs in advanced years, and more often in the male sex than in

FIG. 231.—Fragment of carcinomatous tissue found in stomach-washings (Reinevoth).

the female. The pyloric end of the organ and the lesser curvature are the favorite sites, but other parts may be affected and the entire organ may be involved. Cancer of the stomach may appear

as a ring-like swelling of the mucous membrane and submucous tissue, surrounding the pylorus and causing stenosis; as more or less circular, flat elevations in the lesser curvature or elsewhere; and, finally, as a diffuse infiltration of the mucosa, submucosa, or all of the coats of the entire organ. The mucous surface is generally irregularly elevated, and tends to become ulcerated, especially in the soft variety of cancer and in the cases in which there are localized flat elevations. Sometimes portions of the cancerous tissue may be found in the vomita, and the diagnosis of the disease may be thus established (Fig. 231).

FIG. 232.—Carcinoma of the cardiac end of the stomach; extension into duodenum: *S*, dilated esophagus; *K*, ulcerated carcinoma; *G*, a perforating ulceration; *M*, stomach (Orth).

Perforation of the wall of the stomach may result from necrotic and ulcerative processes (Fig. 232). The neighboring lymphatic glands, especially those in the lesser curvature of the stomach, are usually implicated through the lymphatic vessels. Direct extension to the peritoneum may occur, especially in cases of colloid cancer; and metastasis through the blood-vessels is extremely common. Cancerous emboli are frequently found in the portal radicles within the liver, and multiple cancer-nodes of the liver are usually found in cases which have existed for some length of time. Hematogenous metastasis is most common in soft, ulcerating cancers.

Varieties.—There may be distinguished *hard* or *scirrhous cancers*, *soft* or *medullary cancers*, *adenocarcinomata* or *malignant adenomata*, *cylindrical-celled*, and *squamous-celled carcinomata*. All forms begin in the mucous membrane and spread rapidly to the submucosa. The muscularis may be penetrated and infiltration of the serosa, or even of surrounding tissues, may be observed.

Scirrhous cancer may appear as a circular constricting new growth at the pylorus (Fig. 233). In other cases the disease is extensive, and the entire organ may be involved by uniform infiltration, and macroscopically the appearance of a simple cirrhosis

FIG. 233.—Scirrhus of the pylorus, causing pyloric stenosis: *D*, duodenum; *P*, pylorus; *K*, carcinomatous projections on the mucosa (Orth).

of the stomach is presented. The mucous surface in scirrhus rarely ulcerates.

Encephaloid or soft cancer usually appears as a localized tumor at the pylorus or in the lesser curvature. The mucous

FIG. 234.—Cauliflower carcinoma of pylorus: *M*, stomach; *P*, pylorus; *D*, duodenum (Orth).

membrane is irregularly elevated, ofttimes in a cauliflower manner (Fig. 234). Ulceration on the surface is common, and hemorrhagic extravasation into the stomach is therefore frequent. Metastasis through the blood is liable to occur. Complete perforation of the stomach may take place.

Malignant adenoma, or adenocarcinoma, begins as a proliferation of gastric tubules. The new-formed acini are, however, atypical in arrangement and number, and there is a tendency to conversion of the normal cylindrical cells into cuboidal cells, and to extensive cancerous infiltration by destruction of the basement-membrane of the acini. The appearance of the tumor and its tendencies are the same as those of soft cancer.

Cylindrical cancer, or cylindrical epithelioma, probably springs from the cylindrical lining cells of the stomach, or from the cells in the upper parts of the tubules. Atypical tubular aggregations of cylindrical cells with a tendency to conversion into cuboidal cells are observed. The pylorus is the common seat.

Squamous cancer occurs at the cardiac end, and generally in association with carcinoma of the lower end of the esophagus. It is rare.

Colloid cancer of the stomach appears as a localized, or more frequently, diffuse infiltrating, gelatinous new growth of the mucosa and submucosa. Rapid extension through the walls of the stomach and to the peritoneum is frequent. The degeneration may affect different forms of cancer, but especially the cylindrical variety. The cells and the stroma of the tumor show myxomatous degeneration; and the epithelial elements may in the later stages entirely disappear. Extensive invasion of the peritoneum is not infrequent.

Pathologic Physiology and Results.—Carcinoma of the stomach is most frequently situated at or near the pylorus, and therefore interferes with the propulsion of food. Stagnation of the stomach-contents and fermentation result. The latter is favored by the absence of hydrochloric-acid secretion so habitually observed. In consequence of the stagnation the stomach dilates and may reach enormous size, not rarely filling a large part of the abdominal cavity. Lactic-acid fermentation is frequently pronounced. Among the micro-organisms present in the stomach-contents a long, thread-like bacillus has attracted much attention, and has been supposed by some to occur only in cancer of the stomach. It is certainly frequent, but just as certainly not peculiar to the disease. Disturbances of metabolism, with loss of flesh and strength, are marked.

THE INTESTINES.

CONGENITAL AND ACQUIRED ABNORMALITIES.

Occasionally *total absence* of large parts of the intestinal tract is found in monstrosities. Lesser defects, leading to *narrowing* or *distortion* of the intestines, are more frequent. Marked developmental defects most frequently occur in the rectum, which may

be completely absent, or may be obliterated at the lower end. In such cases there may be fistulous communications with the urogenital tract, or there may be a persistent cloaca, as in fetal life.

Congenital Enlargement of the Intestines.—The colon is most apt to be affected, and may be greatly enlarged.

Diverticula.—Localized dilatations, constituting diverticula, are frequent, the most common form being the *Meckel's diverticulum.* This usually arises from the ileum, about a meter above the ileocecal valve, and is attached to the intestine opposite the mesentery. It represents the remains of the omphalomesenteric duct of fetal life. Occasionally it has been found patulous to the umbilicus. More commonly there is merely a short diverticulum of the intestines, varying from a few to several centimeters in length, and having a closed extremity which may be somewhat dilated. The extremity may be connected with the umbilicus by a cord, but is usually free.

Diverticula are also formed in later life. Very commonly, in cases of constipation, small pouchings or dilatations occur in the large intestine, particularly in the descending colon and rectum. Another form affects the small intestine more commonly than the large bowel. In this there are found small pouches lying near the mesenteric attachment, and owing their origin to localized weakness or separation of the muscle-fibers of the bowel. Protrusion of the mucosa takes place, probably, as a result of pressure from within; and the pouch is therefore a hernious projection of the mucosa and serosa. Such diverticula may be multiple or single.

Congenital Abnormalities in Position.—The position of the several parts of the intestinal tract may vary widely from the normal. Not rarely the ascending colon and cecum are situated on the left side; the sigmoid flexure and descending colon being on the right side. Other abnormalities of position, of less practical importance, are frequent.

Enterocystoma.—A congenital cystic condition found at the umbilicus has been described as cystic dilatation of parts of the original omphalomesenteric system of the fetus, and has been named enterocystoma.

Dilatation.—More or less uniform enlargement of the intestines may result from long-standing constipation. Enormous dilatation of the colon is sometimes seen. In this the wall of the intestine undergoes compensatory hypertrophy, and small pouchings or diverticula are commonly observed, especially in the rectum.

Narrowing, or **stenosis,** of the intestine at any part may be due to pressure of new growths or displaced viscera, to cicatricial constrictions following ulcerations, or to neoplasms. Cicatricial stenosis is particularly common in the rectum following dysenteric ulcer. Narrowing of the lumen may be due to an ingrowth of carcinoma or the presence of papillomatous or polypoid tumors within.

Hernia.—This term is applied to malposition of any of the viscera, with displacement of the organ from the cavity in which it normally lies; but it has been more particularly applied to such displacements of the intestines; and the single term hernia is significant of intestinal hernia.

Occasionally herniæ are congenital; more often they are acquired. Hernia occurs at the points where the abdominal walls or the peritoneum is naturally weak from the emergence of vessels or the existence of natural outlets.

Etiology.—The predisposition to hernia may consist in unnatural weakness of the abdominal wall, especially at the points where hernia is likely to occur, resulting from imperfect closure of such portions or from general muscular weakness. Abnormal movability of the intestines, resulting from natural or acquired elongation of the mesenteric attachments and increased weight of the abdominal contents from the deposit of peritoneal fat, contributes largely to the formation of herniæ. The immediate exciting cause in many cases is strain, and probably in all cases repeated strain helps in the development of the protrusion. The most frequent form of ventral hernia is the umbilical, which occurs especially in infants as the result of imperfect closure of the abdominal walls at the umbilicus.

There may be distinguished two groups or varieties—the internal and the external herniæ.

Internal Hernia.—By this term are designated hernious displacements of the intestines into other cavities within the body, the most important being upward displacement into the thorax through congenital or acquired clefts of the diaphragm (*diaphragmatic hernia*); and backward displacement through the peritoneum into the retroperitoneal space (*retroperitoneal hernia*).

External hernia may be *inguinal*, *femoral*, *ventral*, *vaginal*, *rectal*, *perineal*, *ischiatic*, or *obturator*. The most frequent of these are the inguinal and the femoral. In the former the protrusion may occur through the external inguinal ring, the intestine descending through the inguinal canal, sometimes as far as the scrotum (*indirect inguinal hernia*). In another group of cases the intestine pushes directly forward through the internal inguinal ring, and may present anteriorly under the skin, or may descend through the lower part of the inguinal canal to the scrotum (*direct inguinal hernia*). The indirect inguinal herniæ are sometimes congenital, and are due to the failure of closure of the peritoneal reflection which passes downward through the inguinal canal.

Femoral herniæ are especially common in women, and are formed by the protrusion of the intestine through the femoral ring, the hernia presenting on the inner side of the thigh, at the position of the saphenous opening.

Pathologic Anatomy.—The hernia consists of a sac or wall

and of the contents of the hernia. The sac is usually constricted at its junction with the general peritoneal cavity (neck), and distended and dilated outside of or below this point (fundus or body of sac). The sac of the hernia is always lined with the protruded portion of the peritoneum. The contents of the hernia may be coils of intestine or portions of omentum, or both. Most frequently some part of the small intestine occupies the hernia, and sometimes simply a Meckel's diverticulum has been discovered. In rare cases the sigmoid flexure or other parts of the great bowel may be found.

Secondary changes often ensue. Inflammation of the lining membrane of the sac and of the intestinal coils may lead to fibrous adhesions constricting the neck of the sac and binding the intestines firmly in place. If the contents of the hernia have receded, such inflammation may obliterate the sac completely or merely at its neck, the body of the sac in the latter case becoming distended with serous liquid. In cases in which portions of omentum are included in the hernia hypertrophic overgrowth of the adipose tissue may occur, and may lead to appearances not unlike those of a lipoma.

Herniæ are described as being *reducible* and *irreducible*, according to the ability of replacing the contents into the peritoneal cavity or not. Herniæ become irreducible when the coils of intestine are distended by the accumulation of fecal matter, when fibrous adhesions have narrowed the neck of the sac or bound the coils firmly in place, or when additional coils of intestine or portions of the omentum have descended into the hernia.

Strangulated Hernia.—This term is applied to herniæ in which pressure at the neck by inflammatory exudation or constriction, or inveterate obstruction by accumulating contents of the bowel, has led to obstruction of the circulation in the intestinal coils of the hernia. Intense passive congestion, inflammation of the peritoneal covering of the intestines within the hernia, and, finally, gangrenous necrosis are the frequent results.

INTESTINAL OBSTRUCTION.

Complete obstruction of the intestines, or ileus, may be due to internal strangulation by bands of adhesions, to a twist or volvulus, or to intussusception or invagination.

Internal strangulation may be due to the obstruction of a coil of intestine by fibrous peritoneal adhesions, or by a coil slipping through abnormal openings or perforations in the mesentery or omentum. The persistence of the cord passing from the end of a Meckel's diverticulum to the umbilicus is an unusual cause.

The results of internal strangulation are generally serious. Great dilatation occurs above the point of obstruction, the intes-

tine below becoming collapsed. Great congestion and subsequently peritonitis occur at the point of stricture, and necrosis with perforation may ensue.

Volvulus is the term applied to a twist of some part of the intestinal canal. Occasionally there is simple rotation of the bowel about its own axis, but more commonly a loop of intestine twists about its mesenteric attachment. Abnormal laxity of the mesentery is an important predisposing cause, and may be a congenital condition, or may result from the absorption of fatty deposit between the mesenteric layers. The immediate cause is generally strain or abdominal compression.

The most frequent seat of volvulus is the sigmoid flexure. The bowel above the point of obstruction becomes distended, as in internal strangulation, while the coil included in the twist itself is engorged with blood and frequently presents hemorrhagic infarctions in consequence of the obstruction of the vessels in the mesentery. Complete knots are occasionally observed in volvulus.

Intussusception, or **invagination,** is a condition in which one part of intestine slips into an adjoining part, as one may invert the finger of a glove (Fig. 235). The upper part of the intestine is usually induplicated and pushed into the lower part. Irregular peristalsis, resulting from intestinal disorders, and particularly from atony of one part with increased activity of adjoining parts, is the most frequent cause. Occasionally polypoid tumors within the bowel are dragged forward by the peristalsis, and carry the higher part of the intestine to which they are attached into the lower part. Intussusception is more common in children than in adults, and affects the ileocecal region most commonly. Not infrequently multiple invaginations are found in the small intestine of children; these probably occur during the death-agony or post-mortem.

FIG. 235.—Intussusception (from a specimen in the Museum of the Philadelphia Hospital).

The appearance of intussusception is simply that of one part of intestine pushed into the adjoining part, with secondary inflammatory and congestive changes. Most frequently invagination begins at the ileocecal region, the valve and ileum being carried forward into the ascending colon. Very rarely the ileum itself invaginates through the valve. The attachment of the mesentery leads to a sharp angulation of the area of invagination, and the extent to which the protrusion may occur will depend upon the length of the mesentery. Occasionally

the ileocecal valve may be carried through the colon and rectum and present externally. The adjoining serous surfaces of the invagination tend to unite by peritonitis, and the intussuscepted portion may become gangrenous and be discharged. If peritonitis has established union between the ensheathed and the ensheathing section of the gut, recovery may ensue. Otherwise the perforation leads to fatal peritonitis.

PROLAPSE OF THE RECTUM.

Prolapse of the rectum in consequence of weakness of the sphincter and other parts of the wall, together with repeated straining, is a common condition in infants, and is occasionally met with in adults. In children any form of diarrhea may be complicated by prolapse; in adults chronic proctitis is the most frequent cause. The weakened condition of the sphincter in proctitis furnishes the predisposition, and the characteristic tenesmus of the disease is the immediate cause. Prolapse may be only an occasional condition, or may be constant. Secondary inflammation, ulceration, and even necrosis of the prolapsed portion may occur.

ATROPHY AND DEGENERATIONS.

Atrophy of the mucosa is frequently met with as a part of chronic enteritis in its later stages. This is especially marked in young children suffering from chronic intestinal catarrh and marasmus. Occasionally atrophy of the mucosa or of all of the coats of the intestines may occur as an independent affection, as the result of marantic or cachectic conditions.

Pigmentation.—Pigmentation may be due to hemorrhages in the mucosa or submucosa, and not infrequently after intense hemorrhagic inflammation the bowel may be quite black from the deposit of hematogenous pigment. Brownish pigment deposited in the muscle-cells, analogous to that of brown atrophy of the heart, is occasionally observed in old and cachectic individuals. Similar pigmentation of the muscle-cells and also of the submucosa or mucosa, of even more decided character, occurs in youthful persons addicted to alcohol. The intestines alone may be thus affected, or the liver, spleen, and lymphatic glands are simultaneously involved. The term *hematochromatosis* has been proposed for this condition.

Amyloid degeneration is met with in association with amyloid disease of the liver, kidneys, or spleen, and particularly in cases in which there is tuberculous ulceration of the intestines. The mucous membrane is principally involved, and becomes somewhat hardened and presents a peculiar grayish luster. Superficial erosions and even considerable ulcers may result. The process begins, as elsewhere, in and around the small blood-vessels.

CIRCULATORY DISTURBANCES.

Active hyperemia may occur from acute irritation, and forms a part of inflammation.

Passive hyperemia results from causes similar to those producing congestion of the stomach. Among these, obstructive diseases of the liver, notably cirrhosis, and cardiac and pulmonary affections are most prominent. The intestinal mucosa becomes somewhat swollen, ofttimes edematous, dark bluish-red in color, and occasionally marked by punctate hemorrhages. The mesenteric veins are widely dilated. Occasionally hemorrhagic liquid is found within the intestines, the points of hemorrhage remaining undiscovered.

Hemorrhage.—Petechiæ are found in many cases of violent septic or infectious diseases, in intense anemias, and as the result of marked passive hyperemia. Embolism in cases of ulcerative or malignant endocarditis may lead to petechial hemorrhages, and the same are observed as a part of the morbid anatomy of intestinal anthrax. Large intestinal hemorrhages may occur from typhoid, tuberculous, dysenteric, or syphilitic ulcerations, or from the perforation of a large arterial branch by a peptic ulcer in the duodenum. Hemorrhoids may occasion considerable hemorrhages from the rectum.

Edema of the mucosa may result from passive congestion, and attends acute or chronic inflammations, especially the more intense forms.

Embolism and **thrombosis** of the mesenteric arteries are rare conditions. Embolism may lead to hemorrhagic infarction.

Hemorrhoids result from varicose enlargement of the veins of the rectum. They are usually found in the lower part of the rectum, inside or outside the sphincter, and a distinction is made between internal and external hemorrhoids.

Etiology.—Obstruction of the venous circulation is the important etiologic factor. It may be due to chronic diseases of the liver (cirrhosis), repeated pregnancies, pelvic tumors, or chronic constipation with frequent retention of feces in the rectum. The last-named condition acts in a twofold manner. On the one hand, it causes venous obstruction, and, on the other hand, chronic proctitis, which in turn occasions disease of the veins of the rectum, and thus predisposes them to dilatation. In all cases of hemorrhoids, constipation and the resulting proctitis are important as auxiliary causes. Hemorrhoids are rarely met with before adult age.

Pathologic Anatomy.—The hemorrhoid presents itself as a small polypoid elevation of more or less congested appearance. On section it is found to be highly vascular, and to consist of dilated veins. There may be a congeries of slightly enlarged veins or cavities of considerable size. Between the veins there is more or

less abundant inflammatory connective tissue. Thrombosis often occurs within the cavities; and occasionally the fibrous tissue around them undergoes active proliferation, when a structure resembling fibro-angiomata results. Hemorrhagic extravasations may occur from the veins, and free hemorrhage from the surface is a common symptom. Infective inflammation and phlebitis of the veins sometimes occur. In these cases the hemorrhoid enlarges and becomes inflamed and edematous. Inflammation of the adjoining tissues may occur (proctitis, periproctitis).

Hemorrhoids may cause marked anemia by the repeated hemorrhages, and sometimes occasion septic infections when they have themselves become infected and inflamed.

INFLAMMATIONS.

Inflammation of the intestines, or **enteritis,** may affect any part of the intestinal canal, and involve the mucosa and submucosa more particularly. It is more frequently present in children and in the aged than at other periods of life.

Etiology.—The causes of enteritis are similar to those of gastritis, and among them may be reckoned all forms of irritating foods or foreign matter taken with the food. Poisons of various kinds operate in a similar manner. In many cases the irritant poisons which occasion enteritis are developed within the body in consequence of improper digestion and fermentation. Bacteria play an important *rôle* in this process, and sometimes are themselves the direct cause of enteritis in instances in which improprieties of diet or digestive disturbances have furnished favorable conditions for their growth and multiplication. The normal colon-bacillus is perhaps the most frequent and important micro-organism of ordinary non-specific enteritis, but other organisms doubtless frequently play a part. The colon-bacillus probably increases in virulence under certain conditions and then occasions irritation.

Pathologic Anatomy.—There are a number of varieties of enteritis, and different types may be described, though individual cases rarely conform to a single variety. Of the acute forms of enteritis, the important are the catarrhal, suppurative, and the pseudomembranous.

Catarrhal enteritis may affect any part of the intestinal tract. The mucosa is swollen and usually light-red in color; the arteries are visibly distended, and not rarely there are petechial hemorrhages. The surface is covered with mucous exudate containing desquamated and degenerated epithelial cells and emigrated leukocytes; while the intestinal contents are rendered liquid by serous exudation. The solitary follicles or agminated collections of lymphoid tissue may be particularly swollen and cause projections above the surrounding mucosa. The term *follicular enteritis* is

applied to such cases. In other instances the desquamation of epithelium is more prominent than the mucous exudation, and considerable shreds of mucosa may be loosened and discharged. The term *croupous enteritis* is suggested by such conditions.

Suppurative enteritis differs from the catarrhal form in the greater degree of emigration of leukocytes. The exudate upon the surface may be largely composed of white corpuscles, and in intense cases the surface may be covered with almost pure pus. Round-cell infiltration of the mucosa and the submucosa is present, and focal collections leading to *submucous abscesses* or to *ulcers* upon the mucous surface are occasionally seen. The solitary follicles are enlarged and tend to break down, forming *follicular ulcers.*

Ulceration of the intestines occurs in a variety of conditions. *Peptic ulcers*, similar to those met with in the stomach, are occasionally found in the duodenum. They have the same characters and tendencies as those of the stomach; they may occasion sudden death from hemorrhage. Ulcers in the duodenum are also an occasional result of extensive burns of the skin; and recently attention has been called to the frequency of duodenal ulceration in cases of chronic Bright's disease. Ulcerations of the ileum are habitual in typhoid fever and tuberculous enteritis, and are occasionally due to anthrax or actinomycosis. Sarcomata and carcinomata are rare causes. Ulcerations of the large bowel are met with in chronic enteritis and dysentery. A form of peculiar clinical interest is *anal fissure.* This is a linear ulceration of the rectum in the region of the sphincter. It may be associated with hemorrhoids or be independent.

Pseudomembranous enteritis is characterized by the formation of a grayish membrane upon the surface of the intestine. The large intestine is more frequently involved, and the process is especially met with in dysentery (see p. 510). True diphtheria of the bowel with pseudomembranous deposit may sometimes occur.

Chronic enteritis results from acute attacks or from repeated irritation. Chronic congestion in consequence of hepatic or cardiac affections is a predisposing cause of importance.

In the early stages the mucous membrane is usually more or less swollen, and sometimes proliferative changes in the glandular elements may lead to distinct polypoid elevations. These are especially pronounced in cases in which the healing of ulcers of acute enteritis has occasioned cicatricial constrictions and thus elevated adjoining parts of the mucosa. The elevated portions may undergo proliferative inflammation, and polypoid formations result. In the later stages of chronic enteritis atrophy may ensue, in part as the result of the overgrowth of the stroma of the mucosa and the degeneration of the glandular elements, in part also as the result of the overdistention or tympany resulting from fermentation of the intestinal contents. This atrophy may affect the mucous membrane alone, but more commonly also involves the muscularis. Hyperplastic processes in the lymphoid elements may be a promi-

nent feature in the hypertrophic stage of chronic enteritis, and may give place to atrophy in the later stages. On the other hand, the enlargement of the solitary follicles and Peyer's patches may persist for a long time after atrophy has led to great thinning of the remaining portions of the mucosa.

Pathologic Physiology.—Enteritis may occasion profound disturbances in a variety of ways. In cases of infective character general systemic intoxication may result from the absorption of bacterial products or substances resulting from decomposition of the intestinal contents. In other cases the intensity of the local irritation may, through the nervous system, occasion great depression or shock; and subsequently the exudations into the intestines may cause depletion of the vascular system and failure of the circulation. The local effects and the resulting behavior of the bowels differ in different cases. Sometimes the peristaltic movements are arrested by the intensity of irritation and obstinate constipation results; more frequently hurried peristalsis and the abnormal exudation (serous or mucous) occasion diarrhea. The digestive processes fail from the diseased condition of the bowel, as well as from the rapid peristalsis and premature discharge of the intestinal contents; more or less profound disturbance of health results.

INFLAMMATIONS OF SPECIAL PARTS.

Duodenitis.—Duodenitis occurs in association with gastritis from irritating food and the like. The appearances are the same as in gastritis. Duodenitis is prone to occasion obstruction of the terminal portion of the common bile-duct by the inflammatory thickening of the mucosa and the accumulation of mucus in the mouth of the duct; and in this way gives rise to obstructive jaundice (*catarrhal jaundice*).

Inflammation of the ileum presents no special characteristics, excepting that enlargement of the follicles (*follicular enteritis*) is frequently conspicuous. Follicular ileitis is particularly common in children suffering from infectious fevers, such as diphtheria and scarlatina. Peyer's patches may be considerably enlarged and even ulcerated. The ulcers are generally small, and several may occur in a single Peyer's patch instead of single ulcers, such as occur in typhoid or tuberculous enteritis.

Typhlitis or **cecitis** (inflammation of the cecum) may be due to the irritation of the intestinal contents in consequence of constipation (*stercoral typhlitis*). This affection is probably very frequent, though it leads to no severe consequences and occasions no urgent symptoms. Typhlitis is probably generally of the simple catarrhal variety, but in obstinate constipation or obstruction of the colon ulceration may occur. Perforation or extension

to the surrounding tissues (*perityphlitis*) is the rarest of all consequences. More frequently the latter is secondary to inflammations of the appendix vermiformis.

Appendicitis may be a primary condition, or it may result from primary typhlitis or cecitis. The inflammation of the mucosa of the cecum may extend directly to that of the appendix; or may cause obstruction of the mouth of the appendix in the same manner as duodenitis causes obstruction of the common bile-duct. There results a retention of the contents of the appendix and multiplication with increased virulence of the contained bacteria (Bacillus coli communis, staphylococcus, streptococcus, and others). The mucosa of the appendix, rendered less resistant in consequence of the overdistention and associated congestion, may be penetrated by the micro-organisms and appendicitis results. In many cases fecal concretions are found within the appendix, and less commonly foreign bodies of various sorts have been found. These have been assumed to be the direct cause of the disease, and doubtless may play a part by irritating the mucosa, or injuring it in such manner that micro-organisms easily penetrate it. On the other hand, there is much reason to believe that the fecal concretions are often formed in consequence of the accumulation of mucous and desquamated epithelial cells and the stagnation of the contents of the appendix, after the disease has begun. Obstruction of the arterial supply of the appendix was formerly regarded as an important element in the etiology, but probably is only of secondary importance.

Pathologic Anatomy.—The pathologic anatomy of appendicitis varies in different cases, and we may, for convenience, distinguish a *catarrhal*, a *necrotic* or *gangrenous*, and an *interstitial* form.

In the mildest or catarrhal form there is merely retention of the contents of the appendix and slight disease (swelling and erosion) of the mucosa. The muscularis and serous coat may be congested and edematous, but are not extensively involved. The contents of the appendix are more or less mucopurulent in character.

In the necrotic or gangrenous form the mucous membrane suffers rapid destruction and the muscular and serous coats are quickly invaded. Fibrinous peritonitis soon develops in the serous coat and over the adjacent intestines, either as a result of penetration of bacteria through the walls of the appendix, or in consequence of perforation of the walls. The local peritonitis serves the purpose of restraining the infective disease and prevents diffuse peritonitis. In cases of rapid gangrene, with early rupture or escape of abundant bacteria, general peritonitis may result before a restraining wall can be formed.

The term interstitial appendicitis may be used to designate

cases in which all of the coats of the appendix are involved and in which there is a special tendency to productive changes in the connective tissues. In reality all cases of appendicitis show more or less interstitial change of this character (Fig. 236); but in some it is the conspicuous feature. These cases frequently terminate in chronic thickening of the appendix.

FIG. 236.—Acute appendicitis, with round-cell infiltration and hyperplasia of connective tissue in all of the coats. In large part the round cells of the mucosa and submucosa belong to the normal lymphoid tissue of these parts.

Results.—Mild cases of catarrhal appendicitis may subside after free purgation, with relief of the obstruction at the mouth of the appendix. In more serious inflammations and in cases in which the obstruction remains, the disease spreads through the walls of the appendix to the peritoneum and occasions local peritonitis; or rupture of the appendix occurs, and more intense local or general peritonitis follows (Fig. 237). In either case fibrinous deposits are formed upon the peritoneum, and not rarely a localized abscess (*perityphlitic abscess*) results. The appendix itself may be separated from the cecum, and may lie free in the abscess, or it may be firmly embedded in the fibrinous wall of the abscess. The latter may subsequently undergo inspissation, but more commonly ruptures into the general peritoneal cavity, into some part of the intestines, into the ureter, bladder, or externally. In cases with favorable outcome the appendix is usually bound down by adhesions, attaching itself to neighboring coils of intestine or to other structures. The appendix in such cases is usually distorted and greatly thickened, and repeated attacks of inflammation (*relapsing or recurring appendicitis*) are not unusual.

There is generally more or less systemic intoxication and infection, and secondary lesions may be found in distant organs. Not

rarely pylephlebitis and metastatic abscesses of the liver are encountered.

Colitis, aside from the specific form, dysentery, is most frequently due to irritation by fecal accumulations, and the sigmoid flexure is the common seat. The entire colon may, however, be involved. Thickening of the mucous membrane and

FIG. 237.—Ulcerative and perforative appendicitis, showing perforations; two fecal concretions from other cases of appendicitis (modified from Bollinger).

abundant exudation of mucus are the prominent features of the earlier stages; while in the later stages atrophy and thinning are observed. Ulcerations are not uncommon. When the mucous exudation and the desquamated cells accumulate upon the surface the appearance of a pseudomembrane is simulated, and casts of the bowel or masses of mucus may be discharged from time to time (*mucous colitis*).

Proctitis, or **inflammation of the rectum,** may be due to direct irritation by retention of fecal matter, by parasites, or by toxic agents; or it may occur secondarily after various other diseases of the rectum, such as tumors, hemorrhoids, and the like. The inflammation tends to become chronic. The rectum is generally involved with the colon in cases of mucous colitis.

The mucous membrane is considerably swollen, often edematous, and usually presents petechial hemorrhages. Ulceration may occur secondarily, and extension of the ulcerative process to the surrounding tissues (periproctitis) is not unusual. In the latter cases fistulous communication may be established between a

perirectal abscess and the rectum (*incomplete fistula*), or a fistulous communication may form between the rectum and the exterior (*complete fistula in ano*). Sometimes proctitis is secondary to periproctitis occurring in diseases such as typhoid fever, pyemia, and the like.

INFECTIOUS DISEASES.

Dysentery is a specific, endemic or epidemic inflammation of the large intestine. The term probably includes a variety of affections due to different causes.

In the milder cases of endemic dysentery tainted food and products of fermentation, with perhaps specific bacteria, are the causative agents. Occasionally certain poisons, like mercury, produce similar lesions. In cases of ulcerative dysentery, especially the tropical forms, the Amœba coli is usually regarded as the specific cause (see Part I.). This organism probably enters the intestinal tract through drinking-water and multiplies in the large intestine, where it invades the mucosa and occasions widespread ulceration.

The etiology of the most severe forms of dysentery remains obscure, but the association of certain cases with violent septic diseases suggests the causal factors.

Pathologic Anatomy.—Several varieties may be distinguished, though one of these merges gradually into the other.

Catarrhal dysentery is the mildest form. It is characterized by congestion, swelling, and edema of the mucous membrane. Petechial hemorrhages and follicular enlargements or ulcers are not unusual.

Ulcerative dysentery is marked by swelling of the mucosa and scattered ulcers having a more or less irregular and ragged outline and undermining the mucosa. The ulcers are often surrounded by hemorrhagic infiltration. The ulcerative form tends to become chronic, causing great thickening of the bowel and indolent ulcers.

Diphtheritic dysentery is distinguished by the presence of a pseudomembranous deposit in and upon the mucous membrane. The entire wall of the colon and rectum may be covered with a grayish or brownish, more or less necrotic, membrane ; or smaller areas of like character may be scattered here and there upon a thickened and catarrhal surface. In the mildest cases the process is entirely superficial, in the severest it extends deeply, and the muscularis mucosæ and even the submucosa may be destroyed. To the most violent of all forms the term *gangrenous dysentery* is applicable. Microscopically, the epithelial cells show granular degeneration and become more and more necrotic. They are embedded in a fibrinous or mucofibrinous matrix, and round cells invade the membrane as well as the subjacent tissues.

Results of Dysentery.—In all cases there is a tendency to chronic thickening or inflammation of the large bowel; and mucous colitis or merely a tendency to repeated acute colitis may remain. Occasionally perforation occurs, and peritonitis or periproctitis results. The most frequent complication is abscess of the liver resulting from embolism or from ascending thrombosis of the portal vein. In amebic dysentery the Amœba coli is carried to the liver in emboli and occasions secondary changes.

Cholera.—Cholera epidemica, or Asiatica, is an acute specific inflammation of the small and large intestines, due to the comma-bacillus or vibrion of Koch. This micro-organism is found in the great majority of cases. Occasionally it is not discovered, while other micro-organisms, Bacillus coli communis and streptococci, are present. It is probable that in these instances errors of observation cause the failure of detection.

Pathologic Anatomy.—Cholera is characterized by redness and swelling, and not rarely by petechial ecchymosis of the mucous membrane, particularly of the small intestine. The superficial epithelium suffers early and extensive degeneration, perhaps a form of coagulation-necrosis. The solitary follicles and the agminated glands may enlarge and may suffer ulceration. The intestines contain and discharge a serous exudation, often in large quantities, and containing grayish or whitish particles, which are flakes of desquamated and degenerated epithelium. The term "rice-water" discharges is applied to the evacuations. Extensive areas of the mucous membrane may be laid bare by the desquamation of the epithelium. When cholera has passed to its later stages secondary pseudomembranous inflammation of the mucous membrane is not unusual, and is probably the result of secondary infection.

Associated Conditions.—The blood is thickened and dark-red in color; thrombosis in the heart or venous sinuses is frequent. The kidneys present marked congestion and degeneration, which are dependent upon the action of the toxins of the disease. Lobular pneumonia is a common complication.

Typhoid fever is distinguished by an acute, specific inflammation of the lymphoid elements of the intestines, particularly of the ileum and upper portion of the colon. The specific cause is the Bacillus typhi abdominalis, described by Eberth and Gaffky. This organism enters the gastro-intestinal tract with drinking-water, milk, or other food, and multiplies in the small intestine (see Part I.).

Pathologic Anatomy.—The specific lesions of typhoid fever occur in the lymphatic structures, notably in the solitary follicles, Peyer's patches, mesenteric glands, and spleen.

The solitary follicles and Peyer's patches of the lower end of the ileum are first affected, but later, or exceptionally in the be-

ginning, the lymphoid collections of the upper part of the ileum and jejunum, or of the cecum and colon, may be involved. At first the follicles and patches are swollen and somewhat reddened by congestion. Within a few days of the onset, however, they lose their congested appearance and present themselves as grayish or white elevations projecting from one to several millimeters above the surface (Fig. 238). Microscopically the lymphoid elements are found in a state of active proliferation, and in addition large round cells (endothelial or epithelioid) are more or less abundant. These large cells are actively phagocytic, and have been discovered in the lymphatic channels at some distance from the local lesions, as well as in the mesenteric glands, and in distant parts. The surrounding mucosa may be normal in appearance, or may be somewhat inflamed. The conditions of the lymphoid structures at this stage, to which the term *medullary infiltration* has been applied, remain unchanged for some days or a week. After the

FIG. 238.—Typhoid fever, showing stage of medullary infiltration; enlargement of lymphoid follicles and Peyer's patches (modified from Kast and Rumpel).

FIG. 239.—Typhoid fever, showing necrosis of Peyer's patches and intense congestion of the bowel (modified from Kast and Rumpel).

first week necrosis is prone to occur. The center of the solitary follicles or part of the Peyer's patch becomes more and more soft

and yellow, or sometimes reddish from absorption of blood-pigment. The necrotic portions are discharged after a few days, leaving an ulcerated surface of regular or irregular outline, and presenting necrotic edges with hemorrhagic infiltration (Fig. 239). The ulcers resulting from destruction of the solitary follicles are small and rounded, while those involving the Peyer's patches are elongated, the long axis being parallel with the axis of the intestine. The ulcers are usually found in an acute stage at the end of the second or at the beginning of the third week of the disease. Resolution may occur without necrosis and ulceration, but more commonly ulcers are formed and healing proceeds more slowly. The lymphoid elements of the follicles and patches are usually permanently destroyed, and healing takes place by proliferation of the fibrous stroma. Occasionally, however, complete restitution of the normal tissues occurs. When the lymphoid follicles of the patches have become necrotic and have been infiltrated with blood dark pigmented spots are formed, and give rise to the condition designated as the "shaven-beard" appearance.

Complications.—Extensive necrosis may lead to erosion of a blood-vessel and hemorrhage; or the wall of the intestine may be completely perforated by the necrotic process, and fatal peritonitis may result. In other instances peritonitis occurs without perforation by direct extension of the inflammatory process through the intestinal wall. Very commonly slight reactive peritonitis is found on the serous surface opposite the ulcers. Extensive peritonitis rarely occurs in this way. Peritonitis in rare instances results from necrosis of the mesentery glands, or from rupture of the spleen.

The mesenteric glands are characteristically enlarged, those nearest the points of ulceration being first and most prominently involved. In the first stage they are soft and dark-red in color, exuding a small amount of liquid on section. Later they become larger, harder, and of whitish appearance; they may finally suffer necrosis and rupture. Usually, however, resolution takes place after the first stage.

The spleen is enlarged in most cases, and presents the characteristics of acute splenic tumor. Very rarely perisplenitis or abscess may occur.

Lesions in Other Parts.—The muscles, particularly those of the abdominal walls, frequently show spots of degeneration of a waxy or hyaline character, as described by Zenker. Very rarely petechial or considerable hemorrhages may be found in the muscles; and abscesses are sometimes met with as sequelæ.

The heart-muscle is involved in perhaps a majority of the cases. The muscle-fibers suffer parenchymatous and hyaline degeneration; and less commonly the intermuscular tissues present the characteristics of acute myocarditis. Acute endocarditis

and inflammations of other serous surfaces are rare in typhoid fever as compared with some other infectious diseases.

Acute degeneration of the kidney and acute nephritis are quite common, and the kidney-substance may present small necrotic or lymphomatous foci. Similar lymphomata occur in the liver and throughout the peritoneum.

Acute lobular pneumonia and croupous pneumonia are frequent complications. Osteomyelitis is rare.

The blood in typhoid fever, unlike other infections, presents no leukocytosis, but, on the contrary, may be characterized by leukopenia, the mononuclear leukocytes predominating.

Tuberculosis.—Tuberculosis of the intestines is very common. It may occur primarily from the drinking of infected milk or consumption of the meat of tuberculous animals. Primary tuberculosis of this character is especially frequent in young infants. More commonly tuberculosis of the intestines is secondary to pulmonary or laryngeal tuberculosis, and is due to the swallowing of sputa.

The usual situation of the lesions is the lower end of the ileum, and it is the lymphoid tissues that are prone to be attacked. At first the follicles or Peyer's patches become enlarged and project above the surface. Soon they undergo necrosis and discharge their contents, leaving more or less irregular caseous ulcers. The follicular ulcers are small and rounded, but the more characteristic lesion is an irregular ulcer extending transversely to the long axis of the bowel and often involving a half or more of the entire circumference. These ulcers usually begin as follicular ulcers; later

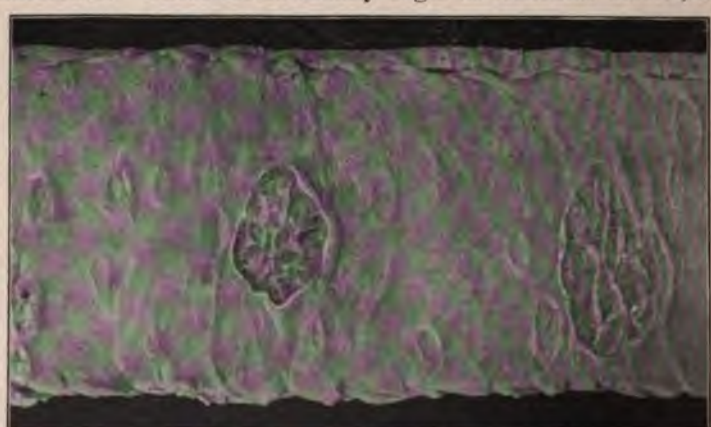

FIG. 240.—Tubercular ulceration of the intestine.

the submucosa is invaded and the tuberculous process extends in a lateral direction along the lymphatic channels running toward the mesentery (Fig. 240).

Microscopically the changes are found to involve the mucous membrane and the adjacent submucous coat. Early caseation is characteristic. On the serous coat may often be seen granular elevations in clusters opposite the ulcers in the mucosa, and extending in lines from the region of ulceration around the bowel toward the mesentery (Fig. 241). These represent tuberculous

FIG. 241.—Miliary tubercles in clusters and disseminated over the serosa (peritoneum) of the intestine; the clusters are situated opposite ulcerations of the mucous membrane (modified from Bollinger).

lymphangitis and small miliary tubercles in the course of the subserous lymphatic vessels.

Tuberculous ulceration rarely causes perforation of the bowel, excepting in the rectum, where periproctitis and *fistula in ano* may result. The ulcers may heal, causing cicatricial distortion or stenosis. Very commonly there is associated tuberculous enlargement of the mesenteric glands, and sometimes the latter are extensively diseased, though the primary intestinal involvement is insignificant. Generalized enteritis of catarrhal character may accompany the specific ulcerative disease.

Syphilis is most frequent in the rectum, though cases of syphilitic disease of the small intestine or colon, in the form of localized or diffuse gummatous involvement, sometimes with secondary ulceration, have been observed, particularly in cases of congenital syphilis.

In the rectum syphilis may appear in the form of warty elevations or as a chancre; also as mucous patches, gummatous nodules or infiltrations. Considerable thickening of the mucosa and submucosa, with ulceration and secondary cicatrization and stenosis (*syphilitic stricture*), may result.

Anthrax occasionally affects the small intestine in persons exposed to infection by their occupations. It is met with among wool-sorters, brushmakers, tanners, and the like. More or less

extensive ulceration is seen in the small intestine, and sometimes in the large intestine. The ulcers are dark-colored and necrotic in appearance, and are commonly surrounded by a hemorrhagic zone. Considerable edema and hemorrhagic infiltration of the neighboring parts of the intestine may accompany the ulceration. The neighboring lymph-glands and the spleen are enlarged. The bacilli of anthrax are found in considerable numbers in the ulcers and in the surrounding tissues.

Actinomycosis of the intestines is very rare. It most commonly affects the region of the cecum, causing first infiltrations and then ulcerations of the mucosa and submucosa.

Enteromycosis is a term applied to intestinal affections resulting from the ingestion of putrid meat, fish, sausages, and the like. Occasionally considerable epidemics may occur. The intestines may present the lesions of catarrhal enteritis or of intense croupous or pseudomembranous inflammation, and there may be erosions or ulceration. Micro-organisms of various sorts have been discovered, but no specific form is recognized. The acute general symptoms, and even the local lesions, may be caused by poisons elaborated by bacteria in tainted foods, rather than by the micro-organisms themselves.

TUMORS.

Connective-tissue Tumors.—Among the benign tumors of the intestines *fibroma*, *myxoma*, and *lipoma* are occasionally met with in the submucosa as small nodular tumors or as pendulous polyps. They may occasion intestinal obstruction and even invagination.

Sarcoma of the intestine is rare. Lymphosarcomatous or lymphadenomatous enlargement of the solitary follicles or Peyer's patches may be met with in leukemia or pseudoleukemia. Round-celled sarcoma springing from the submucosa and deeper layers of the mucosa, and sometimes infiltrating the mesentery, may also occur as an independent and primary affection. Nodules of secondary sarcoma are not rarely met with in the mucosa and submucosa of the intestines (Fig. 242), and the serous covering may be studded with miliary nodules in sarcomatosis.

Epithelial Tumors.—Among the epithelial tumors may be included *inflammatory papilloma*, *adenoma*, and *carcinoma*.

Inflammatory hyperplasia of the mucous membrane may occur in association with chronic inflammations, especially in the large intestine, and may lead to the formation of papillomatous or polypoid elevations of considerable magnitude.

Adenomata are more strictly of the nature of tumors, being independent of inflammatory processes, although no sharp dividing-line can be drawn between the inflammatory proliferations and the

adenomata proper. The latter may occur in the form of flat elevations having a more or less uneven surface and a tendency to

FIG. 242.—Nodule of secondary sarcoma in the mucosa of the intestine (Kast and Rumpel).

hemorrhage and ulceration; or in the form of papillomatous elevations of a cauliflower character. Adenomata arise by

FIG. 243.—Carcinoma of the duodenal papilla (modified from Kast and Rumpel).

hyperplasia of the crypts of Lieberkühn in the duodenum or of Müller's glands, and in their structure they present typical gland-

ular acini, the tubules having a basement-membrane lined with cylindrical epithelium. Adenomata are most frequent in the rectum, but may occur in other parts of the large intestine and in the duodenum.

Carcinoma is the most frequent tumor of the intestines. It occurs in the duodenum, especially at the papilla of the common bile-duct (Fig. 243); at the ileocecal valve, at the flexures of the colon, and in the upper or lower part of the rectum. The appearance is that of a soft, irregular, often ulcerated and bleeding elevation, projecting into the lumen of the gut and causing considerable narrowing, or surrounding the bowel by circular involvement of the entire circumference. The carcinomata of the bowel are, for the most part, cylindrical epitheliomata (Fig. 244) or glandular can-

FIG. 244.—Cylindrical epithelioma of the intestine (Perls).

cers, consisting of atypical acini and tubules, with irregular proliferation and infiltration of the neighboring tissues with masses of epithelial cells. Cases are met with, especially in the rectum, in which there is a clear transition of adenoma into carcinoma (adenocarcinoma), and in general adenomata of the bowel have a tendency to such transformation (Fig. 245). At the lower end of the rectum squamous epithelioma may occur.

The results of carcinoma of the bowel are the same as those of stenosis due to other causes, together with the consequences of the cancerous cachexia and of metastasis. Ulceration of the tumor may lead to perforation.

Myoma of the intestines and multiple *cysts* are occasionally met with.

FIG. 245.—Adenocarcinoma of the rectum (adenoma destruens) (Karg and Schmorl).

PARASITES.

Vegetable Parasites.—Various forms of bacteria are found with such frequency in the intestinal contents that it is difficult to estimate their pathologic significance. Tubercle-bacilli, the bacillus of glanders and of typhoid fever, and the actinomyces produce the specific lesions of these diseases. The Bacillus coli communis is a constant inhabitant, but probably assumes pathogenic properties and leads to inflammatory lesions when the conditions (such as irritation by coarse food, congestion, obstruction) favor its activity and multiplication. Under the same circumstances other micro-organisms likewise become active in the production of enteritis.

Animal Parasites.—The animal parasites are discussed in detail elsewhere, but may be briefly mentioned here with reference to pathologic results occasioned by their presence. Various forms of protozoa have been found, and may occasion inflammations when in considerable numbers. Coccidial psorospermia occur in the epithelium of the villi of the small intestine, and the Megalostoma entericum may be found attached to the epithelium. The Amœba coli may lie free in the contents, or may penetrate through ulcerations. It inhabits the large intestine, and is the probable cause of certain kinds of dysentery.

The larger intestinal parasites are, for the most part, species of vermes. Among the tape-worms Tænia saginata, Tænia solium, and Bothriocephalus latus are the most frequent. Occasionally these may lead to intestinal obstruction by forming thick knots or coils, and sometimes the head of the worm may be attached in the mouth of the bile-duct, causing obstruction and jaundice. Inflammatory changes are rarely met with as a result of these worms.

Among the nematodes, or round worms, the Ascaris lumbricoides, or ordinary round worm, is the most frequent. It is usually multiple, and may occasion obstruction of the intestine or inflammation. Sometimes they perforate the intestinal wall, but it is improbable that the perforation is due entirely to the action of the worm. Previous intestinal ulceration is the more important condition. Obstruction of the bile-ducts or of the appendix may occasionally be due to lumbricoids. The Ankylostoma duodenalis may cause petechial hemorrhages and inflammatory disturbances in the duodenum or jejunum. The worms attach themselves firmly to the mucous surface and may be present in large numbers. The Oxyuris vermicularis, or thread-worm, occupies the large bowel, multiplying in the cecum and descending in the mature state to the rectum ; it may occasion considerable proctitis. In female children vaginitis sometimes results from migration of the worms. The Trichina spiralis when ingested in large numbers occasions violent gastro-enteritis, and its embryos perforate the wall of the intestine and migrate to the muscles.

Larvæ of various forms of flies occasionally occupy the intestinal tract, and owe their presence to the ingestion of the eggs with food. They may occasion enteritis, and may be found in immense numbers in the bowel or the stools.

INTESTINAL RUPTURE AND FOREIGN BODIES.

Rupture may be due directly to traumatism or penetrating wounds ; but more frequently results from ulcerations within. Duodenal (peptic) ulcers not infrequently perforate, and typhoid ulcers occasionally cause rupture. Tubercular, dysenteric, and other ulcers are less prone to penetrate completely. The appendix may rupture from obstruction at its mouth and secondary catarrhal, necrotic, or gangrenous inflammation of its walls. Rectal ulcers frequently cause painful diarrhea, proctitis, periproctitis, and fistulæ.

Intestinal rupture usually leads to rapid peritonitis, but occasionally recovery ensues. A localized peritonitis, by walling off the infected area, may prevent general infection. The rupture may take place between contiguous coils, causing spontaneous intestinal anastomosis.

Foreign-bodies.—Various bodies that have been swallowed

may lodge in the intestines. Occasionally fecal concretions or *enteroliths* are found, especially in the appendix. These consist of a nucleus of epithelial cells, mucus, hair, and the like, surrounded by inspissated fecal matter and earthy salts, phosphate of lime and carbonate of calcium. They may cause considerable irritation, especially in the appendix, and even perforation.

THE LIVER.

Anatomic Considerations.—The liver is peculiar in having a double circulation; one system of vessels, the portal vein and its ultimate subdivision, receiving the blood from the digestive tract for functional purposes; the other system, the hepatic artery and its branches, supplying the nutritive blood for the walls of the blood-vessels and for the interlobular connective tissues, as well as to a certain extent the proper hepatic structure itself. The portal capillaries ramify through the acini and empty into small branches of the hepatic vein lying in the center of the acini. The capillaries of the hepatic artery traverse the interlobular tissue and ultimately empty into the interlobular branches of the hepatic vein. The primary biliary capillaries are merely spaces between the hepatic cells, the larger formed capillaries occupying the interlobular tissues.

MALFORMATIONS AND CHANGES OF POSITION.

Congenital malformations are uncommon. There may be *complete absence of the organ*, especially in certain monstrosities; more frequently *adventitious hepatic tissue* is found in the suspensory ligament or elsewhere. Minor abnormalities in the lobes or fissures are more frequent. *Absence of the gall-bladder* and *congenital stenosis or occlusion of the hepatic ducts* are occasionally met with.

Congenital Alterations of Position.—The liver may occupy the left side in transposition of the viscera. More rarely it is displaced downward, or occupies other abnormal positions.

Acquired Changes of Form.—The most important of these is contraction and lengthening of the organ by lacing. This gives rise to compression along the line of the lower margin of the ribs; the right lobe of the liver may thus be divided into an upper and a lower portion by a deep fissure. The capsule is frequently thickened and the superficial acini atrophic at the line of constriction. Similar indentation by the ribs posteriorly, or by the right crus of the diaphragm, results from pulmonary affections and enlargements of the liver. Other changes of form, due to special diseases of the liver, will be discussed below.

Acquired Changes of Position.—Downward displacement

may result from pleural effusion or emphysema; or it may be due to relaxation and lengthening of the suspensory ligaments. The latter form is more common in women than in men, and is often part of a general enteroptosis. Tight lacing may be a cause of importance. Displacement to the right or left, or tilting upward of the lower edge, may occur in association with various abdominal and thoracic affections.

CIRCULATORY DISTURBANCES.

Anemia of the liver may be part of a general anemia, or it may be due to pressure upon the organ, to various diseases of the liver-substance, or to compression of the blood-vessels. The substance becomes pale and, if the anemia persists, undergoes degeneration.

Active hyperemia is physiologic during digestion, and occurs in association with various inflammatory abdominal diseases. It is rarely extensive, and does not lead to marked pathologic changes.

Passive hyperemia results from obstruction to the circulation due to cardiac or pulmonary diseases, to pleural effusion or adhesions, or to thrombosis or compression of the upper part of the inferior vena cava. It is especially characteristic of cardiac affections, the sluggish venous circulation of the liver accounting for the fact that this organ first evidences failing cardiac power.

The liver increases in size, often considerably; the edges are rounded, and the color on the surface is darker than normal. On section there may be seen deeply congested central veins surrounded by lighter areas, representing the substance of the acini. If the process has persisted, secondary fatty degeneration of the peripheral zones of the acini or atrophy of these takes place, and the light color of such portions, contrasting strongly with the dark, congested central vein, suggests the name *nutmeg-liver* (Fig. 246). In some instances of intense congestion small hemorrhages may occur, especially in the portions lying beneath the capsule. In the later stages degeneration and reduction of size may take place and the organ may become dark-red from deposit of hematogenous pigment. To this form the term *red-atrophy* is sometimes given. In other instances hyperplasia of the connective tissues between the lobules and acini occurs, while at the same time the organ is darkly pigmented. The term *cyanotic induration* may appropriately be given to such. Cases of this sort are in reality instances of *secondary cirrhosis*.

Passive congestion of the liver may occasion considerable disturbance of the hepatic function. The most striking evidence of this is jaundice. This is probably due to the compression of the smaller biliary ducts and capillaries, and in part to swelling of

the lining cells of these channels. The bile at the same time is probably thicker than normal, and does not therefore as readily escape through the ducts as in health.

FIG. 246.—Nutmeg liver: chronic congestion due to cardiac disease (Bollinger).

Embolism and **thrombosis** of the portal vein may occur in consequence of various diseases of the gastro-intestinal tract, particularly in cases of ulcerative enteritis. Embolic occlusion of one of the larger branches of the portal vein may occasion no serious circulatory disturbances, on account of the free collateral circulation and from the fact that the hepatic artery is capable of supplying the entire hepatic circulation. Embolic or thrombotic occlusion of the branches of the hepatic artery is similarly devoid of serious disturbance of the circulation.

Obstruction of the interlobular branches of the portal vein, and particularly when several are coincidently occluded, may occasion decided nutritive disturbances in the hepatic acini. Small areas of necrosis having a grayish or yellowish and somewhat granular appearance, or in other cases foci of necrosis with hemorrhagic infiltration, are the striking lesions. Such conditions are observed in most instances of death from puerperal eclampsia

in consequence of embolism of decidual cells (Fig. 247); and in consequence of various intoxications or infections having their origin in the distribution of the portal circulation. The imme-

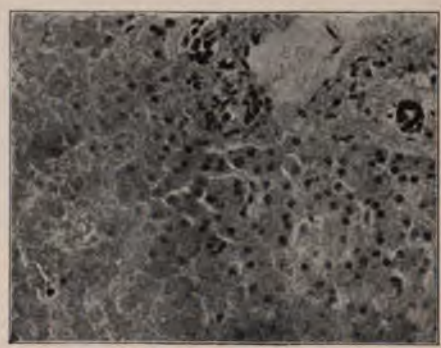

FIG. 247.—Coagulation-necrosis of the hepatic cells in a case of puerperal eclampsia (Karg and Schmorl).

diate cause of the lesions in the latter conditions is hyaline thrombosis of the interlobular portal vessels.

Thrombosis of the portal vein is most frequently the result of infective inflammation of the vein (pylephlebitis), resulting from ulcerative enteritis, appendicitis, or similar processes involving the parts from which the portal blood is received. There may be a gradual ascending inflammation and thrombosis extending from the primary focus of disease to the portal vein; or the latter may be involved in a more direct manner by infectious embolism. The portal vein and its branches in the liver become more or less obstructed, and serious disease of the liver may occur (multiple abscesses). At the same time the obstruction of the vein occasions intense passive hyperemia of the peritoneum, and ascites results.

ATROPHY AND DEGENERATIONS.

Atrophy of the liver occurs in cases of death from inanition or from various organic diseases. (Pressure-atrophy has been referred to above. Acute yellow atrophy is described below.)

The greater part of the liver-structure may be affected, or the atrophy may be limited to the edges or other limited portions. The liver is more or less uneven, and may at the same time be somewhat pigmented.

Microscopically the liver-cells are decreased in size, granular, and dark-colored. At times the acini may disappear entirely, and reactive hyperplasia of the stroma and even proliferation of biliary ducts may ensue.

Localized atrophy occurs in the vicinity of tumors, in the acini surrounded by hyperplastic connective tissue in cirrhosis, and in parts of the liver otherwise subjected to pressure. The liver-cells of the affected part become distorted and decreased in size, and are deeply pigmented (see Fig. 258). In the later stages they break down completely, and are removed. *Red atrophy* (see Congestion of the Liver) is a form of pressure-atrophy with pigmentation, the compression of the hepatic cells being due to overdistention of the hepatic veins and capillaries.

Pigmentation of the liver is prone to occur on account of the sluggish circulation through that organ, and may be of various kinds:

1. Hematogenous pigmentation in the portal areas. Particles of altered blood-pigment are often deposited in the interlobular tissues or in the peripheral zones of the acini in cases of abnormal blood-obstruction in the portal circulation. This is particularly common in pernicious anemia. In this disease the peripheral zones of the acini are habitually infiltrated with pigment-matter, which responds to tests for iron, such as with ammonium sulphid or ferrocyanid of potassium and hydrochloric acid. Somewhat similar pigmentation of the liver may occur in cases of absorption of hemorrhagic effusions in the peritoneum, or in consequence of other forms of blood-destruction. Analogous pigmentation is often met with in the livers and other abdominal organs of drunkards (*hematochromatosis*).

2. Hematogenous pigmentation of the central portions of the acini has been noted in connection with a red atrophy of the liver consequent upon congestion.

3. Biliary pigmentation results from obstruction of the biliary ducts, and is constantly met with in certain forms of cirrhosis and in the vicinity of new growths which compress the biliary passages.

4. Very rarely anthracotic pigmentation has been observed. In one case, at least, there was associated cirrhosis.

Fatty infiltration is more or less physiologic, especially in children and in overfed individuals. Pathologically there may be diffuse infiltration or deposit in the liver-cells of all parts of the organ. Such pathologic fatty-liver may result from overeating and general obesity, or may be due to pulmonary disease or anemic and cachectic conditions. It has generally been held that the immediate cause is retarded oxidation, in consequence of which fat accumulates. It is probable, however, that there is some disease of the hepatic cells, rendering them more active in the storing up, or less active in disposing of fats. This seems especially true in certain cases due to poisons which cause a deposit of fat in the liver, as in geese pampered by antimonial poisoning.

The liver increases in size, often considerably; its edges are rounded, its consistency is doughy, and the color is rather yellow-

ish and glistening. On section there may be visible exudation of oil-drops and the knife may be covered with droplets.

Microscopically the process is found to begin in the peripheral portions of the acini in the form of droplets within the hepatic cells. Soon these increase in size by confluence, adjacent cells are involved, and the entire acinus eventually becomes affected (Fig. 248). In extreme cases the hepatic cell is filled with a single

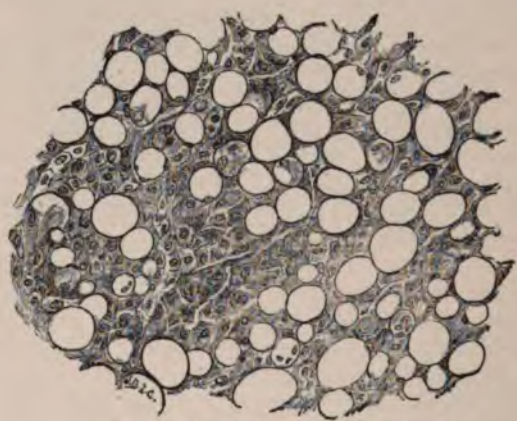

FIG. 248.—Fatty infiltration of the liver.

large oil-drop, which compresses the protoplasm and nucleus. The blood-vessels and other structures may be completely hidden from view ; and the pressure of the fatty deposit may be sufficient to produce a certain degree of anemia, though not enough to occasion serious circulatory disturbances. The functional activity of the liver is diminished.

Parenchymatous degeneration, or cloudy swelling, occurs in various infectious fevers and in consequence of intoxications, notably by phosphorus, arsenic, and antimony. The liver is somewhat enlarged, and of an opaque, grayish-yellow appearance, the outlines of the lobules being extinguished. Microscopically, the liver-cells are found filled with fine albuminous granules more or less obscuring the nucleus. In most instances cloudy swelling terminates by return to the normal state ; but if the intoxication or infection is continued, fatty degeneration may result.

Fatty degeneration may occur as the result of severe anemia, particularly pernicious anemia, or, following cloudy swelling, as the result of infectious diseases or of intoxications. Among the infections, pyemia, yellow fever, relapsing fever, and erysipelas are notable examples. The liver may be greatly decreased in size and softer than normal ; the substance not rarely is friable. The color is yellowish, and oil-drops may exude from

the surface. Microscopically the hepatic cells are filled with small granular particles or droplets of fat, and in the advanced stages they break down completely into granular detritus. Fatty degeneration of localized areas of the liver or of individual acini or cells occurs in association with chronic hepatitis or other diseases causing pressure upon the acini.

Acute Yellow Atrophy.—The most advanced fatty degeneration of the liver occurs in the affection of the organ termed *acute yellow atrophy*. This condition is most frequent in young women, and especially in those addicted to the excessive use of alcohol. Occasionally syphilis seems the etiologic factor, and in some instances of phosphorus-poisoning the appearance of the liver is the same as that which is recognized as acute yellow atrophy. Finally, some cases are idiopathic, arising without recognizable cause. Parturition seems a determining cause in some cases. Micro-organisms of various kinds have been found, and it is likely that all cases are toxic or infectious.

Pathologic Anatomy.—The liver is decreased in size and becomes remarkably soft and friable. On section there is found a variegated appearance, the prevailing color being a brownish or grayish-yellow, in which are scattered bright or dark-red areas. The yellowish areas represent the degenerated and pigmented hepatic cells; the reddish areas foci of hemorrhagic infiltration or

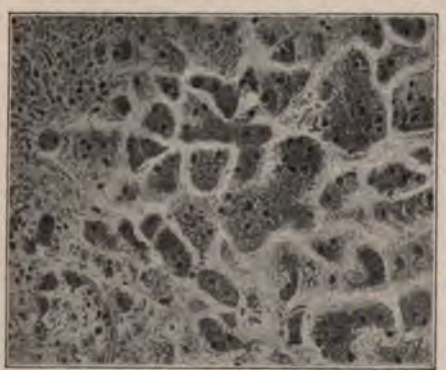

FIG. 249.—Acute yellow atrophy of the liver, showing extensive fatty degeneration and in places complete destruction of the liver-cells (Kast and Rumpel).

pigmentation. The process usually begins in the left lobe, but rapidly involves the entire organ. Sometimes the liver is increased in size during the initial stages, and occasionally a liver enlarged by previous disease suffers terminal acute atrophy.

Microscopically the hepatic cells are found to have undergone rapid fatty degeneration or necrosis, and are filled with or replaced by yellowish pigment-particles. As the process advances, the cells are completely destroyed (Fig. 249). In the red areas referred to,

infiltration with blood-cells and hematogenous pigmentation are observed.

Associated Conditions.—Acute yellow atrophy leads to intense cholemia, in consequence of which biliary pigmentation of the various structures of the body may develop. Petechial hemorrhages may occur in the mucous or serous membranes, or in the skin. The urine contains leucin and tyrosin. More or less profound acid intoxication may occur (see Acid Intoxication, Part I.).

Amyloid degeneration occurs in consequence of syphilis, tuberculosis, and suppurative diseases of the bones, or as a result of long-standing cachexia. It is habitually associated with amyloid disease of the spleen, and often of the kidneys and other structures.

Amyloid degeneration begins in the smallest blood-vessels between and within the acini, causing a more or less pronounced thickening of their walls. The liver-cells themselves may be



FIG. 250.—Amyloid liver (from a photograph by Dr. Wm. M. Gray).

secondarily involved, but more frequently undergo atrophy and fatty degeneration in consequence of the pressure and of diminished nutrition due to compression of the blood-vessels (Fig. 250).

The liver is enlarged and denser than normal. Not rarely it presents a striking translucency, and on section the color is grayish-white or yellow. The peripheral and central zones of the acini are sometimes readily distinguished by their light color from the innermost portions, which are least affected.

Dropsical infiltration of the liver-cells occurs in cases of intense infection and intoxication, especially such as originate in some part of the portal circulation. It is found particularly in the vicinity of necrotic areas due to embolic occlusion of the interlobular portal veins. The liver-substance is swollen, and microscopically the cells are cloudy and ofttimes vacuolated.

INFLAMMATIONS.

Hepatitis, or inflammation of the liver, may be of several forms: a parenchymatous, an acute interstitial, or a chronic interstitial.

Parenchymatous Hepatitis.—In the course of various infections and intoxications a certain amount of parenchymatous degeneration of the liver-cells may take place. This was formerly described under the name parenchymatous hepatitis. The term is generally inappropriate, though in some instances there is associated with the degeneration of the hepatic cells a certain amount of cellular infiltration and reactive inflammation. To such cases the term parenchymatous inflammation might be applied, though in reality even these are more degenerative than inflammatory in nature.

Acute Interstitial Hepatitis, or Abscess of the Liver.—In practically all, if not all, cases abscess of the liver is due to the action of micro-organisms. The bacteria may gain access in several ways. In some cases penetrating wounds, or perforation of gastric or duodenal ulcers or of other pathologic lesions into the liver, occasion direct infection. In other cases the micro-organisms are carried in the circulation and enter the liver with the portal or hepatic blood, or by retrograde embolism through the hepatic veins from the vena cava. Finally, infection may occur by invasion of the bacteria along the bile-ducts.

Most frequently hepatic abscess is secondary to ulcerative disease of the intestines, notably dysentery. In this disease the specific amebæ are carried to the liver in the portal circulation, and occasion necrotic foci in which the bacteria carried within the amebæ multiply and give rise to the further changes constituting an abscess. Similar embolic abscesses occasionally follow appendicitis and perityphlitis, or various forms of intestinal ulceration. Thrombophlebitis of the portal vein not rarely extends to the smaller branches within the liver, and occasions multiple suppurative foci.

In cases of general pyemia multiple abscesses of the liver may occur, especially when the primary infection occurs within the abdomen. Infection by invasion along the biliary tract is especially prone to occur when there is obstruction of the bile-ducts by calculi or otherwise. In tropical countries traumatism without visible contusion may lead to abscesses, and it is not unlikely that micro-organisms from the biliary passages penetrate the hepatic structure in the injured portions.

Among the micro-organisms that have been discovered are the streptococci and staphylococci, the Bacillus coli communis, and others less frequently.

Pathologic Anatomy.—Dysenteric and traumatic abscesses are

usually solitary, and generally occupy the right lobe. In the early stages they appear as spots of grayish or yellowish color, in which the division of the lobules is lost and which assume a more and more granular appearance. Subsequently softening takes place, and a cavity is formed. This increases in size until in advanced cases it may reach enormous proportions. The contents consist of curdy or creamy pus having a yellowish, brownish, or often quite reddish appearance, and the wall is composed of an ill-formed pyogenic membrane. The abscess may consist of a single cavity, or may be partially lobulated. Sometimes there are multiple abscesses. If the cavity is small, resorption of the pus may take place and a cicatrix may result. In other cases inspissation and encapsulation ensue. Large abscesses may rupture into the pleura, into the stomach or intestines, into the peritoneal cavity, or externally. Not rarely the diaphragm and lungs are penetrated, and the pus is evacuated through the bronchi.

Metastatic abscesses, and those due to infection from the biliary ducts or to suppurative pylephlebitis, are multiple and usually of small size.

Chronic interstitial hepatitis, or **cirrhosis** of the liver, is a form of diffuse hyperplasia of the connective tissue, beginning in the interlobular tissues and sometimes extending into the acini, or causing secondary changes in the liver-cells. Hyperplasia of the interlobular bile-ducts, and less frequently of the hepatic cells, may be observed.

Etiology.—Cirrhosis of the liver is essentially the result of hematogenous irritation. The most frequent cause is alcohol, and it is particularly frequent in persons who consume raw spirits. Overeating, with a sedentary life and a gouty diathesis, may also contribute. Other cases are secondary to infectious diseases, notably to syphilis, malaria, or tuberculosis.

Occasionally cirrhosis is due to the absorption of irritants by the portal radicles and their transference to the liver in cases of chronic peritonitis. Certain cases are due to chronic congestion of the hepatic circulation in consequence of cardiac or pulmonary disease; and, finally, obstruction of the bile-ducts may lead to another group of cases.

Morbid Anatomy.—Several varieties having rather marked differences in their macroscopic and even microscopic appearances may be distinguished. The process is essentially the same in the different forms and the causes are similar. The most prominent varieties are *atrophic cirrhosis, hypertrophic cirrhosis,* and *biliary cirrhosis.*

Atrophic cirrhosis (Laennec's cirrhosis) is the ordinary form, which is also known by the name "Gin-drinker's liver." In the earliest stages the liver is often enlarged, but in the typical advanced form it is contracted, extremely hard, granular, or irregu-

larly uneven on the surface, and on section resistant to the knife (Fig. 251). The size of the liver, even in advanced stages, is by no means always small. A study of statistics obtained at the post-mortem table shows that the liver in perhaps a majority of the cases of otherwise typical Laennec's cirrhosis is larger than the

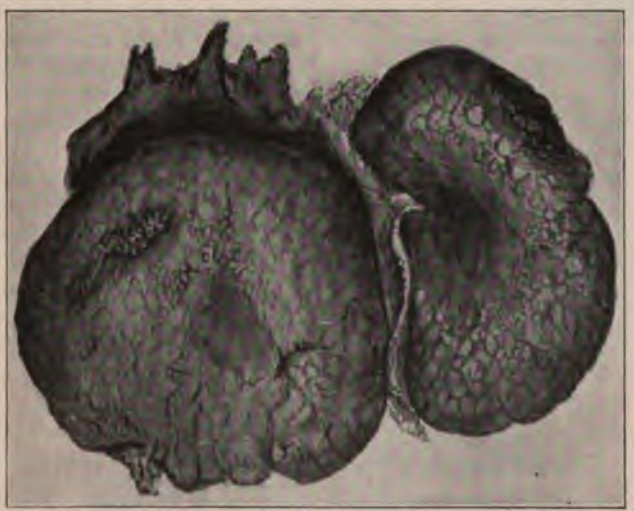

FIG. 251.—Atrophic cirrhosis of the liver of a boy aged sixteen years, showing also thickening of the capsule and ligaments (perihepatitis).

normal organ. The surface of section presents bands of connective tissue surrounding groups of acini, and compressing them so that they rise above the surface. The connective-tissue bands are dull gray or white in appearance, the enclosed acini yellowish or brownish.

Microscopically the process is found to begin as a proliferation of the connective tissues around the interlobular branches of the portal vein. In the earlier stage there are found round-cell infiltration and proliferation of fibroblastic cells, causing moderate obstruction to the portal circulation. Later the connective tissue becomes sclerotic, greater compression of the portal veins ensues, and considerable obstruction of the circulation results. At the same time the acini are compressed and may suffer degeneration. This, however, is rarely pronounced. There is little tendency to extensive invasion of the acini themselves by the inflammatory process. New-formed biliary ducts may be present in considerable numbers in the hyperplastic interlobular tissue.

Associated Changes.—The marked result of atrophic cirrhosis is obstruction to the portal circulation. This occasions congestion of the spleen and gastro-intestinal mucosa, and eventually ascites. When the obstruction becomes extreme collateral circulation may

relieve the congestion of the portal system. The most prominent anastomoses are those between the gastric and esophageal veins, and between the hemorrhoidal veins and the veins of Retzius with the retroperitoneal veins. The veins of the round ligament increase in size and communicate with the superficial veins at the umbilicus.

Gastro-intestinal catarrh and enlargement of the spleen are usually prominent in cirrhosis. Jaundice is rare, because the bile-ducts are rarely compressed.

In some instances the liver is large and smoother, softer and lighter in color, from the fact that considerable fatty infiltration of the acini is associated with the cirrhosis (Fig. 252). In the

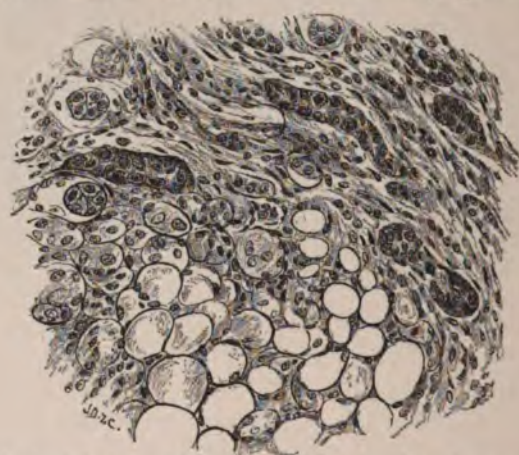

FIG. 252.—Cirrhosis of the liver, showing new-formed connective tissue, proliferated bile-ducts, and fatty infiltration of some of the hepatic cells.

later stages such cases may become converted into the typical form by absorption of the fat.

Hypertrophic cirrhosis is perhaps more frequent in warm climates than elsewhere. The liver is uniformly enlarged, smooth, or moderately granular on the surface, and indurated. On section the color is seen to be more or less yellowish or greenish, and either uniform or mottled.

Microscopically proliferation in the interlobular connective tissues is found, as in the atrophic form, but it does not bear the same relation to the portal veins and is less prone to cicatricial contraction. Unlike the atrophic form, there is decided extension into the peripheral zones of the acini, and everywhere between the columns of hepatic cells there may be seen proliferated fibroblastic cells. Within the new-formed connective tissue may be seen columns of low cylindrical cells surrounding a narrow canal. These are proliferated bile-ducts. Proliferation of the liver-cells

themselves is also frequent, and throughout the organ the cells are found more or less deeply stained with biliary pigment.

Associated Changes.—The most prominent is jaundice. Obstruction of the portal circulation rarely becomes marked.

Biliary cirrhosis is a form of chronic hepatitis consequent upon obstruction of the biliary ducts. The first effect of such obstruction is a swelling of the liver, due to the retention of bile, and perhaps also to congestion. Eventually the stagnation of the bile, with production of irritant substances, leads to reactive inflammation.

The appearance of the liver is much the same as that seen in hypertrophic cirrhosis of the ordinary type. The organ is uniformly enlarged, and may be somewhat granular upon the surface or entirely smooth. On section the substance is found to be deeply bile-stained, and has a yellowish or greenish color. The substance is firm, and the overgrowth of connective tissue may be visible on the surface.

Microscopically the first discoverable changes are spots of insular necrosis in the peripheral zones of the acini. Subsequently

FIG. 253.—Perihepatitis associated with cirrhosis of the liver.

proliferation of connective tissue replaces these and spreads to the interlobular tissues. Proliferation around the interlobular biliary capillaries (*periangiocholitis*) may be a striking characteristic from the first, and multiplication of new bile-ducts and of hepatic cells is frequently observed. In cases of absolute obstruction of the gall-ducts, and in cases in which active fermentative changes in the bile have occurred, rapid fatty degeneration and acute atrophy of the liver may be the terminal change.

Perihepatitis.—Inflammation of the capsule of the liver and

of the superficial portions of the hepatic structure may be associated with cirrhosis (Fig. 253), and not rarely occurs in consequence of chronic peritonitis. It may lead to considerable thickening of the capsule. The pressure of the contracting fibrous tissue may occasion atrophy of the underlying hepatic substance, and a more or less uneven and atrophic organ results. Primary inflammation of the capsule may be an expression of syphilitic infection, and may occur alone or in association with thickening of the peritoneum. Reference will be made, in the discussion of diseases of the peritoneum, to a special form of hyperplastic perihepatitis—that known as the *Zuckergussleber* of Curschmann.

HYPERTROPHY.

The regeneration after injuries of the liver shows the power of the liver-cells to undergo active multiplication. Not rarely active hyperplasia of liver-cells throughout the entire organ may occur in association with other diseases, notably hypertrophic cirrhosis. A simple hypertrophy of the liver also occurs in certain well-developed, robust individuals. Enlargements of the liver formerly regarded as hypertrophies are, for the most part, due to pathologic conditions.

RUPTURE OF THE LIVER.

Rupture may occur from direct traumatic injury, and is particularly common in the new-born when forcible delivery has been necessary. In the latter cases small injuries with secondary hemorrhagic infiltration are observed near the surface of the organ. Portions of liver-cells may be loosened and may be carried as emboli to the lungs. The injury is repaired by active hyperplasia of the liver-cells and of the biliary capillaries, and in this manner the affected part may be restored without the development of scar-tissue. Large injuries, however, occasion the formation of cicatricial tissue.

INFECTIOUS DISEASES.

Tuberculosis may occur in the form of minute, translucent, miliary tubercles, which may be scarcely visible to the naked eye (Fig. 254), or in the form of larger foci. Tuberculosis of the liver is always a secondary disease. The tubercles arise in the interlobular tissue or from the acini themselves. The larger caseous tubercles are rare; they may be associated with diffuse cirrhotic contraction of the organ. Miliary tuberculosis of the capsule of the liver not rarely occurs in tuberculous peritonitis.

Syphilis is met with in the form of diffuse infiltration and cirrhosis, or in the form of gummata. Either of these varieties may be found as a result of acquired or of hereditary syphilis.

In the diffuse form the liver presents much the same appearances as in atrophic cirrhosis, but the connective-tissue bands are much more pronounced and the liver is prone to be irregu-

FIG. 254.—Miliary tubercles in the liver.

larly contracted and lobulated (Fig. 255). Gummata may occur in any part of the organ, and may be single or multiple, presenting themselves as rounded, yellowish, or grayish masses,

FIG. 255.—Syphilitic cirrhosis of the liver: lobulated liver (Kast and Rumpel).

ofttimes showing central necrosis and surrounded by connective-tissue hyperplasia (Fig. 104). Complete cicatrization may lead to decided scar-formation. In addition to these forms, congenital

syphilis may manifest itself in the form of a uniform, diffuse connective-tissue hyperplasia and round-cell infiltration. The liver-cells are pushed apart and are ill-developed or atrophic (Fig. 256).

FIG. 256.—Diffuse congenital syphilis of the liver.

Leprosy occasionally affects the liver, causing the formation of nodular masses.

TUMORS.

Fibromata, lipomata, and **myomata** are occasionally observed as nodular masses, but have little significance.

Angioma is a more important form. This tumor occurs upon the surface of the organ, and is usually of small size, rarely exceeding that of a walnut. It is more commonly found in persons who have died at advanced years than in young persons. Angiomata appear as dark-red or bluish, slightly elevated areas, either sharply outlined and encapsulated, or merging gradually into the surrounding tissue. Microscopically they are found to be cavernous angiomata, and doubtless owe their origin to dilatation of the capillaries, with coincident atrophy of the liver-cells.

Sarcoma of the liver may occasionally be primary, but is exceedingly rare. Secondary sarcoma, on the other hand, is very common, especially the melanotic form following primary sarcoma of the eye.

Lymphadenomata are frequent in the liver in the course of the generalization of leukemic lymphadenoma; but it has not as yet been fully determined to what extent these are to be considered as true tumors, and to what extent as mere infiltrations of leukocytes consequent upon the enormous leukocytosis of this disease. Similar lymphomatous nodules, though much less marked and numerous, occur in typhoid fever and other infectious diseases.

Adenoma of the liver is met with in several forms. There may be either nodular masses, more or less encapsulated and of grayish-white or pinkish color, or a form of diffuse infiltration of the liver-substance by encapsulated nodules of similar character. Considerable cirrhosis of the liver may be associated with the latter cases, and they cannot be clearly distinguished from cirrhotic cancer (see below).

Carcinoma of the liver is rather rare as a primary tumor, but, like adenoma, may be nodular or diffuse. The *nodular* or *massive cancer* appears as a single mass of varying size, ofttimes surrounded by local metastatic nodules. On section the color is grayish or pinkish, and there may be central necrosis and soften-

FIG. 257.—Cirrhotic cancer of the liver (Hanot and Gilbert).

ing. *Diffuse hepatic cancer* occurs as a widespread and more or less uniformly distributed infiltrating growth. Not rarely in such cases there is associated cirrhosis, and the macroscopic appearance of the liver may be strikingly like that of an ordinary cirrhosis, though the liver is sometimes much enlarged (Fig. 257). The terms *cirrhotic cancer* and *cancer with cirrhosis* have been applied to this form. Finally, the diffuse form may surround and spring from the periportal structures, and may ramify in the form of an interlobular infiltration.

Formation and Structure of Adenomata and Carcinomata.—Microscopically there is no sharp dividing-line between these growths. The adenomata present tubular formations of a more or

less elongated and tortuous character, composed of cylindrical or of more irregular-shaped epithelial cells. In some instances these are strikingly like new-formed biliary capillaries, and perhaps they occasionally originate from these structures. More commonly, however, the origin would seem to be from the hepatic cells themselves. The columns of hepatic cells undergo proliferative change, and at the same time become somewhat transformed, assuming the tubular arrangement of adenoma. Occasionally adenoma and cystic adenoma originate from the mucous glands of the larger biliary ducts. When cirrhosis is associated with adenomatous infiltration it is probable that the primary change is a cirrhotic overgrowth which induces secondary hyperplasia of the epithelial cells, instead of degenerative changes, such as usually result from the pressure of new-formed fibrous tissue.

Carcinoma of the liver is similar in origin and structure to adenoma. The cellular acini and tubules are more irregular, and there is an evident tendency to diffuse infiltration and atypical formation of acini.

Secondary carcinoma of the liver is very common as a result of carcinoma of the stomach or of other parts of the portal

FIG. 258.—Metastatic nodules of carcinoma on the surface of the liver (Hanot and Gilbert).

distribution. It is usually due to cancerous embolism in the portal capillaries, with subsequent development of the emboli (Fig. 259). The liver becomes enlarged, and presents nodular masses upon its surface or within its substance. These nodules vary from the size of a pea to that of an apple, and are frequently sharply delimited by capsule-formation, especially those which have reached considerable size. Not rarely the nodules are indented upon the surface (umbilicated) from central softening or from contraction of fibrous tissue within (Fig. 258). Secondary

cancer of the liver may also result from direct extension of cancer of the stomach or of the gall-bladder and biliary ducts. In all cases the new growths tend to compress the bile-ducts and lead to biliary pigmentation of the liver-substance, as well as to general icterus.

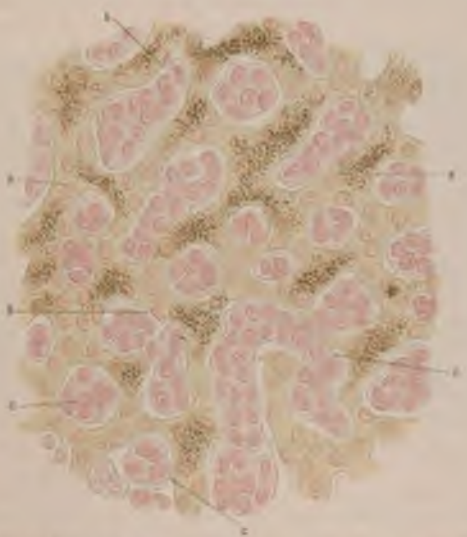

FIG. 259.—Secondary cancer of the liver: *a*, columns of liver-cells filled with bile-pigment; *b*, endothelial walls of capillaries; *c*, carcinomatous emboli in the capillaries (Hanot and Gilbert).

Cysts of the liver are rare. They may spring from the biliary ducts which have suffered simple dilatation, or from the mucous glands of the larger bile-ducts (cystic adenoma). Occasionally small cysts are seen which suggest origin from dilatation of the lymphatic channels.

PARASITES.

Of the protozoa, coccidial *Psorospermiæ* (Fig. 260) have been occasionally demonstrated in the human liver in small nodular tumors; but a more important parasite is the *Amœba coli*, occurring in abscess of the liver secondary to amebic dysentery. The pus of the abscess may contain immense numbers of the amebæ, and doubtless these organisms bear an important relation to the lesion, perhaps causing necrosis by their own activity and then liberating pyogenic organisms which they have carried from the intestines, and which complete the pathologic process. The larval *Pentastoma denticulatum* is occasionally met with.

The *Distoma hepaticum* and the *Distoma lanceolatum* occasionally infest the biliary ducts, and the *Distoma hematobium* the portal vein. *Ascarides* sometimes creep upward in the biliary ducts as far as the branches within the liver. The *Cysticercus cellulosæ* is a rare parasitic formation.

Echinococcus cyst.—The most important parasitic disease of

FIG. 260.—Coccidia in the wall of a bile-duct and the adjacent hepatic structure of a rabbit.

the liver is the echinococcus-cyst, caused by the presence of the larvæ of the Tænia echinococcus (see Part I.). This parasite occasions cystic formations of various kinds within the liver. The cyst has a double wall: the outer, of connective tissue; the inner,

FIG. 261.—Echinococcus multilocularis (Luschka).

a parenchymatous membrane, from which buds (brood-capsules) and secondary cysts are prone to originate. There may be a single cyst containing clear liquid of low specific gravity, or a mother-cyst containing daughter-cysts, either upon the inner wall or floating free within the liquid after their separation. Some-

times even granddaughter-cysts are formed. Occasionally the daughter-cysts are found outside of the mother-cyst, extrusion in such cases having taken place. A form of multilocular cyst is more rarely observed in which there are numerous small cysts embedded in more or less firm connective tissue (Fig. 261). Echinococcus-cysts may rupture into the abdomen or into surrounding viscera. The most serious condition is rupture into the

FIG. 262.—Echinococcus-cyst of the liver (from a specimen in the Museum of the Philadelphia Hospital).

vena cava, as the result of which hydatid disease of the heart, the brain, or other organs may ensue. Bacterial invasion occasionally takes place, and abscess may result. Finally, the liquid contents may be absorbed, and the cyst may be reduced to a small cavity having a shrivelled wall and containing granular or caseous detritus (Fig. 262). Echinococcus-cysts may press upon the gall-duct, producing jaundice, or upon the portal veins, causing ascites.

THE BILIARY DUCTS AND GALL-BLADDER.

INFLAMMATIONS.

Cholangitis, or **inflammation of the biliary ducts,** is most frequently secondary to duodenal catarrh, though it may be the result of direct irritation by gall-stones, by foreign bodies which have entered from the intestine, or by parasites or bacteria. In the cases secondary to duodenitis the inflammation usually extends but a short distance upward from the mouth of the common bile-duct, but there may sometimes be more extensive involvement of the ducts, and the mucous membrane of the gall-bladder may be affected at the same time. The mucosa is swollen, more or less edematous, and secretes abundant mucus. The

result is obstruction of the duct with retention of bile and jaundice.

Suppurative cholangitis may result from bacterial invasion and fermentation of retained bile, or, in a localized form, from the impaction of a gall-stone. More rarely it is due to rupture of suppurative foci in the liver into the gall-ducts; and occasionally it has been found as an independent affection associated with pyemia or other infectious diseases. Among the micro-organisms discovered in suppurative cholangitis the pyogenic micrococci and the Bacillus coli communis are most frequent. The bile-ducts are filled with more or less decomposed bile, or with puriform liquid, and the walls of the ducts, especially the larger ones, may present an ulcerated or necrotic appearance. Small dilatations may occur in places where the duct has become deeply ulcerated, and later hepatic abscesses of considerable size may form.

Chronic cholangitis may be the outcome of an intense acute or repeated acute attacks, but is more commonly met with as a consequence of chronic obstruction of the ducts and retention of bile. A localized form, causing cicatricial stenosis, results from intense inflammatory lesions following the passage of stones. The gall-ducts in chronic cholangitis are more or less thickened, and in the cases due to obstruction may be considerably dilated.

Results of Cholangitis.—In the acute form extension may take place to the ducts within the liver, and in case of bacterial invasion pericholangitis and abscesses may form. More commonly acute cholangitis leads to but a temporary overfilling of the biliary capillaries with bile, and in consequence to obstructive jaundice. When the obstruction is continued for a considerable length of time reactive changes occur in the liver, constituting the form of cirrhosis called biliary cirrhosis (see page 533).

Cholecystitis, or **inflammation of the gall-bladder,** may result from extension of cholangitis, or may be due to the irritation of retained bile or of gall-stones. It is prone to assume a purulent character; and the gall-bladder may become filled with pus (*empyema of the gall-bladder*). This may rupture, discharging into the abdominal cavity, into adjacent viscera, or externally. The wall of the gall-bladder is usually much thickened, and the mucous membrane is swollen and ulcerated.

STENOSIS AND DILATATION.

Stenosis of the bile-ducts is most commonly the result of acute inflammation, causing thickening of the mucosa and accumulation of mucus. It may result from chronic cholangitis with cicatricial overgrowth of connective tissue; from the impaction of gall-stones, or the presence of various foreign bodies, such

as particles of food, mucus, round-worms or other parasites within the duct; from pressure by aneurysms, by tumors of the head of the pancreas, pylorus, duodenum, lymphatic glands, or of the liver; and from tumors of the gall-ducts themselves. Sometimes it is due to the constriction of adhesions resulting from peritonitis. Obstruction of the ducts leads to the retention of bile and dilatation of the ducts above, with consequent enlargement of the liver and jaundice. Obstruction of the cystic duct, which is most frequently due to the impaction of a stone, may occasion dilatation of the gall-bladder with dropsical liquid, in consequence of the passive hyperemia produced by compression of the veins at the neck of the gall-bladder. This condition is spoken of as *dropsy of the gall-bladder*. Sometimes suppurative inflammation occurs, and empyema of the gall-bladder results.

Contraction of the gall-bladder, or even complete shrinkage or atrophy, may result from obstruction at the mouth of the cystic duct, or from inflammatory processes within its walls or surrounding it.

Dilatation of the ducts or of the gall-bladder most frequently results from stenosis of the ducts below.

GALL-STONES; CHOLELITHIASIS.

Gall-stones are concretions resulting from inspissation of bile, or from the deposit of various substances from the bile. Most frequently they are formed in the gall-bladder; occasionally they originate in the bile-ducts.

Etiology.—The causes are imperfectly understood. Advanced years, the female sex, sedentary life, and high living seem to be factors of importance. Inflammatory conditions leading to obstruction and retardation of the outflow of bile, and also to desquamation of epithelium, which, with mucus, serves to form the nuclei of the stones, seem to be among the causes. Besides these conditions there are probably indefinite alterations of the bile which permit of precipitation of some of its constituents, notably cholesterin. Bacterial decomposition of the bile and inflammation of the ducts, causing epithelial desquamation, are regarded as important factors by some authorities.

Structure and Pathologic Anatomy.—Gall-stones may be single or multiple, and may vary in size from minute granular particles of biliary sand to calculi several centimeters in diameter. When single they occur as rounded or oval masses; when multiple they are prone to be marked with facets; when formed within the bile-ducts they are elongated. Biliary sand is, for the most part, composed of biliary pigments in combination with calcium salts. The larger stones on section usually show a central nucleus composed of epithelium or mucus mingled with inspissated bile, sur-

rounded by a zone of somewhat radiating and crystalline structure, composed of cholesterin. Around this may be a coat of bile-pigment. In other cases the entire stone is formed of biliary pigments in combination with calcium salts, or more rarely the calculus consists entirely of carbonate of lime.

Gall-stones may lie in the gall-bladder or ducts without causing serious disturbances, or from time to time attacks of biliary colic denote their passage through the ducts to the bowel. They may pass through the ducts into the intestine when of small size, but often become impacted in the lower part of the common duct, generally just above the duodenal papillæ or in the mouth of the cystic duct. Secondary changes in the gall-bladder (dilatation and inflammation) and in the liver (enlargement, cirrhosis) may result; and the stone may cause local ulceration, and may finally escape into the bowel or into other parts by ulceration. Occasionally gall-stones remain impacted for long periods without causing serious disturbances, enough space remaining to permit the escape of bile.

TUMORS.

Tumors of the gall-ducts and gall-bladder are rare. *Primary carcinoma* arising from the mucous glands is the most important. This appears as an irregular elevation of the mucous surface, and rapidly infiltrates the adjoining parts. In cases of primary cancer of the gall-bladder the liver is soon involved. Gall-stones are present in a great majority of the cases and probably play an important etiologic part by their continuous irritation. On the other hand, the gall-stones may form in consequence of the stagnation of bile and other local conditions caused by the tumor. *Secondary carcinoma* of the gall-bladder or ducts most frequently results from cancer of the liver. The lower end of the duct may be involved in cases of carcinoma of the papilla of Vater. *Sarcoma, fibroma,* and *other tumors* are rare.

JAUNDICE.

Jaundice, or **icterus,** is a discoloration of the skin and other parts, resulting from the presence in the blood of biliary pigments.

Etiology.—Jaundice has been described as being of two forms, the *obstructive, mechanical,* or *hepatogenous,* and the *non-obstructive* or *hematogenous* variety. This distinction, however, has been to a large extent abandoned, and it is now admitted that the abnormal coloring-matter in all cases originates in the liver, and is invariably a hepatic pigment.

Among the distinctly mechanical causes of jaundice the most frequent is occlusion of the ducts by catarrhal duodenitis and cholangitis. To this form the term *catarrhal jaundice* is generally

applied. Less commonly obstruction may be occasioned by foreign bodies, gall-stones, or parasites within the ducts; by the pressure of tumors of the duodenum, pancreas, and the lymphatic glands of the liver or of the gall-ducts themselves; by the pressure of aneurysms upon the ducts; or by occlusion of the biliary passages within the liver by abscess, hydatid cysts, hypertrophic cirrhosis, carcinoma, or other tumors. Congestion of the liver may lead to jaundice by the swelling of the organ consequent upon the overfilling of the vessels with blood, or by reason of the resorption of bile due to the alterations of pressure of the blood in the different vascular channels. Hematogenous jaundice was formerly regarded as due to disintegration of the blood in the general circulation, but it is now recognized that formation of the pigments can take place only in the liver. There are, however, instances of jaundice in which active hemolysis is an element of importance. Jaundice of this character occurs in various severe infections, such as yellow fever, acute yellow atrophy of the liver, the jaundice of the new-born, and in consequence of certain intoxications (phosphorus, toadstools, the venom of snakes). Several explanations may be applied to cases of this kind. Sometimes excessive blood-destruction leads to formation of abnormally large quantities of bile (*polycholia*), and in consequence to absorption of biliary pigment by the lymphatics in the liver. In other cases toxic degeneration of the hepatic cells may lead to stimulation of the hepatic function, or to swelling of the cells and compression of the biliary capillaries, and in consequence to absorption of the bile. Finally, in the jaundice of the new-born, as well as in some instances of sudden emotional jaundice, disturbance of the circulation within the liver may be a potent cause.

Pathologic Anatomy.—Microscopic examination of the liver may show the biliary capillaries distended with bile and the hepatic cells themselves more or less pigmented. The bile is absorbed by the lymphatics, and ultimately reaches the general circulation and pigments the tissues. The earliest evidence is seen in the intima of the vessels; later, all the tissues and organs of the body may be involved, and visible discoloration appears in the skin and external mucous membranes. The urine is dark brownish or greenish in color, and all of the secretions and liquid exudates may be pigmented. In cases caused by obstruction of the bile-ducts the bile cannot reach the intestines and the stools have a quite characteristic putty color. In "hematogenous" jaundice the color of the stools is to a certain extent maintained. Intense disturbances, especially of the nervous system, result from excessive cholemia, but are due to the cholic acid salts, rather than to the biliary pigments.

THE PANCREAS.

CONGENITAL ABNORMALITIES.

Complete absence has been met with in monstrosities. More frequently an adventitious pancreas or heterotopic pancreatic tissue is observed. Small nodules of pancreatic tissue may be found in the omentum, the wall of the intestines, or elsewhere.

CIRCULATORY DISTURBANCES.

Active hyperemia occurs during digestion and in association with acute inflammation.

Passive hyperemia occurs in cases of obstruction to the portal circulation, but rarely leads to notable changes.

Hemorrhage may occur in the pancreas, in the form of minute petechiæ or diffuse hemorrhagic infiltration, as the result of passive congestion or of various hemorrhagic and infectious diseases, such as purpura, scurvy, septicemia, or the extreme anemias.

More extensive hemorrhage in the pancreas and in the tissues surrounding it sometimes occurs as an "idiopathic" affection, the causes being obscure. It is more common in the young than the old, and in the male than the female sex, and at times appears to be dependent upon traumatism. Doubtless in some cases the hemorrhage is the result of necrosis or other pre-existing affections of the pancreas or of its blood-vessels. The changes are most marked in the head of the organ, although any part may be affected. There may be diffuse infiltration, or the hemorrhage occurs in isolated foci. Occasionally considerable collections of blood may be met with, and secondary reactive inflammation and necrosis are frequently observed. The peritoneum, the wall of the duodenum, and other surrounding tissues may be coincidently involved.

Sudden death may occur in this condition from shock or compression of the solar plexus, or the case may terminate in other pancreatic affections. Doubtless chronic indurative pancreatitis originates in this way in some cases. More commonly progressive necrosis and suppurative inflammation terminate the disease.

ATROPHY AND DEGENERATIONS.

Atrophy of the pancreas occurs in old age and as the result of marasmic conditions. The entire organ is involved in such cases. Localized atrophy may be associated with various degenerations or other diseases of the organ. Thus, in carcinoma or in cirrhosis pressure-atrophies are extremely frequent.

The association of atrophy of the pancreas with diabetes is a most important one, and it may be assumed that certain cases of diabetes are wholly dependent upon disease or atrophy of this

organ. Though atrophy is the most common pancreatic condition in diabetes, cirrhosis, carcinoma, and calculous obstruction of the ducts have been observed. It is believed by some that the pancreas elaborates sugar-destroying ferments whose presence in the blood is necessary to prevent hyperglycemia. In diseases of the pancreas this ferment is lacking and glycosuria results.

Parenchymatous degeneration may occur in consequence of acute infections, and resembles the cloudy swelling of the liver, kidneys, and heart occurring in the same diseases. The organ becomes somewhat enlarged; is softer than normal; and may at the same time be congested.

Microscopically the cells are found to have undergone granular degeneration.

Amyloid degeneration is a rare condition occurring in association with amyloid disease of other organs.

Pigmentation may be met with in the atrophic organ of old persons, or in consequence of hemorrhagic infiltration and subsequent disorganization of the extravasated blood. Of particular interest are the cases of *hematochromatosis* affecting the pancreas, together with the intestines, liver, and other abdominal organs in drunkards. The affected organs in this condition present more or less extensive hematogenous pigmentation.

Necrosis of small areas of the pancreas may occur in consequence of hemorrhage or of inflammatory conditions. Sometimes the entire organ is disorganized by a form of gangrenous necrosis, especially in case of pancreatitis resulting from perforation of a gastric ulcer or from extension of other severe inflammatory lesions.

Fat-necrosis is a form of degeneration or necrosis peculiar to the fatty tissue of the pancreas and of the omentum. Most frequently it is found in association with acute or chronic pancreatitis, with tumors of the pancreas, or obstruction of its duct; but it may occur independently, and it may appear in the fatty tissue of the omentum without involving the pancreas. Minute foci, having a gray or white, opaque appearance, or more rarely larger areas due to confluence of small foci of necrosis, are found in the adipose tissues. Hemorrhagic infiltration may be associated, and sometimes extensive hemorrhage may ensue. Inflammation of the pancreatic tissues around the foci of necrosis is common, and in some instances extensive disorganization (necrosis) of the pancreas occurs.

Microscopically the changes consist of, first, the formation of fat-crystals within the adipose cells, and subsequently the disorganization of these and the formation of calcium salts of the fat-acids, the microscopic appearance at this stage being that of indefinite granular or translucent masses. The nature of fat-necrosis has been previously discussed (see page 94).

INFLAMMATIONS.

Pancreatitis may be acute or chronic. The acute variety presents itself in different forms, the most frequent being the hemorrhagic and the suppurative or necrotic. Chronic pancreatitis is analogous to chronic hepatitis, and leads to similar induration or cirrhosis.

Acute hemorrhagic pancreatitis occurs most commonly in young persons, and is probably in most, if not all, cases dependent upon infection of the pancreas through its ducts. It is likely that some cases are not in reality inflammatory, but simply instances of degenerations of the pancreas, with hemorrhage and round-cell infiltration as consequences. The pancreas is swollen, especially at its head; the lobules are enlarged and the interlobular tissues compressed. Hemorrhagic infiltration is a constant condition, but variable in extent. Microscopically the cells of the pancreas are swollen, and usually present the appearances of parenchymatous degeneration. The interlobular tissues are infiltrated with round cells. Localized necrosis and fat-necrosis may be associated. Rapid death is the usual consequence, but it is probable that some of the cases terminate in chronic pancreatitis.

Acute suppurative or **necrotic pancreatitis** may result from direct extension of septic processes in the neighborhood, as in gastric or duodenal ulceration, purulent collections in the peritoneum, and the like. It may also occur as an independent affection, most frequently in consequence of infection from the intestinal tract through the ducts. Occasionally metastatic abscesses are observed in the pancreas. Hemorrhagic pancreatitis may be converted into the necrotic form in consequence of extensive extravasation of blood and secondary infection.

The organ presents a variable appearance, according to the cause and extent of the process. There is generally marked swelling with more or less softening, and not rarely necrotic foci. Complete gangrene or necrosis is an occasional termination. In other cases parts of the pancreas may slough, and may be discharged through the intestines or into the peritoneum, setting up fatal peritonitis.

Chronic indurative pancreatitis, or **cirrhosis** of the pancreas, may be hematogenous in origin, resulting from syphilis and alcoholism, or it may be caused by prolonged irritation exercised through the pancreatic ducts. In the latter case it may be secondary to duodenal catarrhs or obstructions of the pancreatic duct. In some cases it is doubtless the outcome of acute attacks.

The pancreas in the earlier stages is enlarged and hard. On section it may present a homogeneous structure and may be of cartilaginous consistence. Macroscopically the tissues between the acini are visibly infiltrated and hyperplastic, the amount

of connective tissue being greatly in excess of the normal. In the later stages the organ becomes contracted, and may be considerably reduced in size and of stony hardness.

Microscopically the parenchyma of the organ is found to be atrophied or degenerated in consequence of contraction of the hyperplastic fibrous tissue. Fat-necrosis and fatty degeneration of the pancreatic cells are frequently associated.

INFECTIOUS DISEASES.

Syphilis may occur in the pancreas in the form of indurative pancreatitis or of gummata. The former may occur in adults, but is more common in the new-born, in association with indurative changes in the liver, lungs, and other organs.

Tuberculosis of the pancreas, in the form of miliary tubercles, may occur in cases of generalized tuberculosis.

TUMORS.

Primary benign tumors have occasionally been met with, but are unimportant.

Carcinoma.—Primary cancer may affect the head or other parts of the pancreas, and is of the glandular (scirrhous), or, more rarely, of the cylindrical-celled, variety. Compression with secondary cystic distention of the pancreatic duct and obstruction of the common bile-duct or of the veins (portal, superior mesenteric, and splenic) behind the head of the organ may result. Metastasis to the neighboring lymphatic glands and to the liver is frequent. Secondary cancer may affect the pancreas by extension of cancer of the stomach or of the duodenum.

Pathologic Physiology.—Pancreatic carcinoma, and other chronic diseases of the pancreas, often occasion rapid emaciation, and sometimes fatty diarrhea, lipemia, and lipuria. Reference has already been made to the occurrence of diabetes (glycosuria) in pancreatic diseases. In a mechanical way cancer of the head of the pancreas may cause jaundice by obstruction of the bile-ducts; splenic enlargement, intestinal congestion, diarrhea, and ascites by obstruction of the adjacent veins; repeated vomiting and sometimes intestinal obstruction by compression of the duodenum.

Sarcoma is rarely primary. Secondary nodules are occasionally observed.

Cysts of the pancreas may be of several kinds. Dilatation of the pancreatic duct or its branches may occasion a single cyst or multiple cysts filled with serous or gelatinous liquid. Hemorrhagic cysts are sometimes the result of necrosis of portions of the organ, or a primary hemorrhage (hematoma) may be converted into a serous cyst. The latter is the mode of formation of some of the large cysts occurring, for the most part, near the tail of the pan-

creas. In other cases, it has been held, these cysts result from primary necrosis and subsequent digestion of the necrotic area by the pancreatic secretions. In rare instances cysts of the pancreas have a glandular structure somewhat resembling that of ovarian cystomata.

Cystic accumulations in the lesser omental cavity, resulting from localized peritonitis, may be difficult to distinguish from true pancreatic cysts, as some of the latter lie more outside than within the pancreas. In some instances such localized peritonitis seems to be the result of extension of pancreatic inflammations.

The fluid of pancreatic cysts often contains a proteolytic and an emulsifying ferment, but the contents of other abdominal cysts may have similar constituents.

The Pancreatic Duct.

Obstruction of the pancreatic duct may be due to tumors of the papilla in the duodenum or of the head of the pancreas, to calculi, to inflammatory thickening of the duct itself, or to the pressure of contracting fibrous tissue in chronic pancreatitis. Most commonly it leads to *dilatation of the duct*, this sometimes becoming so great as to occasion actual cystic formations (Fig. 263). The dilated ducts are filled with clear liquid, but some-

FIG. 263.—Dilatation of the pancreatic duct and atrophy of the pancreas, due to calculi (Orth).

times through bacterial infection this is rendered turbid, or is actually converted into pus. Occasionally small cysts, caused by distention of the finer divisions of the duct, are scattered through the organ (*pancreatic acne*). These are supposed to result from catarrhal processes in the ducts themselves. These small cysts are filled with clear or puriform liquid. Some cases so described are doubtless instances of fat-necrosis.

Pancreatic calculi are composed of carbonate or phosphate of lime, and usually have an irregular shape. They may occasion cystic distention of the ducts and abscess-formation.

THE PERITONEUM.

CONGENITAL ABNORMALITIES.

Absence of the peritoneum has been described; but more frequently minor defects, such as absence of the omentum or unnatural length of the omentum or mesentery, localized defects, fenestrations, and the like, have been observed. The peritoneal extension into the inguinal canal normally becomes occluded, but may remain patulous and may lead to congenital hernia.

CIRCULATORY DISTURBANCES.

Active hyperemia may occur in association with inflammation, or in the vicinity of lesions within the intestine which have not yet occasioned actual inflammation of the peritoneum itself. The affected part is bright red, the arterioles being distended and the endothelium somewhat swollen and elevated.

Passive hyperemia is more frequent. It may be part of a general venous congestion, or may result from obstruction of the portal vein by thrombosis, cirrhosis of the liver, and similar conditions. The venules may be widely dilated, the deeper layers of the peritoneum somewhat edematous, and the lining endothelium swollen and loosened. Intense passive congestion may lead to ascites or to hemorrhage.

Hemorrhage may occur in the form of punctate extravasations in various septic and hemorrhagic diseases, and in parts adjacent to intense inflammatory lesions, as in the peritoneum covering the bowel near anthrax-ulcerations. Hemorrhagic extravasations may likewise be due to intense passive congestion, as in death from suffocation or in obstructions of the portal circulation. Certain forms of intoxication, like phosphorus-poisoning, snake-venom, or the like, may occasion petechial ecchymosis or large suffusions; and occasionally hemorrhagic extravasations are due to embolic occlusion of the mesenteric arteries. Large hemorrhagic effusions may occur in the retroperitoneal tissues, especially at the root of the mesentery, between the folds of the omentum, or elsewhere into the subperitoneal cellular tissues. These, as well as hemorrhages into the peritoneal cavity itself, are frequently traumatic in origin. Rupture of the spleen, of the liver, of the uterus or Fallopian tubes, or of aneurysms or superficial blood-vessels may be the immediate source of large hemorrhages.

The extravasated blood within the cellular tissues undergoes gradual absorption, as elsewhere, and may leave pigmented areas and fibrous thickening. The blood within the cavity of the peritoneum may be directly absorbed, or may be gradually removed

after clotting by degenerative processes and absorption through the lymphatic channels. Inflammatory reaction is wanting unless the blood-mass is infected.

Dropsy of the peritoneum, or **ascites,** may occur as a part of a general anasarca in cardiac or renal disease, or may be due to obstruction of the portal circulation, notably by cirrhosis of the liver. In these cases ascites may be absent at first from the freedom of the collateral circulation established between the branches of the inferior and superior vena cava and the peripheral radicles of the portal circulation. Eventually, however, ascites ensues. In the earliest stages of certain cases of intense acute peritonitis and in chronic peritonitis, especially the tuberculous form, when the absorption of liquid from the peritoneum is disturbed by occlusion of the lymphatics, the liquid effusion may have a serous and not the ordinary inflammatory character. Chronic peritonitis plays a part in the etiology of many cases of ascites ordinarily regarded as the result of obstruction of the circulation alone, as in cases of cirrhosis of the liver. In such cases the venous stasis may occasion no dropsical exudation until a low-grade chronic peritonitis has developed, when the membrane becomes more permeable and effusion results.

An occasional cause of ascites is obstruction of the thoracic duct by new-growths of its walls, thrombosis within, or pressure from the outside. The ascitic liquid in such cases frequently has a chylous character.

The abdomen in ascites is filled with clear watery or yellowish liquid. Gelatinous masses often form in the dependent parts, as in the pelvis and iliac fossæ. Occasionally the liquid is quite hemorrhagic; in other cases it is milky from admixture of chyle or lymph (*chylous ascites*). The latter cases are dependent upon obstruction and rupture of the lymphatic channels. In other cases, especially in instances of endothelioma or carcinoma of the peritoneum, the liquid has a milky character from admixture of degenerated cells and fatty matter. The term *chyliform ascites* is sometimes applied to such cases. Microscopically the liquid of ordinary ascites shows red and white blood-corpuscles and occasionally a few endothelial cells. In the hemorrhagic cases the number of blood-corpuscles is notably increased, while in chylous ascites there are fat-droplets and granular cells.

Occasionally collections of dropsical liquid occur between the layers of the omentum (*hydrops omenti*).

Ascites causes more or less serious compression and displacement of the abdominal organs. The respirations may be greatly embarrassed by upward displacement of the diaphragm, and the circulation may be obstructed by the pressure of the liquid upon the veins. Secondary changes in the peritoneum are not unusual. Long-standing ascites nearly always gives rise to a certain amount

of chronic inflammation (fibrous thickening of the membrane), and termination in tuberculous peritonitis is not infrequent.

INFLAMMATIONS.

Inflammation of the peritoneum, or **peritonitis,** is the most important condition of this structure. Acute and chronic cases may be distinguished. The latter, in most instances, merely represent terminal conditions following acute forms of the disease. Exceptionally, peritonitis may be a chronic affection from the beginning.

Etiology.—Acute peritonitis is probably always caused by bacteria or bacterial products. It is possible to produce it in animals by injections of chemical poisons into the peritoneum, but it is doubtful if spontaneous peritonitis ever occurs, excepting as a result of infection.

The bacteria gain access to the peritoneum through the blood, by direct migration from the Fallopian tubes, by invasion through the walls of the abdominal viscera, or by perforation of the viscera or external abdominal walls. Hematogenic peritonitis is sometimes met with in cases of general septicemia and pyemia, as in osteomyelitis or malignant endocarditis, but such cases are rare. In these instances the bacteria may be discharged into the peritoneal cavity from the blood, and may thus occasion a direct or primary peritonitis; more frequently a localized lesion, such as a suppurating infarction, is first produced and the peritonitis results secondarily from this. Undoubtedly bacteria are often set free in the peritoneum in the course of infections, but this structure seems to have a high degree of resistance, and seems to be possessed of special means of defence. The experiments of Pfeiffer with regard to the mechanism of immunity (see page 198) may be cited in this connection. Idiopathic peritonitis was a term used by older authors to designate forms of seemingly causeless peritonitis, or such as follow exposure to cold and the like. At the present time we must regard these as exceptional instances of primary hematogenic peritonitis, or more commonly as cases of secondary peritonitis resulting from abdominal infections that have been overlooked.

Peritonitis resulting from direct extension of infective processes is very common. A certain amount of irritation of the serous coat (the peritoneum) of the abdominal organs occurs in most of the diseases of these organs, and in the case of certain infectious diseases this may attain considerable intensity. For example, in cases of ulcers of the intestines or strangulation of a coil of intestine with secondary necrosis, considerable peritonitis, local and eventually general, may occur without perforation of the gut. In such cases the bacteria penetrate the walls of the intes-

tines along the lymphatic channels, and thus reach the serous covering. Similar extensions are found in diseases of the tubes and ovaries, or of the uterus in puerperal sepsis.

Perforative peritonitis is the most important of the forms. It may result from perforation of gastric ulcers or cancer, from traumatic or ulcerative perforations of other parts of the intestinal tract, from perforation of the appendix in acute appendicitis, or from rupture of diseased Fallopian tubes; less commonly perforation of the other abdominal viscera, or rupture of infective foci, such as abscesses of the spleen, liver, pancreas, ovaries, or other structures, or penetration of the abdomen from without by stab-wounds or disease, may lead to peritoneal infection.

Among the micro-organisms that have been detected, the *Streptococcus pyogenes* is most important, and is the cause of the severest forms of peritonitis, such as those occurring in puerperal sepsis. Occasionally the disease is due to the *Staphylococcus pyogenes*, the *Bacillus coli communis*, the *Diplococcus pneumoniæ* the *bacillus of Friedländer*, the *gonococcus*, or other organisms. The Bacillus coli is mainly operative in peritonitis secondary to intestinal diseases, such as appendicitis. Very often, no doubt, peritonitis is the consequence of mixed infection.

Pathologic Anatomy.—Localized and general peritonitis may be distinguished.

Acute localized peritonitis is seen in cases in which bacteria escape gradually and in small numbers through the walls of the viscera, or in instances in which perforation takes place after the production of some exudate which serves the purpose of limiting the extension of the infection. Localized peritonitis is most frequent in the pelvis in association with diseases of the tubes or uterus, and in the region of the appendix. The peritoneum of the area of disease first becomes intensely injected (congested) and the normal luster disappears in consequence of the beginning exudation and disease of the lining endothelium. Subsequently the amount of exudate increases. It may, first, be of serous character, but usually is largely fibrinous, and the amount may be considerable. Thus the appendix is not rarely surrounded by masses of fibrinous exudate a centimeter or two in thickness. The exudate may remain fibrinous, but more frequently becomes fibrinopurulent in the later stages; and in cases of perforative peritonitis localized abscesses are commonly met with. In such cases, if the disease remains well encapsulated, and the patient survives, the exudate may be removed in several ways. Very rarely the pus burrows toward the exterior and discharges; more frequently it empties into the intestine or some other hollow viscus. It may decrease by gradual inspissation, leaving a dry, cheesy mass, which in rare instances finally becomes calcareous. Fibrinous exudates in localized peritonitis

are frequently absorbed, and give place to fibrous-tissue adhesions.

Acute general peritonitis may be the immediate result of the discharge of large quantities of infective matter from a perforated bowel or other organ; or it may occur secondarily to a localized peritonitis when the limiting-wall of exudation is broken down. In these cases the peritoneal covering of the intestines, and to a less extent the parietal peritoneum, become congested and lusterless, as in the localized form. Serous exudation takes place, and may be considerable in amount in some of the most violent forms of the disease. Acute inflammatory ascites is thus produced. Usually, however, the serous exudation is scanty, and very soon the intestines are covered with flakes or thin coatings of fibrinous exudate and are matted together. Subsequently the exudate grows more yellowish from the emigration of leukocytes or pus-cells. When adjacent coils of intestine are agglutinated by the exudate pockets containing serous or seropurulent liquid may be formed between them.

In the most violent forms of peritonitis, local or general, such as those due to strangulation and gangrene of a part of the bowel, or to puerperal sepsis, the exudates may rapidly assume a putrid character, and the deposit upon the serous surface, as well as the serosa itself, may undergo necrotic change. In these cases the cavity of the peritoneum contains more or less ill-smelling brownish, grayish, or blood-tinged liquid exudate, and the affected areas of the peritoneum are covered with greenish or brownish deposits.

Hemorrhagic peritonitis is sometimes observed. It represents no special form, but merely indicates systemic or local conditions, as a result of which hemorrhagic extravasation has taken place into the exudate. This is found in the peritonitis of scorbutic individuals or of persons reduced in vitality by other diseases. It also occurs when passive congestion is associated with peritonitis, as in cases of cirrhosis of the liver. The peritonitis accompanying tuberculosis, and especially carcinoma of the peritoneum, may present hemorrhagic exudate.

Effects of Acute Peritonitis.—The disease of the peritoneum has an immediate and profound effect upon the intestines, and reflexly or in other ways upon the general system. The peristalsis of the bowel in the earlier stages is arrested by spasmodic contraction. Very soon the musculature is paralyzed and more obstinate constipation results. The systemic effects are most strikingly evidenced by the intense shock of the early stages. General septicemia may be the consequence of the infective conditions of the peritoneum.

Chronic peritonitis may be the termination of an acute peritonitis, especially the localized form. In other cases chronic inflammatory thickening occurs in the peritoneum adjacent to or

covering organs the seat of various diseases. Thus in cirrhosis of the liver the peritoneal covering and the reflexions forming the ligaments may be greatly thickened, and similarly the peritoneum covering the spleen may be involved in consequence of chronic congestion or inflammation of this organ.

Chronic peritonitis following local acute peritonitis usually presents itself in the form of fibrous thickenings or adhesions, such as are so often encountered in the pelvis after uterine, tubal, or ovarian disease complicated by peritonitis, and about the appendix after inflammations of this structure. Less commonly chronic peritonitis is met with in the form of sacculated effusions. In such instances the effusion formed during the acute stage is only partially absorbed, and remains as an inspissated liquid.

In other cases dense adhesions are formed, and occasionally calcareous plates are found in the thickened peritoneal covering of the bowels or other parts.

Chronic diffuse peritonitis may result from diffuse acute peritonitis. In such cases there are widespread adhesions, and the peritoneum is more or less diffusely thickened. More or less liquid effusion may be present. In other instances diffuse peritonitis arises in an insidious manner as a chronic process from the beginning. Some of these cases are entirely obscure in etiology; in a few it has seemed probable that syphilis was an etiologic factor. The peritoneum is often uniformly thickened, but in some cases presents small nodular lesions, suggesting miliary tubercles. In several instances these nodules, together with the abundant serous effusion occasionally met with, have led to the diagnosis of tuberculous peritonitis. Microscopic examination of the nodules, however, shows a fibrous structure, and neither giant-cells nor tubercle-bacilli. Tuberculous and malignant peritonitis will be considered below.

Hyperplastic Perihepatitis.—A few cases have been observed of a remarkable disease in which the upper part of the parietal peritoneum and the reflexions covering the liver and spleen are greatly thickened and of dense sclerotic character. The peritoneum is sometimes several millimeters in thickness, gray or white, and suggests the appearance of the "icing" of confectioners. This has led to the term proposed by Curschmann—*Zuckergussleber*. The liver and spleen undergo more or less pressure-atrophy, and ascites is a frequent symptom. The etiology is obscure.

INFECTIOUS DISEASES.

Tuberculosis may in rare instances affect the peritoneum primarily, as in cases in which tubercle-bacilli penetrate the mucosa of the intestines and enter the lymphatics without causing an intestinal lesion; or in cases of infection through the Fallopian tubes. Usually tuberculosis of the peritoneum is secondary to tuberculosis of some abdominal viscus or of more distant organs. Thus among the more frequent causes are tuberculosis of the mes-

enteric or retroperitoneal glands and tuberculous disease of the tubes and ovaries in women. Intestinal tuberculosis rarely leads to more than localized lesions of the serous coat opposite the ulcerations of the mucosa. Pulmonary tuberculosis may occasion hematogenic infection of the peritoneum. Simultaneous tuberculosis of various serous membranes, especially the pleura and peritoneum, is occasionally observed. The source of infection is often hidden; sometimes the pleura is first involved and the peritoneum becomes affected by extension; less commonly the reverse occurs.

Pathologic Anatomy.—Miliary tuberculosis without marked inflammatory changes may occur as a generalized peritoneal affection in acute or subacute general miliary tuberculosis. Local eruptions of similar character are seen in the pelvic peritoneum in cases of tubal or ovarian tuberculosis and upon the serosa of the intestines adjacent to tuberculous ulcers of the bowel.

More important, from a clinical point of view, are the cases in which inflammatory changes are associated with the specific tubercle. In some instances extensive adhesions by fibrinous or fibrous productions are met with, while the tubercles tend to agglutinate, forming masses of considerable size and of cheesy character. The mesenteric lymph-glands may be coincidently involved, being enlarged and caseous. Sacculated collections of serous or seropurulent liquid are sometimes observed. In another variety there is abundant serous exudation. Occasionally the exudate is hemorrhagic.

Tuberculosis of the peritoneum sometimes terminates in complete resolution, the peritoneum being left somewhat thickened, but showing no other evidences of the previous disease.

TUMORS.

Fibromata and **lipomata** are sometimes met with as small nodular or pedunculated outgrowths from the subperitoneal tissues.

Sarcoma may occur in the form of diffuse gelatinous tumors of angiosarcomatous structure, or in the form of *endotheliomata*. The latter variety occasions diffuse thickening, sometimes of considerable areas, of the peritoneum. *Secondary sarcoma* is sometimes observed as nodules of considerable size or as numerous miliary nodules.

Carcinoma of the peritoneum is usually secondary. *Gelatinous* or *colloid cancers* of the stomach and bowel (rectum) frequently extend widely through the peritoneum, causing great thickening and a remarkably gelatinous growth. Not rarely rounded masses of pearly appearance are observed (Fig. 74). In rare instances tumors of the peritoneum of the same general character seem to be primary, and the reasonable explanation has been suggested that parts of intestinal tissue, pinched off in fetal de-

velopment, are the starting-points of the growths. *Secondary cancer* frequently appears in the form of nodular tumors in association with ovarian cystomata that have become carcinomatous, or with primary cancers of the ovaries and other pelvic organs. Occasionally widespread eruption of miliary nodules is met with as a part of *acute carcinomatosis.*

In all forms of carcinoma of the peritoneum inflammatory changes with intestinal agglutination and adhesion are frequent. Hemorrhagic exudation is not unusual. In rare cases the bowels are so firmly fused by the spreading tumor and the inflammatory exudates that they form a solid mass, which on section shows the cavities of adjacent coils of intestines separated by more or less uniform tumor-tissue.

PARASITES.

Echinococcus-cysts occasionally occupy the peritoneal cavity, and may fill it almost completely. *Filariæ* have been found in a few instances; and the *Pentastomum denticulatum* and *Cysticercus cellulosæ* have been reported. Recently an ameboid organism (*Leydenia gemmipara*) has been discovered in the liquid exudate of cases of ascites.

CHAPTER V.

DISEASES OF THE DUCTLESS GLANDS.

THE THYROID GLAND.

Anatomic Considerations.—The thyroid gland is a compound tubular gland, which in fetal life communicates with the pharynx at the base of the tongue by a duct. Later the duct is obliterated, and the gland becomes ductless. Microscopically there are found acini lined with polyhedral or cylindrical epithelium, usually in a single layer. The lumen of the acinus contains more or less gelatinous, or, as it is usually called, colloid material, which seems to be a secretion of the epithelium. It is an albuminate rich in sodium chlorid. The vascular supply of the gland is very abundant, the blood-vessels being numerous and the anastomoses very free. The lymphatic network is equally abundant, and mainly situated in the stroma of the gland around the acini. The larger lymphatics are supplied with valves like those of the veins. Occasionally colloid material has been found in the stroma and in the lymphatics. The capsule of the gland is a fibrous covering from which trabeculæ extend into the substance of the organ.

CONGENITAL DEFECTS.

Occasionally one or another part of the gland is wanting, or in rare instances the entire organ.

Accessory thyroid glands have been found in various situations. Sometimes small masses of thyroid tissue occur alongside of a normal gland, either above it, in the neck; or below it, behind the sternum and in the anterior mediastinum. In other cases the normal thyroid is absent, but is represented by small masses in the situations named, or in other parts. In a few instances tumors at the base of the tongue and within the larynx and trachea have been found to be composed of thyroid tissue.

DISTURBANCES OF CIRCULATION.

Hyperemia of the thyroid gland is met with very frequently. It occurs in cases of cardiac failure, and in consequence of obstruction of the large veins by mediastinal tumors, and the like. In these instances the thyroid may be considerably enlarged, and has a soft, doughy feel. Slight enlargement of the thyroid of congestive character is found in perhaps a majority of the cases of chlorosis, and may be present in any form of anemia. In Graves' disease the thyroid is usually very vascular, and the enlargement of the gland is in large part due to dilatation of the blood-vessels (see page 561).

INFLAMMATIONS.

Acute inflammation, or **acute strumitis,** may occur in the course of various infectious diseases, notably typhoid fever. Occasionally it arises without definite preceding disease. The gland enlarges and becomes rather tense. The termination is usually in resolution, and this may occur very rapidly, suggesting that the enlargement of the gland is due largely to congestion and liquid exudation, rather than to cellular (inflammatory) infiltration.

Acute suppurative strumitis, or **abscess,** occurs in consequence of embolism, in cases of infected wounds, endocarditis, or general pyemia. Sometimes the inflammation extends directly from local diseases, such as diphtheria. The abscess may rupture, or may undergo secondary changes—inspissation, calcification.

STRUMA OR GOITER.

Definition.—Goiter is the name applied to various enlargements of the thyroid gland. It is a clinical rather than a pathologic term. Sometimes a distinction is made between benign and malignant struma, the latter term including definite tumors of the thyroid gland. At the present time the term goiter is restricted to enlargements of a hyperplastic character, which, though often

resembling tumors, cannot be definitely classified among the tumors of the gland.

Etiology.—Goiter occurs endemically in certain situations, as in Switzerland and other parts of Europe, and in parts of Michigan in this country. Sporadically it is met with in all parts of the world. Local conditions of some kind are doubtless among the fundamental causes, but the nature of these conditions is but little known. The drinking-water has always been suspected, and it seems likely that it has some influence, though it is certain that the magnesium and calcium salts have not the importance formerly ascribed to them. Infectious causes have been suspected and micro-organisms have actually been described, but no satisfactory demonstrations have been made.

Pathologic Anatomy.—Two principal varieties may be distinguished: the parenchymatous and the vascular.

Parenchymatous Goiter.—Parenchymatous goiter is a variety in which the glandular tissues or acini undergo more or less active hyperplasia. The gland is generally uniformly enlarged, but sometimes presents lobular or nodular elevations. The tissue is ordinarily somewhat elastic, like that of the normal thyroid, but may in other instances be very firm. Occasionally cystic forms occur, and a subvariety is sometimes distinguished by the term *cystic goiter*.

Microscopically there may be found merely a uniform hyper-

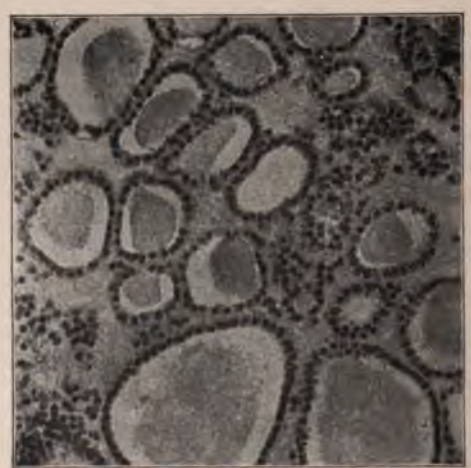

FIG. 264.—Colloid goiter, showing colloid material in the dilated acini (Karg and Schmorl)

plasia of the glandular acini, without any notable change in the structure of the tissue. In other cases the acini are larger and more irregular than in the normal thyroid, suggesting the struct-

ure of an adenoma, and the term *struma adenomatosa* is applied. In most instances the acini contain but small quantities of colloid material, as is the case in the normal gland. Sometimes, however, there is abundant production of colloid, and the acini are greatly distended; the term *colloid goiter* may be applied in such instances (Fig. 264). In certain cases the walls of the acini are destroyed and the colloid of adjacent acini runs together, forming considerable cysts. In these instances the thyroid consists of numerous cystic excavations. Changes in the interstitial connective tissue of the gland may be comparatively slight, but may in other cases become conspicuous. The capsule of the gland may be thickened, and the stroma may predominate over the glandular elements. The term *fibrous goiter* has been suggested for such cases.

Vascular Goiter.—This term is applied to enlargements of the thyroid gland characterized by marked dilatation of blood-vessels within the gland. The glandular tissues themselves may play no part in the process, or they may present changes similar to those described under parenchymatous goiter. The gland undergoes considerable and sometimes enormous enlargement, and may pulsate actively. This form of goiter is met with as the important pathologic condition of Graves's disease (see page 564).

Secondary Changes.—The thyroid frequently suffers secondary changes in goiter. The hyperplasia of connective tissue between the acini has been referred to. Sometimes this becomes so considerable that the term fibrous goiter is warranted. Cystic formations have also been mentioned, the cysts referred to resulting from the confluence of the dilated acini. The contents in such cases consist of colloid material or of more or less serous or hemorrhagic liquid. Occasionally cysts result from hemorrhage in degenerated parts of the gland, with subsequent absorption of the blood, and exudation of serous liquid. The contents in such cases may be purely serous or may consist of brownish grumous matter containing abundant cholesterin. Very rarely secondary proliferative changes occur in the walls of the cyst, causing papillomatous projections. Calcification is a very common terminal change in degenerated goiters. It may occur in isolated areas, or may cause a uniform hardening of the gland. Actual ossification has been observed.

Mechanical Effects of Goiter.—The enlarged gland presses upon the adjacent structures more or less seriously. The trachea is most frequently compressed or dislocated from its median position. Pressure upon the large veins may occasion passive congestions and edema; and less commonly pressure on the carotid artery may interfere with the circulation of blood in the brain. The nerves in the vicinity (vagus, recurrent laryngeal, and sympathetic) are likewise exposed to compression.

INFECTIOUS DISEASES.

Tuberculosis may occur in the form of miliary tubercles or as small caseous nodules.

Syphilis is met with in the form of gummata.

Actinomycosis is a very rare disease of the thyroid gland.

TUMORS AND PARASITES.

Tumors.—The term malignant struma is sometimes applied to tumors, and it is difficult in certain cases to draw a sharp line between certain goiters and distinct new-growths (adenomata).

The term *adenoma*, however, should be restricted to cases in which the proliferation of acini is more or less atypical, and in which the tumor is circumscribed, nodular, or otherwise distinguishable from the pre-existing gland-tissue. Sometimes tumors of the thyroid having typically adenomatous characters give metastasis.

Carcinoma may occur in the form of a nodular, or more diffuse tumor. Metastasis is frequent in cases of carcinoma, but also occurs in cases that present the appearances of an ordinary adenoma. The bones are frequently involved by metastatic deposits. Extension from the thyroid to the adjacent organs is not infrequent.

Sarcoma occurs in several varieties. Round-celled sarcoma and angiosarcoma are particularly malignant.

Secondary tumors in the thyroid are rare.

Parasites.—Echinococcus-cysts have been met with, but are very rare.

GENERAL RESULTS OF THYROID DISEASE.

The physiology of the gland has not as yet been fully determined, though certain facts have become established. The old authors believed the gland to be active as a blood-making organ, and this is still maintained by some. It is, however, unlikely that this function is an important one. The frequent association of thyroid disease with certain general conditions (cretinism and myxedema) has led to experiments upon animals that have established certain important facts.

The immediate removal, by operation, of the entire thyroid gland causes severe nervous manifestations resembling those of tetany followed by rapid death. Partial removal of the gland causes comparatively trivial consequences, but in cases in which total ablation has been practised, and in which a certain amount of thyroid influence has been kept up by injections of thyroid extract or the feeding of thyroid gland, marked symptoms have been found to develop after a period of some months. Among these

symptoms are pallor, edema of the skin, general weakness, disturbances of growth, and alteration of the cerebral functions (intellection, sensation, and motor power). This condition has been termed *cachexia strumipriva*, and its resemblance to cretinism and myxedema will be apparent from a reference to the symptoms of those diseases.

Cretinism.—Cretinism is a peculiar disease, occurring with great frequency in certain parts of central Europe, especially in Switzerland, and not infrequently in other parts of the world. The thyroid gland is sometimes atrophic, and sometimes goiterous, but in all cases diseased. The disease is not, as a rule, present at birth, but usually develops soon after birth; and the parents may be cretinoid or goiterous. Sometimes healthy parents have cretin children. The cretin remains physically and mentally undeveloped; the subcutaneous tissue is flabby, abundant, and sometimes distinctly myxedematous (Fig. 265); the head is large; the lips and tongue enormously thickened, and the latter usually protrudes from the mouth; the hairs of the body are little developed.

FIG. 265.—Cretin, aged seven months; showing facial features and myxedematous condition of hands and feet (author's case at the Children's Hospital).

Myxedema.—Myxedema is a disease that develops in later life; sometimes after distinct diseases of the thyroid (goiter, gumma, tumors, etc.), but often without any manifest disease of thyroid, though atrophy and degenerations (calcification) may be disclosed by the post-mortem examination. There is a peculiar swelling of the eyelids and of the subcutaneous tissue of the face and neck, and subsequently the same change occurs elsewhere, involving the limbs and the entire body. The appearances at first suggest edema, but there is not the usual pitting on pressure, and the feeling conveyed to the hand is that of an infiltration with some form of gelatinous tissue. This has been found to consist of a mucin-like substance, often associated with increase of the adipose tissue itself. The skin of the patient is pallid and exceedingly dry; the hair falls out, and nervous symptoms are developed. Eventually intellection may be almost destroyed.

The resemblance of these diseases to the symptoms produced

by operative removal of the thyroid gland makes it certain that disease of the thyroid is the fundamental condition in cretinism and myxedema. This fact is still more clearly demonstrated by the numerous cures of these diseases following implantation of sheeps' thyroids in the peritoneal cavity, and especially the feeding of thyroid-gland tissue or extracts.

Graves' disease has been referred to in connection with vascular goiters. The cardinal symptoms of this disease are enlargement of the gland, palpitation of the heart, exophthalmos, and muscular tremor. The pathology of the disease has not as yet been fully determined. It seems likely, however, from recent investigations that the thyroid disease, from whatever cause it may result, is the primary disorder. Removal of large parts of the gland has been found to control the symptoms of Graves' disease in a large number of cases, and the feeding of thyroid extract for a long period of time produces symptoms like those of Graves' disease: rapid action and palpitation of the heart, exophthalmos, and tremor. According to the view here expressed, the symptoms which together constitute Graves' disease are probably due to overproduction of thyroid secretion; they are, in fact, the result of *hyperthyroidism*. The opinion, however, is held by others that Graves' disease is primarily an affection of the nervous system.

THE SUPRARENAL BODIES.

Anatomic Considerations.—The suprarenal bodies are composed of a cortical and a medullary portion, and are enclosed in a fibrous capsule from which septa extend into the substance. The cortical portion is composed of aggregations of polygonal cells which frequently contain fat-droplets. Three layers are distinguishable in the cortex: an outer zone, in which the cells are arranged in oval masses; a middle zone, in which they form cylindrical columns extending toward the medullary; and an inner zone, composed of irregularly anastomosing columns of cells. The cells of the middle zone are deeply pigmented and contain abundant granular and globular fat. The medulla of the gland consists of similar polygonal cells arranged in cords or irregularly anastomosing columns. Between these are found large venous channels and numerous non-medullated nerve-fibers, together with ganglion-cells. The fibrous septa of the gland contain blood-vessels and lymphatics.

CONGENITAL ANOMALIES.

Accessory suprarenal bodies may be found in the vicinity of the main body. Of peculiar interest are the portions of suprarenal tissue found in the capsule or cortex of the kidney. These "rests" may subsequently proliferate and form tumors of the kidney (see Tumors of the Kidney).

Occasionally the suprarenal bodies are found in unusual situations.

DEGENERATIONS.

Fatty degeneration is normal in adults. It affects the cortex, giving this layer a yellowish color. The substance of the cortex may separate through the middle zone, forming a cavity suggesting a cyst. This is probably in part a post-mortem production.

Pigmentation is observed in the cells of the medullary portion in persons of advanced age.

Amyloid degeneration occurs in connection with amyloid disease of other organs. The suprarenal body becomes hard and of a grayish, translucent appearance. The degeneration affects the walls of the blood-vessels, from which it extends to the connective tissue. The glandular portions suffer pressure-atrophy. The cortex is more frequently involved than the medulla.

INFECTIOUS DISEASES.

Tuberculosis of the suprarenal body is the most important of its diseases. *Miliary tubercles* may be met with in cases of general tuberculosis, but a *fibrocaseous form* of the disease is more frequent and of much greater significance. The gland is enlarged, sometimes reaching the size of an egg; it is hard and usually rather nodular, or irregular in outline. The capsule is thickened, and the substance of the gland is composed of dry, yellowish cheesy matter, or of a puriform material (Fig. 266). In the later stages the caseous or puriform matter may be absorbed, and fibrous-tissue growth may convert the entire body into a shrivelled, hard mass of connective tissue. Sometimes one gland alone is involved; more frequently the disease occurs bilaterally. Tuberculosis of this form may be primary, but usually is secondary to tuberculosis of the lungs, intestines, or other organs. The general effects of this disease will be discussed below (see Addison's Disease).

FIG. 266.—Caseous tuberculosis of the suprarenal body (Kast and Rumpel).

Syphilis occurs in the form of gummata. Uniform fatty degeneration of the suprarenal body has been met with in congenital syphilis.

CIRCULATORY DISTURBANCES.

Hemorrhage is comparatively rare. It may occur in association with hemorrhagic diseases, or severe anemias, especially leukemia. Sometimes it is caused by traumatism, or by obstruction of the venous circulation. The hemorrhage may be inconsiderable, or may be quite large. In the latter instances secondary rupture of the hematoma may cause death by intraperitoneal hemorrhage, or a hemorrhagic cyst may result.

INFLAMMATION.

Inflammation of the suprarenal body is very rare. A simple and a hemorrhagic form have, however, been described. Abscess may occur in consequence of pyemia, or as a secondary condition following other forms of suprarenal disease.

TUMORS.

Sarcoma is the most frequent form of tumor. Melanotic, as well as unpigmented, varieties are met with. The tumor may reach considerable size, and may destroy the gland completely.

Adenoma and **carcinoma** may arise from the cells of the acini. Histologically these tumors resemble the normal gland in their structure, and the term adenoma is perhaps more suitable than carcinoma. The tumor occurs as a nodular, irregular growth, often of a yellowish or brownish color; it most frequently arises from the cortical portion of the gland.

Gliomata of the suprarenal bodies have been described, but it is doubtful whether these tumors are true gliomata. **Neuroma** is a rare form of suprarenal disease.

Secondary sarcoma and **carcinoma** are not infrequent.

Tumors of the cortex of the kidney, having the structure of suprarenal tissue, are described under Tumors of the Kidneys.

GENERAL EFFECTS OF SUPRARENAL DISEASES.

The physiology of the suprarenal body is still obscure. It is quite generally believed, however, that this gland holds some relation to pigment-formation, as well as to the circulation, either through the action of substances elaborated within the gland or through the nervous system. The last is suggested by the abundance of nervous tissue in the gland.

Addison's disease, in which fibrocaseous tuberculosis of the suprarenal bodies is commonly present, is an affection characterized by brownish pigmentation of the skin of exposed parts of the body (face, neck, and hands), and of the skin in the flexures of the joints, or in other parts subjected to pressure. The pigmenta-

tion usually occurs in a mottled form at first, but soon becomes uniform. Brownish or purplish spots upon the mucous membranes (mouth) are not unusual. Besides pigmentation the characteristic symptoms are great weakness, disturbances of the stomach (vomiting), and cardiovascular asthenia.

Though fibrocaseous tuberculosis of the suprarenal gland is discovered in many cases, Addison's disease may occur in association with other affections of the suprarenal, such as tumors; and it may be absent despite the existence of tuberculosis or of other diseases of both of the glands. The absence of Addison's disease in the latter cases has been explained by some writers by the assumption that the suprarenal disease had not existed long enough for the development of the symptoms of Addison's disease. Occasionally alterations in the sympathetic nervous system (semilunar ganglia and solar plexus) have been discovered when the suprarenal glands were apparently normal. No explanation of such cases can be made. It must be accepted at the present time that the suprarenal bodies are in some way concerned in the etiology of the disease. The disease of the gland need not, however, be of any special sort.

CHAPTER VII.

DISEASES OF THE URINARY ORGANS.

THE KIDNEYS.

CONGENITAL ANOMALIES.

ABSENCE of one of the kidneys is frequently observed. Occasionally one kidney, instead of being completely absent, is atrophic or hypoplastic. The opposite kidney may undergo compensatory hypertrophy. Both kidneys may be wanting in certain monstrosities.

Congenital lobulation is quite common, and is usually bilateral. The kidney is divided into separate lobes by furrows of variable depth. Occasionally there is almost complete separation into numerous lobules.

A few instances have been observed in which there was a third kidney, and usually in these cases two of the kidneys lying to one side of the spinal column were agglutinated.

Fusion of the two kidneys may occur, and there may result a single large organ, with a double pelvis and ureter lying to one or the other side, or a *horseshoe-kidney* may be formed. In the latter

the two organs, which are generally displaced far downward, are united at their lower ends by a commissure passing across the spine just above the lumbosacral junction. The commissure may consist of normal kidney-tissue, or may be fibrous; more commonly the former.

Congenital cysts and other congenital diseases will be referred to below.

CHANGES OF POSITION.

Congenital Malposition.—Not rarely one of the kidneys is displaced downward. It may even occupy the pelvis. In other cases it is displaced laterally or forward, and may be found immediately beneath the anterior abdominal walls.

Acquired malpositions may result from pressure upon the organ, or from elongation of the peritoneal reflections covering the kidney and absorption of the perirenal fat. The right kidney is more frequently displaced than the left, and the condition is especially common in women. Repeated pregnancies, the effects of tight lacing, and diseases or displacement of the liver are prominent causes. Movability or displacement of the kidney may be but a part of a general visceral descent (*enteroptosis*).

Several grades of movability or displacement may be distinguished. In the first, the perirenal fat is wanting, and the kidney is more movable beneath its peritoneal covering than is normal. This occurs in a large proportion of women, and usually affects the right kidney. In more advanced grades the peritoneal reflection covering the kidney is elongated and considerable movability of the organ within the abdomen results. The kidney may be moved from side to side, downward as far as the pelvis in some cases, or upward to the normal position or under the ribs. In a third group of cases the kidney, lying within an elongated peritoneal pouch, is retained in an abnormal position by adhesions.

Results.—Twisting of the pedicle may lead to serious circulatory disturbances, and twisting of the ureter to retention of urine, sometimes causing hydronephrosis. Pressure of the displaced right kidney upon the duodenum may lead to dilatation of the stomach.

CIRCULATORY DISTURBANCES.

Anemia of the kidney may occur as a part of general anemia. The kidney is light in color and rather hard in the earlier stages; but if the anemia persists degenerative softening and enlargement may ensue.

Complete arrest of the blood-supply, produced experimentally, leads to rapid necrosis of the kidney, the organ becoming ashen-

gray in color and of a homogeneous structure, so that the separate parts (cortex, medulla, pyramids) are indistinguishable. Near the cortex, where some circulation is maintained by the capsular vessels, fatty degeneration is observed. Somewhat similar changes are met with in circumscribed areas in diseases in which the circulation in branches of the renal artery is obstructed (see Embolism).

Active hyperemia of the kidney is generally a part of acute inflammation. It may result from irritant chemical poisons or from the toxic action of infectious poisons. The kidney is enlarged, dark red in color, and on section the cortical substance is found to be swollen and marked by dark-red points—the Malpighian bodies. Sometimes punctate or linear hemorrhages may be observed. The urine is somewhat albuminous, and hyaline casts occur. It is difficult to draw a sharp line between this condition and acute nephritis.

Passive hyperemia occurs in cardiac and pulmonary diseases which impede the circulation, or as a consequence of thrombosis of the inferior vena cava or renal veins, or of other local causes obstructing the circulation in the renal veins. The kidney is enlarged and on section the cortex is found to be swollen, the substance of the kidney dark red in color, particularly in the pyramids in the vicinity of the large veins. The Malpighian bodies may be distinctly enlarged and dark red.

Long-standing passive congestion leads to reactive hyperplasia of the interstitial connective tissue of the organ, and thus to a form of *secondary interstitial nephritis.* In these cases the kidney becomes contracted, the surface somewhat irregular, and the capsule ofttimes adherent. The organ may be intensely hard and pigmented, and the term *cyanotic induration* is appropriate.

The urine in passive hyperemia is, as a rule, deficient in quantity, and contains variable quantities of albumin and hyaline or granular tube-casts.

Hemorrhage.—*Punctate hemorrhages* may occur in cases of intense active or passive hyperemia, the extravasation of blood occurring in the interstitial tissues, in the uriniferous tubules, or within the capsule of Bowman. Similar hemorrhages may be observed in acute or chronic nephritis. In these cases the extravasation of blood may occur by diapedesis or by actual rupture of the capillaries. Small hemorrhages may occur in the perirenal tissues in certain of the hemorrhagic diseases. *Large hemorrhages* occur within the kidney-substance only in cases of traumatism.

Edema of the kidney results from obstruction of its venous circulation. The kidney becomes enlarged and soft, and the spaces between the convoluted tubules (the primary lymphatic spaces) are distinctly enlarged. There is associated congestion in these cases. Simple edema of the kidney may result from obstruction of the urinary outflow.

Thrombosis of the renal veins or their branches is rare. It causes intense hyperemia, hemorrhages, and edema, and later necrosis and degenerations.

Embolism is very common in the branches of the renal arteries, especially in cases of disease of the aortic valves or atheroma of the aorta, with fibrinous deposits upon the atheromatous areas. The blood-vessels of the kidney correspond closely to the conception of terminal arteries, and infarction is therefore the usual result. In most cases the infarcts are light-colored areas having a wedge-shape, the base of the wedge being directed toward the capsule of the organ. A zone of reactive hyperemia or hemorrhage usually separates the infarct from the surrounding structures (Fig. 267). Less frequently the infarcts are purely hemorrhagic, the entire area being dark red in color. Minute emboli may lead merely to punctate hemorrhages within the kidney, or to ecchymotic extravasations on the surface.

FIG. 267.—Anemic infarcts of the kidney surrounded by a zone of hemorrhagic infiltration (Kaufmann).

The white or anemic infarcts undergo gradual necrosis and absorption, with cicatrization or encapsulation, the contents in the latter case remaining as a dry detritus. The hemorrhagic infarcts more commonly soften, and finally terminate in cicatrization or in the formation of small cysts. In cases of infective embolism the anemic or hemorrhagic infarct may rapidly break down and form a metastatic abscess.

INFLAMMATIONS.

Inflammation of the kidneys may affect the substance (*nephritis*), the mucous membrane of the pelvis (*pyelitis*), or the capsule and peripheral portions (*perinephritis*).

NEPHRITIS.

Nephritis is the term given to a number of forms of degeneration and inflammation of the substance of the kidney. The term Bright's disease is a clinical rather than pathologic one, being applied to various kinds of kidney-disease attended with albumin-

uria and dropsy. As a rule, however, the names Bright's disease and nephritis are used synonymously.

Nephritis may be acute or chronic; and parenchymatous, diffuse, or interstitial. The term *parenchymatous* is applied to cases in which degenerative changes in the epithelium of the tubules or glomeruli are the most conspicuous feature; the term *diffuse* is applied when exudative or proliferative changes affecting the connective tissues between the tubules and around the glomeruli and blood-vessels are associated in more or less equal proportions with the parenchymatous changes; and the term *interstitial nephritis* is used in cases in which exudative and especially proliferative changes are alone conspicuous.

Etiology.—Nephritis is due in the majority of cases to irritants which reach the kidney through the circulation. Intense acute nephritis may result from various poisons, particularly such as attack the parenchyma of organs, and are, therefore, known as parenchyma-poisons. Among these arsenic, mercury, phosphorus, cantharides, and turpentine are conspicuous. A second group of cases, and perhaps the largest of all, owe their origin to infections of various kinds. Nephritis is a common complication or sequel of scarlet fever, cholera, septicemia, diphtheria, and many other infectious diseases. In these cases the micro-organisms themselves may reach the kidney through the circulation, as in typhoid fever, anthrax, or pneumonia, or the renal irritation may be caused by the toxins, as in cholera and diphtheria. Sometimes infectious nephritis is cryptogenetic, the portal of entrance of the micro-organisms being entirely obscure. In such cases streptococci, particularly, are operative. Certain chronic infections lead to nephritis by the action of the toxins or by slow nutritive disturbances. Such is the case in syphilis, tuberculosis, and malaria. Autointoxication occasions certain cases, as in the nephritis of gout and lithemia.

In a small proportion of the cases nephritis results from irritants reaching the kidney through other channels than the circulation, as in pyelonephritis, a condition consequent upon inflammatory processes ascending from the bladder and ureters, or as in nephritis secondary to extrarenal disease (psoas abscess).

Low-grade renal inflammation may result from chronic congestion of the kidneys in consequence of cardiac and pulmonary disease. In certain cases also it is likely that arterial disease affecting the renal arteries in common with other arteries of the body may initiate renal changes eventuating in a chronic interstitial form of nephritis.

Pathologic Anatomy.—In considering the morbid anatomy the terms parenchymatous and interstitial are preserved, with the understanding that they are not strictly applicable to any given case. Pure parenchymatous inflammation does not exist, nor does

interstitial nephritis occur without any parenchymatous change. Diffuse nephritis is considered under the heading parenchymatous nephritis.

Acute Parenchymatous Nephritis; Acute Bright's Disease.

This results most frequently from infectious fevers and from toxic agents. It is more common in young persons than in the old.

Acute Degenerative Nephritis.—The process in this condition may be almost purely parenchymatous in nature, and more nearly allied to pure degeneration than to inflammation. The epithelium of the tubules, especially in the convoluted portions, and to a certain extent also that covering the glomeruli, is swollen, cloudy, and considerably desquamated. Emigrated leukocytes, and occasionally red corpuscles, are found within the tubules and the capsule of the Malpighian bodies. The term *acute catarrhal* or *desquamative nephritis* is more or less appropriate in such cases. The kidney is enlarged, somewhat swollen, and generally rather pale in color. The changes are most marked in the cortex, which is thicker than normal, and by its light color contrasts strongly with the pyramids. The capsule strips easily. In most cases the affection is one of slight severity.

Acute Glomerulonephritis.—In another group of cases, occurring most commonly in scarlet fever, the glomeruli are primarily attacked and most severely affected throughout the disease. Such cases are designated *glomerulonephritis.* The

FIG. 268.—Acute glomerulonephritis in diphtheria: *a*, albuminous exudate in Malpighian body; *b*, convoluted tubule; *c*, vascular tuft or glomerulus covered with proliferated epithelium (Kaufmann).

capillaries of the Malpighian tuft are distended, and the glomerulus is filled with albuminous exudate, red and white blood-corpuscles and with proliferated and desquamated epithelial cells

derived from the epithelium lining the capsule or that covering the Malpighian tuft (Fig. 268). Occasionally thrombosis occurs within the vessels, and hyaline degeneration may affect the capillary walls; in other cases marked necrotic changes may occur in the epithelium covering the tufts of vessels and lining the sac.

Acute diffuse nephritis is the ordinary form of acute Bright's disease, and is the form in which either of the two preceding are prone to terminate. The kidney is enlarged, and sometimes congested and red in color; at other times it is light-colored or even yellowish in consequence of the epithelial degeneration and the anemia caused by the epithelial swelling. On section the cortex is much increased in width, and when congestion exists it is more or less mottled, showing spots or streaks of reddish color, the intervening portions of the substance being grayish or yellowish in hue. In other cases the entire cortical substance is uniformly gray or yellow. The latter appearance is prone to occur in cases of considerable duration. In intense acute cases there may be punctate or linear hemorrhages, especially toward the surface of the organ, and the entire organ may be of a dark-red color. In all cases the capsule strips easily from the underlying substance.

Microscopically the changes are most varied. In all cases there is more or less degeneration of the epithelium of the convoluted tubules and of that in the Malpighian bodies. In the earlier stages the cells become swollen and granular (cloudy swelling), while in advanced stages they may be filled with dark granules or droplets of fat (fatty degeneration). On the other hand, cases of great intensity may be marked from the very first by complete necrosis of the epithelial cells. Similar changes may be met with in the epithelium of the Malpighian bodies, and the latter may be converted into granular masses in which the capillary tufts are more or less obscured. Associated with these purely parenchymatous changes are found evidences of interstitial involvement in the presence of masses of round cells between the tubules and in the vicinity of the Malpighian bodies. Active proliferation of the connective tissues is also observed, though less markedly, in the same situations. Certain cases are distinguished by their special tendency to hemorrhagic extravasations into and around the tubules and into the Malpighian bodies. To such the name *acute hemorrhagic nephritis* is sometimes applied. This variety is especially common in intense septic or infectious cases, particularly such as are attended with minute embolism of the renal arterioles.

Acute Interstitial Nephritis; Suppurative Nephritis.

Acute interstitial nephritis occurs in practically only one form, namely, in that which is characterized by the formation of purulent foci in the kidney. Acute interstitial changes, non-suppurative in

character, occur, as has been described, in association with parenchymatous nephritis, but not as an independent affection.

Suppurative nephritis may result from metastatic involvement of the kidneys in cases of general septicopyemia, from ascending inflammation in association with pyelitis, or from involvement of the kidney in cases of suppurative disease in the vicinity.

Embolic suppurative nephritis leads to the formation of small foci of suppuration in the substance of the organ, especially toward the periphery. These may occur as mere points of yellowish color, or they may be surrounded by a considerable zone of hemorrhagic infiltration. The surface of the organ may be studded with small elevated points, and as the process advances larger foci may form by confluence. Microscopically the changes are found especially in the vicinity of the Malpighian bodies, in the small capillaries of which the micro-organisms primarily locate themselves. Hemorrhagic extravasation is usually marked, and the accumulations of leukocytes leading to suppuration are the characteristic feature. Degenerative changes may be seen in the epithelium of the vicinity, and, if the case has persisted for a certain length of time, parenchymatous changes may be quite extensive.

In certain infectious fevers micro-organisms escape from the blood through the kidneys (pneumonia, typhoid fever, anthrax).

FIG. 269.—Pyelonephritis, showing lines of ascending suppuration (Kaufmann).

In such cases it is possible that the bacteria which have been excreted may cause infection in the lower parts of the uriniferous tubules. The occurrence of such nephritis is uncertain.

Suppurative pyelonephritis occurs in cases of suppurative pyelitis, especially in consequence of impaction of calculi in the pelvis. In the earlier stages small linear areas of light color are seen in the pyramids and medulla, and microscopically these are found to be uriniferous tubules infiltrated with pus-cells (Fig. 269). In the later stages these may run together, forming purulent collections of considerable size. The superficial portions of the medulla and cortex are only secondarily involved, and the suppurative areas

here assume a more rounded shape. Pyelonephritis may terminate by rupture of the abscesses into the pelvis of the kidney and the discharge of the pus with the urine; by rupture on the surface of the kidney, causing perinephritic abscess; or by inspissation and calcareous infiltration of the contents of the abscess. When discharge has taken place, or when inspissation occurs, induration and cicatrization of the diseased areas result. A considerable portion of the kidney may be thus converted into scar-tissue.

Suppurative nephritis, following **suppuration around the kidney,** leads to the formation of superficial abscesses and erosions.

CHRONIC NEPHRITIS.

Chronic nephritis presents itself in varieties allied to the acute forms, and we may distinguish chronic parenchymatous and chronic interstitial nephritis. The former is practically always a diffuse process, presenting no such limitations to the epithelium of the tubules or to the glomeruli as are witnessed in the acute disease. Chronic interstitial nephritis is characterized mainly by hyperplasia of the connective tissue.

CHRONIC PARENCHYMATOUS NEPHRITIS.

Chronic parenchymatous nephritis in most cases results from acute attacks which have become chronic by continuation or repetition. It occurs after various infectious diseases, in consequence of alcoholism, or in an obscure manner, autointoxication probably accounting for some of the latter group of cases.

Pathologic Anatomy.—The kidney is usually enlarged, and on section the cortical substance is often increased in width. The color is most frequently grayish or yellowish in consequence of the disease of the epithelium and of the anemia caused by the swelling of the cells. The pyramids may be quite red and swollen, or may be compressed and light in color. The capsule strips easily, and the substance of the organ is only moderately firm; sometimes, indeed, it is quite soft. To this form of chronic parenchymatous nephritis the term *large white kidney* is often applied. In other cases the substance of the organ may be quite red in color, or may be mottled, light areas of yellowish or gray color alternating with congested portions. In such cases careful examination may show punctate or linear extravasations of blood, and the term *chronic hemorrhagic nephritis* is not inappropriate. The kidney is enlarged, as in the first variety, the cortex thick, and the capsule easily removed. In either case small cysts may form in the substance of the organ or upon the surface by distention of the convoluted tubules or capsules of Bowman.

In the later stages of chronic parenchymatous nephritis the

degenerative processes in the epithelium become pronounced, and the organ may grow progressively lighter in color and more fatty in appearance. At the same time interstitial processes associate themselves, and the substance of the organ becomes more firm and the kidney is reduced in size. Attachments are formed between the substance and the capsule, which is no longer removable without laceration of the underlying substance. This terminal form of chronic parenchymatous nephritis has been designated as *fatty contracting kidney*, or as *secondary interstitial nephritis*, according to the amount of fatty parenchymatous change or of interstitial overgrowth present in the individual case (see page 577).

Microscopically chronic parenchymatous nephritis is marked by striking degenerative changes in the epithelial cells of the convoluted tubules, and to a less extent in those lining the capsule of Bowman and covering the Malpighian tufts (Fig. 270). The



FIG. 270.—Chronic parenchymatous nephritis, showing marked involvement of the Malpighian body and considerable interstitial change.

epithelium of the tubules is at first swollen and finely granular, the nucleus being obscured and the cells oftentimes becoming fused (cloudy swelling). In the more advanced stages of the process marked fatty degeneration of the cells is discovered, and they may break down completely, so that the lumen of the tubule is filled with fatty and granular detritus (Fig. 271). Extravasations of leukocytes or of red blood-corpuscles may take place, especially in the form known as *hemorrhagic nephritis*. Many of the tubules may be filled with tube-casts of hyaline or more frequently of granular appearance. The Malpighian bodies are usually simultaneously, though perhaps less markedly, affected. The epithelium in the latter is proliferated and degenerated, and the vascular tuft may

present considerable hyaline degeneration. In the hemorrhagic variety the Malpighian body may be completely filled with extravasated blood. Side by side with these parenchymatous changes may be seen changes in the interstitial tissues. Notably, there are proliferation and thickening of the capsule of Bowman and of

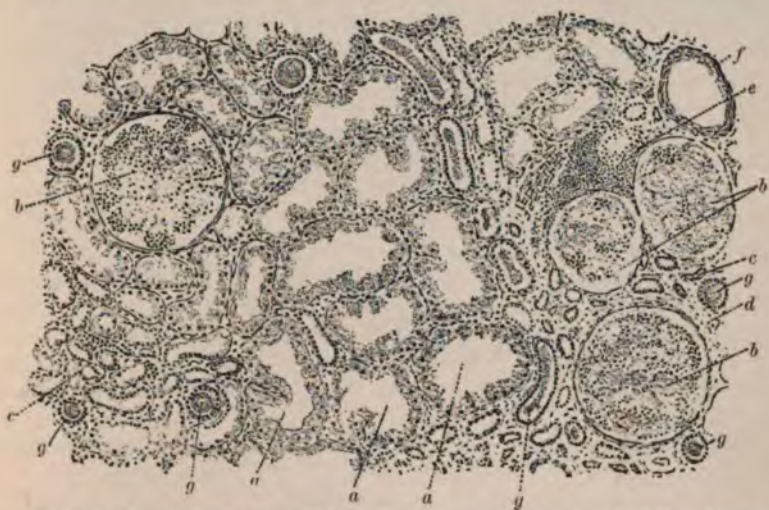

FIG. 271.—Chronic parenchymatous nephritis: *a*, convoluted tubules with cloudy swelling of the epithelium; *b*, glomeruli, more or less degenerated; *c*, atrophic tubules; *d*, sclerotic interstitial tissue; *e*, round-cell infiltration; *f*, blood-vessel; *g*, tube-casts in tubules (Kaufmann).

the connective tissues between the tubules. In advanced stages these interstitial changes are always present, and in those cases known as secondary interstitial nephritis the connective-tissue hyperplasia is the predominating condition. The walls of the small blood-vessels of the kidney are usually thickened by hyperplasia.

CHRONIC INTERSTITIAL NEPHRITIS.

Chronic interstitial nephritis leads to the formation of a contracted kidney. This may be a secondary form of nephritis following chronic parenchymatous nephritis, or it may be primary, when it is often associated with diffuse arteriosclerosis.

Secondary chronic interstitial nephritis is the terminal stage of certain cases of chronic parenchymatous nephritis, and results from a continuous hyperplasia of the interstitial tissues, with degeneration and atrophy of the parenchyma. The organ is reduced in size, and may be quite irregular upon the surface, the irregularity taking the form of large depressions or of fine granulations. The capsule strips with difficulty, portions of the kidney-

substance remaining attached. On section the kidney is found to be firmer than normal, and is of light color, often yellowish (fatty) in hue. The cortex may be nearly the normal thickness, or may be considerably reduced. The small blood-vessels of the substance of the organ may be patulous and evidently sclerotic.

Microscopically the epithelium of the tubules is granular, fatty, or atrophic, and the cells are found detached in great numbers and occupying the lumen of the tubules. The tubules themselves may be compressed by surrounding interstitial overgrowth, or may be distended even to the formation of cystic dilatations. The capsule of Bowman is greatly thickened, and the Malpighian bodies may be much distorted and compressed.

Primary Chronic Interstitial Nephritis; Red Granular Kidney; Arteriosclerotic Nephritis; Gouty Nephritis.—All of these terms have been applied to a form of interstitial nephritis probably produced by irritants conveyed through the circulation. It occurs in consequence of alcoholism, syphilis, gout, chronic plumbism, and chronic cachexias of other kinds. It is not rarely associated with diffuse arteriosclerosis. A certain amount of interstitial nephritis of this variety is a natural lesion of old age.

Pathologic Anatomy.—The kidney is usually decreased in size,

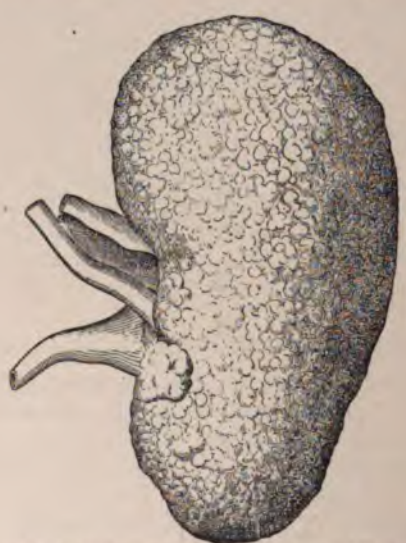

FIG. 272.—Chronic interstitial nephritis; granular kidney (Orth).

and sometimes may be very much contracted. In other cases the reduction in the dimensions is inconsiderable, and the size may even be increased. The surface is irregular, and, on removal

of the capsule, is found to be finely granular or irregularly lobulated (Fig. 272). The capsule itself strips with difficulty. Small

FIG. 273.—Chronic interstitial nephritis: great increase of connective tissue around the glomeruli, renal tubules, and blood-vessels.

cysts may be seen upon the surface. On section the substance is firm, and may sometimes be almost cartilaginous in consistence.

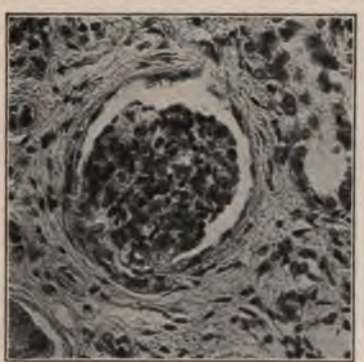

FIG. 274.—Chronic interstitial nephritis (from a photograph by Dr. Wm. M. Gray).

The cortex is narrow, often being reduced to a quarter or one-sixth its normal width; while the pyramids may be increased in size or contracted like the cortex, and not rarely show dense white sclerotic tissue radiating from the apices. In gouty cases deposits of urates may be observed in the same situation. The color of the kidney varies, but is usually grayish-brown or gray. The blood-

vessels in the substance of the organ are usually patulous and their walls visibly thickened.

Microscopically, chronic interstitial nephritis is characterized by great hyperplasia of the connective tissue surrounding the Malpighian bodies and the convoluted tubules, and by hyperplasia of the walls of the blood-vessels (Fig. 273). The overgrowth of connective tissue may be irregular in its distribution, and may vary greatly in amount. In beginning cases there is only moderate thickening of the capsules of Bowman and of the intertubular tissues and walls of the blood-vessels. In the most pronounced cases the kidney-substance is almost wholly transformed into fibrous tissue of dense sclerotic character (Fig. 274). The epithelium undergoes progressive atrophy, the cells shrinking in size and becoming granular and loosened from the basement-membrane. Hyaline or granular tube-casts may be found within the tubules, and the latter are compressed by contraction of the new-formed connective tissue, or in other cases dilated by the disappearance of the epithelium.

Pathologic Physiology of Nephritis.—The effect of acute or chronic nephritis varies greatly in individual cases. Profound systemic disturbances in acute cases are doubtless often the result of the action of toxic substances, which caused the nephritis, rather than of the disease of the kidneys itself. In uncomplicated cases of acute or chronic nephritis the influence upon the general metabolism is seemingly slight. Investigations have not as yet shown any decided increase in the metabolic consumption of the tissues, and no specific disturbances of metabolism of any sort have been discovered. It is very likely, however, that extensive disease of the kidneys does exercise some influence, since these organs undoubtedly have actual glandular functions and are not merely passive agents for the filtration of the blood and the excretion of urine. The peculiar intoxication which occurs in nephritis, and to which the name uremia (*q. v.*) is applied, has received no satisfactory explanation. It is probable that substances normally excreted in the urine are retained in the blood and accumulate to such an extent that intoxication results. It is also likely that substances which are normally elaborated by the kidneys and excreted in altered forms remain in the blood and occasion disturbances. During the progress of uremia there seems undoubtedly to be active tissue-consumption, but accurate studies are wanting.

Gastro-intestinal symptoms are frequent in renal disease. In a notable proportion of cases the gastric secretion has been found deficient, and this may account for some of the disturbances. Putrefactive processes in the intestines have also been demonstrated in some cases, being evidenced by the increased quantity of ethereal sulphates in the urine. In the later stages of nephritis, and especially in uremia, severe gastro-intestinal disorders

sometimes develop. These have been explained by the assumption that urea is excreted through the gastro-intestinal mucous membrane, and undergoes ammoniacal decomposition within the digestive tract. The ammonia formed by this decomposition is supposed to be the immediate cause of the gastro-intestinal disturbance.

The urine in nephritis is of the greatest interest. In acute cases, and sometimes in chronic forms it suffers notable change of appearance by admixture of blood. In other instances the color and physical properties are to a large extent dependent upon its amount. As a rule, the quantity of urine is decreased. The nitrogenous elimination is of particular interest. In acute cases, in which the quantity of urine is greatly deficient, there is undoubtedly an insufficient excretion of nitrogen from the urine; subsequently the nitrogenous element may be excreted in increased quantities. In acute nephritis without marked diminution in the quantity of urine, the nitrogenous elimination may remain satisfactory. In chronic nephritis the elimination of nitrogen in the urine may be reduced, both in the parenchymatous and interstitial forms of nephritis. The amount of urea is very commonly decreased; in part this may be compensated for by increased elimination through the skin and intestines. Nitrogen retention is not invariable, and from time to time periods of increased elimination may occur. The uric acid is usually decreased in quantity, but may be entirely normal in any form of nephritis, and may in some instances be temporarily increased. Ammonia is present in normal quantities. During uremia it may be increased. Xanthin may be present in increased quantities, and creatinin is reduced in quantity.

The urine in nephritis presents two striking peculiarities: the presence of albumin, discoverable by chemical examination, and the presence of tube-casts. Albuminuria is an almost constant symptom, though occasionally, in chronic interstitial nephritis, the amount may be so small that it is not detected by the cruder tests. The more delicate methods will probably detect albumin in every case. Serum-albumin is the more important form, but globulin occurs in small amounts in every case. In hemorrhagic forms of acute or chronic nephritis and in cases complicated by amyloid degeneration globulin may be found in considerable quantity.

The tube-casts met with in nephritis are casts formed within the convoluted tubules, or more rarely in other parts, and are composed of albuminoid substances and possibly sometimes of fibrin. They are formed partly of materials which have accumulated in the tubules by exudation, partly of the granular detritus of the degenerated epithelium, or of red and white blood-corpuscles. We may distinguish a number of varieties, viz., hyaline, cellular, crystalline, and granular casts and cylindroids.

Hyaline casts are clear, rounded bodies having a diameter of from 0.01 to 0.03 mm. and a variable length. Sometimes they are quite short; at other times they extend across several fields of the microscope. They may be straight, or spiral or contorted. Sometimes they are so transparent and light colored that they are scarcely visible, or, on the other hand, they may be of a denser structure and less transparent. Hyaline casts are frequently met with in simple congestion of the kidney and in icterus unassociated with discoverable nephritis. They are most abundant in acute parenchymatous nephritis, but are met with also in chronic parenchymatous and interstitial nephritis. A form of hyaline cast known as the *waxy cast* is met with, sometimes in acute, but more commonly in chronic nephritis (Fig. 275). It is distin-

FIG. 275.—Waxy hyaline casts.

FIG. 276.—Blood-casts, composed wholly of red or white corpuscles, or hyaline substance covered with blood-corpuscle.

guished by the moulded, wax-like appearance and by its apparent rigidity.

Cellular Casts.—The most frequent form is that in which the surface of a hyaline or granular cast is covered with epithelial cells that have detached themselves from the tubules. The entire surface may be covered, or there may be but a few cells here and there. This form is found especially in acute parenchymatous nephritis. *Leucocytic casts* are moulds of the tubules composed of masses of leukocytes. They are found especially in purulent pyelonephritis. Occasionally leukocytes are found upon the surface of other casts. *Blood-casts*, composed of red blood-corpuscles, or of blood-pigment formed by disintegrated red corpuscles, are frequently observed in acute and chronic hemorrhagic nephritis (Fig. 276).

Crystalline Casts.—Moulds of the tubules, composed of uric acid or oxalate of lime, are sometimes observed in chronic nephri-

tis, when there is a tendency to the deposition of the crystals named (Fig. 277). Similar formations may be met with in the urine of the new-born independently of nephritis (see page 589).

Granular casts may be light or dark, according to the amount

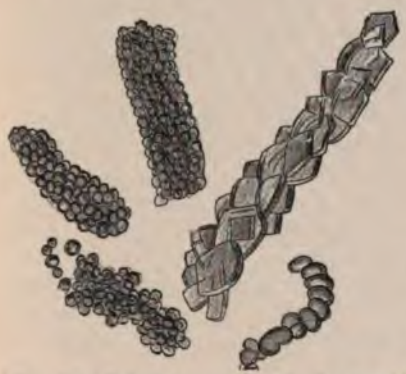

FIG. 277.—Tube-casts, composed of uric-acid crystals.

FIG. 278.—Granular and fatty casts and two compound granular cells.

and character of the granular material. They are composed of substances derived from broken-down epithelial cells, and are especially common in chronic nephritis, though they may occur in

FIG. 279.—Cylindroids: *a* and *b*, cast-like forms; *c*, filamentous forms.

quite acute cases. Sometimes, instead of granular matter, the débris of the epithelial cells occurs as oil-drops, and the term *fatty casts* is appropriately applied (Fig. 278). The diameter and length of granular casts vary considerably. As a rule, the diameter is about the same as that of the hyaline casts, but the length is rarely as great.

Cylindroids are formations resembling casts more or less closely. Sometimes they appear as thread-like formations, rounded or flat, and occurring singly or in twisted bunches. In other cases they may be quite similar to hyaline casts, though distinguished by a long, tapering end or tail (Fig. 279). Cylindroids occur in conditions of renal irritation not sufficient to constitute nephritis, as well as in cases of genuine nephritis. They are also supposed to be produced in the tubular glands of other parts of the genito-urinary tract, as in the glands of Cowper.

Other Constituents of the Urine.—Various cellular constituents are found in nephritis. In acute and in chronic hemorrhagic nephritis white and red blood-corpuscles are frequently observed; and epithelial cells are more or less abundant in all forms of parenchymatous nephritis. In the acuter varieties swollen and granular rounded cells are observed; in the more chronic forms, particularly when fatty degeneration is pronounced, epithelial cells or leukocytes densely filled with dark granular or globular fat are conspicuous. The term *compound granule-cell* has been applied to these cells.

Results of Nephritis.—Nephritis leads to notable changes in the entire organism, and particularly in the vascular system.

Cardiac Changes.—In acute nephritis there may be associated acute degenerative or inflammatory lesions of the heart-muscle, and cardiac dilatation may occur. These, however, are usually results of the infectious or toxic cause underlying the nephritis, rather than results of the nephritis itself. When parenchymatous nephritis becomes subacute or chronic, hypertrophy of the heart (notably of the left ventricle) takes place, and this reaches extreme proportions in chronic interstitial nephritis. The cause of the hypertrophy of the heart has occasioned much controversy. It seems likely that it is in large part the result of irritation and over-stimulation of the heart-muscle by substances retained in the blood, instead of being excreted. The obstruction to the circulation occasioned by thickening of the walls of the renal vessels is of little moment; and the theory that the cardiac hypertrophy is due to a hydremic condition and increased quantity of blood, in consequence of retention of water in the system, is negatived by the fact that such hydremic excess of blood is certainly absent in many cases. Associated arteriosclerosis is undoubtedly one of the important factors in the production of cardiac hypertrophy.

Arteriosclerosis.—The arteries are frequently sclerotic in cases of chronic nephritis. In part this is due to the direct action of toxic products of improper metabolism occurring in Bright's disease; in part it is coincidental or an antecedent condition.

Acute inflammatory lesions of the serous membranes, and to a less extent of the mucous membranes, sometimes occur in Bright's

disease. Acute endocarditis, acute pericarditis, and pleurisy are the most frequent conditions. Of the inflammatory conditions of the mucous membranes tonsillitis and pharyngitis are not infrequent. Enteritis, even of ulcerative type, may occur, especially in chronic nephritis. This, in part, seems to result from vicarious excretion of irritant matters from the intestinal mucosa.

Edema, or **dropsy,** is a frequent manifestation of nephritis. It is most frequent in the parenchymatous forms, particularly in such as occasion changes in the glomeruli and other vascular portions of the kidney. The important etiologic factor is doubtless disease of the blood-vessels. In chronic interstitial nephritis dropsy is rarely observed until the late stages, when manifest arterial disease and failing circulation from cardiac weakness have supervened. The edema usually begins in the loose subcutaneous tissues of the eyelids and hands, but extends to all parts of the body, causing anasarca. Internal edema, and especially edema of the lungs, may be met with.

Uremia is the name applied to certain clinical manifestations probably caused by the retention of toxic substances in the blood which ordinarily are excreted with the urine. The nature of the substance or substances in question remains obscure. Neither urea, potassium nor ammonium salts, uric acid, nor various other constituents of the urine alone produce uræmic manifestations; though the injection into animals of some of these may cause toxic symptoms, such as convulsions or coma. It may be that uremia is caused by the conjoined action of a number of such toxic bodies, but it is not improbable that the poisons are substances as yet undiscovered. The theory that uremia is due to edema or anemia of the brain may be definitely abandoned.

ATROPHY AND HYPERTROPHY.

Atrophy of the kidney may be congenital (hypoplasia), or may occur in old age (senile atrophy). In the latter case the kidney is small, hard, and usually darker in color than normal. The irregular atrophy of the parenchyma leads to irregularities upon the surface of the organ. The capsule may be thickened, and not rarely the perirenal fat is abundant, and considerable fatty deposit occurs beneath the mucous membrane of the pelvis.

Microscopically the renal cells are small in size, somewhat dark, and granular. They may disappear entirely from the tubules in places, and the intertubular tissue and the basement-membrane are correspondingly thickened. The Malpighian bodies may be converted into contracted fibrous areas. In some cases the interstitial processes become so pronounced that the changes in the kidney become those of interstitial nephritis. These cases

are particularly met with in persons of advanced years having arteriosclerosis (see Chronic Interstitial Nephritis).

Hypertrophy may affect one kidney when its fellow is congenitally wanting, has become diseased, or has been removed. Under these circumstances the remaining or healthy organ sometimes undergoes considerable hypertrophy. The appearance is that of a much enlarged but otherwise normal kidney.

Microscopically there may be simply increase of the size of the tubules, or in cases in which the compensatory hypertrophy has begun before the completion of development there may be actual increase in the number of tubules and Malpighian bodies.

DEGENERATIONS.

Parenchymatous degeneration, or **cloudy swelling,** occurs in the kidneys in consequence of the action of various poisons, infectious or chemical. It is met with in practically all cases of diphtheria, scarlet fever, and cholera, and less commonly in many other infectious diseases. Among the poisons the various parenchyma-poisons (*q. v.*, Part I) are all capable of attacking the kidney and producing cloudy swelling. In case of either toxic or infectious degenerations, however, the process is prone to become more serious, and to terminate in acute parenchymatous nephritis. No sharp dividing-line can be drawn between the two conditions.

The kidney is somewhat increased in size, is softer than normal, and on section the cortex is yellowish or of light-grayish color (Fig. 280). The Malpighian bodies may be prominent as

FIG. 280.—Parenchymatous degeneration of the kidney, from a case of cholera (modified from Kast and Rumpel).

red spots lying in the light-colored renal tissue. The pyramids are often congested, and contrast strongly with the cortical substance.

Microscopically, fine granulation of the cells of the convoluted

or other tubules is the striking feature. The nuclei of the cells are obscured, and at times all of the cells of the tubule apparently become fused. Exudative changes and hyperplasia of the interstitial tissues are wanting in a purely degenerative condition. Frequently the kidney is restored to the normal condition, but, on the other hand, acute Bright's disease or fatty degeneration may ensue.

Fatty Degeneration.—This occurs in consequence of the last-described condition, or independently in consequence of general anemia and systemic disorders, as in progressive pernicious anemia and tuberculosis. Fatty degeneration of the kidney frequently occurs in the course of pregnancy, when it is due to disturbance of the circulation in the kidneys or possibly to obstruction of the ureters. In these cases the process usually advances to the condition of diffuse nephritis.

In pure fatty degeneration the kidney is about the normal size, or often smaller than normal; is soft; and on section the cortex has about the normal width. The color is uniformly yellowish or mottled, certain areas being yellowish in color and others normal or perhaps hyperemic. Usually the surface of the kidney is smooth, but sometimes localized spots of degeneration may become depressed and give rise to irregularities.

Microscopically the epithelial cells are granular, or filled with oil-drops (Fig. 281). Not rarely the cells are loosened and lie

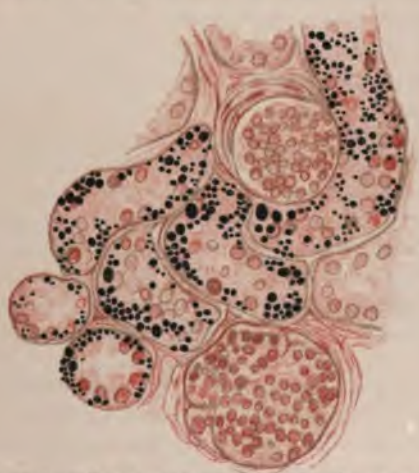

FIG. 281.—Fatty degeneration of the epithelium of the tubules: stained with osmic acid (Simmonds).

free within the lumen of the tubules. The basement-membrane and interstitial tissues may be somewhat thickened, either apparently or actually.

Fatty infiltration is an unimportant condition. In the atrophic kidney of old age and in the contracted kidneys of chronic nephritis fatty infiltration of the areolar tissue beneath the mucosa of the pelvis is frequently observed. Fatty infiltration of the epithelial cells may occur under normal conditions, or in cases in which the blood is surcharged with fat (*lipemia*) and in which the kidneys are actively engaged in its excretion. Fatty infiltration of the perirenal cellular tissues occurs in general obesity, and sometimes as a localized affection in cases of advanced renal disease, particularly atrophy.

Calcification may occur in diseased areas of the kidneys, as in sclerotic Malpighian bodies, in old infarcts and the like. Occasionally calcification occurs in the epithelial cells themselves, particularly in such as have undergone necrosis.

Glycogenic infiltration of the kidneys occurs in diabetes. It affects the epithelial cells, particularly those in the portions of the organ lying between the medulla and the cortex. The kidney is usually increased in size, the cortex broader than normal, and the consistency increased. The substance may be lighter colored and of homogeneous appearance. Microscopically the epithelial cells, particularly those of the tubes of Henle, are found to be altered in character, the normal granular condition of the protoplasm having disappeared. The glycogenic nature of the infiltrating substance is recognized by the dark-brown color obtained by staining fresh sections with iodin.

Amyloid degeneration occurs in the kidneys under the same conditions as in the liver and spleen. It is most frequent in cases of chronic tuberculosis of the lungs, and occurs in cases of long-standing suppuration connected with bone, in syphilis, and as a result of other cachexias. The kidney is enlarged, sometimes to twice its normal bulk, is harder than normal, and on section the substance is found light grayish in color. It may be uniformly grayish or waxy; or, on the other hand, it may be mottled, grayish areas alternating with portions of yellow color, the latter being due to fatty degeneration. Amyloid degeneration begins in the small blood-vessels, particularly those of the Malpighian tufts, and spreads to the connective tissues of the organ, but does not involve the epithelium.

Microscopically the glomeruli may present spots of hyaline or homogeneous appearance in which the capillaries seem completely disorganized, and the entire glomerulus may be transformed into a transparent or translucent mass (Fig. 282). The capsule is thickened and ofttimes simultaneously diseased. The tubules habitually contain hyaline casts. The organ becomes more or less anemic from obstruction of the capillaries, and sooner or later fatty degeneration of the epithelial cells takes place. Inflammatory processes are usually wanting, but nephritis may become

associated with amyloid degeneration, and the latter process may occur in kidneys primarily the seat of nephritis. The urine in amyloid disease is albuminous and scanty; the proportion of serum-globulin is excessive. Not rarely it contains hyaline casts which respond more or less distinctly to the color-tests for



FIG. 282.—Contracted and amyloid kidney (from a photograph by Dr. Wm. M. Gray).

amyloid substance, but these are not diagnostic, and it is doubtful whether they are in reality composed of amyloid material.

CONCRETIONS IN THE URINIFEROUS TUBULES.

Various calcareous concretions, or "infarcts," occur in the uriniferous tubules, particularly in the large collecting tubules near their termination at the apex of the pyramids. Collections of urates, particularly urate of ammonium, are frequently seen in the form of radiating lines of light-grayish, yellowish, or reddish color, marking the pyramids near the apices in new-born infants. These consist of crystalline concretions filling the large uriniferous tubules, and have been considered as a valuable medicolegal indication that the infant had breathed. They are not, however, sufficient proof. Sometimes the concretions are passed with the urine, and are discovered as large casts of conglomerated crystals. Less frequently other forms of crystals are met with in the infarcts of the new-born. Similar concretions occur in gouty individuals, particularly in aged persons, and calcium salts may be deposited when the blood is surcharged with them in consequence of diseases of

the bones. Triple phosphates may be found as a consequence of obstruction of the urinary passages and stagnation of urine.

Concretions composed of bilirubin may be formed in extreme jaundice, and particularly in the jaundice of the new-born. Infarcts composed of hemoglobin may be seen in cases of hemoglobinuria due to infectious and toxic causes.

INFECTIOUS DISEASES.

Tuberculosis.—Tuberculosis may occur in the kidney in the form of minute, grayish-white miliary tubercles as part of a general hematogeneous tuberculosis. A second form, which is also hematogenic, is known as *chronic local tuberculosis.* In this form the substance of the kidney near the cortex, or sometimes that adjacent to the pelvis, is occupied by masses of cheesy tuberculous tissue, and there may be secondary miliary tuberculosis near by. Softening is prone to occur, and the tuberculous focus may discharge into the pelvis of the kidney, leaving a necrotic cavity. The entire organ may be transformed in this manner. Tuberculosis of the kidney may also result from ascending infection, being secondary to tuberculosis of the seminal vesicles of the bladder, of the ureters, and of the pelvis of the kidney. The process first involves the discharging tubules at the apices of the pyramids and spreads outward toward the cortex. Cheesy foci are formed, which may soften and discharge into the pelvis, as in the case of chronic local tuberculosis of the kidney. It is difficult to determine whether tuberculosis of the kidneys is more frequently the result of urogenital tuberculosis primarily affecting the parts below, or the cause of the latter. Primary affection of the kidney is certainly more common than many have been disposed to admit.

Syphilis.—In the earlier stages of syphilis there may possibly be acute nephritis similar to that of other infectious diseases. Syphilis of long duration may lead to amyloid degeneration of the kidney, or to chronic interstitial nephritis. In the latter case contractions of fibrous tissue leading to marked lobulation are rather characteristic. Syphilitic gummata are rare, but have been met with, and in their healing lead to marked scar-formation.

TUMORS.

Fibromata and **lipomata** may occasionally be met with in the kidney in the form of small rounded nodules. In association with calculous pyelitis and other conditions of the kidney leading to atrophy, the fatty tissue surrounding the kidney may be increased to such an extent as to constitute practically a fatty tumor.

Leiomyoma is an occasional growth of the kidney.

Congenital Adenoma.—Under the name of *struma aberrata suprarenalis* has been described a form of tumor of the kidney which results from splitting off of a remnant of the suprarenal capsule and its incorporation in the kidney, where it subsequently grows. The tumor presents the appearance of a small lipomatous growth beneath the capsule of the kidney, or, more rarely, it may attain considerable size. Histologically it consists of epithelial cells arranged in tubules similar to those of the cortical portion of the suprarenal capsule. These undergo considerable fatty infiltration, and almost the entire tumor may be fatty. Occasionally active proliferative changes occur in the epithelium, and a malignant character is assumed.

Sarcoma of the kidney is the most frequent malignant tumor. It may occur congenitally, or in later life. The size and general appearance vary considerably, but for the most part the structure is soft and grayish or sometimes quite red. Extravasations of blood or hemorrhages into the tumor are not uncommon. There may be a distinct capsule, or the growth may be an infiltrating one. Cystic softening is not infrequent.

Microscopically the appearance varies considerably, and the growth may be composed of round cells, spindle cells, or cells of various shapes. Not rarely a certain number of striped muscle-fibers are found, and to such growths the term *rhabdomyosarcoma* has been applied. In other cases there may be embedded in the sarcomatous tissue glandular acini composed of cylindrical or irregular epithelium, and to such the name *adenosarcoma* is applicable

FIG. 283.—Adenosarcoma of the kidney (modified from Kast and Rumpel).

(Fig. 283). Occasionally myxomatous tissue, smooth muscle-fibers, or even islets of cartilage are found. The multiform character of sarcoma of the kidney suggests an embryonal origin, and it is not unlikely that inclusions of the primitive Wolffian body are the starting-point of the disease.

Adenoma of the kidney is rare. It originates in the convoluted tubules, and presents itself in the form of more or less

nodular masses. Microscopically the appearance is that of a tubular adenoma. Proliferative changes occasionally affect the uriniferous tubules in interstitial nephritis, and give rise to small areas of adenomatous appearance. In such cases, however, the appearances are not those of a tumor in the strict sense.

Papilliferous cystic adenoma is sometimes observed. It occasions tumors of small or large size with fibrous capsules and cystic excavations in which the lining epithelium is elevated in a papillomatous manner.

Carcinoma is a rare primary tumor of the kidney, and occurs in persons of advanced years. The growth begins in the cortical substance or in the medulla, and presents itself as a soft white or, in case of hemorrhage into it, red tumor.

Microscopically it is found to be a glandular carcinoma presenting acini composed of epithelial cells of various shapes. Metastasis is rare.

Secondary Tumors.—Among the secondary tumors of the kidney are both sarcoma and carcinoma.

In the same group may be included the *lymphomatous infiltra-*

FIG. 284.—Lymphoid infiltrations between the renal tubules; from a case of leukemia.

tions of leukemia (Fig. 284). In this disease the kidney is often enlarged, and on section is found to be uniformly white or mottled in color, the light-colored areas representing masses of lymphoid cells. Most of these have doubtless been deposited from the circulation, but there is also evidence of local multiplication.

Cysts of the kidney are of various forms. In the course of chronic nephritis, especially the interstitial form, cystic dilatations of the convoluted tubules and Malpighian bodies are observed. These appear as small or large rounded bodies lying immediately beneath the capsule, and on section are found to contain serous liquid,

or colloid material, the result of degeneration of the epithelial lining of the cyst. Sometimes very large cysts of this character are met with in cases of nephritis, or even in otherwise healthy kidneys (Fig. 285). Cysts observed in kidneys which show no other disease

FIG. 285.—Large retention-cyst of kidney (from a specimen in the Museum of the Philadelphia Hospital).

are probably due to undiscovered obstructions of the uriniferous tubules.

Congenital cystic kidneys are of striking appearance. Usually both kidneys are affected, and are transformed into masses composed of innumerable cysts varying in size from microscopic points to cavities as large as a walnut (Fig. 286). On section the cysts are found to be filled with clear urinous liquid, or with colloid material, and between them is a stroma of more or less firm

fibrous tissue. The pelvis of the kidney is usually preserved. These cysts are formed by dilatation of the uriniferous tubules and Malpighian bodies, probably as the result of some fetal disease

FIG. 286.—Congenital cystic kidney (Specimen 2816, Museum N. Y. Hosp.).

which causes obstruction of the tubules at their outlet at the apex of the pyramids, or in consequence of faulty union between the upper and the lower segments of the uriniferous tubules in the development of the organ. Similar cystic degeneration, with enlargement of one or both kidneys, may occur in later life. Finally, cystic adenoma may again be alluded to.

PARASITES.

Bacteria occur in the kidney in various affections: thus pneumococci, typhoid bacilli, the bacilli of glanders and anthrax,

have been repeatedly demonstrated. In pyelonephritis the Bacillus coli communis is probably the usual active etiologic agent. Streptococci occur in the nephritis of septic conditions and in primary infectious nephritis of cryptogenic origin. Bacteria are occasionally found in the uriniferous tubules without gross lesions of the kidney, and are probably excreted with the urine.

Streptococci occur in the urine in the nephritis of septic conditions, and in primary infectious nephritis of cryptogenic origin. Various other bacteria may be met with in the urine (see Bacteriuria).

Animal parasites are occasionally observed, such as echinococcus-cysts, filariæ, the eggs of Distoma hematobium, amebæ, and infusoria. Round worms and the oxyuris sometimes migrate into the bladder or enter through fistulæ.

The echinococcus-cyst occurs in the form of hydatids, which may perforate into the pelvis of the kidney and discharge with the urine, or become inspissated and calcify. The Cysticercus cellulosæ and Pentastomum denticulatum are extremely rare. The Filaria sanguinis hominis occurs in the lymphatic spaces and in the blood-vessels of the kidney in cases of filariasis with chyluria. The kidneys in these cases show a waxy appearance on section, especially toward the apices of the pyramids, and the surface of the kidney may be abnormally lobulated. Microscopically the lymphatic spaces about the uriniferous tubules are greatly distended.

The Distoma hematobium occasionally produces pyelitis and pyelonephritis, with enlargement of the pelvis of the kidney.

THE PELVIS OF THE KIDNEY AND URETER.

CONGENITAL AND ACQUIRED MALFORMATIONS.

Occasionally the pelvis or ureters, or both, may be absent or imperfectly developed. Complete obliteration of the ureter may be observed. More frequently there are two pelves or ureters, and when this is the case the malformation is, as a rule, bilateral.

Obstructions of the ureter may be due to twists, to congenital atresia, or to other diseases of the ureter, particularly at its entrance into the bladder. It may be brought about by the lodgement of renal calculi, by tumors of the ureter, or by pressure upon it from without. The outflow of the urine may be obstructed by diseases of the bladder, and particularly by stricture of the ureter.

Dilatation of the ureter results from the conditions just named, and may reach considerable dimensions (Fig. 287). When

the obstruction is continued the dilatation may affect the pelvis of the kidney as well, and eventually the latter may be enormously enlarged. The pyramids become flattened, and the renal substance may undergo progressive atrophy, so that the kidney is converted into a sac-like formation filled with clear liquid, partly urine secreted in the earlier stages and partly transudate formed after the compression has stopped the renal function. To this condition the term *hydronephrosis* is applied.

FIG. 287.—Dilatation of the ureter due to calculous obstruction.

CALCULUS.

Calculi are of frequent occurrence in the pelvis of the kidney, and are formed by the precipitation of various normal or abnormal constituents of the urine. There may be merely small gritty particles lying in the calices or in the pelvis, to which the term *renal sand*, or *gravel*, is given; or there may be large stones, almost filling the pelvis and calices, and forming more or less accurate moulds of these. The most frequent forms are those composed of uric acid and oxalate of lime, but phosphate and carbonate of calcium and triple phosphate calculi are occasionally found. Stones composed of cystin and xanthin are rare. Uric-acid calculi are composed of the acid itself, or of urates, and present themselves as yellowish, brownish, or red, smooth or somewhat irregular formations. Those composed of oxalate of lime are irregular in shape and of brownish or red color.

The results of renal calculi may be trivial or serious. Small particles of renal sand are frequently passed without serious disturbance. Large calculi tend to set up inflammation of the pelvis of the kidney, and may obstruct the outflow of the urine, causing hydronephrosis (Fig. 288). In some cases cancer seems dependent upon the continued irritation of a retained calculus.

INFLAMMATION.

Inflammation of the pelvis, or **pyelitis**, may result from the irritation of poisons ingested, such as cantharides, turpentine, and the like, or it may occur in the course of infectious diseases of various kinds. More frequently it results from the irritation of a calculus, or from ascending inflammation consequent upon cystitis

and ureteritis. The mucous membrane becomes reddened and swollen, and not rarely is marked with hemorrhagic ecchymoses. The surface is covered with more or less desquamated epithelium and pus-cells. The inflammation may extend to the substance of the kidney (*pyelonephritis*). Considerable purulent exudate may take place, particularly when there is a calculus partially obstructing the ureter. When there is complete obstruction the pelvis may become dilated with pus, and the calices or the entire kidney may be converted into a large pus-sac (*pyonephrosis*). Deposits of triple phosphate may occur in pyelitis, and may occasion incrustations upon the mucous surface.

Inflammation of the ureter, or **ureteritis,** may occur under the same conditions as pyelitis. The mucous membrane of the ureter becomes swollen and reddened, as in catarrhal inflammations elsewhere, and there may be erosions or superficial ulcerations. The other coats are thickened by inflammatory infiltration and, in chronic cases, by fibrous-tissue overgrowth.

FIG. 288.—Calculus in the pelvis of the kidney and upper part of the ureter.

FIG. 289.—Tuberculous pyelonephritis (modified from Bollinger).

INFECTIOUS DISEASES.

Tuberculosis of the pelvis of the kidney may occur as a miliary tuberculosis, or in the form of caseous nodules or masses. The latter may be primary and hematogenous in origin, or may

result from ascending infection (Fig. 289). In such instances the mucosa becomes more or less extensively infiltrated, and later caseous and ulcerated. The process extends to the calices, and subsequently to the pyramids and other parts of the substance of the kidneys. The pelvis may contain considerable quantities of caseous or puriform matter, and the kidney-substance may be extensively involved. The urine contains pus-corpuscles and often tubercle bacilli in great numbers. Tuberculosis of the ureters leads to nodular or diffuse thickening, and commonly to more or less obstruction (Fig. 290).

FIG. 290.—Tuberculous nodule in the wall of the ureter, with beginning hydronephrosis (from a specimen in the Museum of the Philadelphia Hospital).

TUMORS.

Primary cancer is extremely rare. Secondary cancer may affect the pelvis in association with the kidney, or the ureters in association with the bladder. Small cystic formations are not uncommonly seen in the mucous membranes of the ureters, and may be due to inflammatory obstruction of the crypts, to proliferation and softening of the lymphoid follicles, or to parasitic invasion (*psorospermiæ*).

PARASITES.

Round worms have occasionally been found in the ureters. The eggs of Distomum hæmatobium are frequently deposited in the mucous membrane, and occasion inflammation and papillomatous excrescences.

THE URINARY BLADDER.

MALFORMATIONS.

Congenital malformations of the bladder are comparatively common. Among the more important is *exstrophy*. The anterior wall of the abdomen and of the bladder being wanting, the mucous membrane, with the openings of the ureters, is exposed to view. Not uncommonly this condition is associated with epispadias, or division of the clitoris. Sometimes the small intestine discharges through the exstrophic bladder, the large intestine being contracted or completely absent.

Occasionally the urachus remains patulous in consequence of atresia of the neck of the bladder or urethra, and the urine is discharged from the umbilical end. In other cases the urachus is closed at either end and the intervening portion is dilated, with the formation of a cyst. Again, there may be only partial obliteration of the urachus, the remaining portion in connection with the bladder being patulous and greatly dilated, forming a congenital adventitious sac. In one case under my observation this constituted a cavity of considerable size, and when filled distended the abdomen as far as the umbilicus. Congenital diverticula may occur in the anterior wall, and less commonly at the sides of the bladder. Complete absence of the bladder, division into lateral portions by a septum (*vesica bipartitis*), and other congenital defects are rare.

Acquired Malformations.—*Dilatation* of the bladder may result from congenital or acquired stenosis of its neck, or of the urethra; or from paralysis of its walls, in consequence of disease of the spinal cord or nerves. The organ may be greatly increased in size, often reaching the umbilicus. When the dilatation is acute the walls are greatly thinned, but when it has been gradually developed compensatory hypertrophy of the muscularis and of the submucous fibrous tissues leads to thickening of the walls. In these cases the mucous surface presents a ribbed appearance, fibrous-tissue bands standing out prominently and the mucosa being pouched between the bands. Diverticula of considerable size may form in this way, and the walls of the bladder sometimes present a considerable number of pouches.

CHANGES OF POSITION.

The position of the bladder, or of portions of it, is sometimes abnormal. Thus it may enter into a hernia, or a part of the wall of the bladder may prolapse with the wall of the vagina, forming vaginal cystocele. The latter is due to the traction of the prolapsing uterus, or to repeated overdistention of the bladder, with

weakness of the anterior vaginal wall. Complete inversion of the bladder through the urethra is occasionally observed in women.

RUPTURE.

Rupture of the bladder may be due to traumatism, and particularly to perforation by fractured pelvic bones. Rupture from overdistention is rare. Occasionally it may result from abdominal compression when the bladder is distended with urine, and ulcerative processes beginning in the mucous membrane may perforate the wall, or phlegmonous inflammations or degenerating new-growths surrounding the bladder may lead to perforation. In women perforations are frequently established between the bladder and vagina in consequence of pressure of the fetal head or of forceps, and vesicovaginal fistula results. Perforation into the peritoneal cavity is usually followed by fatal acute peritonitis. Rupture into the tissues below the peritoneal reflections gives rise to widespread infiltration of urine and phlegmonous or gangrenous inflammation.

CIRCULATORY DISTURBANCES.

Active hyperemia may result from irritant poisons, such as cantharides, or may occur in persons suffering from paraplegia, in consequence of disturbances of innervation.

Passive hyperemia occurs when there is pressure upon the inferior vena cava or thrombosis of that vein. The mucous membrane becomes dark-red and is often marked with punctate hemorrhages. Considerable varicosity of the veins at the neck of the organ may occur, and may give rise to copious hemorrhages, or to obstruction and retention of the urine.

Hemorrhages in the mucous membrane occur in severe congestion or inflammation, and in various hemorrhagic diseases. Large hemorrhages into the cavity itself may result from traumatism from without, or from calculi. The varicosities before mentioned may occasion considerable hemorrhage, as may also papillomatous or other new-growths. Large quantities of blood with little admixture of urine may lead to the formation of dense clots within the organ, but when the quantity is small the blood is mingled with the urine.

INFLAMMATION.

Inflammation of the bladder, or **cystitis,** varies in extent, duration, and character. Acute cystitis may result from irritant poisons excreted with the urine, and frequently attends acute infectious diseases. In these cases, however, the disease is gener-

ally mild. More intense forms occur from extension of inflammation to the bladder in cases of urethritis, or when septic material is introduced in catheterization. Retention and decomposition of the urine from strictures or prostatic hypertrophy are frequent causes of chronic cystitis.

Cystitis may present itself as a mucopurulent catarrh, acute or chronic in course; as phlegmonous inflammation; or as a pseudomembranous process.

Mucopurulent cystitis in the acute stages causes swelling of the mucous membrane, with injection of blood-vessels and sometimes punctate hemorrhages. The surface, especially at the base, is covered with mucopurulent exudate of a tenacious character, in which pus-cells and desquamated epithelium are abundant. The urine tends to undergo ammoniacal fermentation.

In chronic cases thickening of the submucosa and hypertrophy of the muscularis cause great thickening of the organ, and the surface within is usually ribbed from the prominence of the fibrous-tissue bands and the pouching of the mucous membrane between the bands (Fig. 291). Erosions and ulceration may occur upon the surface, and occasionally perforation of the walls takes place. Incrustations of triple phosphate and of other common salts frequently cover the surface.

FIG. 291.—Dilated ribbed bladder.

Phlegmonous cystitis results from intense infections, or from the retention of urine in paraplegia. The submucous tissue is considerably swollen and infiltrated, and complete perforation of the walls and paracystitis or phlegmonous inflammation of the tissues surrounding the bladder may ensue.

Pseudomembranous cystitis occurs in certain severe infectious diseases, and may present itself in the form of a typical pseudomembrane, or as a combination of phlegmonous and pseudomembranous inflammation. Occasionally pseudomembranes are formed without any inflammatory process, in nervous individuals, and in the course of or after pneumonia I have seen a cast of the entire bladder of this nature.

INFECTIOUS DISEASES.

Tuberculosis of the bladder is usually secondary to tuberculosis of the kidney, or to that of the prostate, seminal vesicles, or epididymis. Tubercular ulcers independent of tuberculosis elsewhere in the urogenital tract may occur in phthisis or intestinal

FIG. 292.—Tuberculosis of the bladder (Orth).

tuberculosis, but such cases are rare. The lesions observed in tuberculosis of the bladder are ulcerations, for the most part occupying the base and surrounding the orifices of the ureters, and there may be distinct or clustered tubercles. Numerous small ulcers, or a single large ulcerated surface may be observed (Fig. 292). Deposits of triple phosphate frequently form incrustations on the surface.

Syphilitic ulcers have been observed in the bladder, but are extremely rare.

CALCULI AND FOREIGN BODIES.

The bladder is the commonest seat of urinary calculi. They may occur in the form of fine particles or gravel, or as stones of considerable size. Usually there is but one; sometimes a considerable number may be present. The shape and general appearance depend upon the composition of the stone.

The formation of calculi is due to precipitation from the urine of its various earthy or other constituents as the result of stagnation and fermentative change. Foreign bodies often form the nuclei of stones, and thus a calculus in the bladder may form around broken portions of catheters, hairpins, or other foreign bodies inserted into the urethra. Similarly, parasites may be the nucleus, and in ordinary cases of stone the mucous or degenerated epithelial cells constitute the focus about which the deposit occurs. There is practically never a simple sediment of saline or earthy material, but a combination of the latter with some albuminous matrix. Catarrhal conditions of the bladder, especially when combined with stagnation of the urine as the result of hypertrophy of the prostate, urethral stricture, and the like, are the most common antecedent causes.

Calculi in the bladder may be composed of uric acid or urates, of oxalate of lime, of various phosphates, of carbonate of lime, or of certain organic compounds.

Uric acid and urate calculi are less common in the bladder than in the kidney. They result from surcharge of the urine with uric acid in lithemic or gouty individuals, and from acid decomposition rendering the uric acid and urates insoluble. They are yellowish or red in color, rounded, slightly granular or smooth upon the surface, and, as a rule, quite hard. The calculi composed of urates are usually more irregular and softer, and are generally lighter in color. Frequently phosphates are combined with them.

Phosphatic calculi may be of several kinds; they may be composed of phosphate of lime, triple phosphate, or mixed phosphates. They form the most frequent variety of calculi and concretions in the bladder, and are generally due to alkaline decomposition causing a deposit of the simple phosphate of lime or of the combination of phosphate of magnesium with ammonium phosphate, known as triple phosphate. These deposits may occur in the form of incrustations upon the surface of the bladder in various diseases, or in the form of irregular, soft, and more or less white calculi.

Oxalate of lime occasions rounded, hard calculi, of brownish color and of irregular, granular surface, from which they derive the name *mulberry calculi.* They occur in conditions similar to those causing uric-acid stones.

Calculi composed of carbonate of calcium, sulphate of calcium, cystin, xanthin, and indigo are extremely rare.

Results of Urinary Calculi.—While cystitis and retention of urine frequently cause stone, the latter is prone to occasion increased irritation and inflammation, and may cause serious obstruction to the outflow of urine, and thus retention in the bladder. Ulceration may take place, and perforation of the bladder-walls may ensue. Hypertrophy of the walls occurs when the stone only partially obstructs the outflow, and under the same conditions the ureters may become distended and hydronephrosis may occur.

FIG. 293.—Tuft of papilloma of the bladder (thionin; × 90) (Martin and Taylor).

Not rarely the stone lies in a pouched dilatation of the wall of the bladder, either from having been formed in that situation in consequence of stagnation of the urine, or from having caused a dilatation by weakening the walls at a certain point. Complete encapsulation of the stone has been observed in such cases.

TUMORS.

Polypoid outgrowths from the mucosa may be observed in chronic cystitis.

Papillomata occur either as the result of chronic irritation,

or as apparently causeless tumors. The papilloma presents itself as a somewhat cauliflower-like elevation affecting the base, and sometimes considerable portions of the mucosa, and has a whitish or grayish color. It is usually vascular, and therefore frequently occasions hemorrhages.

Microscopically it is composed of a delicate connective-tissue stroma containing large, thin-walled blood-vessels, and covered with cylindrical epithelium (Fig. 293). Occasionally papillomata become transformed into malignant epitheliomatous growths.

Carcinoma is a rare form of primary tumor. It occurs as a somewhat papillomatous thickening of the mucosa, or as a more considerable infiltration of the wall of the bladder (Fig. 294).

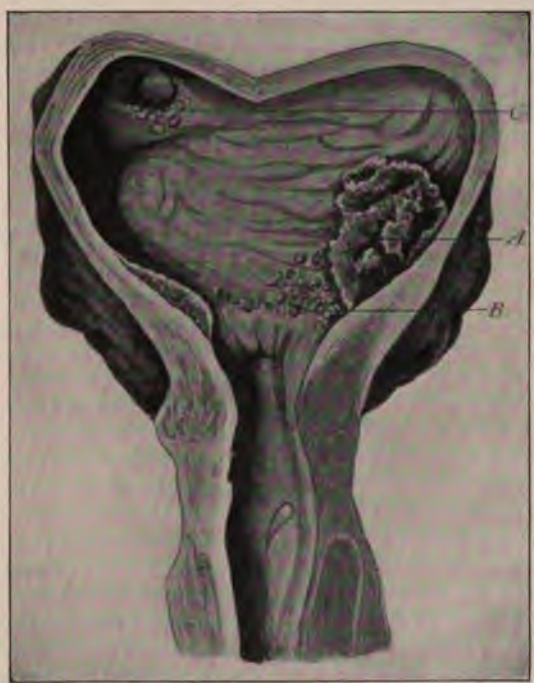

FIG. 294.—*A*, epitheliomatous tumor; *B*, wart-like growths; *C*, villous growths (Clado).

Microscopically it is composed of large polymorphous epithelial cells infiltrating the walls more or less deeply and irregularly, or arranged in acini or alveolar formations.

Secondary carcinoma of the bladder may result from extension of prostatic or uterine cancer. Very rarely the bladder is involved by metastasis.

Fibroma, fibro-adenoma, myoma, and **myxoma** are occa-

sionally observed, and *cysts* may be formed by closure of pouched diverticuli or by distention of the patulous urachus. Cysts of obscure origin are sometimes met with; dermoid cysts are rare. *Sarcoma* is very rare.

ABNORMAL CONDITIONS OF THE URINE.

Quantity.—The normal quantity in the adult is from 1500 to 2000 cc. Conditions which check the perspiration or action of the bowels increase the amount of urine; excessive sweating and diarrhea have the reverse effect. In the latter case the excretion may be almost suppressed (*anuria*). The same may occur in acute nephritis, or chronic nephritis with uremia, in extreme anemia, and in acute or chronic obstructive conditions in the gastro-intestinal tract interfering with absorption of water. Occasionally anuria is reflex, resulting from obstruction of the urinary passages by calculi. The quantity of urine is increased (*polyuria*) in cases of excessive consumption of water, and habitually in diabetes mellitus and insipidus and in chronic interstitial nephritis.

Specific Gravity.—Normally the specific gravity is 1015 to 1020. It becomes increased when the amount of urine is decreased, and *vice versâ*. The specific gravity is especially high in diabetes mellitus, despite the polyuria, sometimes reaching 1040 or 1050. It is low in most forms of chronic nephritis, in diabetes insipidus or simple polyuria, and in anemia and hysteria, or other nervous diseases.

Color.—The normal amber color is due to the presence of various pigments, especially urobilin and uroerythrin. These are derivatives of hemoglobin or bilirubin.

In pathologic conditions other pigments, such as hematoporphyrin, pathologic urobilin, melanin, etc., are met with. Indican is present in the urine in the form of a chromogen, which may sometimes become oxidized, with the formation of dark-colored pigment-animal indigo. Certain drugs eliminated with the urine cause discolorations. Bilirubin occurs in jaundice and other conditions, and blood or hemoglobin may cause discoloration.

Reaction.—The normal reaction is acid, but frequently after meals it becomes neutral or even alkaline. The ingestion of certain foods rich in alkalies or acids, which become converted into alkaline carbonates (citrates, acetates, etc.), may occasion an alkaline reaction, while other acids lead to the opposite result. Decomposition of the urine usually causes an intense alkaline reaction, by conversion of the urea into ammonia. Occasionally the reaction of the urine is amphoteric, both red and blue litmus-paper being acted upon.

Glycosuria is a term applied to the presence of glucose or grape-sugar in the urine. This may be a transient condition in

various diseases, such as chorea, cerebrospinal fever, whooping-cough, and epilepsy, and is not uncommon in gouty persons indulging in a free diet. Sometimes it results from the effects of poisons, such as morphin, chloroform, or carbonic oxid; but in some of these cases the reactions of glucose are simulated by other and quite different reducing-substances present in the urine. Permanent and decided glycosuria is characteristic of diabetes mellitus only.

Levulosuria, the presence of fruit-sugar, **lactosuria,** that of milk-sugar, and **dextrinuria,** that of dextrin in the urine, have been discovered.

Choluria is the name indicating the presence of biliary pigments and acids in the urine. It is most frequently observed in cases of jaundice due to hepatic disease, but may also occur in so-called hematogenous jaundice, the formation of the pigment in some of the latter cases probably taking place in the kidneys themselves. The urine presents a dark color, varying from brownish to greenish. Oxidizing substances, such as fuming nitric acid, produce a play of colors.

Microscopically the cellular constituents of the urine are found stained, and granular concretions of bilirubin or rhombic crystals may be observed. Hyaline casts, more or less deeply stained by the pigment, are frequently seen.

Urobilinuria.—Urobilin occurs in the normal urine mainly as a chromogen, or is converted into urobilin on the addition of acid. Sometimes, urobilin is present in large quantities in the fresh urine. This has been particularly observed in fevers, in jaundice, and in certain anemic diseases, especially in pernicious anemia.

Indicanuria.—Indigo-blue occurs in the urine as a chromogen which gives rise to the formation of indigo on decomposition. This indican, or indoxyl sulphate, is a product of indol derived from the intestine, and an excess of indican in the urine is significant of intestinal decomposition.

Other forms of the ether-sulphuric acid series occur in the urine, but are less significant.

Acetonuria occurs to a slight extent in health, but more particularly in conditions of inanition, in gastro-intestinal disturbances, and in fever. It is especially significant in diabetes mellitus, and may become very pronounced toward the latter end of this affection.

Diaceturia, or the condition in which diacetic acid appears in the urine, is also met with in fevers and inanition, but particularly in diabetes.

Lipaciduria refers to the presence of fatty acids in the urine, but has no special significance.

Hydrothionuria refers to the presence of sulphuretted hydrogen in the urine. This is noted occasionally in autointoxications,

or as the result of fermentative changes in the urine. The urine may have a foamy appearance, to which the term *pneumaturia* is sometimes applied. Other gases may be present, but only in small proportion and rarely.

Melanuria is a term applied to the dark discoloration of the urine occasionally seen in persons suffering from pigmented tumors. It also occurs in phthisis and other wasting diseases. As a rule, the urine becomes darker after addition of oxidizing substances, but it may be quite dark when passed. It contains iron and sulphur.

Albuminuria.—Minute traces of serum-albumin probably occur in the normal urine. The term albuminuria, however, is applied to cases in which albumin is readily detected. It may be accidental—that is, dependent upon the admixture of albuminous substances from the mucous membrane lining the urinary passages, —or essentially renal in character. In the former instances the presence of abundant blood or pus-cells indicates the nature of the case. True renal albuminuria consists of the excretion with the urine of serum-albumin and serum-globulin, the former being considerably more abundant than the latter. Pure serumuria is extremely rare, and pure globulinuria perhaps even more so.

Albuminuria is more frequently the product of actual renal disease or nephritis, and is then due to the disease of the epithelium of the glomeruli and tubules. A certain amount of albumin occurs in degenerative or congested conditions of the kidneys; in various general diseases affecting the blood and without manifest disease of the kidney, such as anemias, diabetes, and the like; in certain nervous affections probably influencing the circulation; and in disorders of the digestive tract.

At times albuminuria is periodic or cyclic, this periodicity depending upon general conditions, such as diet, exposure, and exercise, which in turn affect the blood or renal circulation. Considerable amounts of albumin in the urine are never physiologic.

Large proportions of globulin occur in amyloid disease of the kidneys.

Albumosuria.—Various albuminous substances derived from serum-albumin or serum-globulin, and not coagulable by heat, occur in the urine. These are hydration-products designated albumoses or propepton. True pepton has never been found in the urine. Albumosuria occurs in cases in which pus-cells or large exudates are undergoing absorption, as in septic processes, pneumonia, and the like (*pyogenic albumosuria*). In another group of cases intestinal malassimilation or decomposition comes into play (*enterogenic albumosuria*). In the third group diseases of the blood, such as leukemia and various intoxications, are active (*hematogenic albumosuria*). A fourth, or puerperal, form occurs after labor. It has also been observed repeatedly in malignant tumors of the skeleton.

Nucleo-albuminuria.—Nucleo-albumin, formerly supposed to be mucin, is derived from the protoplasm of the surface-epithelium of the urinary tract, and occurs in the urine in small quantity in nearly all persons, and in large quantity when there is irritation of the lining mucosa, particularly in pyelitis and cystitis.

Fibrinuria occurs in conditions in which lymph or blood gains access to the urinary passages. Fibrinous casts or shreds may be passed, or small flocculent particles are observed. Fibrinuria is usually associated with hematuria or chyluria.

Hematuria is a term applied to the presence of blood in the urine. This may be accidental from admixture of menstrual blood and the like, or may be a pathologic condition, in which the blood originates from the kidneys, ureters, bladder, urethra, or other parts of the urinary system. Renal hematuria may result from intense congestion or from hemorrhagic nephritis. Traumatism, either from without or from calculi in the pelvis, is a frequent cause. Tumors and specific inflammatory processes are occasional causes. Sometimes hematuria is due to intense anemia, hemorrhagic diseases, or severe intoxications. Hematuria which is due to admixture of blood with the urine below the kidney results from traumatism, injury by calculi or catheterization, from vascular tumors, and occasionally from inflammatory or other disease-processes.

Renal hematuria is distinguished from that originating in the bladder by the intimate admixture of urine and blood, and by the associated evidences of renal disease—renal epithelium, tube-casts, etc. Fragmentation of the red corpuscles is said to indicate renal hematuria. In hematuria originating in the bladder larger clots may pass, in association with bladder-epithelium and mucin (nucleo-albumin). In cases of sudden renal hemorrhage large clots, sometimes forming casts of the pelvis, may be formed and discharged.

Hemoglobinuria indicates the presence of free hemoglobin or of methemoglobin in the urine, without the presence of blood-corpuscles. Hemoglobinuria results from causes which lead to disorganization of blood and elimination of the coloring-matter through the kidneys. It is met with in various infectious diseases, such as malaria, and in intoxications, as in poisoning with potassium chlorate, carbolic acid, arsenic, and other drugs, or with toadstools. It occasionally results from snakebite or poisoning by other venomous animals.

Paroxysmal hemoglobinuria is a form of intermittent disease especially frequent in subtropical countries. The attacks sometimes seem to be determined by exposure to cold and other external influences, whilst the predisposition may be dependent upon syphilis or other general disorders. The urine presents a dark-red or brownish color, and when tested with the spectro-

scope shows the bands indicative of hemoglobin or methemoglobin.

Microscopically the hemoglobin may present itself in the form of granules or cast-like formations, or sometimes as crystals. Blood-corpuscles are absent, or at most present in extremely small numbers.

Lipuria.—A small amount of fat may appear in the urine in cases of advanced diffuse nephritis with fatty degeneration, and in certain cases of pyelitis. In other cases lipuria results from disorders in which there is excess of fat in the blood (lipemia). This occurs in cases of excessive consumption of oil or fatty food and in cases of intoxication, notably by arsenic. It is sometimes present in diabetes, phthisis, chronic alcoholism, and obesity, and fractures injuring the marrow, or serious traumatism of the subcutaneous fatty tissues may cause fat-embolism and lipuria.

The appearance of the urine varies with the amount of fat, but, as a rule, there is a solid scum upon the surface, and there may be large oil-drops. Occasionally the urine is quite milky when recently passed. Microscopically, oil-drops are more or less abundant; and fat-crystals may be discovered.

Chyluria is the name applied to a milky condition of the urine which probably results from admixture of lymph or chyle. The urine is light colored, and more or less milky in appearance. Often there is a reddish discoloration from associated hematuria (*hematochyluria*). The urine contains albumin and sometimes albumoses.

Microscopically, numerous oil-drops of varying size and, usually, blood-corpuscles are detected. The most frequent cause is the obstruction of the lymphatic channels and their subsequent rupture in the kidney or bladder in consequence of the lodgement of the Filaria sanguinis hominis. In these cases the embryos of the filariæ are usually detected in the urine. Sometimes a chyluria is non-parasitic, but the causes are obscure.

Bacteriuria.—Normally the urine contains no bacteria. In cases of cystitis or other inflammatory diseases, however, and particularly when catheterization has been practised, bacteria of decomposition may be present, such as the *Micrococcus ureæ*, *Bacterium termo*, the *Bacillus proteus*, yeast-fungi, and other forms. Not rarely the *Bacillus coli communis* is met with, particularly in ascending infections of the urinary tract. In cases of certain infectious diseases, such as typhoid fever, pneumonia, and erysipelas, the specific micro-organisms may be found in the urine, having escaped from the blood through the capillaries of the glomeruli. Streptococci are also met with in primary and secondary infectious nephritis. The *Bacillus tuberculosis* may be discovered in cases of tuberculosis of the kidney, ureters, bladder, or other parts of the urinary tract (Fig. 295). It is frequently present in clusters,

this constituting a marked point of distinction from the smegma-bacillus, which is often found in urine, especially that of women, and is easily mistaken for the tubercle-bacillus. Another point

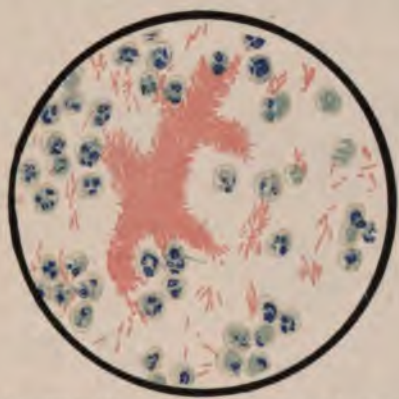

FIG. 295.—Tubercle bacilli in the urine; from a case of tuberculous cystitis (Jakob).

of distinction is the greater ease with which the smegma-bacillus, stained with carbol-fuchsin, may be decolorized by alcohol. Positive differentiation in doubtful cases is made by injection of the urine into guinea-pigs.

CHEMICAL CHANGES AND SEDIMENTS.

The various inorganic and organic constituents of the urine may be present in excessive quantities, and may form deposits, or abnormal chemical substances may be detected.

Uric acid is deposited in the form of yellowish, brownish, or reddish crystals of whetstone shape, or as irregular angular formations superimposed or clustering together (Fig. 296). The color is due to uroerythrin, taken up from the urine. Excess of uric acid occurs in lithemic and gouty conditions, and the crystals may deposit from a highly acid urine, even though there be no excess.

Oxalate of lime occurs in the form of highly refracting octahedral corpuscles, their appearance being likened to that of an envelope (Fig. 297). Certain foods rich in oxalates may cause excessive excretion, and oxaluria occurs as an independent condition of obscure nature allied to gout and lithemia. Oxalates deposit from highly acid urine, even though no excess be present. This must be distinguished from oxaluria proper.

Phosphates.—Various forms of phosphates are found in crystalline form in urinary sediments. Basic phosphate of magnesium and neutral phosphate of lime are found in urine becoming alkaline, while the phosphate of ammonium and magnesium, or

triple phosphate, is met with when alkaline decomposition takes place. It presents itself in different forms, the most characteristic being the large coffin-lid crystals and certain star-shaped formations (Fig. 298). Triple phosphate is especially abundant in cystitis with alkaline decomposition of the urine in the bladder.

FIG. 296.—Various forms of uric-acid crystals.

FIG. 297.—Various forms of crystals of oxalate of calcium.

Urates.—Urates are deposited from acid urines as a whitish or reddish sediment of amorphous character. The reddish color sometimes observed is due to admixture of urinary pigment. In decomposing urine, of somewhat alkaline reaction, urate of ammonium is deposited as hedgehog crystals or masses (Fig. 299).

FIG. 298.—Crystals of triple phosphate (ammonium-magnesium phosphate).

FIG. 299.—Urate of ammonium crystals.

Hippuric acid is rarely met with, excepting after the ingestion of benzoic acid or of certain fruits. It forms long, prismatic crystals, which occur in groups.

Carbonates and **sulphates** are rarely observed in urinary sediments.

Fat-crystals occur in the form of fine needles, or of aggregations arranged in a star-like manner and resembling tyrosin groups (Fig. 300). They are found in cases of chronic nephritis, pyelitis, and cystitis.

Tyrosin.—This substance usually occurs in the urine in solution, or rarely in the form of sheaves composed of fine needles arranged in star-like clusters (Fig. 300).

Leucin occurs as small spheres, often having a somewhat radiated structure within. These are most readily discovered when the urine has been partially evaporated.

Leucin and tyrosin are observed in acute yellow atrophy of the

FIG. 300.—Leucin-spheres and tyrosin-needles.

FIG. 301.—Cholesterin-plates and fat-crystals (needles).

liver, in phosphorus-poisoning, and occasionally in severe infectious fevers.

Cystin occurs in the form of hexagonal plates often superimposed. They are most frequently associated with cystin calculi in the kidney.

Xanthin is extremely rare, but may be associated with xanthin calculus.

Cholesterin appears in the form of flat, quadrilateral plates, with a re-entering angle at one of the corners (Fig. 301). They are met with in old cystitis or pyelitis, but are rare.

Indigo.—Amorphous particles or crystals of indigo may be found in urine containing great excess of indoxyl sulphate. They present a characteristic bluish color.

Bilirubin, hemoglobin, methemoglobin, and **hematoidin** are occasionally seen as brownish granular concretions or in the form of rhombic crystals (see Choluria, Hemoglobinuria).

THE URETHRA.

CONGENITAL ABNORMALITIES.

Absence of the urethra is sometimes met with in association with other defects of development. Partial deficiencies and abnormal structure of the urethra are more frequent. Thus in the female it may be reduced in length and open in the anterior wall of the vagina, and in the male may terminate at the base of the scrotum. Obliteration of part of the urethra (atresia) may occur in cases of defective development of the corpus spongiosum; more commonly there is obliteration of the meatus. Other abnormal conditions will be considered in connection with defective development of the penis.

INFLAMMATIONS.

Inflammation of the urethra, or **urethritis,** is most frequently due to a specific micro-organism—the gonococcus of Neisser. Some cases, however, are non-specific, resulting from irritation by chemical or mechanical agents with associated infection (staphylococci, streptococci, or other organisms). Some of these cases are caused by direct traumatism, as by blows, injuries caused by catheterization, and the like; in other cases foreign bodies, as calculi, become lodged in the urethra and occasion inflammation, or injure the urethra in passing. Urethritis, like inflammations of other mucous membranes, may occur in various infectious diseases, such as typhoid fever, scarlet fever, small-pox, etc. In the female, inflammations of the vagina and vulva frequently extend to the urethra. A form of pseudomembranous urethritis of obscure origin has been observed in a few cases.

Specific urethritis, or *gonorrhea*, is always due to direct infection with the gonococcus (for description of the organism, see Part I.). Certain conditions of the urethra favor infection; thus an adherent prepuce, by causing greater retention of the infective matters, increases the liability, and probably congested and irritated states of the urethral mucosa heighten the susceptibility. The vulnerability of different individuals probably varies; and doubtless the micro-organism has greater virulence in some instances than in others.

Pathologic Anatomy.—Urethritis usually first affects the mucosa at or near the meatus, but tends to spread rapidly to the posterior parts. The mucosa is at first intensely congested, red, and swollen. Soon a purulent exudate, of yellowish or greenish color, makes its appearance. The small crypts or lacunæ swell and become distended with purulent exudate.

Microscopically, urethritis presents the features of an intense purulent catarrh. Within a few days of the onset the superficial epithelium becomes loosened and begins to desquamate;

and at the same time polymorphonuclear leukocytes make their way to the surface between the epithelial cells. The pus-cells and epithelium of the surface-exudate contain gonococci in abundance, and the organisms are discovered in the cells and to a less extent between the cells of the deeper layers of the mucosa (Fig. 302). The process extends most deeply in those parts of the

FIG. 302.—Acute urethritis, showing purulent infiltration and gonococci in the cells and between the cells (Birch-Hirschfeld).

urethra (penile portion) in which the lining epithelium is of the columnar variety.

Associated Lesions.—In simple cases the disease proceeds no further than has been described, but after a period of several weeks gradually subsides. Very frequently, however, the inflammation extends in various directions, and complicating conditions arise. Sometimes the infective agents penetrate the *membrana propria* of the small glands (Littré's glands), or enter the submucosa by direct invasion through the interglandular parts of the mucosa. Leukocytic collections in the submucosa or *periurethral* abscesses may result. In these cases the gonococcus alone may be the infective cause, or other pyogenic organisms may be associated; sometimes periurethral lesions are caused by staphylococci independently of gonococci. Occasionally accumulations of pus in Tyson's glands may simulate periurethral abscesses. In the female similar purulent distention of the glands of Bartholin is a frequent lesion. The inflammation of the urethra is often confined to the anterior portion (*anterior urethritis*), but may extend to the

posterior portion (*posterior urethritis*). In the male, secondary involvement of the prostate gland is likely to occur with posterior urethritis; and, more rarely, the organisms invade the vas deferens and find their way to the epididymis, causing acute *epididymitis.* The bladder is rarely involved, the mucosa apparently offering considerable resistance to the infection. In the female, acute vaginitis, and especially inflammation of the cervix uteri, are commonly associated. Secondary extension to the uterus may occasion gonorrheal endometritis; more frequently the uterus is but little affected, while the Fallopian tubes suffer intense inflammation. Catarrhal or purulent salpingitis, often complicated with local peritonitis, is one of the most important of the complications. When pus from a gonorrheal urethritis is brought in contact with the conjunctiva a severe form of *purulent conjunctivitis* results.

Metastatic lesions are not infrequent. Among these, *gonorrheal arthritis* is the most familiar. It usually occurs late in the disease, sometimes after an interval of weeks or months from the onset, and involves the larger joints (knee, elbow, wrist). Purulent exudation and fibrous anchylosis may result. A similar lesion is *gonorrheal tenosynovitis.* Sometimes the pericardium, endocardium, and myocardium are involved; and, more rarely, the pleura and the membranes of the cord.

Enlargement of the lymphatic glands of the inguinal (*bubo*) region is frequent; sometimes it terminates in suppuration.

Chronic urethritis is usually the result of continuation of the acute form. It may present itself in the form of a chronic catarrhal process, as a hyperplastic inflammation, or as a productive or cicatrizing form.

In the catarrhal form of chronic urethritis the lesion is practically the same as in the acute disease. The epithelium is loosened and more or less desquamated, and sometimes distinct erosions are observed. Definite ulcerations may occur in parts back of strictures. The columnar epithelium may be converted into the squamous form in localized areas or diffusely. The crypts and glands of the mucosa may be distended with desquamated cells and more or less periglandular inflammation may be observed.

In the hyperplastic variety the mucosa is thickened in a papillomatous manner, and diffuse catarrhal inflammation is associated.

The productive or cicatrizing form is the most important. It may be diffuse in character, but is usually localized and leads to stricture-formation.

Stricture of the urethra is most frequent in the membranous portion, but may occur in the anterior parts. Not rarely there are several strictures in the course of the canal. Histologically the stricture is the result of productive inflammation of the mucosa and submucosa. It is therefore a lesion of slow development, and may not become obstructive for months or years after the acute

attack of gonorrhea, to which it owes its origin, has subsided. The lumen of the urethra is encroached upon in limited area or for a considerable distance, and on section the stricture is found to be hard and resisting. When the lumen of the urethra is greatly narrowed the outflow of urine is impeded, and hypertrophy of the walls of the bladder results. Later, dilatation of the bladder, and even of the ureters and pelvis of the kidneys, may result. The urethra back of the stricture frequently presents the lesions of chronic catarrhal or hyperplastic urethritis, the obstruction serving to prolong the original inflammation of these parts. Rupture of the urethra and extravasation of urine into the cellular tissues, with subsequent necrosis and gangrene, may occur.

In chronic urethritis there is usually a constant but slight discharge of mucous exudate (*gleet*). Examination of this may discover no gonococci, or only an occasional group. The urine contains flocculent shreds (clap-threads), which on microscopic examination are found to be granular or homogeneous structures resembling cylindroids, and often covered with pus-cells that have adhered to the surface. The amount of discharge may be quite copious at times, especially in the hyperplastic and catarrhal forms of chronic urethritis.

INJURIES OF THE URETHRA.

The urethra may be injured by traumatism from without or within. In cases of falls with injury of the perineum the membranous portion of the urethra may be seriously lacerated, and in women injuries sustained during labor may cause immediate rupture of the urethra, or may first occasion inflammatory and necrotic changes in the anterior wall of the vagina and secondary perforation of the urethra. Injuries from within the urethra may be due to forced attempts at catheterization when some form of obstruction opposes the passage of the instrument. "False passages" are thus occasioned, and may result in fistulæ and extravasations of urine. Concretions or calculi from the kidney or bladder may lodge in the urethra, and may cause immediate perforation or primary inflammation, with secondary rupture of the walls.

Rupture of the urethra causes extravasation of urine into the periurethral cellular tissues. If the skin is intact and the urine cannot escape, widespread inflammation, necrosis, and gangrene are liable to occur. Fistulous communications may be established with the exterior, or, in women, with the vagina.

INFECTIOUS DISEASES.

Gonorrheal urethritis is the important infectious disease of the urethra. For convenience, it has been described under Inflammations.

Tuberculosis of the vesical end of the urethra may be associated with tuberculosis of the bladder. *Lupus* sometimes involves the meatus and anterior end of the urethra in cases of lupus of the external genitalia of women. Very rarely tuberculosis of papillary form is met with in the urethral mucosa.

Syphilis.—The chancre may occur in anterior parts of the urethra in either sex. It usually undergoes rapid ulceration.

TUMORS.

The urethra of women is more often the seat of tumors than is that of men.

Small polypoid tumors are occasionally seen hanging from the meatus; they may be of cystic character, like the polyps of other mucous membranes.

Carcinoma is usually secondary to cancer of the external genitalia (vulva, vagina, glans penis). Primary carcinoma originating from Cowper's gland has been described, and a few cases of carcinoma of other parts of the urethra have been observed.

Cysts of the mucous membrane, due to retention of the contents of the small glands, are occasionally met with, especially in the posterior portion of the urethra. The inner lining of the cyst is elevated in the form of papillæ covered with squamous epithelium.

Sarcoma of the urethra has been described, but is very rare.

CHAPTER VIII.

DISEASES OF THE REPRODUCTIVE ORGANS.

THE UTERUS.

Development and Anatomy.—The uterus is formed by the fusion of the middle portions of Müller's ducts, the fusion first occurring below where the cervix uteri is developed. The epithelial lining of the ducts gives rise to the mucosa of the uterus, and its outer layers to the muscularis. The utricular glands are developed by ingrowths from the lining cells, and first appear and reach their most complex development in the cervical portion. The outer surface of the cervix (*portio vaginalis*) is lined with stratified squamous epithelium; the cavity of the uterus and cervical canal with cylindrical ciliated cells. In the cervical portion are found numerous racemose glands and between them simple tubular glands; in the corpus uteri the glands are simple tubules.

CONGENITAL ABNORMALITIES.

Absence of the uterus is very rare. The organ, however, may be represented only by a mass of rudimentary tissue. Hypoplasia of the uterus may be a congenital condition, or may be the result of arrested development and the consequent failure to increase in size at the age of functional activity. The term *uterus fœtalis seu infantilis* is applied. Stenosis and atresia of the uterus and vagina may be the result of disease or maldevelopments, due to partial obliteration of Müller's ducts.

Among the more striking malformations of the uterus are those which result from incomplete fusion of Müller's ducts. In nor-

FIG. 303.—Uterus bicornis unicollis (Winckel).

mal development these ducts unite and fuse in the lower portion to form the uterus and vagina, but remain separated above, where they form Fallopian tubes. Among the anomalous conditions of the uterus are *uterus bicornis,* in which the cervical portion of the

FIG. 304.—Uterus septus (Cruveilhier).

uterus is single, or two entirely distinct uterine cornua are present (Fig. 303); *uterus septus,* in which the external appearance may be that of a single uterus, but on section a septum is discovered, which divides the organ into lateral halves (Fig. 304). The term

uterus unicornis is used to designate cases in which but one of Müller's ducts has developed, the other remaining rudimentary. Malformations of the vagina may be associated with those of the uterus already named, though this is rarely the case. A number of subdivisions have been distinguished for each of these malformations, but they are unimportant.

ALTERATIONS OF POSITION.

The normal position of the uterus is one of slight anteversion with anteflexion; that is, the fundus lies a little farther to the front than the cervix, and there is a slight band or flexure in the middle portion.

Anteflexion is a condition in which there is marked angulation of the uterus, the fundus falling forward. Relaxation of the ligaments predisposes to this condition; and it may be caused by the pressure of tumors situated posteriorly, by distention of the rectum with gas, by the traction of adhesions and by abnormal conditions of the uterus itself, causing a loss of tone in the walls. The grade of anteflexion varies greatly. Among the effects of this condition is interference with the discharge of menstrual blood, with consequent accumulation and intense dysmenorrhea.

Anteversion, or the tilting forward of the uterus without abnormal angulation, occurs under similar conditions, but is less important.

Retroflexion of the uterus occurs in cases in which the walls of the uterus are abnormally soft and have lost their tone. It may be caused by the pressure of tumors or the traction of adhesions. Sometimes it is due to habitual constipation, causing pressure of masses in the rectum upon the lower part of the uterus (cervix); retroversion and subsequently retroflexion are produced. Laxness of the vaginal walls and rupture of the perineum may cause this or other abnormal positions of the uterus by depriving the organ of its support from below and subjecting it to the unresisted pressure of the abdominal viscera. The degree of retroflexion varies from slight angulation to a complete backward doubling of the organ. The fundus may undergo considerable congestion from the interference with circulation, and it is not rarely enlarged. Adhesions between the uterus and rectum are frequent.

Lateral displacements of the uterus are rare.

Upward dislocation may be caused by pressure of tumors in the pelvis; it may be due to the traction of adhesions between the uterus and large tumors of the ovary. In such cases the uterus may be greatly stretched and the vagina may be similarly affected.

Prolapse of the uterus is a term applied to descent or downward displacement. It is possible to distinguish any num-

ber of degrees of prolapse, but it is sufficient to speak of two only: *incomplete prolapse*, in which the os uteri is still within the vagina, and *complete prolapse*, in which it projects through the vulva. The causes of prolapse of the uterus are numerous. Injuries to the perineal floor and unusual laxity of the vaginal walls or the ligaments of the uterus are very important. Traumatism and excessive pressure upon the uterus from the abdomen may cause descent of the organ, especially if laxity of the ligaments was present before. Enlargement of the uterus itself may be the cause of prolapse, and in any case the organ usually becomes enlarged after the prolapse, in consequence of passive congestion. The cervix is generally directed somewhat backward, and the mucous membrane frequently presents catarrhal inflammation and contains enlarged veins. The cavity may be filled with considerable mucous secretion.

In some instances of apparent complete prolapse the fundus of the uterus may be but little displaced, the great descent of the os uteri in such instances being due to *hypertrophic elongation of the vaginal portion of the cervix*.

In all cases of prolapse the anterior and posterior walls of the

FIG. 305.—Complete prolapse of the uterus (Penrose).

vagina are displaced downward more or less, and sometimes may be completely everted. The anterior vaginal prolapse may draw with it the posterior wall of the bladder, and *cystocele* results. Similarly the posterior vaginal wall may drag down the anterior wall of the rectum, and *rectocele* is produced (Fig. 305).

Inversion of the uterus is a condition in which the organ is turned inside out to a greater or less extent. This condition is caused by traction upon the placenta during labor, when it is acutely developed; or by the similar traction of polypoid submucous tumors, when it is more slowly formed (Fig. 306). There

FIG. 306.—Fibroid polyp, producing partial inversion of the uterus (Penrose).

may be only a slight inversion of the fundus, or the organ may be completely inverted and may present itself through the vagina and vulva. Secondary changes are apt to occur in such cases. The mucous membrane suffers catarrhal inflammation with ulceration; and the entire uterus, though at first perhaps enlarged by congestion, subsequently atrophies.

STENOSIS, DILATATION, AND RUPTURE.

Stenosis of the uterine cavity may occur as a congenital condition, or may be acquired in cases in which inflammation has led to cicatricial stricture. There may be almost complete obliteration of the external or internal os uteri.

Dilatation of the cavity of the uterus is a not infrequent result of stenosis. The dilated cavity may be filled with mucus or seromucous secretion from the mucous membrane (*hydrometra*), or with accumulations of menstrual blood (*hematometra*). Occasionally in cases of hydrometra secondary decomposition of the liquid causes gas-formation, and *physometra* results. In cases of hematometra the amount of blood in the uterine cavity may be

very considerable, and in some instances rupture of the wall of the uterus is the result. This may be simply due to the increasing pressure, or it may result from inflammation or ulceration at the point of stenosis.

Rupture of the uterus may occur during pregnancy or labor; and occasionally at other times in consequence of inflammations, abscess, softened tumors, and the like. The most frequent and serious consequence of rupture is peritonitis. Occasionally, when rupture has occurred during pregnancy, the fetus may be enclosed in a sac formed by circumscribed peritonitis; the rupture may at the same time heal. Subsequently the fetus may be disorganized and discharge through the abdominal wall. This is a very unusual termination.

Laceration of the cervix uteri is a very common accident of labor.

CIRCULATORY DISTURBANCES.

Hyperemia of the uterus is a physiologic condition during menstruation, and occurs in all forms of acute inflammation of the organ. There is no essential difference between menstrual hyperemia and that of pathologic conditions.

Menstruation.—Examination of the mucous membrane during the period shows swelling of the membrane, with multiplication of the interglandular cells and dilatation of the lymphatic channels. The uterine glands are elongated and the cells more or less swollen. Congestion is always conspicuous, and the superficial epithelial cells are desquamated more or less considerably. In the interval between the periods regeneration of the mucous membrane takes place. The term *dysmenorrhea membranacea* is applied to abnormal menstruation in which membranous formations are discharged from the uterus (Fig. 307) and in which there is severe pain. The membranes consist of intact portions of desquamated cells more or less degenerated. Cases of this character are particularly prone to occur when chronic inflammations of the mucosa have existed, and the affection is then termed *endometritis exfoliativa*.

FIG. 307.—Membrane discharged in membranous dysmenorrhea (Penrose).

Passive hyperemia of the uterus occurs in conditions of general venous stasis, but especially when dislocations of the uterus cause pressure upon the venous plexuses. The organ is enlarged, the veins in the serous surface are prominent, the mucous membrane is dark red, and when the congestion is long continued chronic endometritis may result.

Hemorrhages may occur into the uterine cavity, into the wall of the uterus, or into the peritoneum outside the uterus. Hemorrhages during menstruation and in labor are physiologic forms. Pathologic increase of menstrual hemorrhage is spoken of as *menorrhagia*, which may occur in certain general diseases, such as anemia, or in consequence of local conditions, notably tumors. Intense congestion of the organ from cardiac disease or from malpositions of the uterus may also lead to hemorrhages during the menstrual period. Hemorrhages between the menstrual periods are spoken of as *metrorrhagia*. This may be caused by general conditions, such as the hemorrhagic diseases, and infections (smallpox, etc.); but it is especially frequent as a result of local diseases, of which fibroid tumors are the most important.

Hemorrhages into the substance of the uterus are rare, and are generally due to traumatism.

Hemorrhages into the peritoneal cavities or into the cellular tissues in the vicinity of the uterus are more frequent. Of the intraperitoneal hemorrhages the most frequent is accumulation of blood in Douglas's pouch (*retro-uterine hematocele*). The blood in this case may come from various sources, such as ruptured ovarian follicles, ruptured tubes in tubal pregnancy, hematosalpinx, or rupture of varicose veins in the broad ligament. The blood may become absorbed without causing other pathologic results, or it may set up inflammation and result in adhesions between the uterus and rectum. Not rarely perforation with discharge of the blood through the rectum or vagina occurs.

Hemorrhages into the vesico-uterine pouch and hematoma between the layers of the broad ligament are rare.

INFLAMMATIONS.

Inflammation may affect the mucous membrane of the uterus, when the term *endometritis* is applied, or the wall of the uterus, when it is termed *metritis*. The names *perimetritis*, indicating inflammation of the peritoneal covering of the uterus, and *parametritis*, inflammation of the cellular tissues in the vicinity of the uterus, are unnecessary, as these conditions are simply forms of local peritonitis. For purposes of convenience the inflammations of the uterus occurring during the puerperium will be separately considered. Some of the conditions here described as inflammatory are not positively of such nature, though no sharp line of division can be drawn between the inflammatory and the hyperplastic forms.

Acute catarrhal endometritis may result from traumatism, or from infection with pyogenic organisms or gonococci. Occasionally it occurs as a complication of general infectious diseases, such as typhoid fever and cholera. The mucous mem-

brane is swollen and intensely hyperemic; very often small hemorrhages are observed. Desquamation of the epithelial cells, with mucopurulent secretion, causes considerable discharge. In most cases the body of the uterus is affected, but in the gonorrheal form the cervical portion is the most frequent seat. Very intense forms may occasion necrosis of the epithelial cells and the formation of pseudomembranous deposits. This is particularly frequent in the infectious diseases.

Chronic endometritis may be the continuation of acute endometritis, and is especially apt to occur in persons of reduced vitality, such as scrofulous or chlorotic women, or in those in whom the circulation is sluggish. The influence of passive congestion has already been referred to. Very often the etiology is entirely obscure.

The mucous membrane in the earlier stages is simply swollen, and produces abundant mucopurulent secretion. Later, hyperplastic changes occur, the hyperplasia affecting either the uterine glands or the interstitial tissue. The terms *endometritis glandularis* and *endometritis interstitialis* have been applied to distinguish these varieties. In the former, microscopic examination shows an abundance of proliferated glandular acini extending through the depth of the mucous membrane (Fig. 308). In the latter the

FIG. 308.—Glandular endometritis.

glands are less conspicuous, but round-cell infiltration and abundant connective-tissue hyperplasia between the glands are conspicuous features (Fig. 309). In some of the cases, particularly in those of the glandular form, the process seems more closely allied to tumor-formation than to inflammation; and it is very

difficult to draw a sharp line between some forms of adenoma and sarcoma of the mucous membrane on the one hand, or chronic inflammations on the other hand. The mucous membrane may in

FIG. 309.—Interstitial endometritis.

the advanced stages be considerably swollen and project in a polypoid form (Fig. 310). Later, atrophy may take the place of hypertrophy, and in some instances the lining epithelial cells change

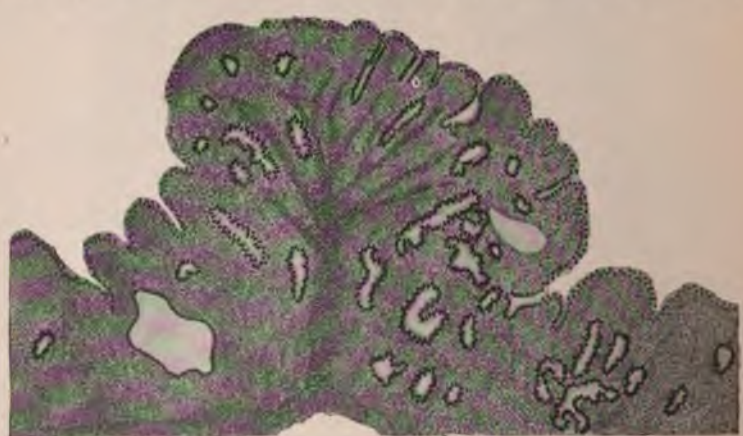

FIG. 310.—Polypoid endometritis (Penrose).

their character from the typical columnar cells to a distinct squamous type. The small glands of the membrane may be obstructed at their mouths and cystic distention may result. This

is particularly conspicuous in the case of the Nabothian glands of the cervix, and retention-cysts of these glands may reach the size of a pea or a small cherry. Occasionally erosions or slight ulcerations are met with in cases of chronic endometritis.

Chronic endometritis of the cervix is frequently secondary to inflammations of the vagina, and may be due to gonorrheal infection or other causes. The mucous membrane of the cervical canal is greatly thickened, and may project from the os uteri (ectropium). Retention-cysts of the Nabothian glands are sometimes a conspicuous feature; and cystic mucous polyps are not unusual.

Chronic endometritis may lead to chronic metritis, or by extension may occasion tubal disease. Clinically it is characterized by more or less constant mucopurulent discharge.

Erosions of the uterus are especially frequent in the cervix; they result from endometritis. The mucosa within the cervical canal undergoes hyperplastic changes and projects from the os uteri in a polypoid form. Between the papillomatous projections cystic formations may develop, and these may rupture, leaving exposed ulcerations. Granulation-tissue is developed from the submucosa, and sometimes this becomes exuberant in character.

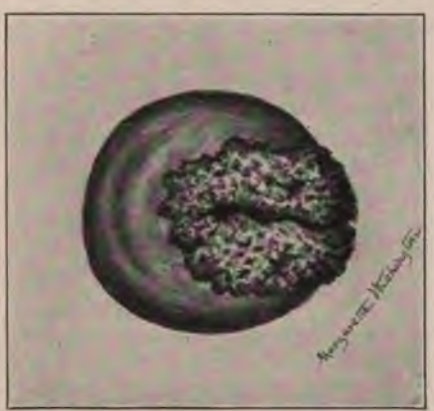

FIG. 311.—Left lateral laceration of the cervix, with erosion (Penrose).

Other erosions are due to laceration of the cervix (Fig. 311); and occasionally congenital erosion has been observed.

Phagedenic ulceration of the cervix has been described as an independent disease. Some of the cases are undoubtedly instances of ulcerating carcinoma; in other cases ulcerations in this situation have been met with in which microscopic examination showed no evidence of carcinomatous tissue.

Acute metritis is rarely met with, except during the puerperium, but may be the result of acute endometritis. The wall

of the uterus becomes thickened, soft, and edematous. Occasionally purulent infiltration is observed.

Chronic metritis frequently occurs in the puerperium as a result of retarded involution of the uterus. It may be occasioned by chronic congestion of the uterus, or may be secondary to chronic endometritis. The uterine wall is infiltrated with round cells, and the connective tissues undergo active hyperplasia, which in the later stages leads to great thickening and induration. Coincidently there is usually some hypertrophy of the muscular elements themselves. It is by no means certain that all of the cases grouped under this term are inflammatory in nature. Some are certainly more closely allied with diffuse tumor-formation. The mucous membrane is usually thickened, and becomes secondarily involved if it was not primarily diseased. The peritoneal covering may be similarly affected, and chronic perimetritis with adhesions of the uterus results.

INFECTIOUS DISEASES.

Puerperal Infections.—This term may be applied to various forms of infection occurring during the puerperium, but in the majority of instances the streptococcus is the specific organism.

Etiology.—Two important factors are concerned: (*a*) injuries to the surface of the uterus, vagina, or vulva; and (*b*) some form of infection. The more or less denuded surface of the uterus offers a ready entrance to micro-organisms, as well as an absorptive surface for soluble poisons produced by micro-organismal decomposition within the uterus; and infection may take place without any further injury than that occasioned by the normal processes of labor. In most instances, however, there is actual injury either of the surface of the uterus, cervix, vagina, or vulva, and the micro-organisms or poisons are admitted through these wounds. There may be primarily, however, more than a simple injury of the mucous surface. In consequence of prolonged pressure necrotic lesions terminating in gangrene may first be established, and from this secondary infections may take place. In cases in which infection occurs without injury to the walls, as well as in cases in which injury has been sustained, the pathogenic organisms may first find a lodgement and multiply within the blood-clots or retained secundines within the uterus; and the organisms or their toxic products are secondarily admitted to the uterine tissues.

Puerperal infection is probably in most cases the result of the entrance of micro-organisms from without, and may be traced to want of cleanliness on the part of the accoucheur or the surroundings. Sometimes widespread epidemics have been caused by the carelessness of a single obstetrician, whose hands perhaps had be-

come infected from operating upon or examining cases of erysipelas, general pyemia, or the like.

Among the micro-organisms, as has already been stated, the Streptococcus pyogenes is most important. Staphylococci of various sorts, bacilli resembling the Bacillus coli communis, the bacillus of tetanus, gonococci, and other organisms occasionally infect the puerperal uterus, but in these instances the pathologic conditions are different from those met with in ordinary puerperal infection, which may be considered as practically always a streptococcic infection.

Pathologic Anatomy.—In most instances there is primarily a lesion upon the mucous surface of either the uterus, the vagina, or the vulva. The nature and extent of this depend upon the amount of injury occasioned during labor. In some instances the lesion is trivial in extent, and remains so, though widespread infection results from it. In most cases, however, there is a rapidly spreading inflammation of the endometrium or mucosa of the vagina, and pseudomembranous deposits are very frequently met with upon the surface. Necrotic and gangrenous changes in the mucous membrane are most pronounced in cases in which prolonged pressure has been exerted by the head in its descent or by instruments.

The extension of the infection may occur in two ways, either through the blood-vessels or through the lymphatic channels; and the local and general lesions vary correspondingly.

In cases in which the infection spreads along the blood-vessels there may be primarily septic softening of the thrombi within the uterus and purulent phlebitis of the venous channels at the placental site. Thrombosis extends from this situation through the veins to the various plexuses in the vicinity, and infected emboli are carried through the circulation to distant organs, such as the lungs, the kidneys, and the spleen. Metastatic abscesses and inflammatory swelling of the affected organs result. The kidneys in particular are often the seat of numerous punctate or miliary abscesses.

In the cases in which extension occurs along the lymphatic channels the uterus is enlarged, soft, and often pultaceous. Streaks or lines of light color may be observed running from the mucous surface toward the periphery. These represent the lymphatic vessels filled with purulent exudate. The walls of the lymphatics may be penetrated, and perilymphangitic abscesses are thus occasioned. When the process has extended to the lymphatics in the outer layers of the uterus phlegmonous inflammation of the subperitoneal tissues (parametritis) results, and finally the peritoneum itself may be involved.

The spleen is enlarged, though less decidedly than in the form in which infection occurs through the blood-vessels.

Extension along the mucous membrane itself may lead to asso-

ciated disease of the tubes; more frequently the tubes are invaded at their abdominal end after peritonitis has developed.

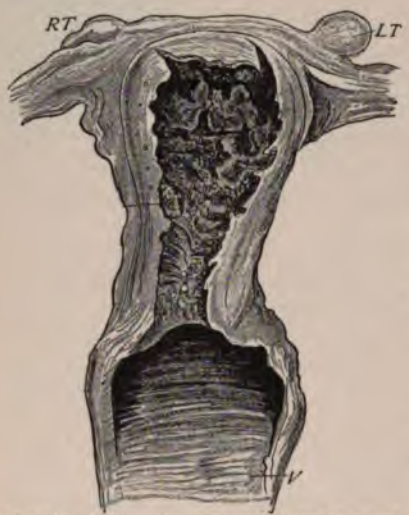

FIG. 312.—Diffuse tuberculosis (ulcerative and caseous) of the endometrium (Kaufmann).

Puerperal sepsis is peculiarly virulent and rapid in its course, and may occasion widespread changes in all of the tissues of the body.

Tuberculosis.—Tuberculosis of the uterus is most frequently met with in the mucous membrane, and is usually secondary to disease of the tubes. Direct infection may possibly occur through coitus; but is certainly rare. The disease occurs in the form of a nodular or diffuse infiltration with a tendency to rapid ulceration or caseous necrosis involving the mucous membrane and to some extent the submucosa. The entire cavity of the uterus may be covered with caseous and necrotic deposits

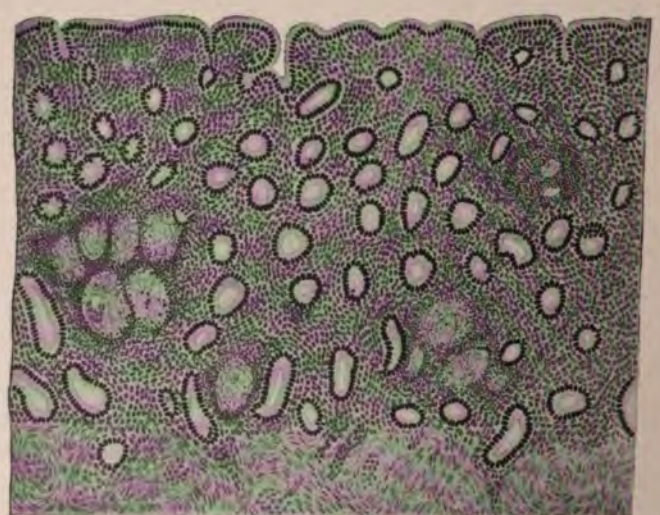

FIG. 313.—Miliary tuberculosis of the endometrium and glandular endometritis (Beyea).

(Fig. 312). In the later stages the process may extend deeply, even involving the muscular layer of the organ. The cervix

is rarely attacked. Sometimes miliary tubercles are found in the uterine mucosa without marked degeneration (Fig. 313).

Syphilis of the cervix uteri may occur in the form of a chancer, or as tertiary infiltration.

ATROPHY AND DEGENERATIONS.

Puerperal Atrophy.—The uterus suffers a most remarkable atrophy following labor. This proceeds very rapidly at first, and then more slowly; and under favorable conditions the organ resumes its previous condition in the course of a few months. The muscular fibers decrease progressively, from their previous hypertrophied condition, in which they frequently attain a length and diameter three times the normal, until, at the end of involution, the usual size and appearances are attained. Many muscle-fibers undoubtedly are destroyed. The process of involution is really one of fatty degeneration.

Senile Atrophy.—The uterus undergoes progressive atrophy at and after the period of the menopause, and finally becomes greatly reduced in size. The substance of the organ may undergo a progressive sclerosis, or in other instances becomes softer than normal. Catarrhal endometritis is often associated, and the columnar cells are sometimes converted into squamous epithelium.

Fatty degeneration, independent of that which occurs during puerperal involution, is a rare condition, but may occur in the course of certain infectious diseases, such as typhoid fever, or may result from the action of the parenchyma-poisons.

Amyloid degeneration is rare and unimportant.

HYPERTROPHY AND HYPERPLASIA.

Hypertrophy of the entire uterus may occur in association with inflammation or metritis, or may result from chronic congestion of the organ. The enlargement in cases usually designated as hypertrophied is, for the most part, due to new-formed connective tissue. True hypertrophy occurs as a physiologic process during pregnancy. In this variety the muscle-fibers increase enormously in size, and doubtless also multiply their number. The blood-vessels and connective tissues undergo corresponding hypertrophy.

Hypertrophy of the cervix uteri is occasionally met with independent of hypertrophy of the uterus as a whole. It may be caused by chronic irritations of the cervix, as in cervical endometritis, or may result from obscure causes. Frequently it is met with in prolapse of the uterus, and sometimes it may cause a simulation of prolapse.

Hyperplasia of the mucous membrane of the uterus has been referred to in the discussion of chronic endometritis. In

some instances that are designated as endometritis the pathologic process seems to be rather of a purely hyperplastic character, and more closely allied to tumor-formation than to ordinary inflammation. In these cases the mucous membrane in all parts of the uterus may be greatly thickened, and may suffer more or less papillomatous transformation. Sometimes limited portions are affected, and polypoid formations result.

Polyps of the uterus may be of various sorts. Very commonly they present themselves as simple mucous polyps, due to projection of parts of the mucous membrane; in other cases secondary changes, such as cavernous dilatation of the blood-vessels or cystic transformation of the small glands contained in the polyp, occasion marked variations from the original appearances. Myofibromata, sarcomata, and other forms of tumors originating in the mucous membrane or just beneath it may assume a polypoid appearance.

TUMORS.

Leiomyoma; Myofibroma; Fibroid.—The tumors of the uterus designated by these terms are in nearly all cases composed of smooth muscle-fibers and fibrous tissue; and from the pathologic standpoint the term myofibroma is therefore most applicable. They present themselves in the form of rounded and usually well-circumscribed masses, from the size of a grape-seed to that of tumors weighing forty or fifty pounds. They are generally multiple; are very hard; and on section have the appearance of concentric or irregular lamellæ. Microscopically the tumor is composed of smooth muscle-fibers and of fibrous tissue arranged in bundles or layers running in various directions. The muscle-fibers are frequently found arranged concentrically about small blood-vessels, and in some instances the vessels are telangiectatic.

Secondary changes are very common, the most frequent being calcification. This may begin either in the center or at the periphery, but more commonly it is diffuse. Edema of the tumor may cause it to become quite soft, and cystic transformations due to softening or to distention of the lymphatic spaces are sometimes observed.

Several varieties have been distinguished, according to the seat of the tumors. In some instances they are embedded in the wall of the uterus, when the term *interstitial* or *mural fibroids* is applied (Fig. 314). In other cases they arise in the uterine walls just beneath the mucous membrane, when they are called *submucous fibroids.* These may gradually project into the cavity of the uterus as *fibroid* polyps. In the third group of cases the tumors have a *subperitoneal* location, and may project from the outer surface of the uterus as knobbed masses (Fig. 315), which may become pedunculated. In rare instances they extend between the layers of the broad liga-

ment. Fibroid tumors are benign in a pathologic sense, but occasion serious disturbances either by pressure or by the metrorrhagia

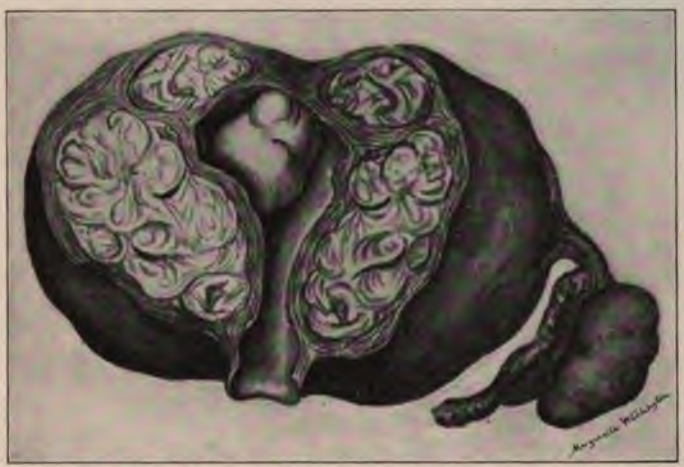

FIG. 314.—Interstitial fibroid tumor of the uterus: a small submucous fibroid appears in the uterine cavity (Penrose).

and endometritis to which they frequently give rise. Subperitoneal fibroids may become free bodies in the peritoneal cavity, and the

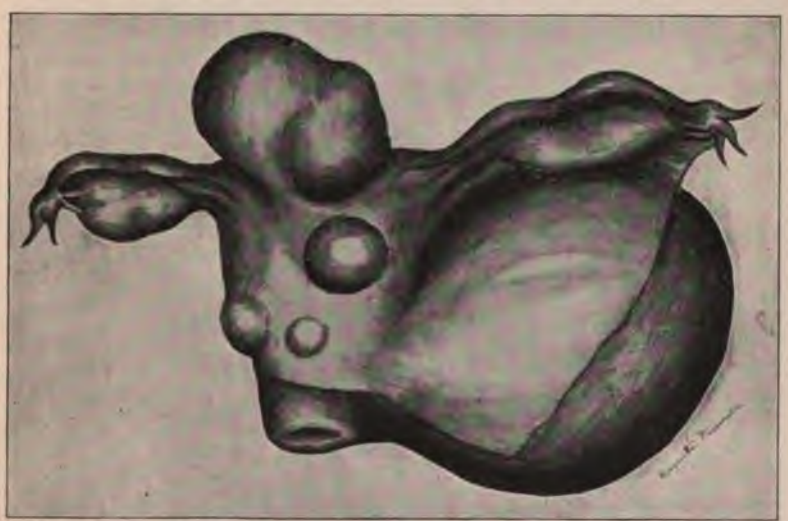

FIG. 315.—Subperitoneal fibroids and an intraligamentous fibroid of the uterus (Penrose).

submucous form is sometimes discharged from the uterus after a spurious labor.

Sarcoma of the uterus may arise from the muscular layer or from the endometrium. That arising from the myometrium is usually associated with myoma and fibroma. In some cases the sarcomatous elements of the tumor are developed in a pre-existing myofibroma. In other cases the sarcoma and fibroma are coincidentally formed. These tumors differ from typical fibroids in being more rapid in growth, less well circumscribed, softer, and more homogeneous in appearance. Sometimes they are situated just beneath the endometrium, and become converted into *sarcomatous polyps.*

Sarcoma of the endometrium may occur in a circumscribed or papillomatous and in a diffuse form, the latter involving the entire mucous membrane of the organ. The papillomatous variety is soft and villous and highly vascular. In some cases the structure is that of angiosarcoma. In the diffuse form the entire cavity of the uterus may be filled with soft villous projections from the mucous membrane.

A special form of sarcoma has been described as occurring in the vaginal portion and cervix. In this the tumor has a grape-like structure, and microscopically consists of myxomatous tissue with areas of sarcomatous character. It occurs in young persons, even in childhood.

Adenoma.—Adenoma may occur in the form of polypoid outgrowths from the mucous membrane, or as a diffuse process not readily distinguishable from that commonly designated as endometritis glandularis. Both of these forms are benign.

Malignant adenoma usually arises from the corpus uteri, and presents itself as a soft, irregular elevation of the mucous membrane in a localized area, or diffusely involving a large part of the endometrium. It tends to spread through the walls of the uterus, invading the myometrium (Fig. 316) and finally penetrating to the peritoneal covering, where secondary nodules may develop. Histologically it is characterized by the production of atypical branched gland-acini with comparatively little stroma, the latter being of soft fibrous character. The tumor is malignant in its tendency to invade the wall of the uterus and neighboring structures, and it may become converted into actual carcinoma in the later stages. In such instances the acini in places show a heaping of epithelial cells and a tendency to destruction of the basement-membrane, with proliferation of the cells in the stroma.

Carcinoma.—Carcinoma is the most frequent of the malignant diseases of the uterus, and usually invades the cervical portion; more rarely it arises from the corpus uteri. Carcinomata starting on the vaginal surface of the cervix are squamous-celled epitheliomata; those originating in the cervical canal and in the corpus uteri are tubular or glandular carcinomata.

Carcinoma of the portio vaginalis usually begins from the

inner surface of one of the lips of the os uteri, and causes a firm infiltration of the affected portion, the disease penetrating into the

FIG. 316.—Malignant adenoma: the section is taken from the deeper parts of the tumor, and shows the invasion of the myometrium.

submucosa and muscularis. Subsequently ulceration takes place, and the diseased area becomes converted into an elevated and

FIG. 317.—Diffuse cancer of the endometrium (Penrose).

irregularly ulcerated surface. Extension may take place to the vaginal walls and to the tissues surrounding the cervix uteri.

Ulceration may establish communications between the vagina and bladder or rectum. Extension upward into the supravaginal portions of the cervix and to the corpus uteri may occur through the lymphatic channels, or by direct invasion. Secondary involvement of the lymphatic glands of the iliac, lumbar, and inguinal groups is frequent.

Instead of the usual indurated and ulcerating form, cervical epithelioma may present itself as a cauliflower-growth—that is, as a destructive or malignant papilloma. In such cases it is likely that the growth often begins as a papilloma, causing irregular elevations, and that the penetration into the tissue at the base of the growth is a secondary development. In the later stages this form, like the preceding, undergoes ulceration. Both varieties, but particularly the latter, frequently cause uterine hemorrhages.

Carcinoma of the corpus uteri and of the cervical canal develops from the tubular and acinous glands of the mucous membrane. It may begin as an adenomatous growth, subsequently becoming transformed into carcinoma. Macroscopically the growth presents itself as a villous or papillomatous thickening of the mucosa, either localized or diffuse (Figs. 317 and 318). In

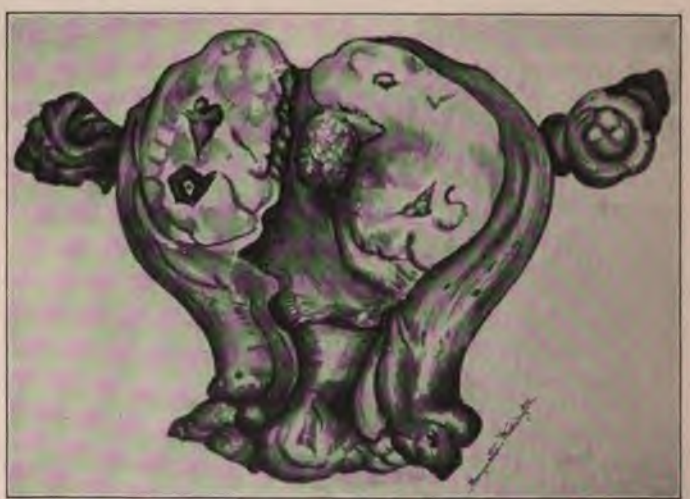

FIG. 318.—Cancer of the body of the uterus: a large, single cancerous nodule in the anterior wall has been divided (Penrose).

the later stages considerable involvement of the wall of the uterus occurs, and even perforation may take place. Microscopically the usual appearances of glandular cancer or adenocarcinoma are discovered (Fig. 319).

Squamous epithelioma is met with in rare instances in the corpus uteri, especially in women of advanced years. The ex-

planation of this growth is that it arises from epithelium that has undergone a change from the customary columnar to the squamous form, in consequence of chronic endometritis.

FIG. 319.—Glandular cancer of the cervix uteri.

Cysts.—Small cysts of the wall of the uterus may be associated with various forms of tumors, such as myofibromata; and a form of adenocystoma, probably originating from remnants of the Wolffian duct, has been described. Dermoid cysts have been occasionally observed.

PARASITES.

Echinococcus-cysts are sometimes met with, and a few cases of supposed Cysticercus cellulosæ have been described, though the nature of the formations was uncertain.

THE OVARIES.

Development and Anatomic Considerations.—The ovary and testis are developed from a primary indifferent sexual gland, which is indistinguishable in the two sexes. This indifferent gland is formed on the ventro-mesial surface of the Wolffian body by a localized thickening of the mesothelial elements. The ovarian stroma is subsequently formed by ingrowths of the surrounding mesoderm. The ovary consists of a stroma of peculiar spindle-shaped connective-tissue cells. In the central or medullary portion the tissue is highly vascular; the peripheral or cortical part contains abundant Graafian follicles in which the ova are de-

veloped. These follicles are formed from primary tubular indentations of the cuboidal or columnar epithelium that covers the organ. These indentations are the tubes of Pflüger. After full development of the ovary they are wanting, the greater part by constriction of the deeper portions having formed Graafian follicles. The *paroöphoron* a vestigial structure, is the part of the ovary at the hilum. It consists of connective tissue and blood-vessels with a number of parallel tubes which are remnants of the Wolffian body. The same tubules surrounded by connective tissue extend outward between the layers of the broad ligament, constituting the *parovarium*. Sometimes part of the Wolffian duct remains patulous and constitutes the duct of Gärtner. This is the homologue of the vas deferens.

CONGENITAL ABNORMALITIES.

Occasional *absence* of one or both ovaries has been discovered with other developmental defects, or independently. *Hypoplasia* occurs in chlorosis, and occasionally in association with other conditions. Sometimes *supernumerary* ovaries have been found. The additional ovaries may be formed by division or by separation from one of the normal glands.

CHANGES IN POSITION.

More or less extensive dislocations of the ovaries may occur, the most notable being that in which one of these organs descends into a hernial sac, occupying either the inguinal or crural canal. Dislocations resulting from pressure, adhesions, and the like are frequent.

CIRCULATORY DISTURBANCES.

Active hyperemia, or **congestion,** may be either a physiologic or pathologic condition. The former occurs during the menstrual period, the latter in association with inflammation of the neighboring structures or in the earlier periods of inflammation of the ovaries themselves.

Passive congestion is met with in chronic cardiac diseases, and as a result of local obstructions to the circulation by tumors, inflammatory adhesions, and the like.

Hemorrhage.—Small hemorrhages into the ovarian tissue are very frequent. Their occurrence is usually sufficiently accounted for when the functional activity of the organ is considered. At each periodical ovulation a small follicle ruptures, to discharge the contents containing the ovum. Generally there is a slight extravasation of blood at such times, which is subsequently absorbed. At the same time that the extravasation and absorption are taking place the inner lining of the follicle proliferates somewhat, and

the cells then undergo fatty degeneration. The whole process gives rise to a yellowish nodular formation, termed the *corpus luteum*. Subsequently this is removed by absorption of the blood and by degeneration and absorption of the proliferated cells of the lining membrane, and a small scar alone remains. The latter, especially when more than usually fibrous, is known as the *corpus fibrosum*. This is commonly a little pigmented, in consequence of the pre-existing extravasation of blood. The corpus luteum, which is developed from a follicle formed at the time of impregnation (corpus luteum of pregnancy), differs somewhat in character. The epithelial proliferation is much more active, and the wall of the follicle is intensely congested. Rapid involution does not take place, the follicle often persisting for considerable periods after the termination of pregnancy.

Exceptionally, considerable hemorrhages may take place into the follicles, and small hemorrhagic cysts or cysts containing blood-stained liquid may be formed.

INFLAMMATION.

Inflammation of the ovaries, or **oöphoritis,** is generally a secondary condition resulting from an extension of inflammation from the neighboring reflections of the peritoneum, or from extension of infective processes along the Fallopian tube. The extension from the neighboring peritoneum, as well as from the uterus, may be direct—that is, along the planes of tissue or through the lymphatic or vascular channels. Primary oöphoritis is probably very rare.

The ovary becomes enlarged, and in the earlier stages is more or less congested. Later the tissues become yellowish, either uniformly or in scattered areas. Finally the process may terminate in necrosis or abscess-formation. Such ovarian abscesses may reach a considerable size, and break into any of the hollow viscera near by or into the peritoneal cavity. In more favorable cases there are only small collections of pus, and these may subsequently become inspissated. The most satisfactory of all terminations is in complete resolution, or in induration (*chronic oöphoritis*).

Localized inflammations may sometimes occur about the follicles. These may terminate in follicular abscesses, which either discharge and lead to scar-formation, or become inspissated.

INFECTIOUS DISEASES.

Tuberculosis.—Among the infectious diseases tuberculosis alone is of importance. It may arise as a primary disease of the ovaries, but much more frequently is secondary to inflammation

of the tubes or other parts of the genital tract. It may give rise to the formation of small or large cheesy masses, showing a tendency to softening with formation of tuberculous abscesses. The ovaries may occasionally be the seat of miliary tuberculosis.

TUMORS.

The ovaries are frequent seats of tumors, both benign and malignant. By far the largest proportion are cystic.

Connective-tissue Tumors.—*Fibroma* may occur as small nodular growths, either single or multiple. In some cases the tumors are of considerable size. Combinations of fibroma with leiomyoma may also be met with; these *myofibromata* resemble those of the uterus. Occasionally *fibrosarcoma* is encountered.

Chondroma is a rare form of benign tumor.

Sarcoma may occur in the form of spindle-celled sarcoma, fibrosarcoma, or more rarely as round-cell sarcoma. It appears as rounded tumors with more or less pronounced encapsulation. Degenerations, such as myxomatous, are not infrequent, and cystic change may be occasioned by dilatation of the follicles. In some cases proliferations of the walls of the follicles constitute an important part of the growth. To such cases the name adenosarcoma may be applied. Angiosarcomata and endotheliomata have occasionally been described.

Cystic Tumors.—Of the cystic conditions of the ovary we must distinguish the *simple follicular cysts* and the more important *myxoid* or *colloid cystomata* and *dermoid cysts*. Of the cystomata there are two varieties—the papillary and the glandular.

Follicular cysts are developed by distention of the Graäfian follicles with dropsical liquid. The ovary may be considerably enlarged by cystic cavities, lined with epithelium and containing clear watery liquid, or occasionally blood-tinged contents. Cysts of this character are very common in cases of induration of the ovary following oöphoritis.

Colloid or Myxoid Cystomata.—Colloid or myxoid cystomata present themselves as tumors of small or large size, having a tendency to a multilocular cystic character. The cavities are filled with a more or less gelatinous or mucoid liquid. Sometimes hemorrhage takes place, and the contents are correspondingly altered. Two subvarieties may be distinguished: the glandular and the papillary.

Glandular cystomata are distinguished by the constant proliferation of the epithelial elements in the form of acini. This occasions a multilocular character, new cysts springing from the walls of the original cavity or appearing within the substance of the primary tumor. The terms *adenocystoma* and *cysto-adenoma* are appropriate. The tumor may present itself as a large, single,

rounded, cyst with insignificant projections of small cysts upon the inner lining; while in other cases there is found on section a uniform multilocular character. Microscopically the characteristic feature of these tumors is the formation of regular gland-acini, showing a single layer of epithelial cells, or at most a few layers resting upon a basement-membrane. The stroma of the tumor is composed of fibrous connective tissue, with some unstriped muscle-fibers. The contents of the cysts have the mucoid or colloid character referred to, and chemically a substance is discovered that is absent from simple follicular cysts of the ovary and is less abundant in papillary cystomata. This substance is termed pseudomucin or paralbumin, and is somewhat related to mucin. Occasionally, when the cysts are old the contents may be quite watery.

Cystomata soon destroy the ovary, the unaffected ovarian tissue being spread out within the wall of the cyst. The tumor is attached in the pelvis by a pedicle consisting of the broad ligament and Fallopian tube, and often forms secondary inflammatory adhesions to adjacent parts.

Glandular cystomata arise either from embryonal rests (Pflüger's tubes), or from ingrowths of the surface-epithelium of the organ. It is generally considered unlikely that they arise from Graafian follicles.

Papillary Cystomata.—Papillary cysts occur in two forms, the one closely resembling glandular cystoma in its general appearance, the other presenting itself as a papillomatous condition of the surface of the ovary. In the former, or papillary myxoid cystomata, large cystic tumors are developed. On section through these there is found a papillomatous or cystic proliferation of the lining membrane, but the tendency to the formation of secondary cysts is much less pronounced than in the glandular varieties, and the fibrous stroma is less abundant. The secondary cysts in this variety may be formed by fusion of the free ends of proliferating papillæ, or by myxomatous degenerations within the stroma of the papillæ. The liquid of the cysts resembles that of the glandular form, but contains less pseudomucin, and is more frequently hemorrhagic. On microscopic examination it is found that the inner lining of the cyst and the papillary projections consist of stratified ciliated epithelium. Calcareous bodies arranged in a concentric fashion (psammoma-bodies) are frequently met with in the stroma, as well as in the epithelium. The same calcareous bodies are occasionally found in glandular cystomata.

The papillomatous ovarian tumors differ from the glandular in being almost invariably bilateral (Fig. 320). Their origin has not as yet been certainly determined, but it is probable that they originate from the paroöphoron, a vestigial remnant of the parovarium. Some have held that they may originate from the Graafian follicles,

or from ingrowths of the surface-epithelium. This is assuredly not a frequent origin.

The surface-papillomata of the ovary present themselves as irregular masses of a cauliflower appearance. The papillæ of projections are covered with ciliated epithelium, as in the cystic form. There is no essential difference in structure, and it is probable

FIG. 320.—Double papillomatous cyst of the ovary: the right cyst has ruptured and is turned inside out, showing a mass of papillomata; papillomata have penetrated the wall of the cyst; the peritoneum has been infected, and a papillomatous growth appears on the fundus uteri (Penrose).

that in most instances the superficial forms result from a rupture of the cystic variety and the subsequent external proliferation.

The papillomatous cystomata and the surface-papillomata have a marked tendency to carcinomatous transformation, and tend to spread to the peritoneum, causing metastatic nodules in the vicinity or throughout the entire abdomen.

Dermoid Cysts.—Dermoid cysts are frequently met with in the ovary. They may occur as small nodules or as very large tumors, and are usually unilateral. The larger ones substitute the ovarian tissue completely; less commonly they may be pedunculated, the ovary in part remaining intact. Combinations with glandular cystomata are not infrequent.

The dermoid cyst is a smooth-walled sac, the inner surface presenting somewhat irregular projections and having more or less pronounced characteristics of epidermal tissue. The cystic contents are a putty-like material of grayish color, containing long, blonde hairs and teeth, and sometimes ill-developed bone. The grayish material consists of fatty detritus containing degenerated epithelial cells, and usually abundant cholesterin-crystals. The wall of the dermoid cyst, though usually in the main composed of epidermal structure, may contain elements of the three blastodermic layers. The dermoid cyst may occur in childhood, or even in fetal life, but usually does not present itself till adult years.

The nature of the tumor has not been certainly determined,

but it is quite evident that it represents an attempt at the formation of an organism. It has, therefore, been designated by some as a *fœtus in fœtu.* Others have looked upon it as the result of a form of parthogenesis.

Secondary changes not infrequently occur. Inflammatory conditions of the walls may occasion abscess. Sometimes the epithelium proliferates actively, and the dermoid, in part or as a whole, is converted into a carcinoma.

Carcinoma.—Carcinoma of the ovary may be a primary growth of glandular character developing from the follicles, or it may be of a mucous or colloid variety, when the ovarian tissue becomes converted into a gelatinous mass. In the latter case the tumor tends to spread to the adjacent peritoneum, and widespread metastasis along this membrane may occur.

CYSTS OF THE PAROVARIUM.

Cysts of the parovarium may be considered in this place on account of their clinical resemblance to ovarian cystomata (Fig. 321). They are distinguished, however, by their intraligamentous

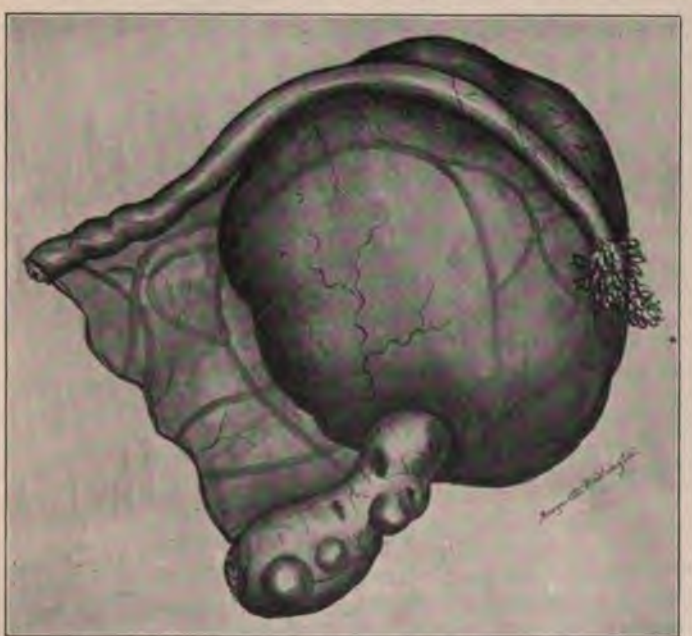

FIG. 321.—Cyst of the parovarium: there is no distortion of the ovary; the Fallopian tube has been much elongated.

situation, by their almost invariably unilocular character, and usually by their clearer and more serous liquid contents. The

ovary is usually uninjured. The inner lining consists of ciliated epithelium.

CYSTS OF KOBELT.

These are thin-walled, pedunculated cysts about the size of a pea (Fig. 322). They are frequently met with, and are seated at

FIG. 322.—Fallopian tube, ovary, and parovarium: *a*, hydatid of Morgagni; *b*, cyst of Kobelt's tube; *c*, Gärtner's duct.

the side of the ovary. The wall is fibrous, the lining membrane composed of cubical epithelium, and the contents a clear serous liquid. The cyst results from distention of one of Kobelt's tubes in the parovarium.

THE FALLOPIAN TUBES.

Development and Anatomy.—The tubes are formed from the upper ends of Müller's ducts. The lower ends of the ducts fuse to form the uterus and vagina. Each tube is covered by a peritoneal coat, and its walls consist mainly of longitudinal and circular muscle-fibers. The mucosa is thrown into well-marked longitudinal plications, which at the uterine end are further complicated by secondary elevations. The epithelial lining consists of columnar ciliated cells.

CONGENITAL ABNORMALITIES.

The tubes may be absent or may be defective. Congenital atresia is occasionally observed. The tubes may be unusual in length and may communicate with the uterus in abnormal situations.

CHANGES OF POSITION.

In dislocations of the ovaries the tubes are correspondingly dislocated. Independent of displacements of the ovary, the tubes

may be distorted or pulled out of their usual position by inflammatory adhesions, and may thus be bent at sharp angles or bound down in various malpositions.

STENOSIS.

Congenital stenosis of the tubes, or complete closure of the lumen, may affect the entire length of the tube or a limited portion, principally near the middle. Acquired stenosis may result from pre-existing disease of the tube itself, or from adhesions secondary to localized peritonitis. The most frequent situation in these instances is the abdominal or fimbriated end. A narrowing of the lumen of the tube may be occasioned by angulation or by dislocations.

DILATATION.

Dilatation on the proximal side of obstructions or stenosis is frequent. The dilatation is more marked when inflammatory conditions of the mucous membrane are present. The abdominal end of the tube may enlarge so as to form a cyst of considerable size, filled with serous or seromucous liquid, when the middle portion is stenotic. When the lower end is obstructed the entire tube becomes dilated, and it frequently shows a tortuous and irregularly pouched condition, due to its attachments to the broad ligament. In such instances the mucous membrane is pushed inward at the bends, and projects prominently into the lumen of the tube. Secondary changes of the epithelial lining are not unusual in consequence of the irritation of the retained secretions. The normal epithelium may be wholly lost, and the lining may consist of squamous epithelial cells. Purely inflammatory dilatations will be referred to below.

CIRCULATORY DISTURBANCES.

Active hyperemia of the mucous membrane may be a part of acute inflammations of the tubes, and is very frequently found at the fimbriated extremity in association with peritonitis. The mucous membrane is swollen and bright red in color. There may be excess of mucous secretion.

Passive hyperemia occurs in conditions in which the general venous circulation in the abdomen is impeded.

Hemorrhages into the tubes may occur physiologically during the menstrual period, and sometimes considerable amounts of blood are found under these circumstances. Small hemorrhages into mucous membranes may occur in association with inflammations of the tubes and in the course of some of the infectious diseases.

Hematoma of the tube, or the collection of blood in the tube, results from stenosis of the lower end with accumulation

of the menstrual discharges in the proximal portions. The blood may remain in a more or less natural condition for a long time, or may undergo secondary changes. Sometimes it discharges through the abdominal end of the tube into the peritoneal cavity, and leads to retro-uterine hematocele.

INFLAMMATIONS.

Inflammation of the tubes, or salpingitis, may be acute or chronic.

Acute salpingitis presents itself in several forms, such as an acute catarrhal and a suppurative form. In most cases the inflam-

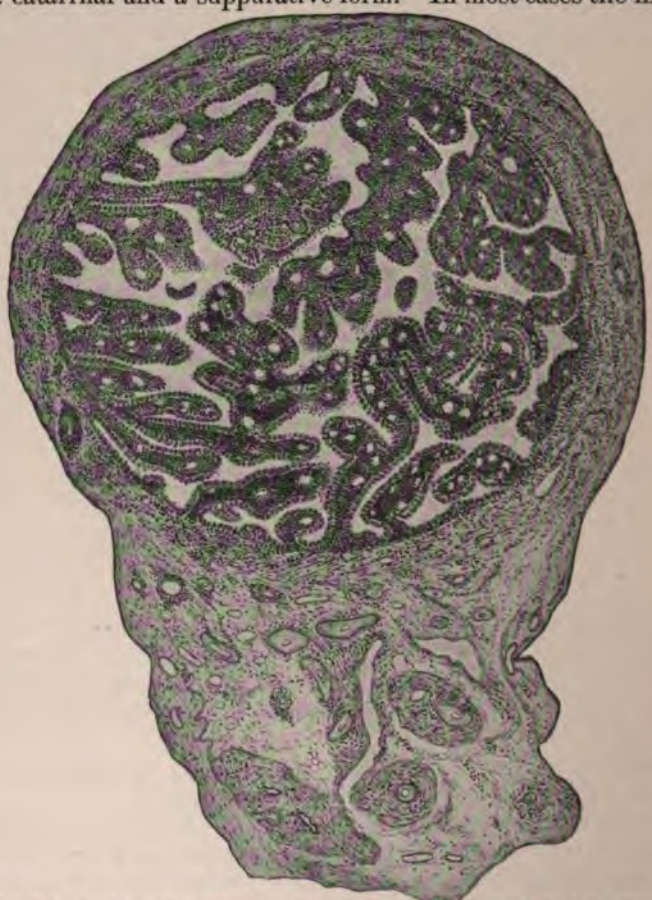

FIG. 323.—Acute septic salpingitis: section about the middle of the tube (Beyea).

mation results from the entrance of irritants from the uterus, and the tubal disease is secondary, therefore, to endometritis or to other

disease of the uterus. Among the micro-organisms discovered, streptococci, staphylococci, the gonococcus, the Diplococcus pneumoniæ, and the Bacillus coli communis may be mentioned. The infective organisms may extend directly along the mucous membrane, or more rarely may reach the tubes through the lymphatics. In rare instances salpingitis may be secondary to local peritonitis.

Pathologic Anatomy.—In acute catarrhal salpingitis the mucous membrane is swollen, hyperemic, infiltrated with round cells, and covered with more or less abundant mucous secretion, which may distend the tube considerably. In the later stages the secretion is

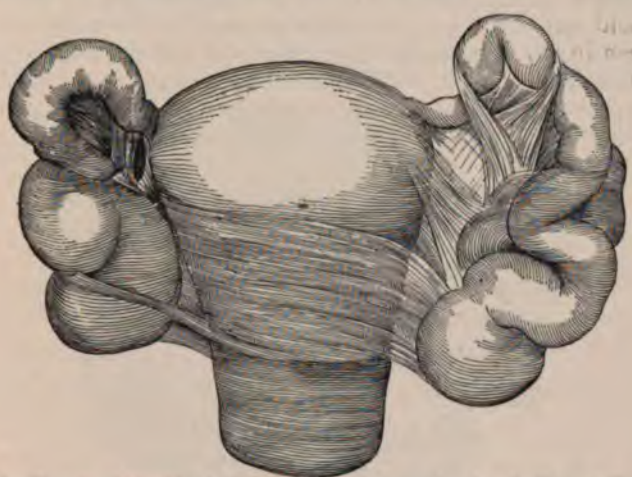

FIG. 324.—Chronic salpingitis: both Fallopian tubes are closed and adherent (Penrose).

apt to become mucopurulent. Interstitial inflammation, with thickening of all of the layers of the tube-wall, is frequently a secondary result. In acute suppurative salpingitis the walls of the tube are infiltrated with round cells (Fig. 323), the mucous surface may discharge abundant pus, and the tubes may become distended with this exudate if the abdominal and uterine ends are closed by the inflammatory process. This result, however, is less frequent than in the case of chronic salpingitis. The mucous membrane in these cases is intensely inflamed and often slightly ulcerated upon the surface. Sometimes the distention is so great that the tubes are converted into pus-sacs the size of an egg or a small lemon. In case of acute suppurative or necrotic salpingitis secondary to puerperal sepsis the mucous membrane may be covered with a necrotic membrane; the term *diphtheritic salpingitis* has sometimes been applied to such a condition.

The exudates within the tube may remain for a long time without change, or may undergo gradual inspissation, and sometimes

even calcification occurs. When ulcers of the mucous membranes have formed, rupture of the tube and consecutive peritonitis may occur, especially during straining efforts, as in labor. Acute local or general peritonitis more frequently results from discharge of infective matter from the abdominal end of the tube.

Microscopically, in all forms of salpingitis extensive round-cell infiltration is observed in all of the layers of the tubes.

Chronic salpingitis, as a rule, results from the continuation of an acute form. The wall of the tube becomes thickened and the muscular layer is often hyperplastic. Proliferative changes in the mucous membrane are not unusual, and may lead to actual polypoid outgrowths. Occasionally small follicular formations are seen in the mucosa; but ulcerations of the mucous membrane are infrequent. When the inflammation extends to the serous coat inflammatory adhesions are frequently formed (Fig. 324), and may bind the tube firmly to adjacent parts and occasion great conges-

FIG. 325.—Hydrosalpinx, showing complete inversion of the fimbriæ (Penrose).

tion or distortion. Very often the abdominal end of the tube becomes occluded by inflammatory adhesions, or by inversion and agglutination of the fimbriæ. At the same time the swelling of the mucosa obstructs the uterine end, and in consequence the tube becomes a closed pouch which fills with pus (*pyosalpinx*), seropurulent liquid (*hydrosalpinx*) (Fig. 325), or hemorrhagic fluid (*hematosalpinx*). Intercurrent acute salpingitis frequently takes place in cases of chronic tubal disease.

INFECTIOUS DISEASES.

Tuberculosis of the tubes may be either primary or secondary, and is probably much more frequent than has been supposed. Secondary tuberculosis may occur in the miliary form in association with tuberculosis of the peritoneum or with general tubercu-

losis. In other cases secondary tuberculosis leads to caseous and fibrous changes in the walls of the tubes. The latter become greatly thickened, and microscopically there is found a diffuse cellular infiltration with scattered giant cells and here and there definite tubercles. The fibrous changes progress more slowly, and may eventually become the conspicuous feature. Primary tuberculous salpingitis is similar in its appearance to the form just described. The infection may occur through entrance of the organisms at the uterine end of the tube, and certain observations would indicate that pre-existing gonorrheal salpingitis predisposes to secondary tuberculous infection. There are usually considerable adhesions of the tubes to the neighboring organs, and particularly to the ovary, and secondary miliary tuberculosis of the peritoneum

FIG. 326.—Tuberculosis of the Fallopian tubes. The disease has extended to the peritoneum, which is covered with tubercles (Penrose).

is frequently observed (Fig. 326). The lumen of the tube is filled with purulent liquid, and sometimes certain portions, particularly the abdominal end, may be greatly distended, forming cysts containing puriform liquid.

Syphilis has been observed in the form of gummata, and also in the form of diffuse sclerosis, in cases of congenital origin.

TUMORS.

Fibromata and **fibromyomata** are met with in the external walls of the tubes as nodular masses. They frequently undergo secondary calcification. **Lipoma** occurs in the external coat lying between the layers of the broad ligament.

Papillomatous elevations of the mucous membrane are quite frequent, and in some cases a transformation of papilloma to carcinoma takes place. Probably most instances of **primary**

carcinoma of the Fallopian tubes have this origin. **Secondary carcinoma** may result from extension of uterine cancer.

Sarcoma occurs in various forms, and **syncytioma malignum** may affect the tubes after tubal pregnancy.

Cysts of the tubes are usually the result of localized distentions of the lumen in consequence of obstructions. Small cystic formations of obscure origin are sometimes found in the peritoneal covering of the tubes and along the attachment of the broad ligament. Their contents may be colloid or serous.

The *hydatids of Morgagni* are small cystic formations about the size of a pea, hanging by a long pedicle at the fimbriated end of the tube. They are probably the result of distention of the closed end of Müller's canal.

Tubo-ovarian cysts are formed by distention of the abdominal end of the tubes when the fimbriated extremities are attached to the ovary, or in other cases may be the result of rupture of follicular cysts of the ovaries themselves into the abdominal end of the tubes.

EXTRA-UTERINE PREGNANCY.

Etiology.—Any obstruction to the downward migration of the ovum may lead to its retention and development in abnormal situations. The actual cause is usually difficult to determine. Impregnation possibly frequently takes place in the Fallopian tube; but unless some obstruction arrests the passage of the ovum into the uterus, normal uterine gestation takes place. Swelling or rapid decidua-formation of the mucosa of the tubes may be one of the causes, and chronic salpingitis, by causing destruction of the cilia of the epithelial cells, and thickening and adhesions of the walls of the tubes, acts in a similar manner. Any other form of obstruction, as by tumors or external compression, may be included among the etiologic factors.

Varieties and Pathologic Anatomy.—All cases of extra-uterine pregnancy are probably in the beginning tubal pregnancies. This condition may occur in any part of the tube. It is rarely found at the uterine end, but may occur there in that part of the tube which is embedded in the wall of the uterus. The term *interstitial pregnancy* is applied to this form.

Tubal Pregnancy.—The changes which occur in the tube are analogous to those met with in the uterus. The same forms of membranes and deciduæ are developed, and a placenta develops, as in the uterus. The muscularis of the tube may hypertrophy somewhat; but in the end the increasing size of the contained ovum leads to thinning and stretching of the walls of the tube. It is an interesting fact that the mucous membrane of the uterus forms a decidua of more or less complete development in cases of extra-uterine pregnancy (Fig. 327).

Among the terminations of tubal pregnancy are the following:

1. The tube may rupture into the broad ligament, into the peritoneal cavity, or, in cases of interstitial pregnancy, into the uterus. As a result of these accidents hematoma of the broad ligament, hematocele, and local or general peritonitis may occur,

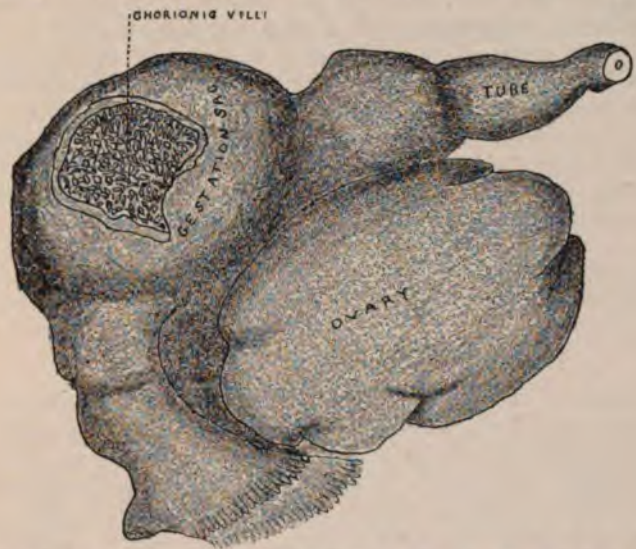

FIG. 327.—Tubal pregnancy, removed before rupture. The opening that has been cut in the tube shows the chorionic villi (Penrose).

or sudden death may take place as a direct result of the hemorrhage. Sudden death from collapse is more frequently due to this cause than has generally been supposed.

2. The ovum may be destroyed in the tube and the gestation cease. In this case the fetus subsequently undergoes various changes. More or less degeneration usually occurs, and shapeless masses or adipocere may result. In other cases calcification of the remnants of the disorganized fetus leads to the formation of a *lithopedion*. This may take place within the tube, or after rupture of the tube and enclosure of the fetus in a sac formed by circumscribing peritonitis.

3. Premature discharge of the ovum (*tubal abortion*) may occur, and the gestation may terminate without serious results. In other cases, however, it leads to a discharge of the blood through the unclosed abdominal ostium of the tube into the peritoneal cavity; and hematocele, peritonitis, or sudden death from hemorrhage may occur.

4. In very exceptional cases tubal pregnancy goes on to full term without rupture of the tube. Spurious labor may then

come on, the fetus, as a rule, perishing. The liquor amnii is absorbed, and degenerative changes leading to mummification, or the formation of adipocere or of a lithopedion, take place. The mummified fetus may remain for many years. Very rarely after spurious labor the fetus is discharged into the peritoneal cavity, and may be delivered through the rectum or in other ways.

Abdominal Pregnancy.—This term is given to cases in which the tube has ruptured and the ovum, enclosed in its membranes, escapes into some part of the abdominal cavity, where it remains free or surrounded by adhesions the result of peritonitis. The placenta, as a rule, remains in the tube; but it may also establish secondary attachments to parts of the peritoneum. Primary abdominal pregnancy—that is, impregnation and gestation in the abdominal cavity—does not seem ever to occur.

THE VAGINA.

PROLAPSE OF THE VAGINAL WALLS.

Prolapse of the anterior or posterior wall of the vagina may be due to abnormal relaxation of the tissues, or it may be secondary to prolapse of the uterus and similar conditions that press the vaginal walls downward. Not infrequently the posterior wall of the bladder is dragged downward with the anterior wall of the vagina, and *vaginal cystocele* results. Similarly the anterior wall of the rectum may be carried downward with the posterior wall of the vagina; this is termed *vaginal rectocele.*

STENOSIS OF THE VAGINA.

Congenital stenosis is rare. More frequently the lumen of the vagina is narrowed by contraction of cicatricial tissues formed in inflammatory diseases of the walls, or by adhesion of the opposite surfaces following ulcerations. Complete occlusion may occur in the latter form of cases, especially in old women.

WOUNDS AND FISTULÆ.

Injuries to the vaginal walls may be caused by the insertion of sharp bodies or instruments, or by coitus. Much more frequently injuries are due to stretching or pressure during labor. Superficial lacerations caused by overdistention are frequent, but more extensive injuries may be caused by prolonged pressure of the infant's head or by instruments used in delivery. In such cases infection and phlegmonous inflammation are prone to occur, and vesico-vaginal, urethro-vaginal, or recto-vaginal fistulæ are sometimes the result. The urine or feces may be discharged

through the vagina, and often cause secondary inflammations of the entire vaginal mucosa.

Similar fistulæ may be due to ulcerative processes of other kinds, to necrosis of carcinomata of the vagina, or to diseases of the bladder or rectum.

CIRCULATORY DISTURBANCES.

Active hyperemia occurs in the early stages of inflammation. The mucous membrane is light red in color and a little swollen.

Passive hyperemia is frequent in pregnancy; and occurs in consequence of pressure due to other causes, such as uterine tumors and the like. The mucosa becomes swollen and edematous, and may be moist from increased secretions.

Hemorrhages into the vaginal walls are most frequently due to traumatism. Inflammation and ulceration may result from the hemorrhagic extravasation.

INFLAMMATIONS.

Acute Catarrhal Inflammation, Vaginitis, or **Colpitis.**—This condition is frequently due to gonorrheal infection, but may result from other causes, such as mechanical and chemical irritants, or in young girls from the invasion of the Oxyuris vermicularis from the rectum. The mucous membrane is usually deeply congested, and the surface is covered with mucopurulent exudate. In gonorrheal cases the cervix uteri and urethra are, as a rule, coincidently affected.

Exfoliative Vaginitis.—In rare cases of intense catarrhal vaginitis, in which the deeper layers of the mucosa are principally involved, membranous formations, consisting of parts of the superficial epithelial layers, may be discharged.

Pseudomembranous vaginitis may occur in association with various infectious diseases, such as pneumonia, pyemia, cholera, etc.; but it is more frequently the result of pressure-necrosis and infection occurring during labor, and is one of the lesions of puerperal sepsis. The surface of the vagina is more or less extensively covered with a dirty and exfoliating pseudomembrane. After discharge of the latter ulcerations are often formed. Extensive necrosis of the vaginal walls may occasion great destruction, and in some instances phlegmonous inflammations of the perivaginal tissues may cause separation of the mucosa.

Chronic catarrhal vaginitis may be the continuation of an acute inflammation, or may occur in a gradual manner in women reduced in vitality. The mucosa usually presents appearances somewhat like those of acute cases, though the congestion is less

marked. Abundant mucopurulent or mucous discharge (leucorrhea) may be present. Erosions of superficial epithelium and enlargements of the lymphoid follicles are sometimes observed. In long-standing cases the surface may be smooth and the entire mucosa somewhat indurated.

INFECTIOUS DISEASES.

Tuberculosis may occur in the form of ulcers associated with uterine tuberculosis, or in the form of lupus from extension of the latter from the vulva.

Syphilis.—Chancers may occur in any part of the vagina, and circumscribed (gummatous) or diffuse infiltrations have been described.

TUMORS.

Fibroma and **myofibroma** may arise in the muscular layer of the vaginal wall, and may project as nodular masses or assume a polypoid form.

Sarcoma may occur as a circumscribed mass, but more commonly as diffuse infiltration which tends to ulcerate.

Papillomata are not infrequent, in the form of small warts or as considerably elevated condylomata.

Carcinoma of the vagina is most frequently secondary to cervical cancer. Similarly it may follow cancer of the vulva. Primary carcinoma of the vagina is rare. It occurs in the form of a circumscribed villous projection.

Cysts of the vaginal walls vary in size and number. Frequently they are multiple, and the size ranges from scarcely discoverable cavities to those the size of an egg. The contents are usually serous and colorless, or less frequently of brownish color. In some instances a flat epithelial lining has been discovered. The origin of these cysts is probably variable. Some seem to arise from remnants of the lower end of the Wolffian duct; others are probably lymphangiectatic. The multiple small cysts sometimes occurring in pregnancy are due to follicular distentions, or to small hemorrhages with subsequent cystic change.

THE DECIDUA, PLACENTA, AND FETAL MEMBRANES.

Anatomic Considerations.—The fetus is enclosed within a delicate fibrous membrane, the *amnion*, and this is covered with a second membrane, the *chorion*. After the deposit of the ovum in the uterus the mucous membrane of the latter undergoes a form of hyperplasia, in which the uterine glands and the blood-vessels take part conspicuously, and thus the organ becomes lined with a thickened mucosa. The latter is termed the *decidua vera*. A

reflection from this covers the fetus enclosed in its membranes, the reflection being known as the *decidua reflexa*. At about the fifth month of development the decidua reflexa and the decidua vera unite and fuse. The portion of the decidua vera at which the placenta is subsequently located is termed the *decidua serotina*. In this portion the vascular system is particularly marked, and is composed of large venous sinuses with thin walls. The fetal chorion carries on its outer surface numerous small projections, or villi. In the region of the decidua serotina these villi undergo marked hyperplasia and bury themselves between the venous sinuses of the decidua. At the junction of the villi and the decidua two layers of cells are developed. The first, immediately covering the villi, consists of cubical epithelial cells (Langhan's cells). Outside of these, and uniting the villi with the maternal tissue, is a layer of clear protoplasmic material containing large nuclei. This has the appearance of nucleated protoplasm, rather than that of collections of cells of definite outline. This protoplasmic layer, *syncytium*, is probably, like Langhan's cells, derived from the covering of the chorionic villi though some authorities contend that it is maternal in origin.

ABNORMALITIES OF DEVELOPMENT.

The Placenta.—Abnormal smallness of the placenta, or hypoplasia, and abnormal largeness are occasionally observed. More frequently an adventitious placenta (*placenta succenturiata*) may be attached to the main placenta, or may lie near it. Abnormal location of the placenta at or near the neck of the uterus (*placenta prævia*) is an important condition, from its liability to cause hemorrhage and miscarriage.

The Umbilical Cord.—Occasionally the cord is divided near its placental end into two or more branches. The placenta may be correspondingly divided, or single. The attachment to the placenta may be marginal instead of central, and sometimes the blood-vessels spread out into a broad marginal attachment, with absence of their gelatinous covering. The latter is termed *velamentous insertion*.

Abnormalities of the blood-vessels, such as branching, a single artery, two veins, etc., are unimportant.

Twists and knots of the cord are frequent, and may strangulate the cord and stop the circulation, causing death of the fetus.

Thickening of the intima of the umbilical vein and of the adventitia of the arteries is probably syphilitic in nature.

CIRCULATORY DISTURBANCES.

Hydrorrhœa gravidarum is a condition in which abundant serous or somewhat turbid liquid is secreted from the deciduæ.

The condition occurs in women suffering from general anemia, but is probably due to local conditions within the uterus. Abortion or miscarriage is not unusual.

Hemorrhages from the decidua or into the decidua and placenta are not infrequent. Hemorrhages from the surface may be due to preceding decidual disease, or may be obscure in origin. Large hemorrhages may cause rapid discharge of the uterine contents. In cases of that abnormal position of the placenta called placenta prævia hemorrhages are frequent.

Fleshy moles is the term used to designate formations in the deciduæ and placenta resulting from gradual hemorrhage and destruction of the ovum. The hemorrhage takes place in the decidua, and then extends between the chorionic villi into the fetal membranes, which may be more or less extensively torn apart. Irregular masses of clotted blood attached to the placental site and to the chorion are discovered. The amniotic cavity contains viscid fluid and the ovum is more or less completely disorganized. Sometimes no recognizable remnants can be found. The moles may be retained a long time, and may undergo secondary calcareous infiltration. Usually they are soon discharged.

Placental Infarcts.—This term is applied to light-colored, more or less indurated areas met with in the placenta, deciduæ, and sometimes in the chorion. The nature of these formations is still somewhat uncertain. They are composed of fibrin, of reticulated or granular character, with occasional areas of softening and hemorrhagic accumulations, and are not rarely surrounded by a zone of cellular infiltration. Some of these "white infarcts" may be only an exaggeration of the normal coagulation-necrosis occurring toward the end of pregnancy. When they are extensive it is very probable that they represent results of disturbances of circulation caused by thickening of the walls of the blood-vessels.

INFLAMMATION.

Inflammations of the placenta (*placentitis*), of the chorion villi, or of the decidua (*endometritis decidualis*) may occur in association with preceding diseases of the uterus, and especially in cases of syphilis of the mother or fetus. The inflammation takes the form of cellular infiltration and induration. This may begin in the decidua and extend to the placenta, and may be of a diffuse or circumscribed character. The villi of the placenta may be greatly compressed by the inflammatory tissue, and may suffer fatty degeneration and atrophy. In other cases the inflammatory changes are most pronounced in the walls of the blood-vessels and around the vessels of the chorion and umbilical cord. Nodular thickening or diffuse induration results, the latter especially in cases in which coincident involvement of the chorionic villi has occurred.

Diffuse hyperplasia of the decidua is sometimes described as *endometritis decidualis.* The inflammatory nature of such cases, however, is uncertain.

INFECTIOUS DISEASES.

Tuberculosis of the placenta was suspected as a possible condition long before positive demonstrations were made. In recent years, however, a number of undoubted cases have been described. Macroscopically there may be but little change in the appearance of the affected parts.

Small tubercles, containing abundant giant cells and tubercle bacilli, first appear in the decidua scrotina, and later invade the placental and chorionic tissues between the villi. The epithelial covering of the villi undergoes hyperplasia, forming collections of large cells. In the later stages of the process caseous necrosis of the tubercular structures takes place, and the villi themselves suffer invasion and degeneration. Their blood-vessels are frequently occluded by hyaline thrombosis and proliferation of the endothelial lining. Tubercle bacilli have been demonstrated in the vessels of the fetal side of the placenta, though less frequently and abundantly than in the maternal vessels.

Syphilis of the placenta may take the form of a diffuse hyperplasia, or of a nodular or gummatous process. The placenta is enlarged, indurated, and heavy; it is light colored in localized areas or diffusely. Microscopically, cellular proliferation springing from the adventitia of the blood-vessels is the characteristic feature. The epithelial cells covering the villi may proliferate, and fatty degeneration of the body of the villi is not infrequent. The chorion and amnion may be diffusely thickened. The syphilitic nature of cases conforming with the above description is often doubtful, as is also the nature of some of the cases of placentitis that are often described as syphilitic.

HYPERPLASIA.

Occasionally diffuse or circumscribed thickening of the deciduæ occurs in association with chronic metritis; the term *endometritis decidualis* is applied to this condition (see Inflammation).

Placental Polyps.—Portions of the decidua, and especially the placenta, retained in the uterus, may remain firmly attached and may undergo subsequent proliferative change, forming polypoid tumors of adenomatous structure. These are particularly frequent after abortion.

Destructive Placental Polyps.—Like the preceding, these originate in retained portions of the placenta, but differ in the more active proliferative changes that take place. On the uterine surface they are covered with fibrin and blood-clots, and at their

attachments are composed of variously formed cells, including large epithelium-like cells enclosed in a vascular stroma. The growth may involve the uterine tissues to a considerable extent. Its nature is obscure in some particulars, but resembles that of the syncytioma.

Hydatid moles present themselves as rounded, rather translucent bodies hanging by their pedicles to the outer surface of the chorion, and often attached one to another in clusters, resembling a bunch of grapes. Microscopically they are found to be composed of myxomatous or more or less edematous fibrous tissue containing few cells and free nuclei, and covered in the outer surface by epithelial cells (Fig. 328). The nature of the hydatid mole has been

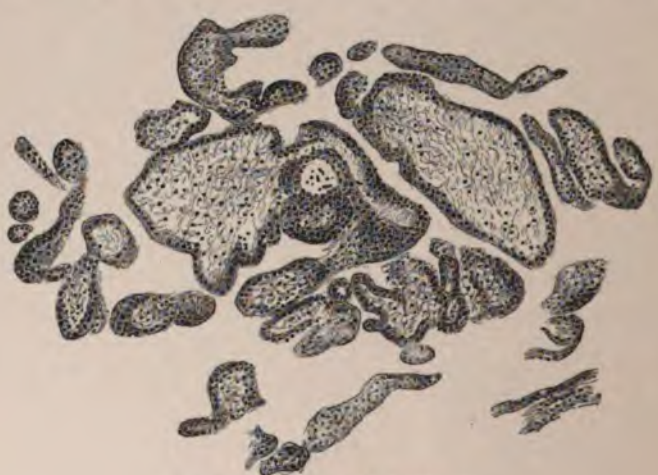

FIG. 328.—Section of a hydatid mole.

the subject of some controversy. Virchow taught that they are simply myxomatous hypertrophied chorionic villi. More recent investigators have found evidences of active hyperplasia of the superficial epithelium of the chorion villi, with secondary degeneration, edema, and necrosis. This accounts for the fact that sometimes the moles extend deeply into the decidua, and even into or through the muscular wall of the uterus.

Hydatid moles are especially met with in women suffering from chronic constitutional diseases (nephritis, anemia) and in those becoming pregnant late in life. Endometritis seems to bear some relation, though the disease is evidently one of the fetal rather than maternal tissues. This is shown by the limited extent of the disease in some cases, and by the fact that in twin pregnancy the membranes of only one of the fetuses may be affected. When the disease is extensive death of the fetus usually results, and the

moles are discharged in the form above described, or enclosed in clotted blood.

Syncytioma Malignum.—The nature and peculiarities of this condition have been sufficiently described (see page 155).

THE VULVA.

WOUNDS.

Injuries of the vulva frequently occur during labor. Laceration of the fourchette is very common, and in a considerable proportion of cases more extensive tears extending into the perineal body, and sometimes through this into the rectum, are observed. Prolonged pressure and contusion during labor may occasion hemorrhages into the tissues of the vulva.

CIRCULATORY DISTURBANCES.

Active hyperemia is met with in acute inflammations.

Passive hyperemia and **edema** occur in conditions in which there is general venous stasis, as in cardiac or pulmonary diseases. They are also met with in pregnancy. The vulva is dark red in color, sometimes cyanotic; the subcutaneous and submucous tissues become edematous, and in consequence the labia majora may swell enormously.

Hematoma of the vulva is caused by compression and contusion of the vulva during parturition, or less frequently at other times. Varicosity of the veins is a predisposing cause of importance. Considerable masses of blood ("thrombi") accumulate in the submucous tissues of the vulva and vagina. These may be subsequently absorbed, or they may discharge through the skin in consequence of superficial ulcerations and ruptures. Infection of the thrombus may cause abscess of the labia or other affected parts.

INFLAMMATION.

Acute catarrhal inflammation results from the same causes as occasion acute vaginitis. The pathologic appearances are, in general, the same, though edematous swelling is likely to be more marked. Distention of the glands of Bartholin and secondary abscess-formation in these glands are common conditions in gonorrheal vulvitis.

Chronic inflammation sometimes follows acute vulvitis. Considerable hyperplasia of the mucosa is sometimes the result. Erosions and ulcerations are less frequent.

Phlegmonous inflammation, or **abscess,** of the submucous tissue of the labia majora sometimes results from exten-

sion of a similar process in the adjacent parts, or may be the direct result of injuries and hematoma, with secondary infection.

INFECTIOUS DISEASES.

Diphtheria sometimes attacks the vulva, especially in puerperal women. The pathologic conditions are similar to those observed in other mucous membranes.

Tuberculosis may occur in the form of lupus. The lesions are irregular ulcers with elevated edges and more or less necrotic bases.

Syphilis.—Chancers are met with on the sides of the labia and elsewhere.

Chancroids occur in the same situations as chancers. Very often opposite sides of the vulva are involved by attrition.

Gangrene of the vulva may be the consequence of severe contusions or inflammations occurring in the course of various infectious diseases.

TUMORS.

Fibroma, fibromyxoma, and **myofibroma** are occasionally met with as nodular tumors or polyps arising from the labia majora. **Lipoma** and **sarcoma** may present a similar macroscopic appearance. All of these growths are rare.

Elephantiasis vulvæ is a not infrequent affection, especially in eastern and tropical countries. It may be due to congenital dilatations of the lymphatic channels, or to lymphangiomatous tumor-growths. More frequently elephantiasis is caused by inflammatory conditions that occasion obstruction to the flow of the lymph. In some instances the etiology is very obscure.

Pathologically, elephantiasis consists of a thickening of the subcutaneous connective tissue, with more or less involvement of the skin as well. The disease may begin in the clitoris, or in one or other of the labia, and may be confined to the part primarily affected, or may extend to other parts. The affected portions are tough and edematous; the skin is tightly bound to the subcutaneous tissue. The surface may be irregularly elevated, but in other cases is smooth. Superficial ulcers may occur, and sometimes the dilated lymph-channels communicate with the surface, discharging lymph (lymphorrhea).

Papillomatous tumors are not infrequent in syphilitic women in the form of elevated condylomata. A somewhat analogous condition of obscure etiology is that termed *caruncle*. It presents itself as a papillomatous and highly vascular elevation at the meatus of the urethra.

Adenoma arising from the glands of Bartholin has been described.

Carcinoma is uncommon. It most frequently arises from the clitoris, but may affect any portion. Glandular cancer may begin in Bartholin's glands.

Cysts are quite frequent. Small retention-cysts, containing pultaceous (atheromatous) matter, are sometimes met with in the labia majora. Larger cysts, containing serous or somewhat blood-stained liquid, may result from hematomata, or may be lymphangiomatous in origin. Hydrocele of the canal of Nuck has the superficial appearances of a cyst of the labia. Retention-cysts of Bartholin's glands have been referred to above.

THE PENIS AND SCROTUM.

CONGENITAL ABNORMALITIES.

Absence of the penis is rarely observed; more frequently it is abnormally small, resembling the clitoris of the female. Occasionally the organ is doubled, each half containing a duct, one for the discharge of urine, the other for seminal fluid.

Hypospadias is the condition in which the urethra terminates in an orifice on the under surface of the penis, in the pendulous portion or at the bulb, or occasionally at the root of the scrotum or in the perineum. *Epispadias* is a less frequent condition; the urethral orifice in this case is found upon the dorsal side of the organ. Excessive length of the prepuce is a frequent abnormality; there may be associated with this stenosis of the preputial opening, so that the glans penis cannot be exposed (*phimosis*).

INFLAMMATION.

Inflammation of the mucous membrane of the glans penis (*balanitis*) and of the prepuce (*posthitis*) is not infrequent. Among the more frequent causes are uncleanliness, with decomposition of smegma retained beneath the prepuce, irritation by the urine in cystitis or other inflammatory diseases, gonorrheal infection, and chancroids. The mucous membrane becomes swollen and red, and considerable purulent exudate may be discharged. Edematous swelling of the prepuce is frequent, and may cause inability to retract the prepuce over the glans (*phimosis*). In other cases the prepuce, previously drawn back, becomes so tensely swollen that it cannot be pushed forward to its normal position (*paraphimosis*).

In catarrhal inflammation of the prepuce there may be associated retention-cysts of the mucous glands. The cysts may rupture, causing small ulcerations.

Inflammation of the cavernous bodies may result from traumatism, or from extension of gonorrheal urethritis, and may sometimes occur in infectious diseases, such as small-pox, pyemia,

etc. The penis swells considerably, and abscesses or diffuse purulent infiltration may result. In traumatic cases with hemorrhagic exudation necrosis or gangrene may result. In case of favorable termination after severe inflammations cicatrices may be formed.

INFECTIOUS DISEASES.

Syphilitic chancres and **soft chancre** or **chancroid** are frequently located upon the prepuce or its frenum, or upon the glans penis (the lesions are described in Part I.).

Tuberculosis is a rare condition in this situation. It has been met with in the form of necrotic ulcerations. It is very likely that direct infection of the penis may occur during coitus with a woman who has genital tuberculosis.

TUMORS.

Papilloma, or **condyloma acuminatum,** is not infrequent on the glans penis and prepuce. Sometimes it has a distinctly inflammatory origin, occurring in association with gonorrhea, syphilis, or other forms of local irritation; in other cases it originates without discoverable cause. There are usually several or many warty elevations, and occasionally a mass of warts is aggregated in a cauliflower fashion. Microscopically, condylomata are composed of a stroma of vascular connective tissue covered with squamous epithelium. The cauliflower-form may be distinguished from epithelioma by observing that the mucous membrane is not infiltrated and is movable upon the underlying tissues.

Carcinoma (epithelioma) of the penis may arise from the glans or from the prepuce. It may present itself as an infiltrating growth with a tendency to ulceration, or as a papillomatous, cauliflower-like growth. In the latter case it is probable that the primary growth was papillomatous, with secondary carcinomatous association, or that the original tumor was carcinomatous, followed by papillomatous outgrowths. Considerable destruction of the glans penis may occur, and metastatic nodules are frequently formed in the inguinal glands.

Epithelioma of the scrotum is comparatively frequent in chimney-sweeps and paraffin-workers.

Elephantiasis of the scrotum is a common disease of the East. The scrotum may be enormously enlarged. Some cases are due to filariasis; in other cases filariæ cannot be demonstrated. Somewhat similar thickening of the prepuce is a rare condition.

Cysts.—Small cysts, due to occlusion of the glands of the mucous membrane and of the skin, are occasionally met with under the prepuce and in the scrotum. Dermoid cysts of the scrotum are occasionally observed.

Lipomata, angiomata, and **fibromata** are rare forms of tumors of the penis.

Concretions beneath the prepuce result from phimosis with retention of the smegma. Sometimes they increase by constant additions until they reach considerable size (200 g.). In one case under my observation gouty tophi in the prepuce grew to the size of a small lemon.

INJURIES OF THE PENIS.

Direct traumatism may occasion serious laceration of the corpora cavernosa, especially when the penis is erect at the time of injury. Considerable hemorrhagic extravasation may occur, and inflammation or even necrosis and gangrene may ensue. Fracture of the penis is a term applied to rupture of the fibrous capsule of the cavernous bodies. Both this and less extensive lacerations occasion great hemorrhagic swelling, with subsequent inflammation or necrosis. Injuries to the penis may cause rupture of the urethra, with extravasation of urine.

THE TESTICLES.

CONGENITAL ABNORMALITIES.

Absence of one or both testicles is a rare condition. More frequently the organ is *hypoplastic*, remaining undeveloped through life.

The most frequent congenital abnormality is *cryptorchismus*, the condition in which one or both testicles remain in the abdominal cavity, in the inguinal canal, or elsewhere in the tract through which normal descent occurs. The undescended testicle may descend at or before puberty, or may remain fixed in its abnormal position. In the latter case, especially if the testicle is in the inguinal canal, secondary inflammation or atrophy may occur. Slight defects in the development of the testicle are not infrequent, but are unimportant.

ATROPHY AND HYPERTROPHY.

Atrophy may follow any form of inflammation of the testicle or epididymis, such as those occurring after gonorrhea, mumps, and other infectious diseases or traumatism. In other instances pressure upon the organ, as in hydrocele, tumors, etc., is the cause of atrophy. The most frequent form is that which occurs as a natural process of involution in old age (*senile atrophy*).

The testicle decreases in size, increases in hardness from overgrowth of connective tissue, and is usually more pigmented than in health. Microscopically the seminal tubules are found to have

undergone fatty degeneration, and contain fatty débris and blood-corpuscles.

Hypertrophy of one testicle may occur as a compensatory process in cases of disease, atrophy, or removal of its fellow. Hypertrophy of this sort has been produced experimentally in animals. The seminal tubules increase in size, but are otherwise normal.

DEGENERATIONS.

Fatty degeneration is frequently observed in testes subjected to pressure through tumors or other pathologic conditions, and in cases of atrophy of the testicle from any cause. The epithelium of the tubules is attacked, and may be completely destroyed, with production of fatty detritus.

Myxomatous degeneration occurs in various tumors of the testis and in gummata.

Calcification may affect old inflammatory deposits, especially those of the epididymis.

Caseation is a frequent condition in tuberculous and syphilitic lesions; and abscesses may undergo a process of inspissation, with formation of dry, caseous material.

CIRCULATORY DISTURBANCES.

Active hyperemia of the testis, epididymis, and especially of the membranes, occurs in association with acute inflammations.

Passive hyperemia is caused by pressure upon the veins or disease of the veins (varicosity). The testis and epididymis become swollen from edema, and, if the hyperemia persists, fatty degeneration and atrophy may result. Serous effusion into the tunica vaginalis (*hydrocele*) may occur, but this condition is more frequently inflammatory (see page 666).

Embolism of the spermatic artery may occasion hemorrhagic infarction, followed by necrosis or gangrene of the testis. This sequence has been observed in a few cases, and has been proved experimentally. Sometimes gangrene seems to be caused by phlebitis of the pampiniform plexus.

INFLAMMATION.

Inflammation may involve the testis (*orchitis*), the epididymis (*epididymitis*), or the tunica vaginalis (*vaginitis testis*).

Etiology.—Traumatism is a frequent factor in the etiology, and causes inflammation of the epididymis and membranes more frequently than of the testicle itself. Blows, bruises, and contusions are the usual conditions that cause this form of inflammation.

In another group of cases the irritants are micro-organisms conveyed through the blood. Thus in typhoid fever, tuberculosis,

pneumonia, and various forms of septicopyemia the specific organisms have been discovered in the areas of inflammation. Similar inflammations occur in scarlet fever, syphilis, and small-pox, and are doubtless caused in the same way, though the specific organisms are unknown. In these cases the testis is more frequently affected than the epididymis.

In a third group of cases infection occurs through the vas deferens, and the epididymis is affected first and often alone. The most frequent infectious agent in this group of cases is the gonococcus; but other micro-organisms may enter the vas deferens, reach the epididymis and cause inflammation, in other diseases of the bladder or urethra, or after operations upon these parts, such as crushing vesical calculi, cutting urethral strictures, and the like.

Pathologic Anatomy.—Inflammations of the different parts may be separately considered.

Acute Orchitis.—In acute orchitis the testis is swollen and more or less edematous on account of inflammatory exudation. Microscopically the striking feature is round-cell infiltration of the intertubular tissues. This may be diffuse and uniform, or may occur in circumscribed areas. The latter is especially common in the orchitis of variola and pyemia. The round cells may infiltrate the walls of the tubules, and may be discharged into the tubules in great numbers. At the same time the epithelial cells may suffer degeneration and desquamation. Intense orchitis may lead to the formation of abscesses, single or multiple. These may subsequently undergo complete absorption, or may become inspissated and encapsulated, the contents of such a focus consisting of fatty detritus and cholesterin. In other cases the abscess may rupture externally, and occasionally granulations springing from the tunica albuginea or the testis may protrude through the opening. The term *benign fungus* is applied to this condition.

Chronic orchitis usually results from the acute form. The inflammatory changes of the intertubular tissues gradually lead to induration, and the testis becomes hard and contracted, the connective tissue and septa being increased in density, the tubules at the same time suffering degeneration and atrophy. In cases following acute suppurative orchitis the tissues surrounding the inspissated abscess become sclerotic, and the tubules are in large part or wholly destroyed. Small nodular areas are discovered in such cases, and on section these are found to consist of a dense wall of fibrous tissue enclosing thickened pus containing fatty detritus and cholesterin. The membranes surrounding the testis are usually thickened and united by adhesions.

Chronic orchitis without a definite antecedent acute stage is a frequent result of syphilis (see page 668).

Acute epididymitis occurs when infective agents have reached the epididymis through the vas deferens. There is tense swelling

of the epididymis, and not rarely associated inflammation with serous exudation in the tunica vaginalis. The testis is not, as a rule, involved. The process begins as an acute catarrhal inflammation of the tubules of the epididymis; later, cellular infiltration and occasionally abscess-formation occur in the intertubular connective tissues. The inflammation is sometimes completely resolved, but in other cases fibrous thickening, diffuse or nodular, results. Inspissated abscesses surrounded by fibrous tissue are sometimes seen, as in orchitis. The epithelium of the tubules embedded in the new-formed fibrous tissue may undergo a certain amount of proliferation, suggesting the appearance of adenoma or cancer. The vas deferens may be permanently obstructed, and the tubules on the proximal side and in the testis may undergo cystic distention. Extensive epididymitis very commonly causes atrophy of the testis.

Vaginitis testis and **periorchitis** are terms applied to inflammation of the tunica vaginalis testis. This condition is usually the result of orchitis or epididymitis, but may sometimes occur as a primary inflammation resulting from traumatism or other forms of irritation.

The tunica vaginalis is a reflection of the peritoneum, and inflammatory conditions arising in it resemble those of the abdominal peritoneum.

Serous or serofibrinous vaginitis testis is the most frequent form. This may be acute or chronic, and is characterized by the accumulation of small or large collections of serous liquid. In slowly developed cases the quantity of liquid may be one or two liters. It may be clear serum, but often contains flakes of fibrin, or leukocytes, and is sometimes reddish from the presence of red blood-corpuscles. Sometimes the liquid is milky or turbid, and contains fat-droplets and cholesterin-crystals. A chylous variety occurs in tropical countries, and is probably caused by the Filaria sanguinis hominis.

Hydrocele is the term used to designate effusions of these sorts. Sometimes the liquid contains spermatozoa, when the term *hydrocele spermatica* is applied. This condition is due to the escape of spermatozoa from improperly developed spermatic tubules or from ruptured cysts of the epididymis or testis. In certain cases it is difficult to distinguish hydrocele spermatica and spermatocele (see page 670).

When hydrocele persists the tunica vaginalis undergoes hyperplastic thickening, and small, wart-like elevations may be formed (*periorchitis prolifera*). These nodules may become separated and remain in the sac as free bodies, like those in the joints. Another result of the secondary inflammatory changes in the membrane is adhesion of the reflexions, causing a bilocular or multilocular hydrocele.

When the canal connecting the sac with the peritoneal cavity has remained patulous the fluid of hydrocele may be pressed into the abdominal cavity. The term *hydrocele processus vaginalis* is applied to such cases, and the term *hydrocele funiculi spermatici* to cases in which only the upper part of the vaginal canal is patulous and filled with liquid. *Hydrocele funiculi cystica* results from collections of fluid in the middle portion of the canal, the upper and lower ends being obliterated.

Purulent vaginitis testis occurs in association with epididymitis and orchitis, and sometimes primarily after traumatism. An ordinary hydrocele may be converted into a purulent collection by puncture with infected instruments. The sac is more or less distended with purulent liquid, and the surface of the membrane is covered with fibrinopurulent exudate. The pus may discharge externally, or may become inspissated; and extensive adhesions may obliterate the sac.

Hemorrhagic Vaginitis Testis.—In severe acute inflammations the exudation may be more or less hemorrhagic. More distinctly hemorrhagic forms of inflammation result from traumatism; in these cases there is first extravasation of blood and then inflammation. The sac may be lined with fibrinous and hemorrhagic deposits, and the membrane becomes thickened. In the terminal stages considerable thickening and sometimes calcification of the tunica vaginalis are observed.

Inflammation of the vas deferens may be associated with epididymitis or orchitis, or may occur independently in cases of direct traumatism. In syphilitic disease of the testis, and less commonly in other forms of orchitis, the vas deferens may be greatly thickened.

INFECTIOUS DISEASES.

Tuberculosis is most frequent in the epididymis, but may involve the testicle as well. The infection occurs in one of two ways: either through the vas deferens, in consequence of tuberculosis of the prostate, seminal vesicles, or bladder; or through the circulation in cases of pulmonary or other forms of tuberculosis. It has been shown that tubercle-bacilli are discharged from the body in the seminal fluid in cases of pulmonary and other forms of tuberculosis; and when local conditions predispose tuberculous infection of the epididymis may occur. Gonorrheal epididymitis seems to constitute such a local predisposition. Primary hematogenous infection of the epididymis seems to occur in rare cases.

In cases of infection through the vas deferens there are formed in the walls of the tubule of the epididymis small tubercular masses, which rapidly increase in size and run together, forming caseous

areas of considerable size. Further invasion occurs along the lymphatic channels and the tubule, and rapid involvement of a considerable part of the epididymis results (Fig. 329). The tubule surrounded by tuberculous tissue may become filled with des-

FIG. 329.—Tuberculosis of the epididymis and testicle (modified from Bollinger).

quamated epithelium and puriform or caseous matter, and may be dilated in a cystic form. Extension to the testicle may occur, but is unusual.

Associated serous or serofibrinous vaginitis testis is not infrequent; and in some cases the tuberculous disease itself extends to the testicular envelopes and causes nodular elevations, or ulcerations and fistulous communications with the surface.

Hematogenous tuberculosis of the epididymis is, in the first place, of the miliary form; but the tubercles grow rapidly and caseous nodules are rapidly formed.

Tuberculosis of the vas deferens may be secondary to tuberculosis of the seminal vesicles and bladder, or of the epididymis. It is characterized by caseous swelling of the walls of the duct.

Syphilis is not infrequently seen in the testicle in the late stages of acquired syphilis and in congenital syphilis. The epididymis and the membranes are secondarily involved. Two forms may be distinguished. The more frequent is that in which diffuse induration of the testicle occurs; in the less frequent variety there are circumscribed gummata. In the diffuse form the organ is more or less uniformly indurated, and on section dense bands of fibrous tissue are conspicuous. The tubules suffer compression, degeneration, and atrophy, and sometimes become

converted into cheesy foci. The gummata have the usual translucent or cheesy appearance. When the membranes are involved diffuse thickening occurs; and in rare cases the disease extends to the skin, causing superficial granulations (*syphilitic fungus*). The vas deferens is often greatly thickened, as are also the walls of the blood-vessels of the testis and epididymis.

Lepra of the testis occasions nodular lesions and pressure-atrophy of the tubules. Lepra-cells containing bacilli, as well as free bacilli, occur in the tubules in abundance. This fact is important as indicating a possible mode of transmission of the disease.

TUMORS.

Fibroma is occasionally observed in the rete testis and tunica albuginea as a small nodular tumor.

Chondroma is rare. It may occur in the epididymis or rete, as a single node or as multiple small nodules. More frequently, small cartilaginous areas are found in carcinomata or other tumors of the testis.

Osteoma is very rare.

Myxoma is rare, except in association with other tumors.

Rhabdomyoma sometimes occurs in the form of flesh-like growths of the testis.

Sarcoma may occur in any of its various forms in the testis, and less commonly in the epididymis. It forms rapidly growing whitish or reddish tumors. Secondary changes, such as fatty degeneration, hemorrhage, cystic softening, and caseation, are not infrequent. Cystic dilatation of the seminal tubules may occasion marked changes in the appearance of the tumor. The cysts are small, and filled with turbid liquid containing fat, desquamated cells, and cholesterin; or large, and contain serous liquid, either clear, turbid, or blood-tinged. The lining epithelium of the cysts is columnar, or, in case of cysts of the epididymis, often ciliated. The walls of the tubules in some instances undergo active hyperplasia, giving rise to papillomatous elevations of the inner surface, and a truly adenomatous proliferation may occur. In the latter cases the tumor may be designated *adenosarcoma*. Growths of this variety are sometimes met with in young adults or children, and most frequently in the rete testis. They are more or less malignant, causing frequent metastasis through the lymphatics or blood-vessels.

Adenoma of the testicle is rare; much more frequently cystic tumors have a more or less adenomatous character (see Cysts).

Carcinoma may occur in the form of a scirrhus, but more frequently as a soft or medullary variety (Fig. 330). Mucoid and colloid degenerations are rather frequent, and cystic softening may occur. Cysts may also result from dilatation of the tubules. Carti-

laginous areas are sometimes found in the stroma of the growth; to such the term *chondrocarcinoma* is applied. More or less complete destruction of the testicle and epididymis is frequent, but the tunica albuginea usually resists invasion for a considerable time. Carcinoma of the testicle seems to originate from the epithelium

FIG. 330.—Carcinoma of the testicle (from a specimen in the Museum of the Philadelphia Hospital).

of the convoluted tubules. Metastasis through the lymphatics and blood-vessels is frequent, and extension through the testicular envelopes to the skin may occur.

Cysts.—Retention-cysts of the tubules are frequent in cases of inflammation and induration of the testis and epididymis. Sometimes they contain a simple milky liquid; in other cases spermatozoa are found in the fluid, and to these cysts the term *spermatocele* is applied. The cysts may be numerous and small, or may be very large, containing a hundred or more cubic centimeters of liquid. The cysts are found in the body of the organ; but, when large, project from the surface. Very large cysts push the testicle and epididymis to one side. Occasionally cysts originate from the hydatids or the paradidymis. These may be spermatoceles, when one of the vasa aberrantia opens into them.

Secondary proliferations of the epithelium of the cysts may convert a simple into a *papilliferous cystoma;* and occasionally

the primary process seems to be one of adenomatous character, the cystic condition being the result of secondary distention or of the peculiar character of the acini formed.

Small cystic cavities may contain mucous liquid or thick, curdy material. In the latter case the term *atheromatous cyst* is applicable.

Dermoid cysts are occasional tumors of the testis proper. They may be simple sacs, lined with epidermal tissue and filled with pultaceous matter; or *complicated dermoids*, containing teeth, bone, muscle-fibers, and nerve-tissue.

PARASITES.

Echinococcus-cysts are rarely met with.

THE PROSTATE GLAND.

INFLAMMATION.

Inflammation of the prostate, or **prostatitis,** is most frequently secondary to posterior urethritis. Sometimes, however, it results from other causes, such as metastatic involvement in general pyemia or other forms of infection. Inflammations in the vicinity and direct injuries of the prostate may likewise cause acute inflammation.

Pathologic Anatomy.—A simple and a suppurative form may be distinguished.

Simple Prostatitis.—In the ordinary prostatitis following urethritis the disease takes the simple form, the gland being congested and swollen, and causing by its enlargement more or less obstruction of the urethra. Small suppurative foci may be formed in and about the glandular pouches and tubules.

Suppurative or phlegmonous prostatitis, or abscess of the prostate, may be a terminal condition of the previous form, or it may be developed primarily. In cases of metastatic prostatitis a number of foci of suppuration may occur and subsequently coalesce, or a diffuse suppurative infiltration may take place. The development of abscesses is usually acute, though in some cases it may occur insidiously. If the abscesses are small they may subsequently undergo encapsulation, inspissation, and even calcification. Larger abscesses are prone to rupture into the urethra, usually through a number of openings. Sometimes, however, the inflammation extends to the tissues around the gland, causing *periprostatitis*, and later rupture into the rectum may occur. Extensive phlegmonous inflammation of the pelvic tissues is an unusual result.

laginous areas are sometimes found in the stroma of the growth; to such the term *chondrocarcinoma* is applied. More or less complete destruction of the testicle and epididymis is frequent, but the tunica albuginea usually resists invasion for a considerable time. Carcinoma of the testicle seems to originate from the epithelium

FIG. 330.—Carcinoma of the testicle (from a specimen in the Museum of the Philadelphia Hospital).

of the convoluted tubules. Metastasis through the lymphatics and blood-vessels is frequent, and extension through the testicular envelopes to the skin may occur.

Cysts.—Retention-cysts of the tubules are frequent in cases of inflammation and induration of the testis and epididymis. Sometimes they contain a simple milky liquid; in other cases spermatozoa are found in the fluid, and to these cysts the term *spermatocele* is applied. The cysts may be numerous and small, or may be very large, containing a hundred or more cubic centimeters of liquid. The cysts are found in the body of the organ; but, when large, project from the surface. Very large cysts push the testicle and epididymis to one side. Occasionally cysts originate from the hydatids or the paradidymis. These may be spermatoceles, when one of the vasa aberrantia opens into them.

Secondary proliferations of the epithelium of the cysts may convert a simple into a *papilliferous cystoma;* and occasionally

the primary process seems to be one of adenomatous character, the cystic condition being the result of secondary distention or of the peculiar character of the acini formed.

Small cystic cavities may contain mucous liquid or thick, curdy material. In the latter case the term *atheromatous cyst* is applicable.

Dermoid cysts are occasional tumors of the testis proper. They may be simple sacs, lined with epidermal tissue and filled with pultaceous matter; or *complicated dermoids*, containing teeth, bone, muscle-fibers, and nerve-tissue.

PARASITES.

Echinococcus-cysts are rarely met with.

THE PROSTATE GLAND.

INFLAMMATION.

Inflammation of the prostate, or **prostatitis,** is most frequently secondary to posterior urethritis. Sometimes, however, it results from other causes, such as metastatic involvement in general pyemia or other forms of infection. Inflammations in the vicinity and direct injuries of the prostate may likewise cause acute inflammation.

Pathologic Anatomy.—A simple and a suppurative form may be distinguished.

Simple Prostatitis.—In the ordinary prostatitis following urethritis the disease takes the simple form, the gland being congested and swollen, and causing by its enlargement more or less obstruction of the urethra. Small suppurative foci may be formed in and about the glandular pouches and tubules.

Suppurative or phlegmonous prostatitis, or abscess of the prostate, may be a terminal condition of the previous form, or it may be developed primarily. In cases of metastatic prostatitis a number of foci of suppuration may occur and subsequently coalesce, or a diffuse suppurative infiltration may take place. The development of abscesses is usually acute, though in some cases it may occur insidiously. If the abscesses are small they may subsequently undergo encapsulation, inspissation, and even calcification. Larger abscesses are prone to rupture into the urethra, usually through a number of openings. Sometimes, however, the inflammation extends to the tissues around the gland, causing *periprostatitis*, and later rupture into the rectum may occur. Extensive phlegmonous inflammation of the pelvic tissues is an unusual result.

ATROPHY AND DEGENERATION.

Atrophy of the gland is occasionally met with in youthful individuals, and may be the result of disease or removal of the testis. It also occurs in the aged, and in this case atrophy of the tissues surrounding the prostatic ducts may be accompanied by dilatation of the ducts themselves. The gland then presents a cavernous appearance. Atrophy of the gland sometimes leads to incontinence of urine.

Fatty degeneration of the epithelium of the gland and of the muscle-fibers is frequent in old age, and may occur as an independent condition or in association with hypertrophic enlargement of the gland. The gland becomes soft, and diffusely yellow or mottled in color.

CONCRETIONS.

Prostatic concretions are not unusual in persons of advanced age, and are frequently found in considerable numbers. They vary in size from almost microscopic granules to bodies the size of a millet-seed. On section through the gland these brownish-colored bodies give the appearance of a surface sprinkled with snuff. The granules are usually round or oval, and are characterized by concentric lamellations. They may be colorless at first, but usually become brownish. The term *amylaceous bodies* has been applied to them, and they have been supposed, though erroneously, to be composed of amyloid material, such as occurs in amyloid degeneration. When they reach considerable size calcareous salts may deposit around them and give them an irregular form. Sometimes the concretions are discharged through the prostatic ducts into the urethra; in other cases the larger concretions project prominently into the urethra beneath its mucous membrane.

INFECTIOUS DISEASES.

Tuberculosis of the prostate is usually found in association with tuberculosis of the other genital organs, especially the vas deferens and epididymis. It is also met with in association with tuberculosis of the bladder or kidney. The prostate is usually diffusely enlarged, and may be somewhat nodular upon the surface. On section caseous areas are found, or the entire gland has a caseous appearance. Recent tubercles are rarely visible, as caseation progresses with unusual rapidity in this organ. Primary tuberculosis of the prostate is rare.

HYPERTROPHY AND TUMORS.

Hypertrophy of the prostate is a condition sometimes inflammatory in character, sometimes more probably of the nature of

tumor-formation. It occurs most frequently in the aged. The causes are often quite obscure. In some cases chronic posterior urethritis seems to be the important factor; in other instances disturbances of the circulation, and especially varicose conditions of the veins, are active in the causation.

FIG. 331.—Hypertrophy of the middle lobe of the prostate: *A*, middle lobe of prostate; *B*, urethra (White and Wood).

The organ may enlarge in a uniform manner, or there may be nodular or localized swelling. Of the localized form the most important, from a clinical aspect, is that in which the middle lobe or the isthmus of the gland enlarges and projects under the posterior wall of the urethra as a small or large rounded elevation, or as a

transverse bar or obstruction (Fig. 331). According to the investigations of some authorities, the enlargement in such instances is due to a hyperplasia of accessory prostatic tissue lying immediately under the mucous membrane of the bladder and of the prostatic portion of the urethra, with subsequent involvement of the isthmus of the gland itself.

On section through the gland there may be a uniform induration, or in other cases, in consequence of associated changes in the epithelial or glandular elements, there may be scattered through the gland areas of softening or of proliferation of the glandular elements, or of cystic distention of these. In such instances the indurated gland presents more or less softened or cystic foci.

Microscopically, in the diffuse form, involving the stroma alone, the gland presents merely the features of uniform fibromyomatous

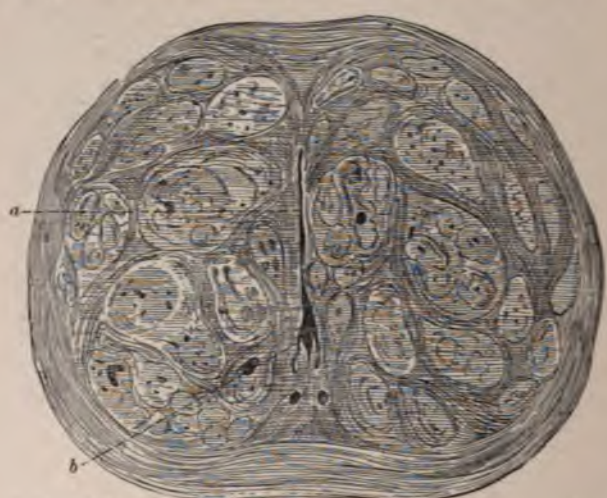

FIG. 332.—Section of hypertrophied prostate of a man aged 74 years; natural size: *a*, urethra; *b*, colliculus seminalis (Socin).

proliferation, and corresponds in structure with fibromatous or myofibromatous tumors of the uterus (Fig. 332). In other cases the glandular elements take an active part in the pathologic process, and a distinctly adenomatous character is added. The glandular elements may undergo fatty degeneration, and the lumina of the acini and tubules may be filled with milk-like, fatty material. In other cases pronounced cystic distention of the gland occurs.

Results of Hypertrophy of the Prostate.—Enlargements of the prostate usually interfere with the discharge of urine. This is particularly marked in cases in which the middle lobe projects into the urethra, though in some instances the opposite result may be produced, viz., incontinence of urine due to interference with

the contractions of the sphincter of the neck of the bladder. In cases of enlargement of one of the lateral lobes obstruction to the flow of urine is caused by lateral deviation and compression of the urethra.

The muscular walls of the bladder at first become hypertrophied and dilatation of the bladder subsequently occurs. Cystitis, distention of the ureters and renal pelves, and ascending infection, causing ureteritis, pyelitis, and pyelonephritis, are among the late results.

Sarcoma.—Sarcoma is a rare tumor of the prostate. It generally has the characters of lymphosarcoma, and is a rapidly growing, destructive tumor. In a few cases combination with adenoma has been observed.

Carcinoma of the prostate is more frequent than sarcoma, though it is not a common tumor. It occurs in relatively young persons. The tumor arises from the epithelium of the tubules, and takes the form of nodular, grayish or white masses which cause irregular enlargements of the gland, and not rarely project into the urethra or the base of the bladder. Superficial ulceration of the mucous membrane over these projections is not infrequent. The stroma of the gland usually proliferates actively. Metastasis to the inguinal glands, or to distant parts, including the bones, is not infrequent; but direct extension to the bladder, seminal vesicles, or rectum is more common.

Cysts of the prostate are usually the result of retention of exudates within the glands or their ducts. Occasionally cystic formations seem to arise from remnants of Müller's ducts.

COWPER'S GLANDS.

Inflammatory conditions are met with in these glands in association with similar affections of the prostate. Occasionally, independent inflammation of Cowper's glands results from posterior urethritis. The gland is enlarged and presents the usual appearances of inflammation. The termination may be abscess-formation. Obliteration of the mouths of the ducts may occasion cystic conditions in the glands, and carcinoma has been described.

THE SEMINAL VESICLES.

Inflammation.—*Acute inflammation* of the seminal vesicles may occur in association with gonorrheal urethritis. The vesicles become distended with seminal secretion and mucopurulent exudate. Their walls are swollen, and the mucous membrane presents the appearance of catarrhal inflammation.

Chronic inflammation may result from the acute form, and causes contraction and thickening of the walls.

Tuberculosis of the seminal vesicles is common in cases of urogenital tuberculosis. The vesicles are rarely independently affected. The walls become thickened and may present nodular, cheesy masses, and there may be ulcerations of the mucous surface. The cavities of the vesicles contain caseous or puriform material.

Tumors.—*Primary carcinoma* has been described; but *secondary carcinoma*, resulting from extension of cancer of the adjacent structures, is more common.

Cystic distention and the formation of *diverticula* result from obstructions of the ejaculatory duct. The contents of the vesicles in such cases are seromucous in character.

Concretions frequently result from calcification of inflammatory exudates. They are especially frequent in association with tuberculosis.

THE MAMMARY GLANDS.

CONGENITAL ABNORMALITIES.

Absence of one or both breasts may occur in association with other defects of development of the thoracic walls. Incomplete development of the mammary glands, or hypoplasia, may be associated with hypoplasia of the genital organs.

Supernumerary mammary glands are frequently observed; the term *polymastia* is given this condition. The supernumerary gland or glands may be situated between the normal glands, below these, or in distant parts, such as the back, shoulders, and arms. They may occur in either sex, and may be structurally complete and functionally active; or may be merely rounded masses of mammary tissue without excretory ducts or nipples. In the latter instances the probable explanation of the condition is that in the process of development parts of the normal glands have been split off and have separately developed.

Early Development.—The mammary glands may be developed at an abnormally early period, in correspondence with early development of the genital organs.

Abnormal functional activity (secretion) may be stimulated by various diseases of the genital organs; and in the newborn of either sex during the first week of life slight secretion of colostrum-like material is frequent.

Abnormal development of the male breast is occasionally observed, especially about the age of puberty, and sometimes copious secretion of milk takes place. Usually the organ subsequently atrophies, but exceptionally the enlargement and secretion persist.

CIRCULATORY DISTURBANCES.

Hyperemia occurs during the menstrual period and at the beginning of lactation, as a physiologic process, and causes slight

swelling and redness. Pathologic hyperemia plays a part in the process of inflammation.

Hemorrhages are usually the result of traumatism. They may occur into the gland itself, or into the connective tissue in front of or behind the gland. Occasionally hemorrhages are due to intense inflammation or to tumor-formation. The blood may find its way into the lactiferous tubules, and may be in part discharged from the nipple. In case of large hemorrhages the blood may subsequently undergo absorption or inspissation, and hemorrhagic cysts may be formed.

INFLAMMATIONS.

Acute inflammation of the mammæ, or **acute mastitis,** is rarely met with, excepting during the puerperium. Exceptionally it may occur in cases of general pyemia, or in the new-born as a result of active secretion and obstruction to the outlets. Sometimes inflammation of the glands results from direct extension of inflammatory processes of the skin, subcutaneous tissue, or thoracic walls. Puerperal mastitis is infective in character, and results from injury or disease of the nipple, from which the infective agents enter the glands. The actual portal of entrance may be the discharging tubules, or may be fissures and erosions of the nipple. Various micro-organisms have been discovered, including staphylococci and streptococci.

Pathologic Anatomy.—The gland is swollen and distends its capsule tensely, the skin is reddened, and a general hyperemia of the gland is noted. During the earlier stages the inflammation may be localized or may be diffuse. In the former case more or less circumscribed induration is discovered, while in the latter the organ is uniformly indurated. The tendency of mastitis is to a termination in suppuration. On section through the gland areas of light-yellowish color indicate the purulent infiltration, while in the later stages more or less extensive abscesses are formed. The latter may communicate with the lactiferous tubules, and pus and milk may be discharged from the nipple. The abscesses tend to extend in various directions, and may finally rupture upon the surface through fistulæ. After discharge of the pus granulation-tissue is formed, and the cavities are obliterated by cicatricial tissue. When the larger discharging tubules are opened by the abscesses fistulæ may be formed, which continuously discharge milk. Small collections of pus may become encapsulated and inspissated, being converted into cheesy or partly calcified matter.

The connective tissues around the mammary gland are sometimes involved by extension, and suppurative or necrotic *perimastitis* results. Extension to the thoracic walls and pleura is rare.

Chronic Mastitis.—Diffuse induration of the mammary

gland, resembling in its histologic features the indurative or chronic interstitial inflammations of other organs, is occasionally seen in middle-aged or old women. The causes are obscure, and it is difficult to distinguish some of the cases from certain forms of fibromatous tumors. The gland becomes hardened and sometimes slightly increased in size. In other cases retraction of the connective tissue causes a reduction in the size. On section firm bands of connective tissue are conspicuous, and the lactiferous tubules may be distended, forming small or large retention-cysts. This form of disease will be further discussed under Fibroma.

ATROPHY AND HYPERTROPHY.

Atrophy of the gland occurs as a physiologic process after the menopause, or it may result from local causes, such as abscess or tumor-formation. Artificial menopause, following oöphorectomy or diseases of the reproductive organs, may occasion atrophy similar to that normally present in old age. The gland may simply decrease in size, without notable change of any other kind. Sometimes, however, connective-tissue hyperplasia accompanies the atrophy of the glandular elements, and diffuse infiltration may occur.

Hypertrophy of the gland is sometimes met with in girls at the age of puberty, and leads to a uniform enlargement of the organ. In some cases there is a true hypertrophy of all the constituents of the gland; in other instances dilatation of the lymphatic channels, or degenerative changes, may cause a simulation of true hypertrophy. Both breasts, as a rule, are affected, and there may be increased functional activity (*galactorrhea*).

DEGENERATIONS.

Fatty infiltration, or **lipomatosis,** of the gland may accompany atrophy, or may occur as an independent condition. The gland may be greatly enlarged. Accompanying this degeneration there is usually diffuse hyperplasia of the connective tissue.

Myxomatous degeneration may be associated with fatty infiltration.

INFECTIOUS DISEASES.

Tuberculosis of the mammary gland may be associated with tuberculosis of the axillary glands, or of other parts, or may be primary. The tubercle-bacilli reach the gland either through the lactiferous tubules or through the blood. The disease is characterized by the formation of distinct tubercles, which tend to unite and form caseous areas. There is rarely extensive disease.

Syphilis, in the form of gummata, is sometimes met with in acquired or congenital syphilis.

TUMORS.

Fibroma may be met with in the form of circumscribed nodular growths, or, according to the view of some pathologists, as a diffuse process. Circumscribed fibroma presents itself as a hard, nodular tumor, often having a distinct capsule, and on section presenting a lamellar arrangement. The glandular elements of the organ in the area of invasion may undergo secondary hyperplasia, and thus a form of fibro-adenoma may be developed. In the cases termed *diffuse fibroma* the entire organ may be indurated, or nodular areas of sclerosis may be found in various parts of the gland. The acini and ducts may at the same time undergo proliferation, forming adenomatous structures ; or compression of the ducts may lead to retention-cysts. It is difficult to determine in individual cases whether the process is one of tumor-formation or one of inflammatory hyperplasia.

A form of particular interest is that known as **intracanalicular fibroma.** In this the proliferating fibrous tissue projects into the normal or dilated tubules in the form of papillary elevations. The mucosa lining the tubules is pushed forward by the ingrowths, and covers these in the same manner as epithelium covers superficial papillomata of the skin or mucous membranes. The gland

FIG. 333.—Intracanalicular fibroma of the mammary gland (Kaufmann).

may be greatly enlarged, and on section presents an appearance resembling that of a cut through a cauliflower (Fig. 333).

Lipoma of the mammary glands occurs in the form of round,

encapsulated tumors of the interstitial or periglandular connective tissues.

Myxoma may occur in a diffuse form, causing a transformation of the gland into myxomatous material, or as circumscribed tumors.

Myomata containing smooth muscle-fibers, and mixed tumors containing striated muscle-fibers, are rare.

Chondroma and **osteoma** have been observed.

Sarcoma is most frequently of the round-cell variety. It occurs in a diffuse form or as circumscribed nodules; association with fibroma and myxoma is not infrequent.

In *diffuse sarcoma* the gland undergoes a uniform enlargement, and the neoplasm extends rapidly, forming attachments to the skin and sometimes causing superficial ulceration. In other cases extension toward the chest-walls may occur, and may finally reach the pleura. On section through the gland a lobular character of the tumor may be recognized, and areas of fibrous or myxomatous character are visible here and there. Cystic conditions, sometimes met with, may be due to obstruction and consequent distention of the lactiferous tubules. The term *cystosarcoma* is appropriately applied to such cases. The sarcomatous tissue may project into the dilated tubules in a polypoid form (*intracanalicular sarcoma*). Section through the gland in such cases presents an appearance not unlike the surface of section of a head of cabbage. Cysts may also be formed in sarcomata by degenerative softening.

Localized sarcomata occur as nodular tumors arising from the connective tissue surrounding the acini. On section through the tumor the glandular acini may be seen within the nodules.

In any form of sarcoma the epithelium of the tubules and acini may undergo secondary proliferation, when the term *adenosarcoma* is applicable.

Adenoma of the mammary glands may be an independent growth, or may be associated with fibroma, sarcoma, or other tumors. The independent form presents itself as a circumscribed, encapsulated, nodular tumor, somewhat firmer than the substance of the normal gland. Microscopically it consists of more or less typical glandular acini. These are usually somewhat dilated, and the epithelial cells are larger than those of the normal gland (Fig. 64). Instead of a single layer of columnar cells, active hyperplasia may cause a complete filling of the acinus with epithelial cells. Fatty degeneration of the cells is not infrequent, and sometimes there is a certain amount of milk-secretion, causing additional distention of the cavities.

Carcinoma.—Carcinoma may develop from the tubules or from the acini of the glands. It may begin as an adenomatous tumor, which subsequently undergoes carcinomatous transformation, or may be a typical glandular cancer from the beginning.

In the cases primarily adenomatous the structure of the acini becomes atypical and the epithelial cells tend to penetrate the membrana propria and form irregular collections or columns in the interstitial tissue. Degenerative changes are often observed, among which fatty degeneration is most frequent. Mucoid degeneration and a form of caseation are sometimes met with, and calcification may take place in the interstitial tissues. Occasionally an attempt at formation of milk occurs in the cancer-acini.

Varieties.—Among the varieties of carcinoma are the medullary, the simple, the scirrhous, and the myxomatous.

Medullary carcinoma, or **soft cancer**, is characterized by its softness and the abundance of liquid (cancer-juice). It grows rapidly and soon invades a large part of the gland, and attaches

FIG. 334.—Ulcerated carcinoma of the breast.

itself to the skin, which may finally be broken, exposing an ulcerated surface (Fig. 334). Actual inflammatory changes terminating in suppuration are not infrequent.

Scirrhous cancer is slower in growth, and is usually very hard; the skin is firmly attached to the tumor, and the nipple is usually retracted. On section the tumor is found to be of a firm, fibrous, and somewhat translucent character; extensions of the growth are seen radiating in various directions from the body of the tumor. Microscopically the growth consists of fasciculated connective tissue, enclosing round or elongated collections of cancer-cells (Fig. 72).

Simple carcinoma stands between the medullary and the scirrhous forms in point of hardness, as well as in point of malignancy. The three forms differ only in the relative amount of epithelial elements and fibrous tissue.

Myxomatous, colloid, or **gelatinous cancer** is a rare form in which the interstitial connective tissue suffers mucoid change, and the epithelial cells of the cancer-acini undergo more or less fatty or exceptionally mucoid degeneration (Fig. 73).

Results.—Cancer of the breast may extend directly to the subcutaneous tissues and skin on the one hand, or to the walls of the chest and pleura on the other hand. Metastasis frequently takes place through the lymphatics, the axillary glands, as a rule, presenting the first evidence of metastasis. Malignancy varies with the softness or hardness of the tumors, the scirrhous form frequently having a comparatively benign character. Sometimes the increasing growth of connective tissue in this variety leads to practical cessation of the growth of the tumor.

Mammary cancers are much more frequent in the female than in the male sex. They are commonly met with after the age of forty, and traumatic influences seem to bear some relation to their occurrence.

Cysts.—Repeated reference has been made to the retention-cysts of the lactiferous tubules caused by compression or other forms of obstruction. The gland may contain a few or many cystic cavities about the size of a pea, containing whitish or milky liquid. Occasionally the contents of the cysts are cheesy (*atheromatous*). Distention of the acini of the glands in consequence of obstructions to the outflow of milk may lead to large cystic tumors containing milk (*galactocele*). In the later stages the contents of such cysts may become thickened or caseous.

CHAPTER IX.

DISEASES OF THE BONES.

Anatomy and Development.—Bone is a dense form of connective tissue, the cement-substance being impregnated with lime-salts. It may be spongy or compact in character. On transverse section one sees certain oval openings, surrounded by concentric lamellæ of a substance containing lime-salts. Each opening is the end of a so-called Haversian canal, which with the surrounding lamellæ forms a Haversian system. The areas between the Haversian systems are filled with osseous tissue not arranged concentrically. Between the lamellæ of bony tissue are

seen irregularly oval spaces—lacunæ—from which run branching canaliculi. In preparations of fresh bone the lacunæ are found to be occupied by the bone-cells, which are irregular and have branching projections extending some distance into the canaliculi. In the center of the bones are found hollow spaces containing the bone-marrow. This is a vascular tissue, in the meshes of which are found large and small rounded cells resembling the lymphoid cells, red corpuscles, ordinary leukocytes, and some nucleated red corpuscles. A form of cell of particular interest is the large multinucleated giant-cell, or myeloplaque. The marrow extends in the form of projections into the substance of the bone and communicates with the Haversian canals.

Surrounding the bone is the fibrous periosteum. This consists of a dense outer layer and a more cellular inner one, which is osteogenetic in function.

Development.—The beginning of the change of the original cartilage into bone consists in the multiplication of the cartilage-cells and their arrangement in longitudinal rows. They grow into cartilage-corpuscles of considerable size, calcification at the same time occurring in the matrix between these cells. Simultaneously vascular projections extend inward from the perichondrium ; the cartilage-cells and preliminary calcareous deposit are subsequently removed, primary marrow-spaces being thus formed. Bone-cells are deposited in the spaces between the original cartilaginous trabeculæ, and at once begin to cover themselves with bony deposits, the cartilaginous trabeculæ gradually diminishing by absorption. By these processes a spongy form of bone is developed. Subsequently the concentric calcareous lamellæ of the Haversian systems are deposited within the spaces, and the spongy bone is thus converted into the dense form.

DISORDERS OF DEVELOPMENT.

Many congenital defects of development are observed, such as the appearance of supernumerary bones, the absence of certain bones, the failure of union between epiphyses and diaphyses, etc. These conditions are of little pathologic interest. The most important developmental disease is rickets.

RICKETS.

Definition.—Rickets or rachitis, is a constitutional disorder, attended with abnormal developmental processes in the bones, of which active proliferation of the cellular elements and lack of normal calcification are the most important.

Etiology.—The causes of rickets are still very obscure. The disease is in some way connected with improper nourishment, though

there is probably also an inherited disposition. It has been sought to establish a connection between rickets and syphilis, but any such relation is doubtful. Various chemical theories have been offered in explanation. Formerly it was supposed that the presence in the digestive tract of lactic acid in excess prevented the proper absorption of calcium; this theory, however, is generally abandoned. The disease occurs in infants during the first year of life, and continues during the second and third years, after which the active manifestations subside.

Pathologic Anatomy.—Rickets leads to various deformities, principally situated in the long bones and skull. The epiphyses, as those of the wrist, ankle, etc., are swollen, and in more advanced stages the shafts of the long bones may be variously distorted.

Sharp bends (*infractions*) may be observed in the long bones, and complete fractures may occur. The alteration of the skull is characteristic. The head is large and square in shape, the forehead prominent, and the fontanelles remain open a long time. Osteophytes may form, and not rarely areas are found in the temporal or other bones in which the mineral substance is deficient or almost completely wanting (*craniotabes*), the spaces being filled by a parchment-like membrane. Deformities of the chest are frequent, the chicken-breasted condition being the most marked. In the beginning of the disease slight enlargement of the ends of the ribs at the junction with the costal cartilages, causing the

FIG. 335.—Rachitic enlargement of the end of a rib (modified from Bollinger).

beaded appearance called the "rachitic rosary," is observed (Fig. 335). Various distortions of the spinal column, flattening of the pelvis, and other deformities may be met with in marked cases.

The *minute changes* of rickets consist in a form of abnormal development, in which calcareous deposition does not progress in the normal manner, but is replaced by proliferation of the cellular elements. In consequence of this the bone presents irregular areas of partial calcification lying between portions made up of greatly proliferated and enlarged cartilage-cells. Projections from the marrow and periosteum extend deeply and visibly into the body of the bone, which is thus composed for the most part of osteoid instead of osseous tissue. The marrow-spaces are irregular and excessive in size. These changes in the bone are marked at

the epiphyseal extremities, and thus lead to the visible enlargements. It is thus seen that the process in rickets is failure of development of the normal structure, rather than absorption of existing bone. The original calcareous deposit around the cartilage-cells is largely or completely absorbed, as in normal bone-formation, and often even more rapidly. The subsequent deposit of calcareous bone does not form, but in place of it there occurs a rapid proliferation of cartilaginous and other cells.

Associated Conditions.—The changes in the bones do not constitute the entire pathology of rickets. There are frequently gastro-intestinal disorders, such as catarrhal inflammations of the mucous membrane. Proliferative changes are met with in the spleen and liver, leading to fibrous overgrowth and enlargement, and the blood is more or less profoundly altered. Decrease in the number of red corpuscles and leukocytosis are the conspicuous features. Nucleated red corpuscles may be found in more or less abundance, according to the grade of anemia, and the leukocytosis involves a special increase of mononuclear elements, and myelocytes may be present.

Congenital rickets differs in some respects from the disease met with after birth. The extremities are short and thick, the ends of the bones enlarged, and the shafts bent. There is increase of the original cartilage and of the periosteum, with an arrest of development of the bones.

REGENERATION OF BONE.

Regeneration of bone occurs most typically in the healing of fractures, and also as a part of various pathologic processes in which a certain amount of destruction of bony tissue has taken place. Hypertrophy may be included in the same group of affections.

Fractures.—**Definition.**—Fractures are breaches in the continuity of bone which occur in consequence of direct force or of muscular contractions. The bone may be broken in various directions, the line of fracture being straight or irregular, directly transverse to the long axis of the bone, or oblique. The bone may be broken into a number of splinters (*comminuted fracture*), or the fracture may be a single one. There is always more or less injury to the soft parts immediately surrounding the bone, and sometimes extensive injury causes communication between the outer surface and the seat of fracture through flesh wounds (*compound fracture*).

Repair of Fractures.—The process of repair is much the same as the process in the original formation of bone. Immediately after the fracture there is more or less hemorrhagic extravasation within the marrow and around the broken ends of the bone. Within

a few days cellular infiltration, with congestion and edematous swelling of the periosteum and marrow, as well as of the bones, may be noted. Proliferative changes then take place in the same situations and new blood-vessels are formed. The tissue soon becomes somewhat hardened from deposit of calcareous matter and cartilaginous formation. Its condition varies greatly in different cases; sometimes it is quite fibrous, in other cases almost purely cartilaginous. Gradually it is converted into bone by the regular processes of bone-formation. At this stage the seat of fracture is occupied by a deposit of soft, bony material of considerable bulk, which causes a local thickening of the bone. Finally the excess

FIG. 336.—Fracture of the femur, showing malposition of the ends of the bone and abundant callus (modified from Bollinger).

FIG. 337.—Fracture of humerus; section through the bone, showing the repair of the fracture (modified from Bollinger).

is removed by absorption, the parts in the direct line of the bone upon which the strain naturally falls becoming thickened, while other parts are absorbed.

The original deposit of osteoid or chondroid material at the seat of fracture is termed *callus* (Fig. 336). Part of this is deposited on the exterior (*periosteal callus*), and is derived from the periosteum; part is within the marrow-cavity (*myelogenous callus*); and a third

part is sometimes seen between the ends of the bone (*intermediary callus*). The last is produced by the periosteum.

The healing of fractures under the most favorable circumstances—that is, in cases in which the fragments of bone are restored to their proper position—is accomplished with but little disturbance of the normal relations. The seat of fracture may be permanently thickened, and there is always some shortening of the affected bone. When the fragments are not placed in proper position, angular deformities, with considerable thickening from deposit of bony material between the fragments, result (Fig. 337).

When the fragments are not kept in apposition, or when the general condition of the patient is unsatisfactory, the union of the fragments may be prevented and "ununited fractures" result. The ends of the fragments in these cases become rounded by absorption of the sharp edges, forming false joints (*pseudarthroses*).

Hypertrophy.

Local or general hypertrophy of bone may be found. *Local hypertrophies* may occur in consequence of increased strain upon certain parts of a bone, either directly or through the muscles. In muscular individuals hypertrophy of this kind is frequently seen at points of attachment of the muscles. In cases of injury or incapacity of one of the limbs the other may show hypertrophy.

Giant growth of certain bones, or of the entire skeleton, may be observed. Local hypertrophy of this kind, dating from childhood, is especially common in the upper extremities, and is frequently unilateral. It may be observed as a bilateral condition in the fingers. Complete giant growth usually begins about the age of puberty. The individual, previously developed as others, begins to grow abnormally until an excessive size is reached. The bones are not only very large, but often markedly thickened and irregular.

Acromegaly is an allied condition in which giant growth of the hands and feet, forearms and legs, and parts of the face, notably the lower jaw and bridge of the nose, is observed. A certain amount of hyperplasia of the soft tissues in the affected region accompanies this change. The etiology of this affection is still unsettled. Hyperplastic conditions, tumors, and other diseases of the hypophysis cerebri have been met with in a considerable proportion of the cases. In some of the skeletons of giants investigated with regard to this point enlargement of the sella turcica has been found, and this evidences the occurrence of enlargement of the pituitary body in some, at least, of such persons. The exact relation between pituitary disease and bony hypertrophies remains obscure.

CIRCULATORY DISTURBANCES.

Hyperemia is normal during the development of bone, or may accompany inflammatory disturbances of the neighboring parts. The marrow becomes more or less light- or dark-red in color, and the periosteal vessels may be injected. The entire bone may have a pink or reddish color.

Thrombosis may occur in the blood-vessels of the marrow.

Hemorrhage beneath the periosteum and in the marrow is comparatively common. It may result from traumatic causes or from scorbutic or purpuric conditions, as well as from inflammatory affections of the parts involved. Considerable subperiosteal hemorrhages are found in cases of infantile scurvy. The separation of the periosteum from the bone may lead to necrosis of the superficial layers of the bone. A similar accumulation of blood beneath the periosteum is that found over the bones of the skull in the new-born—the *cephalohematoma*. This results from the traumatism of labor. Large accumulations of blood of this nature may be absorbed or may undergo suppuration.

Hemorrhage into the substance of bone may accompany other diseases affecting it, such as caries, tumors, and the like.

INFLAMMATIONS.

Periostitis.

Definition.—Periostitis, or inflammation of the periosteum, may be of various forms, and may lead to different results. Sometimes the evidences of inflammation are very apparent; in other cases the disease appears in the form of a chronic productive process, leading to overgrowth.

Etiology.—Periostitis may be the result of traumatism, with or without the establishment of a communicating wound. In the latter case the injury provides an area of lessened resistance, which may subsequently become infected. In the former case the infection is direct, coming from the outside. Hematogenous infection without local injury is frequently observed. Infective periostitis may result from extension of an inflammation situated near the bones or from osteomyelitis. In all forms of bone-disease more or less local periostitis occurs as a complication. In some cases the etiology is obscure, as in the periostitis which occurs during pregnancy and leads to the formation of osteophytes.

Pathologic Anatomy.—We may distinguish simple, suppurative, and ossifying periostitis.

Simple Periostitis.—The membrane becomes swollen, red, and sometimes infiltrated with blood. Microscopically there are round-cell infiltration and proliferation of the periosteal tissue. If the process has been extensive, and the irritation long con-

tinued, a termination in fibroid thickening may be observed. This is not unusual in cases of fractures.

Purulent Periostitis.—The disease may be circumscribed or diffuse. There are marked swelling and cellular infiltration, particularly in the deeper layers, and abscess-formation results. Separation of the periosteum from the bone ensues, and may lead to local interruption of the circulation between the periosteum and the bone, and consequent superficial necrosis of the bone with exfoliation results. In the diffuse form of periostitis widespread areas of the periosteum may be quickly involved and rapid destruction takes place. In these cases a considerable inflammation of the surrounding tissues is customary. In all instances there is a tendency to burrowing of pus toward the surface, and its eventual discharge. The retention of necrotic portions of the bone may lead to continued suppuration, but with removal of the dead portions healing usually occurs. Ostitis and osteomyelitis are very frequent results of periostitis; on the other hand, they may be in certain cases the original cause.

Ossifying periostitis leads to the formation of bony excrescences, exostoses, or osteophytes. There is first a proliferation of the osteogenetic layer of the periosteum, then partial ossification, and finally complete bone-formation with firm attachment to the underlying bone. These changes may be circumscribed or diffuse, and cause irregular elevations or general thickening of the bone. Occasionally the surrounding connective tissues are implicated (*parostitis*). Ossifying periostitis may occur in the vicinity of joints affected with chronic arthritis. It may occur as a result of diseases of bones attended with considerable destruction, such as tumors, tuberculosis, etc. Occasionally the causes are entirely obscure. An interesting form is that which occurs in the bones of the hands and feet, forearms, and legs in tuberculosis of the lungs and empyema, or more rarely in other diseases; to this the term *hypertrophic osteo-arthropathy* has been applied. This is a form of osteoperiostitis of ossifying type, and it seems to be due to the action of circulating toxins developed in the diseases with which it is associated.

Associated Conditions and Results.—The conditions met with in the adjacent bones and other parts have been referred to. General infection and intoxication may follow upon the suppurative cases, and death may then occur from septicopyemia. Permanent thickening of the bone may result in any case, or resolution may be practically complete.

Osteomyelitis and Ostitis.

Definition.—Acute osteomyelitis and ostitis are usually combined, and occur as an inflammatory condition affecting the mar-

row and its extensions into the communicating canals of the bone. The lamellar substance of the bone is only secondarily involved.

Etiology.—Osteomyelitis is an infective disease resulting from hematogenous infection in the course of various diseases, from local infections in cases of traumatism (fracture, amputation), or from periostitis. Various micro-organisms, including staphylococci, streptococci, typhoid bacilli, and the Bacillus coli communis, have been discovered.

FIG. 338.—Necrosis of femur, the result of acute osteomyelitis (Warren).

Pathologic Anatomy.—The marrow first becomes red and edematous, then cellular infiltration and proliferation are superadded, and finally collections of pus or diffuse purulent transformation follow. The surrounding bone is involved, becoming more or less infiltrated, softening, and not rarely undergoing necrosis (Fig. 338). Small or large sequestra may be formed, or the bone may necrose completely. Periostitis is generally associated, and the tissues around the bone are usually infiltrated and suffer suppurative or necrotic changes. Hypertrophic changes may occur in the periosteum and superficial layers of bone, causing a bony encasement of central sequestra. In such instances a suppurating sinus, extending from the bone to the surface, usually remains.

Associated Conditions.—Implication of the neighboring parts is habitual—deep-seated abscesses, arthritis, etc. General infection is usually the final result, and commonly leads to a fatal end. Marked changes in the blood have been observed—leukocytosis, large proportions of large mononuclear cells, myelocytes.

Chronic Ostitis.

Chronic inflammatory processes are more apt to involve the bone than the marrow, though the beginning of the disease may be frequently in the latter situation. It may be suppurative, degenerative, or hypertrophic in character.

Etiology.—Chronic ostitis may follow osteomyelitis and necrosis, necrotic sequestra keeping up a constant irritation. In

these cases the disease is primarily infective. The chronic inflammations of bone due to tuberculosis and syphilis have special characters, which will be described below. In many cases the cause of chronic ostitis is obscure, though probably circulating toxic substances are the specific factors. Direct traumatism, periostitis, or other inflammatory diseases surrounding the bone may be the immediate causes.

Pathologic Anatomy.—In the necrotic and suppurative form, following osteomyelitis, there is more or less softening of the bony substance by absorption of the calcareous matter, and at the same time proliferation, in the form of granulation-tissue, of the cellular elements of the marrow and its prolongations within the Haversian channels. Localized abscesses may be formed, or infiltration of pus in various directions with increasing necrosis of the intervening bone may occur.

The degenerative form of ostitis is a variety in which the calcareous matter is absorbed and the bone thus rendered more soft and porous. The term *inflammatory osteoporosis* is applied to this. In the process of absorption there are formed upon the outer and inner surfaces of the bone, or within its substance, areas of erosion, hollow spaces or indentations, showing bone-corpuscles and giant-cells lying upon the eroded bony tissue. These depressions are the so-called Howship's lacunæ. The giant-cells, which are active in the absorptive process, have been termed *osteoclasts*, and are identical with the osteoblasts or osteoplaxes of developing bone. Simultaneously with this absorption of the lamellæ of bone there is proliferation of the marrow-substance in the eroded areas, and at the same time there may be increased vascularization of this intervening tissue. Perforations are frequently established through the lamellæ by the penetration of new-formed blood-vessels, so that neighboring excavated areas communicate. This form of inflammation of the bone is frequent in the neighborhood of necrotic areas or osteomyelitic collections of pus, and plays a part in the pathologic processes of osteomalacia and other bone-diseases. It is rarely an independent condition.

The hypertrophic form of chronic inflammation leads to increased density of the bone, to which the term *condensing ostitis*, or *osteosclerosis*, is applicable. It may occur as a reactive process surrounding areas of osteoporosis or other local diseases of the bone, or in association with ossifying periostitis. Occasionally it occurs in certain bones or parts of bones without local or well-ascertained general causes. Such cases are met with in syphilitic persons. The anatomical changes consist in the deposition of increased quantities of bony tissue by the same processes as are operative in normal bone-formation.

The disease designated as *leontiasis ossium* is a form of osteosclerosis affecting the bones of the head and face, and causing

irregular thickening and enlargement of these bones. The cause of this condition is obscure.

HYPOPLASIA AND ATROPHY.

Hypoplasia, or the lack of development of bones, may occur as a local or general condition. Local hypoplasia may be due to injuries or diseases which render a part of the body useless. General hypoplasia is found in cretins and dwarfs.

True atrophy of the bones may involve an entire bone or only portions of it. General atrophy of the whole or of parts of a bone occurs as a result of inactivity or want of use, as in cases of palsy, chronic rheumatism, and the like. The implication of certain parts of the nervous system (trophic centers) is particularly important, as the atrophy resulting in such cases is much more extensive than that occurring in cases of similar inactivity from other causes.

Partial atrophy of the bone may be due to pressure by aneurysms, tumors, and the like. In these cases there is gradual absorption of bony substance, and the process is really one of inflammatory osteoporosis.

General Atrophy.—Absorption of the bony substance, with resulting osteoporosis, may occur in marasmic individuals, particularly in seniles. In these cases it is held by most authorities that the pathologic condition is dependent upon the failure of replacement of bone to make up for the normal absorption constantly taking place. In these cases the bone becomes extremely fragile from the increase of its marrow-spaces and its general porosity. This condition of fragility is termed *fragilitas ossium*, or *osteopsathyrosis*. Occasionally this condition of fragility is met with as an idiopathic disease, without definitely discoverable causation and without evident disease of the bones. Such cases have been found to occur in certain families through several generations.

DEGENERATIVE CONDITIONS.

Caries.

Caries is a term applied to the molecular destruction of bone, corresponding to ulceration of the soft parts. It may be associated with osteomyelitis, or with necrosis due to traumatism or various infective conditions. The changes consist in progressive softening and crumbling of the bone, with eventual destruction of more or less considerable areas. Caries is especially frequent as a part of tuberculosis of the bones, and will be described in connection with that disease.

Necrosis.

Definition.—Necrosis is a term applied to the death of a small or large portion of bone in mass.

Etiology.—Among the causes are the various acute or chronic diseases of the periosteum, bone-marrow, and adjacent bone. In cases of purulent periostitis the separation of the periosteum from the underlying bone leads to interruption of blood-supply and superficial necrosis. Similar results occur in cases of osteomyelitis. Necrosis of the bone may also occur in consequence of embolic obstruction of the blood-vessels.

Pathologic Anatomy.—Necrosis may be *partial* or *total*, and may occur in the center of the bone or at the periphery. The dead portion of the bone, termed *sequestrum*, presents itself as an irregular, more or less eroded fragment, almost completely or completely separated from the remaining structure. The separation occurs by the process of demarcation, as in necrosis of the soft parts. This line consists of an area of absorption of the calcareous matter and proliferation of the cellular elements. The necrotic portion, or sequestrum, acts as a foreign body, and by its continued irritation keeps up a suppurative inflammation of the surrounding tissues. Fistulous communication with the exterior is usually observed. If the sequestrum is peripheral and has been discharged, the periosteum or the bone may replace the lost tissue by regeneration. If the fragment is large or centrally placed, discharge is impossible and suppurative inflammation continues, sometimes for years. In these cases considerable hyperplastic material may be deposited over and around the sequestrum, and thus irregular thickening of the bone may be produced.

A peculiar form of necrosis is that occurring in consequence of chronic phosphorus-poisoning. It is met with in persons engaged in the manufacture of phosphorus-matches, and affects the maxillary bone. The existence of carious teeth aids in the development of this form of necrosis, probably by admitting micro-organisms which infect the bone already altered by the poison. The process begins in the periosteal and subperiosteal portions of the bone, and ends in more or less complete necrosis.

Associated Conditions.—Long-standing necrosis causes great deterioration of the general health, particularly in cases in which suppurating sinuses are formed. Systemic infections may follow and amyloid degeneration of various organs may occur.

Osteomalacia.

Definition.—This is probably a general disease leading to absorption of the bone-salts and to other changes in the bone, which cause extreme flexibility.

Etiology.—The causes of osteomalacia are still obscure. It is a disease occurring with especial frequency in puerperal women, but it may occur in men and in non-puerperal women. A number of theories have been offered to explain the disease, but none of them has been established. In some respects it seems not unlikely that it is a trophoneurosis. It is particularly frequent in certain regions (endemic), while in others it occurs very rarely (sporadic).

Pathologic Anatomy.—The changes in the bone lead to various deformities and changes of appearance. Distortions, bends, and even fractures are observed in the long bones, and deformities due to abnormal curvatures of the spine are not infrequent. The pelvis shows peculiar changes which may prove very troublesome during labor. The characteristic change is a beaked condition, due to displacement forward of the pubes and a lateral indentation. This gives a triangular form to the outlet of the pelvis or superior strait. The bone-marrow is often quite red, and the periosteum in the neighborhood of bends or fractures may be thickened by cellular proliferation. The minute structure of the bone in osteomalacia shows a more or less pronounced absorption of calcareous matter, but the normal lamellar arrangement of the bone may be preserved. In the region of bends and fractures osteoid tissue of irregular structure, with bony corpuscles of considerable size, may be observed; while in other situations the regular lamellar arrangement and the ordinary small-sized bone-corpuscles are seen. Irregular areas of homogeneous or granular appearance may be interspersed within the normal osseous tissues. The line of demarcation between such abnormal non-calcareous portions and the unaltered bone may be either sharply drawn or diffuse.

Associated Conditions.—Patients suffering from osteomalacia are usually greatly reduced or cachectic, and frequently perish with terminal pneumonia. Some cases end in recovery by restitution of the bone. It has been claimed that there is evidence in all cases of puerperal women of some bony absorption, and osteomalacia, therefore, would seem to be but an exaggeration of normal conditions. Normally the slight bony changes are corrected after the puerperal period is passed.

INFECTIOUS DISEASES.

Tuberculosis.

Tuberculosis may occur in bones in several forms. Miliary tubercles may be found in the bone-marrow in the course of general miliary tuberculosis, and local tuberculous disease of the periosteum may be met with. The most frequent and most important form of tuberculosis is tuberculous ostitis with caries.

Etiology.—The involvement of the bones is nearly always secondary, the first manifestations of tuberculosis occurring in other structures, notably the lymphatic glands and the lungs. The disease of the bones may be due to direct extension or to hematogenous infection. Not rarely the joints are first involved and the neighboring bones only secondarily.

Traumatic influences are of importance in determining the situation of hematogenous tuberculosis. The traumatism causes circulatory disturbances in the bone, and thus produces a suitable soil for the bacilli to find lodgement. Bone-tuberculosis is most frequent in early life; it may actually begin *in utero.*

Pathologic Anatomy.—The tuberculous lesion of bone first presents itself as an area of grayish color, with congestive reddening of the parts around and intense injection of the bone-marrow in its vicinity. Subsequently there are rapid cheesy change and

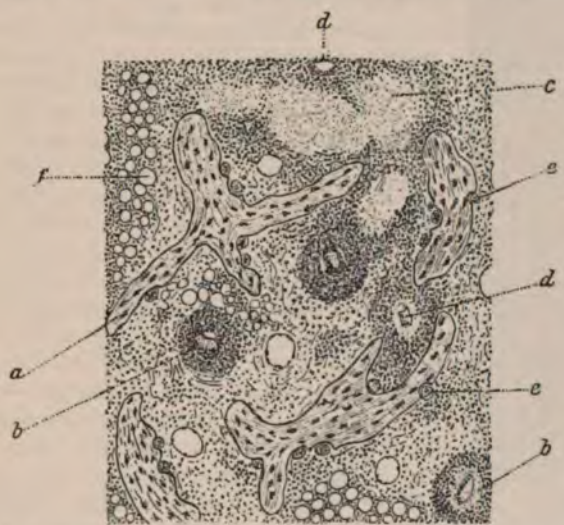

FIG. 339.—Tuberculous caries of one of the bones of the foot: *a*, bony trabecula; *b*, tubercle with caseous center; *c*, caseation in a focus of tuberculous tissue; *d*, giant-cells in tubercles; *e*, osteoclasts; *f*, fatty marrow (Kaufmann).

more or less softening of the area of inflammation. Microscopically, tubercles in various stages of degeneration are discovered, and in addition areas of diffuse tuberculous granulation-tissue and caseous degeneration (Fig. 339). At the same time extension occurs at the periphery and new foci are established. The entire diseased area may be separated from the uninvolved bone as a sequestrum, but more frequently there is gradual carious softening, with formation of semifluid, cheesy material containing gritty particles of bone or calcareous matter. Complete softening leads to the for-

mation of a "tuberculous abscess" (Fig. 340). In these cases a more or less irregular cavity is formed within the bone, the wall of the cavity being covered with a pyogenic membrane developed from the marrow and its extensions into the Haversian canals. The contents of the abscess are puriform or cheesy. The process tends to extend to neighboring parts, particularly to the joints. When the abscess has penetrated the encasing bone it may spread within the soft parts, thus forming large tuberculous abscesses (so-called *cold abscesses*). These may burrow along the planes of the tissues to considerable distances from the point of formation, presenting at the surface of the body in some favorable situation, as, for example, in the groin, in psoas-abscesses.

FIG. 340.—Tuberculous "abscess" in the lower end of the humerus (modified from Bollinger).

Reactive changes may occur locally, and more or less restitution may take place. Complete encapsulation of a small focus may occur by the formation of a surrounding zone of granulation-tissue and cicatrization, or by new-formation of bone occurring after the activity of the tuberculous process has been arrested. When adjacent portions of articulating bones are involved the integrity of the articulation is disturbed, and subsequently ankylosis may be established by the formation of exostoses and their union.

Seats and Associated Conditions.—Among the bones more frequently affected are the vertebræ, the long bones, particularly the femur, and parts of the skull. In the vertebræ the bodies are generally affected, and angulation or distortion of the spine results (Pott's disease). The cold abscesses formed in these cases may burrow considerable distances, pointing far below the place of origin. Those springing from the cervical vertebræ may point beneath the mucous membrane of the pharynx or esophagus, or anteriorly in the neck above the clavicle or shoulder. The abscesses formed in tuberculous caries of the dorsal vertebræ may point under Poupart's ligament. Tuberculous disease of the petrous portion of the temporal bone is not infrequent following tuberculous disease of the ear; it is important as a possible cause of tuberculous meningitis. Tuberculosis of the head of the femur and of the hip-joint is one of the most frequent forms of surgical disease in chil-

dren. The phalanges are sometimes involved in early childhood by a curious form of tuberculosis, in which the shaft of the bone increases in size by gradual absorption and tuberculous softening within and deposition of new bone from the periosteum without.

Syphilis.

Syphilitic disease of bones may appear in various forms. Allusion has already been made to the condensation of the bones, or osteosclerosis, in this disease. Syphilis may also occur in the periosteum as a nodular periostitis, or in the substance of the bone in the form of degenerating gummata. Congenital syphilis gives rise to certain peculiar alterations.

Etiology.—Syphilitic changes in bone are confined almost exclusively to the tertiary period. They may occur without other luetic disease, or as concomitants of hepatic, splenic, or other visceral disorders. The disease of the bones is frequently determined by local injuries; especially is this true of the periosteal forms.

Pathologic Anatomy.—*Syphilitic periostitis* is very common upon the shin-bone, less frequent in the periosteum of other long bones. There is, first, slight swelling of the periosteum, due to multiplication of the cells. Subsequently this cellular mass undergoes gummy or mucous degeneration, and the mass presents the appearance of a small gumma. Superficial erosion, or even necrosis, of the bone may take place, and discharge of the contents may occur. Following this, hypertrophic processes in the bone and adjacent periosteum lead to the formation of bony nodes. These nodes may, however, be formed without the occurrence of softening and discharge from the periosteal lesion, the process in this case being one of simple ossifying periostitis. *Gummata* of the bones generally begin in the deeper layers of the periosteum, but tend to involve the bone more extensively than the form just described. The gummatous infiltration and proliferation occur along the blood-vessels of the periosteum and extend into the substance of the bone. Considerable areas may thus be implicated. The bone itself is absorbed, or may undergo rapid caries or necrosis. Around the area of syphilitic change may occur a zone of reactive hyperplasia of the bone and periosteum. The gummata themselves become cheesy or undergo mucoid degeneration, and eventually may discharge upon the surface. Syphilitic gummata are most frequent in the bones of the head, tibia, and sternum.

Occasionally gummata arise in the marrow of the bones instead of the periosteum.

Congenital Syphilis.—The bony changes of congenital syphilis are quite characteristic. The alterations occur at the junction of the epiphyses with the diaphyses of the long bones. Longitudinal

section through these parts shows the line of junction as a bluish-white or yellowish-white irregular zone about 2 or 3 mm. in thickness (Plate 7). In more advanced stages this line becomes thicker and more yellow. The minute changes consist in proliferation of the cartilage-cells and subsequent fatty degeneration. Microscopically the proliferated cellular elements, fatty cells, and granular detritus are conspicuous features. The epiphyses may be completely separated from the shaft.

Associated Conditions.—Involvement of the neighboring parts is not infrequently seen in syphilitic diseases of the bones; thus there may be gummatous infiltration of the superficial tissues with syphilis of the bones of the extremities, while in the case of skull-bones extension inward may lead to involvement of the dura and brain. When the process occurs about the foramina of exit of nerves the sheaths of the latter may become involved. Gummata of the sternum sometimes lead to the formation of retrosternal collections of puriform material. Amyloid degeneration of various organs frequently follows bone-syphilis.

Lepra.

Changes may occur in the bones in cases of mutilating leprosy, or more rarely in nervous lepra. Among these changes are ostitis and osteomyelitis; considerable destruction of the bones may be produced.

TUMORS.

Exostoses are frequently met with in connection with definite disease of the bones and joints, or as more or less idiopathic outgrowths (Fig. 44). They may be *cartilaginous* or *fibrous* in character, but subsequently may become *osseous*. They present themselves as flat, rounded elevations, or as more or less irregular outgrowths. Sometimes they are multiple and involve a number of bones of the skeleton. In such cases, particularly, heredity has been claimed as an important cause.

Fibroma, lipoma, myxoma, and **angioma** may be mentioned among the true tumors as benign growths occasionally met with. They arise most frequently from the periosteum.

Chondroma and **osteoma** are more common than these, and involve any part of the bone (Figs. 42 and 45).

Sarcoma.—The most important of the primary tumors of bone is sarcoma. This may originate in the periosteum, bone-marrow, or the bone itself. It may be spindle-celled, or less frequently round-celled or alveolar. Sometimes it is melanotic. The giant-cell sarcoma, or osteosarcoma, is particularly important. It is most frequently met with in the lower jaw, beginning within the bone and causing a more or less rapid swelling. The tumor is surrounded by a shell of bone, which, however, sooner or later

PLATE 7.

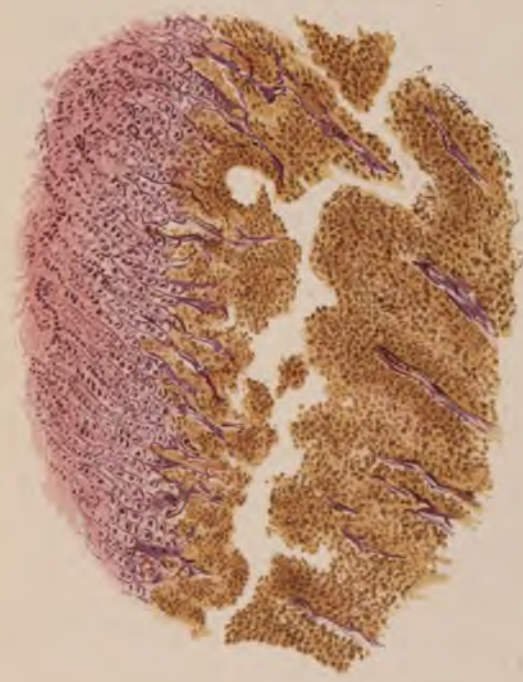

Epiphyseal junction in congenital syphilis; specimen stained with hematoxylin.

becomes perforated when the new growth spreads to the neighboring parts (Fig. 58). In all forms of sarcoma there is absorption of the bone-substance in the vicinity. A form of sarcoma springing from the periosteum is described under the name of *osteoid sarcoma.* This tumor consists of fibromatous or round-celled sarcomatous tissue in which osteoid elements are irregularly embedded. More or less calcification and bone-formation are observed. The tumor may be quite soft or very hard; it tends to spread to the neighboring soft parts, and may give rise to metastasis. It is particularly frequent at the ends of the long bones.

Secondary sarcoma of the bone-marrow is not rare in general sarcomatosis.

Myeloma.—This term has been applied to a form of multiple primary tumor of the bone-marrow allied to the lymphatic growths of leukemia and Hodgkin's disease. The term *lymphadenia ossea* has also been given to it. Probably a number of distinct conditions (some of them secondary tumors) have been described under these names.

Chloroma is a form of sarcoma, having a greenish or yellowish color, that is met with in the periosteum, especially about the orbits and other parts of the skull.

Primary carcinoma of the bones has been observed in a few cases. It can only be explained upon the assumption that islets of epithelial tissue have been deposited in the bone by faulty development. Most cases, however, described as primary carcinoma were probably in reality alveolar sarcomata.

Secondary carcinoma of the bones is not rarely met with, especially in cases of cancer of the breast, thyroid gland, and prostate. The secondary nodules may occupy the periosteum or the bone-marrow. The bone becomes exceedingly fragile, and fractures are not infrequent.

Cysts and Parasites.—Cystic transformation of myxomata and of sarcomata may be met with. Occasionally dermoid cysts are observed. Among the parasitic diseases Cysticercus cellulosæ has been described in a number of instances.

CHAPTER X.

DISEASES OF THE JOINTS.

Luxation.—The most frequent injury of joints is that known as luxation, in which the relations of articulating bones are disturbed. In these cases the ligaments and other soft tissues around the joints are more or less torn, and in consequence become inflamed. If the luxation is reduced, this inflammation subsides quickly, and frequently normal conditions are restored. If the luxation persists, various secondary changes may occur. Ankylosis in abnormal positions may take place by the formation of fibrous adhesions, or in more favorable cases a false joint may be established. In the latter cases local atrophy takes place in one of the bones, forming a depression into which the end of the other fits. Later, ossifying periostitis produces an elevation around the depression of the socket, and thus a well-formed joint may be produced.

Ankylosis is the term applied to the condition in which the normal movability between articulating bones is prevented by interosseous attachments. Pathologically, ankylosis may be *fibrous*, *cartilaginous*, or bony. All of these forms are met with after chronic inflammatory conditions of the joints.

DISTORTIONS OF JOINTS.

Distorted conditions of the joints may be due to contractions of the muscles and tendons, or to cicatricial tissue in the neighborhood of the articulation. Changes in the joints themselves may be present as primary or as secondary conditions. Among the more important of such deformities of joints are the various sorts of **club-foot**: *pes varus*, the sole of the foot turned in; *pes valgus*, the sole of the foot turned out; *pes equinus*, the foot extended and supported upon the anterior ends of the metatarsal bones; *pes calcaneus*, the foot flexed and resting on the heel. Combinations of these conditions are frequently met with. At the knee-joint are found: *genu valgum*, in which the knees are bent in (knock-knee), and *genu varum*, in which the knees are bent out (bow-legs).

CIRCULATORY DISTURBANCES.

Hyperemia of the joints occurs as a part of acute inflammations, and involves the synovial membranes particularly. The synovial fluid may be increased in quantity.

Hemorrhage into the joint may result from traumatic causes or from inflammatory conditions, particularly in the course of hem-

orrhagic diseases, notably scurvy and hemophilia. The blood may remain fluid for a long time, and the joint not rarely has the appearance of chronic arthritis with effusion. Later, resorption of the blood takes place.

Dropsy of the joints occurs in the course of acute and chronic inflammations.

INFLAMMATIONS.

Acute arthritis may be traumatic or hematogenous, or in other cases is secondary to disease in the vicinity. Hematogenous arthritis may occur in the course of various infectious diseases, such as scarlet fever, small-pox, pyemia, etc. In the same group must be considered acute articular rheumatism, which is doubtless an infection conveyed to the joint through the blood.

Pathologic Anatomy.—Various forms may be distinguished, such as the *dry* or *fibrinous*, the *serous*, and the *seropurulent*. In all cases there is, first, a deep congestion of the synovial membrane. The ligaments and the cartilage are more or less implicated at the same time. The terms synovitis, implying involvement of the synovial membrane, and panarthritis, implying general involvement, may be applied. In the dry or fibrinous form there is a deposit of fibrin upon the surface, with or without serous exudation. In the genuine serous form the exudation is purely serous, but more commonly seropurulent liquid is observed. Entirely purulent exudate is sometimes formed (empyema of the joints).

Results.—In the milder cases complete resolution may take place without destruction of the tissues of the joint. In the more serious cases there is inflammation of the articulating cartilages, with consequent ulceration or caries, or even considerable necrosis, of the cartilage. The underlying bone may be laid bare, and ostitis or osteomyelitis may result. Sometimes discharge of purulent material into the surrounding tissues occurs, and fistulous communications with the exterior may be established. These processes may lead to extensive disorganization of the joints, with luxations and, in later stages, ankylosis.

Associated Conditions.—General systemic infection may follow these acute inflammations of the joints.

Chronic arthritis may be due to a variety of causes. It may follow the acute forms already described or may be primarily chronic. Among the more important causes are traumatism and certain infections. It occurs in the course of gout and in certain nervous diseases, probably as the result of disturbance of the trophic mechanism. Chronic arthritis of the aged has perhaps a similar causation, and rheumatoid arthritis is nearly allied.

Pathologic Anatomy.—A variety of forms may be distinguished. The same etiologic factors may, however, give rise to one or another in individual cases.

Chronic serous arthritis, or hydrops articulorum, is frequently due to repeated acute arthritis. The joint is filled with thin synovia, and the synovial membrane is somewhat thickened. The surface of the joint may be more or less covered with an injected synovial membrane (*synovitis pannosa*). The knee-joint is most frequently involved.

Chronic purulent arthritis is always infectious, and is usually the outcome of an acute seropurulent or purulent arthritis. The conditions met with have already been described. It terminates in more or less extensive disorganization of the joint, and in favorable cases in fibrous ankylosis (Fig. 341).

FIG. 341.—Fibrous ankylosis, due to chronic purulent arthritis.

Arthritis deformans, or *rheumatoid arthritis*, occurs in persons past middle age, but sometimes in young persons, and even in childhood. Constitutional depression and exposure seem in some way to predispose. There are, first, alterations in the cartilages of the joints, consisting of softening and ulceration or erosion, which make the surface irregular and rough. At the same time some hyperplasia of the cartilage-cells takes place, but the hyperplastic elements subsequently undergo degeneration, and are absorbed. In this way the cartilage is gradually reduced and the ends of the bone laid bare. The synovial membrane and ligaments at the same time become thickened by hyperplasia. Subsequently the articulating end of the bone is involved. There is, first, absorption, and secondarily proliferative changes at the periphery of the articulation, in the form of exostoses or osteophytes. The joint is considerably deformed and thickened. Subluxations are common, and the deformity leads to immobility of the joint, or ankylosis. This form of arthritis is particularly common in the metacarpo-phalangeal joints of the hand, and in the other small joints of the hands and feet (Fig. 342). Later the knee, elbow, and vertebral articulations may be involved.

Chronic dry arthritis with ulceration, or senile arthritis, is particularly common in the hip-joint (*malum coxæ senile*). There is gradual absorption of the cartilages and of the exposed surfaces of the bone. Subsequently the surrounding parts of the bone undergo sclerosis and hypoplasia. The changes are similar to those of rheumatoid arthritis, but are more slowly developed.

FIG. 342.—Rheumatoid arthritis, showing extensive deformity of the hands.

Neuropathic arthritis is met with in the course of spinal diseases, such as locomotor ataxia and syringomyelia (Fig. 343). It re-

FIG. 343.—Neuropathic arthritis of the knee in a case of locomotor ataxia.

sembles the forms just described, is slowly developed, and is usually quite painless, suggesting a purely degenerative or trophic disorder.

Gouty Arthritis.—Gout is a constitutional disease with a tendency to a peculiar form of arthritis. The latter consists in the deposit of crystals of urate of sodium and calcium in the cartilage-cells and intercellular substance of the articulations, and in more advanced cases in the connective tissue of the joints and the tissues round the joints (Fig. 344). These crystalline deposits occur

FIG. 344.—Deposit of crystals of urate of sodium in an articular cartilage (Lancereaux).

in definite attacks, as a rule, each attack (*gouty paroxysm*) being marked by inflammatory processes in the joint. Hyperemia of the synovial membrane, with serous effusions and with sometimes more evident inflammatory manifestations (hyperplasia of the cartilage-cells and round-cell infiltration), is observed during the paroxysms, and by their repetition chronic changes in the joint are produced. The cartilages may become more or less eroded, and even carious changes and suppuration may take place. The joints most frequently involved are the small joints of the hands and feet, notably the metatarso-phalangeal joint of the great toe. The larger articulations are less commonly involved, and usually after the smaller joints.

Associated Conditions.—The pathology of gout is by no means confined to the changes in the joints. The disease is a general one, and pathologic changes are found in various organs. There is a tendency to thickening of the blood-vessels, to atheroma, and to sclerotic changes in the kidney, liver, and heart; and uratic deposits may occur in the organs named or in the subcutaneous tissue or superficial cartilages, such as those of the ear and nose (*gouty tophi*). Concretions or calculi are frequently formed in the kidney or bladder.

INFECTIOUS DISEASES.

Tuberculosis.

Tuberculosis, when primary in the joints, usually begins in the synovial membrane. Frequently it is secondary to tuberculosis of the adjacent bone. In such cases any part of the joint may be first involved.

Etiology.—Tuberculous arthritis is most frequent in childhood, and occurs in those predisposed by heredity. The immediate determining cause may be traumatism, this serving to localize the disease in a joint rendered peculiarly susceptible. Tuberculous arthritis is frequently secondary to scrofulous disease of the skin or glands, or to pulmonary tuberculosis, but is often primary.

Pathologic Anatomy.—The changes met with in the joints vary somewhat in different cases. In instances beginning in the synovial membrane there are formed more or less abundant, soft, spongy granulations, which may eventually fill the entire joint-cavity. These are pinkish or whitish in color, and may show gray or yellow spots or tubercles quite plainly. Later this granulation-tissue tends to degenerate, becoming mucoid or breaking down by suppurative or cheesy change. In the early stages the soft tissues of the joint are considerably inflamed and edematous; later they may show ulcerative or necrotic change, and similar alteration may occur in the articular cartilages. Puriform softening of the granulations and the tissues of the joint may lead to the development of *cold abscesses* within the joint, and the latter may eventually burrow to the exterior. In cases progressing unfavorably the joint is greatly disorganized by the advancing necrotic changes. The abnormal productions are either discharged or inspissated, and ankylosis of the joint by fibrous adhesions takes place.

The external appearances of tuberculous joints are often quite distinctive. The joint is swollen and boggy, or somewhat elastic to the touch, and usually more or less distorted from subluxation. There is little evidence of acute inflammation. In cases terminating in ankylosis the bones are generally left in faulty position in consequence of the formation of adhesions and the irregular contractions of muscles.

Secondary Disorders.—Long-standing tuberculosis of the joints occasions profound disturbances of the general health, and sometimes causes definite disease, such as amyloid degeneration of various organs. Disseminated tuberculosis rarely results.

Syphilis.

Syphilitic disease of the joints may occur in hereditary lues. The cartilages of the joints are eroded, and thickening of the ligaments with puriform exudation into the joint is observed. The phalangeal articulations are most frequently involved. In later life gummata in the neighborhood of the joints may invade the latter by contiguity.

TUMORS.

Hyperplastic conditions are met with in the synovial fringes of the joints in association with arthritis or independent of such.

These hyperplasias may take the form of *fibrous growths*, or they may become *lipomatous*. An interesting form of new growth is seen in the so-called rice-bodies. These are small fibrous or cartilaginous bodies, up to the size of a small nut, which are entirely free in the joint or attached by a fine pedicle to the synovial membrane. They are formed from the synovial fringes, and probably result from injury in most cases. The joints may be secondarily involved in various forms of bony tumors.

THE TENDON-SHEATHS AND BURSÆ.

Inflammations of the sheaths of tendons (*tenosynovitis*) and of the bursæ (*bursitis*) occur under similar circumstances and in similar forms as inflammations of the joints. A form of chronic bursitis with dropsical effusion frequently occurs in the bursa beneath the patella from chronic irritation (housemaid's knee), and in the bursa at the joint of the elbow (miner's elbow). These conditions are analogous to hydrops articulorum.

Ganglion is a condition of the tendon-sheaths of some clinical interest. It presents itself as a rounded cystic nodule, most frequently upon the back of the hands and wrists. Distinct fluctuation may be discovered, or the cyst may be so dense that it feels stony hard. The ganglion results from a localized dropsical condition of the sheath of the tendons, with frequently a lateral hernious projection. A similar condition is sometimes caused by projection of the synovial membrane of the joints.

CHAPTER XI.

DISEASES OF THE VOLUNTARY MUSCLES.

Congenital malformations are occasionally met with, such as absence of a part or of an entire muscle.

HYPERTROPHY.

Hypertrophy is frequently produced by athletic exercise or laborious occupations. This affects the parts brought into play, and is proportioned to the amount of work and the constitution or condition of the individual. The muscle-fibers increase in thickness and probably also in number.

Sometimes muscular hypertrophy is met with in cases in which no adequate cause is discoverable. Thus in local or general giant growths the muscles may be involved with other parts.

Pseudohypertrophy will be discussed among the degenerative conditions.

CIRCULATORY DISTURBANCES.

Anemia of the muscles may be part of a local or general anemia; it is often quite insignificant in comparison with anemia of other parts. In some of the general anemias the muscles may present a dark appearance, due to degenerative conditions.

Hyperemia is physiologic during and after exercise. It occurs as an active process in association with inflammatory conditions and as a passive congestion in cases of vascular stasis.

Hemorrhages may be traumatic, or may result from rupture of the vessels in consequence of inordinate blood-pressure or local degeneration of the vessel-walls and the surrounding muscle-fibers. Among the conditions in which hemorrhage takes place are tetanus and other convulsive disorders, fevers, and hemorrhagic diseases, such as scurvy, hemophilia, and septic diseases. The hemorrhages may occur in the form of small extravasations between the fibers, or of more extensive infiltrations in the intermuscular planes. In cases of traumatism, scurvy, or hemophilia, considerable blood-tumors may be formed, the muscle-fibers being pushed aside or torn apart. The blood is more or less rapidly absorbed. Pigmentation and fibrous-tissue proliferation may result.

Embolism of the arteries or **thrombosis** of the veins does not produce serious disturbances, as a rule. In cases of embolism, secondary results may follow if the embolism is infective.

INFLAMMATIONS.

Inflammation of the muscles, or **myositis,** may be acute or chronic, and may present itself in a variety of forms. Acute myositis may be local or disseminated.

Localized Acute Myositis.—This form may be due to injuries, such as contusions of the muscles or wounds communicating with them, or may be infectious in character, resulting from the direct extension of infectious diseases of the skin, subcutaneous tissues, bones, and other adjacent parts, or from embolism. A serous, a hemorrhagic, and a purulent form may be distinguished.

Serous myositis is characterized by an edematous condition of the muscle, which gives it a peculiar gelatinous appearance on section. Microscopically there is cellular infiltration of the muscle-bundles, while the muscle-fibers themselves become swollen and suffer granular degeneration or hyaline change, and sometimes vacuolation.

Hemorrhagic myositis is an intense form, and is met with in muscles adjacent to gangrenous or phlegmonous lesions, malignant pustules, and the like. Myositis occurring in scorbutic individuals is frequently of the hemorrhagic form, as is also that which occurs in consequence of the sting of venomous snakes or other animals.

The muscle becomes more or less tensely swollen, and on section the hemorrhagic infiltration is plainly visible as a diffuse process or as localized areas of hemorrhage.

Suppurative myositis may be circumscribed or diffuse. Circumscribed myositis, or abscess of the muscle, may result from entrance of micro-organisms through the lymphatic or vascular circulation, or it may be due to traumatism, with communications from the surface. Occasionally suppurative inflammation occurs in an obscure manner, when the term cryptogenetic myositis is applicable. Distinctly metastatic abscesses may be occasioned by embolism.

In association with suppurative inflammations of the skin or subcutaneous tissues and the mucous membranes there may be seropurulent or phlegmonous myositis, with the formation of irregular abscesses. In these cases the lesion spreads by infiltration, and the muscle-fibers undergo widespread degeneration (fatty degeneration, hyaline change, and necrosis). Abscesses in the muscles extend and rupture in various directions, and may leave considerable areas of scar-formation.

Disseminated acute myositis or **polymyositis** may appear without any definite cause, sometimes in association with tuberculosis of the lungs, or as a distinctly secondary affection in association with infectious diseases, like typhoid fever, diphtheria, etc. In the primary form there may be widespread muscular disease, with swelling and tenderness of the muscles and sometimes redness and edema of the skin. The term *pseudotrichinosis* was applied from the resemblance of the appearances to those of trichinosis, and the name *dermatomyositis* has also been given this condition. Some of the conditions included under the heading *muscular rheumatism* by clinicians are doubtless instances of the kind here referred to. Examination of the muscles shows pallor of the tissue, and sometimes visible areas of degeneration. Microscopically there are cellular infiltration between the muscle-fibers and swelling, with loss of striation of the fibers themselves. More advanced degenerations of the fibers, such as granular change, coagulation-necrosis, and vacuolation, may be observed. The affected muscles lose their functional contractile power, and more or less palsy results. When affecting the muscles of the pharynx and respiration this becomes serious in predisposing to inspiration-pneumonias.

The condition described as secondary acute polymyositis is degenerative to a greater extent than inflammatory, and will be considered among the degenerations.

Chronic myositis may be suppurative in type or productive.

Chronic suppurative myositis may be the outcome of acute suppuration, and is particularly frequent in association with tuberculosis and actinomycosis.

Chronic productive myositis is characterized by the formation of connective tissue between the muscle-fibers. The fibers themselves, as a rule, undergo degenerative changes, though occasionally showing regeneration to some extent. This condition may be the termination of acute myositis, or it may occur in the vicinity of various localized diseases of the muscles or of the neighboring parts. In some cases, if not all, the primary change is degeneration of the muscle-fibers, and the interstitial or fibrous tissue is reactive in character. Some of the cases will be considered under the head of muscular atrophies. The changes that occur in the interstitial tissue of the muscles consist primarily of proliferation and round-celled infiltration. Later there is formation of firm connective tissue. Some multiplication of the muscle-nuclei and actual increase in size of the muscle-fibers may be observed. Degeneration of the muscle-fibers, however, is more prominent, and is generally in proportion to the degree of connective-tissue change. The fibers may show cloudy swelling or hyaline changes, or more complete degeneration, such as fatty degeneration, fragmentation, or vacuole-formation.

Ossifying myositis is a variety of productive myositis. It may occur in the form of bony nodules in parts subjected to constant irritation or strain, as in the case of the deltoid muscle in soldiers and the adductor muscles in horsemen. Similarly, in the vicinity of disease of the bones and periosteum, nodules may develop in the muscle. A form of more general disease, termed *myositis ossificans progressiva*, has been observed in youthful persons, without discoverable cause. It affects the muscles of the back and neck, and sometimes those of all parts of the body. The muscles are swollen, and first present inflammatory manifestations, terminating in fibrous change which finally leads to bone-formation. The osseous tissue is at first in the form of spicules or small nodules, but gradually increases to considerable proportions. The muscles themselves contract, and various deformities with pseudo-ankyloses may result. The muscles of the face, diaphragm, and heart are unaffected.

ATROPHY AND DEGENERATIONS.

Several forms of atrophy are recognized. Certain cases are dependent upon disease of the spinal cord or nerves (neuropathic form), others occur as primary diseases of muscles (myopathic form), and in another group the change is due to simple nutritional processes (simple and senile forms).

Neuropathic muscular atrophy may be the result of disease of the anterior horns of the gray matter of the cord. To the cases in which this lesion is the underlying pathologic condition the

term *progressive muscular atrophy* has been applied. The causes of this disease are obscure.

It leads to progressive atrophy of the muscles of the hands, arms, and shoulders, and less frequently of those of the body and buttocks. It usually begins in the small muscles of the hands, but sometimes affects those of the shoulders first. The muscles become pale and rather flabby. Microscopically the fibers show various forms of degeneration. Fragmentation in a longitudinal or in a transverse direction, coagulation-necrosis, and occasionally fatty degeneration of the fibers may be seen. Sometimes the fibers seem to grow smaller by a simple atrophic process (Fig. 345). Coincidently, reactive proliferation is seen in the connective

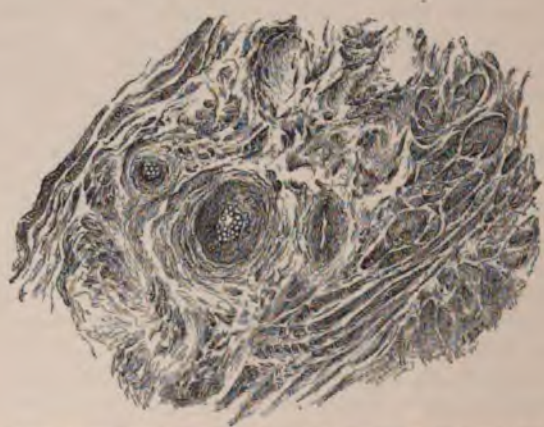

FIG. 345.—Neuropathic muscular atrophy, showing atrophy of the muscle-fibers, increase in the interfascicular fibrous tissue, and thickening of the blood-vessel walls.

tissue between fibers, and doubtless this to some extent causes further muscular degeneration. The muscle-cells themselves may proliferate quite extensively.

Secondary neuropathic muscular atrophies may occur in various spinal diseases, such as syringomyelia and in degenerations following cerebral disease. These are essentially similar in character to the primary neuropathic variety, though their clinical character is different. Section, disease, or injury of motor nerves may lead to local atrophies by separating the muscles from their trophic centers in the cord.

Myopathic muscular atrophy occurs in children and young persons, and is frequently hereditary. It begins in the buttocks, thighs, or calves, and sometimes in the shoulders. Two forms have been distinguished: the simple atrophic form and the pseudo-hypertrophic form. The anatomical changes in the former are the same as in the neuropathic variety just described.

Pseudohypertrophic Muscular Atrophy.—In this condition the muscles increase greatly in size, but are soft and flabby. The child may present the appearance of an athlete, with enormous calves and thighs, but is extremely weak and can scarcely stand. Microscopically the causation of the enlargement is found to be a considerable degree of intermuscular proliferation of connective tissue, with marked fatty infiltration. Sometimes in this form, as well as in other varieties, some actual enlargement of the muscle-fibers is observed, but this is doubtless degenerative.

Simple muscular atrophy may be senile in origin or due to lack of exercise. In these cases the muscle-fibers become smaller, and some proliferation of the connective tissue is generally present. In senile cases brown atrophy may occur, brownish pigment-particles being deposited in the atrophic fibers, especially near the nuclei.

Parenchymatous degeneration of the muscles may occur in the vicinity of inflammatory lesions, tumors, or other areas of disease. It may also occur in the course of infectious diseases in association with coagulation-necrosis. The fibers become cloudy and lose their striated appearance from the presence of minute granules. In some instances inflammatory changes in the inter-fascicular connective tissues are associated with the degeneration of the fibers. Cases of this sort may be called *secondary acute polymyositis.*

Fatty degeneration is found under the same circumstances as the above, and also in chronic cachectic diseases and in cases of poisoning with phosphorus and other "parenchyma-poisons." The muscle-fibers have a streaked or spotted, yellowish appearance, and are more or less flabby. Microscopically the fibers are seen to be filled with small oil-droplets, which obscure the striations. All parts of the fiber may become degenerated until the sarcolemma-sheath contains only a mass of fat-droplets and detritus.

Fatty infiltration may occur in association with atrophy in the condition above described—pseudohypertrophic muscular atrophy; and in various nervous diseases in which the muscles waste from disease or trophic change. A certain amount of lipomatosis may occur in general obesity.

Amyloid degeneration is rare and unimportant.

Calcification may occur in the form of ossifying myositis, and locally in scars following various local diseases—abscesses, etc.

Coagulation-necrosis, or **hyaline degeneration,** is of great clinical importance. It was first discovered by v. Zenker as one of the lesions occurring in typhoid fever. The muscle-fibers at first become granular and cloudy (*parenchymatous degeneration*), and later waxy or hyaline change occurs in streaks or

completely transforming the fibers. Transverse fragmentation is common, and gross rupture of the muscle may be met with. In the latter cases hemorrhagic infiltration, or even considerable hemorrhage (*hematoma*), may be occasioned. Reactive inflammatory change in the interstitial connective tissue is generally present. This disease occurs in the course of typhoid fever, but also in various other febrile and infectious conditions. It is most common in the abdominal muscles (rectus abdominis), in certain muscles of the extremities, and in the heart. The latter situation is, of course, of greatest significance (see Diseases of the Heart).

INFECTIOUS DISEASES.

Tuberculosis may occur in the form of cold abscesses in association with tuberculous disease of bone, or less frequently of the lymphatic glands or other parts. In these cases there is a gradual extension of the caseous and liquefying tuberculous disease into the muscles, and sometimes the abscesses burrow to great distances within the muscular sheath, as, for example, in *psoas abscess.* Less destructive tuberculous myositis may occur in the muscles beneath the skin and mucous membranes by extension of tuberculous processes. In these cases cellular infiltration and tubercle-formation, with some caseous change, may be observed. Miliary tubercles, or larger tubercular nodules due to hematogenous infection, are rare.

Syphilis may occur in the form of gummata, and it is likely that some cases of diffuse productive myositis are syphilitic in nature. As in other parts of the body, the blood-vessels in these cases have been described as particularly thickened.

Glanders, actinomycosis, and **anthrax** may involve the muscles in the vicinity of the specific lesions. Nodular and, later, necrotic or suppurative foci are the lesions observed.

TUMORS AND PARASITES.

The tumors of muscles, for the most part, spring from the interstitial connective tissue. Among the benign tumors *fibromata*, *myxomata*, and *lipomata* are sometimes met with. *Osteoma* and *chondroma* are found as localized lesions resulting from irritation or as true tumors. Striped muscle-tumors, or *rhabdomyomata*, are rarely found in the muscles, though occasionally seen as small nodules.

More important than the above is *sarcoma*, which occurs as a primary tumor comparatively frequently. The fibrous and spindle-celled varieties are common, and round-celled sarcoma are sometimes observed. The tumors originate from the connective tissue, though it is held by some that the muscle-fibers themselves may undergo sarcomatous transformation.

Carcinoma is a rare tumor, and is always secondary. The secondary form is not rarely seen in the muscles in the vicinity of carcinomata of other structures, such as the mammary gland.

Among the *parasitic diseases* of muscles may be mentioned trichinosis, cysticercus invasion, and hydatid disease. The first occasions disseminated myositis, to which reference has already been made. The other two conditions are rare and not important.

CHAPTER XII.

DISEASES OF THE BRAIN AND ITS MEMBRANES.

THE DURA MATER.

CIRCULATORY DISTURBANCES.

Active hyperemia occurs in the dura in association with tumors, gummata, and other focal diseases. The vessels of the dura surrounding the area of disease become distended and the membrane may be diffusely reddened.

Passive hyperemia may occur under the same circumstances as the above, and also in cases of thrombosis of the venous sinuses.

Hemorrhages are usually due to traumatism, and may occur on the outer or inner surface of the dura. Extradural hemorrhages are more common than intradural, especially in cases in which there is fracture of the skull. A collection of blood between the skull and the dura is sometimes designated *internal cephalohematoma.* Small hemorrhages into the dura may occur in infectious or hemorrhagic diseases and in cases of death from asphyxia.

INFLAMMATIONS.

Inflammation of the dura, or **pachymeningitis**, may be acute or chronic, and hemorrhagic, suppurative, or productive in character.

Hemorrhagic pachymeningitis occurs more frequently in the aged than in the young, and is a not uncommon condition in the insane. Chronic alcoholism and traumatism seem to be factors of some importance. In the early stages of the disease the inner surface of the dura exhibits a superficial deposit or membrane of grayish color, with brown or red spots, the latter being composed of altered blood-pigment (hematoidin). Microscopically the membranous deposit is found to consist of soft granulation-tissue containing numerous thin-walled blood-vessels. Later, diapedesis of blood-corpuscles,

or actual hemorrhages, occur, and the diseased area may have the appearances of a simple collection of blood or of a more or less stratified hemorrhagic exudate. Sometimes the amount of exudate and of hemorrhage may be such as to cause considerable cerebral compression, and in other cases death may occur from the hemorrhage itself. Occasionally the blood is in part absorbed, and a serous collection (*hygroma duræ matris*) results. The seat of the disease is usually in the area of distribution of the middle meningeal artery.

Suppurative pachymeningitis may occur in consequence of injuries, caries, or other diseases of the skull. Sometimes it results from purulent softening of thrombi in the venous sinuses, and very rarely it is secondary to leptomeningitis. Not rarely localized suppurative pachymeningitis results from disease of the middle or internal ear, with extension through the petrous bone. The dura becomes thickened by cellular infiltration, is soft and edematous, and not rarely undergoes necrotic change. The disease may be localized or diffuse, and may occasion secondary thickening and adhesions of the dura in cases terminating favorably.

Productive pachymeningitis may be of fibrous or ossifying character. The etiology is often obscure. Some cases follow hemorrhagic or suppurative pachymeningitis; in some the process seems to be primarily productive. Syphilis is probably a cause of importance. The dura, in the fibrous variety, is simply thickened and more or less attached to the pia-arachnoid and the inner surface of the skull. When firm attachments with the skull are formed osteophytes are frequently found upon the surface of the bones and in the dura (ossifying pachymeningitis). Osseous plates may be met with in the falx cerebri and tentorium cerebelli.

INFECTIOUS DISEASES.

Tuberculosis may occur in the form of miliary tubercles in association with tuberculous leptomeningitis. It may also be associated with tuberculosis of the bones; and, in rare instances, has been met with as a primary disease of the dura. In the latter cases the disease takes the form of a caseous nodular thickening of the membrane.

Syphilis may occasion a form of diffuse productive pachymeningitis, or gummata. The latter may originate in the dura, and extend to the pia or skull-bones, or they may originate in the bones and invade the dura secondarily. Gummata in this situation present themselves as more or less flattened nodular growths of grayish color, having a marked tendency to caseous change and to resolution, with formation of circumscribed thickenings and adhesions of the dura.

TUMORS.

Tumors of the dura mater occur with considerable frequency. The most common is probably *alveolar sarcoma.* This may occur in various situations, either as a flat swelling, or as a somewhat pyramidal mass, with the apex toward the brain, into the substance of which it projects; it is often firmly attached to the skull. Other forms of sarcoma are *angiosarcoma,* characterized by the proliferation of the cells of the adventitia of the blood-vessels, and a form in which the fibrous tissue so predominates as to make it really a *fibroma,* although nests of endothelial cells are found scattered throughout it. Other forms of sarcoma, however, also occur, particularly a *small round-cell variety,* which is usually multiple and the result of metastasis from some other portion. The latter tumors are usually flat, diffuse, and often extensive. They may or may not cause bulging of the skull. In any of these forms, but particularly in those in which the fibrous connective tissue is in excess, calcareous infiltration is not uncommon. In nearly all cases these tumors may produce erosion of the inner surface of the skull. Hyaline degeneration of the intercellular substance is very common. Among the other tumor-like growths are fibrous changes that may or may not be inflammatory in nature, and lead to circumscribed or diffuse thickening of the dura mater, and usually cause it to adhere densely to the skull. These are most apt to be found in old people. In addition to the round-cell sarcoma, *gliosarcoma* of the brain and *carcinoma* of the scalp may give rise to secondary growths in the dura mater, but these are extremely rare.

THE PIA AND ARACHNOID.

CIRCULATORY DISTURBANCES.

Anemia of the pia may occur in cases of general anemia.

Active hyperemia is constantly present in the early stages of meningitis. It is also met with in cases of death from alcoholism, and in severe infectious fevers, though in most of these cases microscopic examination discloses the fact that the process is really one of beginning inflammation. The pia is red and the small arterioles are injected. The fluid in the subarachnoid space is in excess, and may be slightly turbid or sanguinolent.

Passive hyperemia occurs in cases of general venous stasis, as in heart-disease, pulmonary diseases, and venous thrombosis. The large veins are greatly swollen, and the subarachnoid fluid is excessive.

Hemorrhages.—Small punctate hemorrhages may occur in cases of meningitis, in scurvy, purpura, and the like. Larger

hemorrhages between the pia and arachnoid are most commonly due to traumatism, and may sometimes be the result of rupture of aneurysms. The blood in cases of large hemorrhages may cause injurious cerebral compression, if rapid death does not follow the hemorrhage itself. Occasionally the blood becomes inspissated and absorbed, the membranes in these instances becoming thickened and pigmented, or it may be encapsulated and the pigment absorbed, giving rise to a clear cyst (*hygroma*).

Edema of the membranes themselves, or collections of edematous liquid in the subarachnoid space (external hydrocephalus), may be due to passive congestion. The membranes are thickened and of translucent, gelatinous appearance; the subarachnoid fluid causes elevation of the arachnoid and more or less compression of the cerebral convolutions. *Hydrops ex vacuo* is a form of dropsical effusion under the arachnoid, resulting from atrophy or hypoplasia of the cerebral convolutions. The space normally occupied by cerebral substance is in these cases filled with serous liquid.

INFLAMMATION.

Inflammation of the arachnoid and pia is called **leptomeningitis.** It is always an infectious process, and may be either acute or chronic.

Etiology.—The commonest cause of acute leptomeningitis is the pneumococcus. It is found in about 60 per cent. of all cases, and in these pneumonia is often an associated or primary condition. The pneumococcus may reach the meninges either by the blood- or lymph-channels, or by creeping along the lymphatic spaces in the areolar tissue between the esophagus and vertebral column; occasionally it enters directly from the ear or nasal cavity. Other micro-organisms that have been found are the streptococcus, the staphylococcus, Friedländer's bacillus, the Bacillus pyocyaneus, the bacillus of glanders; the actinomyces, the typhoid bacillus (of which a number of cases have been reported), the Bacillus coli communis, and the bacillus of bubonic plague. Meningitis occasionally occurs in the course of gonorrhea, but no case has as yet been reported in which the gonococcus was certainly demonstrated. Mixed infection is not uncommon, consisting usually of the pneumococcus and one or other of the more common pyogenic micro-organisms, and the latter are also frequently found associated with the tubercle-bacillus. The cause of epidemic cerebrospinal meningitis is the *Diplococcus intracellularis meningitidis*, discovered in 1887 by Weichselbaum in six cases that he examined, and subsequently found in other cases by Goldschmidt, Guarnieri, Netter, Faber, and others.

Pathologic Anatomy.—The gross changes may vary from those that are not recognizable macroscopically, to collections of green-

ish pus in the subarachnoidal space half an inch or more in thickness and covering the entire surface of the brain. In the slightest forms the presence of the condition may be suspected by the slight edema of the arachnoid, and perhaps a small collection of fluid containing flakes along the fissures of the brain. In some cases, however, even this does not occur, and it is impossible, without a microscopic examination, to say that inflammatory processes exist. Microscopically, sections in these cases usually show overfilling of the small vessels with blood, and a greater or less number of round cells, usually polynuclear, immediately surrounding it. Often this collection of round cells is most marked in the recesses of the convolutions. Staining for bacteria usually reveals the presence of a few, although in these cases they are rarely numerous. If the process has been more severe, or of longer duration, the edema of the arachnoid becomes more pronounced; its glassy, moist appearance being very distinctive. The vessels are usually injected; and this applies particularly to the veins, which appear as dark-blue tortuous cords running through the membranes. In the subarachnoidal space there is now a considerable collection of fluid, and along the sides of the arteries usually a distinct collection of lymph or pus. Sometimes, but not always, the arterioles are also distinctly injected, and occasionally there is a faint pinkish coloration, due to the injection of the capillaries.

This form may be localized or diffuse, and is usually secondary to some local source of inflammation, which is most frequently middle-ear disease. The process often shows distinct indications of rapid extension.

The more extensive diffuse forms show considerable variation in the part affected with greatest intensity, and have been divided into leptomeningitis of the vertex and leptomeningitis of the base. Ordinarily the purulent exudate is most pronounced along the course of the middle cerebral artery, extending from either side of the sella turcica outward and upward.

The changes observed consist of diffuse injection of the soft membranes, edema of the arachnoid, and a perivascular serofibrinous exudate along the course of the vessels coming from the veins. Microscopically, sections show around these vessels a mass of fibrin, in which are embedded a considerable number of polynuclear leukocytes. Often cells undergoing fatty degeneration are also found in these masses, lying close to the walls of the vessels in the portions of the brain where the changes are most pronounced. In this condition micro-organisms are usually found quite readily, either within or without the cells, those within the cells, in particular, frequently showing a partial loss of staining-power, that has been taken to indicate phagocytic activity.

In the most severe cases the entire subarachnoidal space is distended with a purulent accumulation. The surface of the brain

can no longer be seen, the thick greenish exudate covering the convolutions as a smooth mantle. In nearly all these cases there is also pronounced edema, the arachnoid looking thick, shiny, and moist. Microscopic sections show the ordinary picture of a purulent accumulation; pus-cells in a fibrinous meshwork, desquamated endothelial cells, and micro-organisms. In all forms of acute leptomeningitis petechial hemorrhages into the arachnoid are common. The substance of the brain and cord may also be involved, and this involvement may vary from a slight increase of the neuroglia-elements just beneath the pia, to the presence of foci of round cells. These foci are usually found about the small vessels or lymphatics dipping in from the pia, the latter situation being by far the more frequent. Ordinarily they are microscopic and surrounded by a narrow zone of partially degenerated nervous substance, outside of which there is again a slight increase in the neuroglia-tissue and cells. Occasionally, however, the cerebral involvement may be more extensive, and large abscesses are formed, leading to the destruction of considerable portions of the nervous substance. The nerve-fibers, even those in the neighborhood of the lesion, rarely show distinct alterations. The ganglion-cells, however, exhibit slight diffuseness in taking the stain, or irregularities in the arrangement of the chromophilic bodies. If the abscesses are larger, either involving or close to the gray substance, the ganglion-cells may show extensive degeneration, with entire loss of staining-power and fragmentation of the protoplasmic processes, nothing being left to indicate the position of the cells excepting an irregularly shaped vesicle containing some brownish pigment. These larger foci, however, are usually found in the white substance.

An attempt has been made to distinguish varieties of meningitis according to the infective agents, and Netter has stated that in pneumococcic infection the pus is viscid and greenish; in streptococcic infection, more serous and less adherent to the membranes. Honl believes that only four forms can be differentiated—the thick, viscid pus of the pyogenic micro-organism, the yellowish exudate of tuberculosis, the bluish-green pus of the Bacillus pyocyaneus, and the purulent exudate containing yellowish grains of actinomyces.

Epidemic cerebrospinal meningitis does not differ essentially from the ordinary septic form, excepting in its cause. As a general rule the inflammatory process begins upon the convexity of the frontal lobes, and proceeds backward and downward, the basal meninges being involved late in the course of the disease. Aside from those forms occurring as a complication of other pathologic conditions that lead to death before the meningitis has been fully developed, it is the one most likely to kill the patient before distinct alterations have become evident. These

cases are spoken of as *foudroyant* or *fulminant*. The disease is often accompanied by lesions in other parts of the body, as petechiæ in the skin, suppuration in the joints, multiple abscesses, endocarditis, degenerations of the myocardium, and suppuration of the labyrinth of the ear.

Associated Changes.—Besides the meninges of the brain, those of the cord are almost always involved, even in cases of tubercular meningitis. The peculiarities of these conditions are described in the section on the spinal cord. Extension along the fold of pia mater that covers the choroid plexus is also exceedingly common. The cerebrospinal fluid may be turbid, there is a moderate amount of lymph on the ependyma and over the surface of the plexus, and the latter may even contain small abscesses. Not infrequently, in prolonged cases, meningitic adhesions and occlusion of the aqueduct of Sylvius give rise to an acute hydrocephalus.

INFECTIOUS DISEASES.

Tuberculous meningitis is usually a secondary affection, although in children it may occasionally appear in connection with a few recent foci in other parts of the body. The bacilli reach the meninges ordinarily by the blood-vessels, particularly, in all probability, by the left carotid, from which situation they may spread along the base or to the vertex. Occasionally they seem to pass up the vertebral arteries, and may then affect the cerebellum more severely than the base of the cerebrum. Tuberculosis may also extend directly from the tubercular lesions of the skull or of the middle ear, and it has occasionally been observed to occur after traumatism. Other routes of infection, however, have been suggested, particularly, as in acute purulent meningitis, the organisms have been supposed to pass up the posterior mediastinum, the retropharyngeal areolar tissue, and thence into the cranial cavity. Mixed infection not infrequently occurs, and has been supposed to account for the purulent exudate. It is certain, however, that pure tuberculous meningitis may occasion the formation of pus. The organism that is most frequently found in connection with tubercle-bacillus is the pneumococcus, and it may be found intimately associated, although it has been stated that the tubercle-bacillus appears to predominate at the base of the brain and the pneumococcus in the exudate of the convexity.

Pathologic Anatomy.—In cases that die of pulmonary tuberculosis it is not uncommon to find, particularly upon the convexity of the pia mater, a number of small grayish nodules. These are not always apparent upon superficial inspection, but by cutting through the cerebral hemisphere as far as the pia, and then stripping it away from the under surface of the membrane and holding the latter up to the light, they may readily be seen. In certain

cases tubercle-bacilli have been found when recognizable macroscopic lesions were entirely absent. Microscopic examination, however, has usually revealed a few masses of epithelioid cells and some slight perivascular round-cell infiltration.

When the infection is more severe the tubercles are usually most numerous upon the base of the brain, particularly on either side of the carotid canal and in that part of the base just posterior to the dorsum sellæ. Ordinarily the disease assumes the form of disseminated miliary tuberculosis. The tubercles are situated between the arachnoid and the pia, often in the depths of the sulci. They vary in size up to 0.5 cm. in diameter, and often show slight cheesy degeneration in the center. The meninges are congested, and usually there is an exudate of inflammatory liquid that contains flocculi of lymph, or is even seropurulent in character. Microscopic examination shows that the tubercles are composed of epithelioid cells, which occasionally present some evidence of division. Giant-cells are also present, although perhaps not so frequently as in lesions in other parts of the body. There is usually round-cell infiltration about the vessels, and the latter are apt to be distended. This round-cell infiltration may also extend into the cortex of the brain, and the tubercles are often found in the latter situation. Tubercles may also exist in the choroid plexus. Sometimes, if the process has lasted for some time, and the tubercular masses have increased in size, they may undergo cheesy degeneration and form irregular masses; these are usually found at the base of the brain, and often cause serious pressure upon the cranial nerves that they involve.

Occasionally, when only a small number of bacilli have reached the meninges and have been deposited in one point, a single cheesy nodule may be found, particularly in one of the sulci, forming the meningeal *tyroma*, that sometimes attains a considerable size. In these less acute cases the exudate is considerable, and involves not only the subarachnoidal space, but also the ventricles of the brain, causing a condition that was formerly described as *acute hydrocephalus*. Numerous tubercles are found in the choroid plexus, and the ependyma is covered with slight elevations resembling somewhat the appearance of cor villosum. These are usually found to consist of proliferated endothelial cells and of the subependymal neuroglia and fibrous tissue. Tuberculous infiltration of the brain-substance is, however, very common. This may either be nothing more than an extension by continuity along the lymph-spaces and blood-vessels dipping from the pia or ependyma into the brain-substance, and giving rise to small foci composed of epithelioid and giant-cells surrounded by leukocytes, and perhaps exhibiting a slight degree of cheesy degeneration in the center; or else considerable areas of softening, which are perhaps caused by the formation of thrombi. These are most frequent in the corpus striatum and the crura, and appear as grayish-white or yellowish

areas of softened and degenerated nervous tissue. Not infrequently, punctiform hemorrhages are found in the cortex about these areas of softening. The tubercle-bacillus is usually readily found, although this is exceedingly difficult if the tissue has been hardened in Müller's fluid. In general, extension of the tubercular process to the meninges of the cord occurs if the duration of the process is at all prolonged, but the vertebral canal is so much longer than the spinal cord that pressure-symptoms rarely occur, and, as the irritation is slight, the cranial symptoms dominate the clinical course.

Syphilis may occur in the form of gummatous infiltration. In these instances there are found flattened nodular thickenings of the arachnoid and pia, of grayish or pinkish color, and tending to undergo necrotic change. The process begins in the inner surface of the arachnoid, or sometimes in the walls of the blood-vessels, and extends to the pia and cerebral substance on the one hand, and to the dura on the other. In another form of syphilis there is diffuse infiltration or syphilitic leptomeningitis, causing considerable thickening of the meninges.

Chronic syphilitic leptomeningitis and meningo-encephalitis are

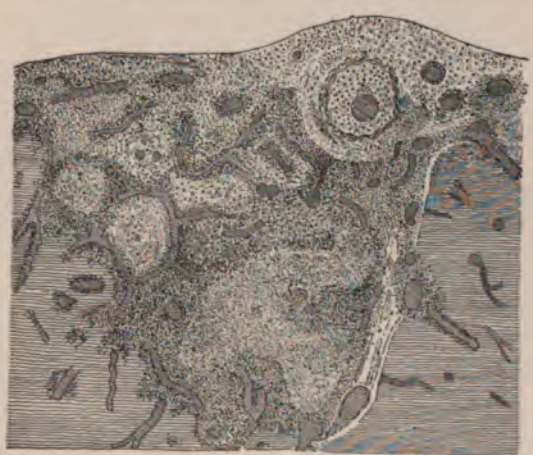

FIG. 346.—Gummatous meningo-encephalitis (Ziegler).

occasionally met with. In these cases the membranes are thickened and fibrous, and secondary extension of the infiltration into the cerebral cortex occurs (Fig. 346).

TUMORS.

The Pacchionian Bodies.—The most common, and clinically perhaps the least important, tumors of the arachnoid are the

Pacchionian bodies. These occur as small granular masses or circumscribed nodules, chiefly along the upper edge of the superior longitudinal sinus, often extending a short distance laterally over the convex surface of the convolutions. Microscopically they consist of dense masses of fibrous tissue, covered by a layer of proliferated endothelial cells, which give them a concentric structure. Occasionally some calcareous nodules may be found in them. They usually grow only outwardly, and frequently erode the skull, giving rise to little pits upon the inner surface.

Endotheliomata are most frequently found in the pia mater. They occur as irregular alveoli, lined with cuboidal or round endothelial cells. These are not always arranged in a single layer, but may occasionally fill the alveolus, although this is not common, and more frequently some have broken loose and lie free in the cavity. The cells often show karyokinetic changes, and occasionally alterations in shape, due to mutual pressure. These tumors resemble carcinomata closely, but the presence and proliferation of the

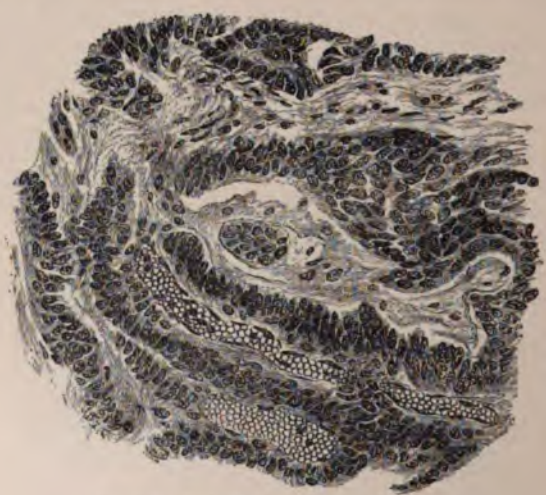

FIG. 347.—Endothelioma of the pia mater.

epithelium-like cells in the stroma, such as occur in carcinoma, have not been observed (Fig. 347).

Cholesteatomata are of two kinds: those consisting exclusively of squamous epithelial cells, and those containing, in addition, various other epidermal structures, such as hairs or sebaceous glands. They are usually situated in or about the median line, along the base of the brain or on the upper surface of the corpus callosum, or somewhere along the choroid plexuses. Those containing hair are most frequently found near the cerebellum, grow-

ing either from the arachnoid, or, more rarely, from the outer surface of the dura. The latter may occur upon the frontal or occipital bones, and often show calcareous infiltration, or even true osseous formation.

Lipomata are rare. They are usually found in children, and always in the soft membranes, especially the pia mater. The most frequent seats are the upper surface of the corpus callosum and the corpora candicantia. According to Bostroem, they are probably epidermal in origin, nothing but the subcutaneous fatty tissue being left.

Teratomata may be present. Chiari has described a case that grew from the lining membrane of the third ventricle in an infant that died at the age of seven weeks. It consisted of a medullary white mass and a number of serous cysts. The solid substance was composed of fetal brain-substance, in which were fissures lined with epithelium similar to that of the central canal of the cord, and ganglion-cells, retinal cells, skin-glands, and jelly of Wharton. Fibrous and cartilaginous tissues were also present.

THE BRAIN.

DEVELOPMENT AND ANATOMY.

Development.—(For convenience, the development of the cord is considered in this place with that of the brain.) The central nervous system commences as a shallow depression, that appears in front of the primitive streak in early embryologic existence. It is bounded on either side by ridges, known as the *medullary folds.* The groove gradually becomes deeper, and finally the two medullary folds unite, giving rise to the formation of the *medullary canal,* which is soon separated from the dorsal surface of the embryo by the interposition of mesoblastic tissue. The canal is first formed in the portion that subsequently forms the cervical region of the spinal cord. Just beneath the medullary canal there is a cylindrical collection of cells, often with a small cavity in the center that forms anteriorly a shallow groove, the so-called notochord. Its function is unknown, and it eventually disappears during embryonic existence, although traces may still be found in the intervertebral cartilages at birth. In some of the lower animals a small sac-like dilatation is found anteriorly, from which a process extends downward and apparently stops at the hypophysis cerebri; but it is not certain that it forms a portion of this organ. The anterior extremity of the embryo continues to grow, and bends downward, forming the cephalic fold. In this part of the neural canal three dilatations occur—*the primary vesicles of the brain;* the posterior portion ultimately forms the spinal cord.

The Cord.—At first the wall of the embryonal cord is composed of a single layer of cylindrical epithelial cells (*spongioblasts*), with nuclei at various distances from the central canal; these ultimately become the nuclei of the glia-cells. The central ends remain cylindrical; the peripheral ends become branched, forming the myelospongium, probably the antecedent of the neuroglia-fibers, which, according to some recent investigations, become separated from the cells. At the age of about five weeks in the human embryo, certain cells, with a considerable amount of clear protoplasm, are found near the inner limiting membrane, the so-called *germinal cells.* Subsequently other cells appear, probably derived from the

germinal cells, as they are first found in the situations occupied by these, the so-called *neuroblasts*. These are distinguished by the appearance of a projection, pointing toward the periphery of the spinal cord, that grows out from the protoplasm and ultimately pierces the external limiting membrane to become an axis-cylinder. The central canal, at this period, is usually elliptical in shape, with the long axis dorsoventral. The anterior and posterior ends are very thin, and the former ultimately becomes invaginated to form the anterior commissure.

Just outside of the cord, probably from masses of epiblastic cells derived from its wall, the cells of the spinal ganglia appear. These are, at first, bipolar, one process extending into the spinal cord, and the other peripherally, but ultimately the two processes unite at their commencement. The spinal cord at first completely fills the spinal canal, but after the fourth month the vertebral column begins to grow somewhat more rapidly, and at birth the conus terminalis is opposite the third, and in the adult extends only to the lower end of the first, lumbar vertebra. The nerve-fibers are at first non-medullated, but later myelin-sheaths appear, first in certain parts of the posterior columns, and lastly in the pyramidal tracts, which often, at birth, are not yet entirely medullated. The membranes are derived from the mesoblast.

The Brain.—The three primary vesicles from which the brain is developed continue to grow, and the first is subdivided by a median constriction into two secondary vesicles, the prosencephalon and the thalamencephalon. From the former two lateral offshoots appear, which give rise to the cavities of the lateral ventricle; and from the walls of these are developed the cerebral hemispheres, the olfactory lobes, and the corpus callosum. The cavity of the second vesicle forms the third ventricle, and from its walls grow the nervous part of the eye, the optic thalami, and the pituitary and pineal bodies. The cavity of this vesicle (mesencephalon) forms the aqueduct of Sylvius, and from its walls grow the corpora quadrigemina and the crura. The posterior primary vesicle also becomes constricted, forming the epencephalon and the metencephalon. The two cavities, however, remain united and form the fourth ventricle. From the walls of the anterior portion are developed the cerebellum and the pons. From those of the posterior portion, the medulla oblongata.

The ultimate shape of the brain, however, is largely determined by certain flexures and by the growth and extension of the axis-cylinders, which pass in various directions and form the white matter, the greater bulk of the central nervous system. The first flexure is beneath the mesencephalon and concave from the ventral surface. The second flexure is concave dorsally, and is just beneath the epencephalon. The third grows at the junction of the metencephalon with the spinal cord, and is concave ventrally. Differing from the cord, the growth of the brain exceeds that of its containing bony capsule. As a result the surface of the hemispheres is usually thrown into folds. The earliest of these appear during the third month, and are usually transverse to the axis of the brain, although not invariably. The lateral ventricles at this stage are very large, and the sulci project into their cavities as ridges. During the fourth month they disappear, with the exception of three—the Sylvian, the calcarine, and the parieto-occipital fissures. The hippocampal fissure also appears about this time. The other permanent sulci appear about the end of the fifth month, the earliest being the fissure of Rolando; but many of the secondary fissures do not develop until after birth.

The **sympathetic nervous system** is probably only an offshoot of the central nervous system. The cells first appear upon the spinal nerves, from which they wander, remaining connected with them by short branches, the rami communicantes. Some authorities, however, believe that the sympathetic system is developed from the mesoblast.

Anatomy.—The brain consists of the two cerebral hemispheres, the basal ganglia, the pons, the medulla, and the cerebellum. Its weight varies from 1200 to 1300 grams in the adult female, and from 1300 to 1400 grams in the adult male. Its consistency at birth is very soft; in the adult it becomes somewhat firmer, but is always softer than the normal liver. Its color varies from grayish-white in the parts composed of medullated fibers, to reddish-gray in those composed chiefly of ganglion-cells. The cerebral hemispheres are two large symmetrical masses occupying the greater portion of the cranial cavity; they are separated by the superior longitudinal fissure, and united by the corpus callosum and the anterior commissure. They are joined to the pons by the crura. Their surfaces are rendered very irregular by the presence of numerous fissures or sulci; and are divided into the frontal, parietal, occipital, and temporosphenoidal regions. The important fissures are the Sylvian, the Rolandic, and the parieto-occipital on the external surface; the calloso-marginal, the calcarine, and the parieto-occipital on the medium surface.

The hemispheres are composed essentially of an outer layer of gray matter, the cortex, containing ganglion-cells, and of fibers passing from these in various directions and uniting them with other parts of the central nervous system. These may be divided into three main classes: the *projection-fibers*, passing between the cortex and the basal ganglia, or into the internal capsule; the *transverse or commissural fibers*, passing between two hemispheres; and the *association-fibers*, passing between different areas in the same hemisphere. The most important of the projection-fibers are those which arise in the motor portion of the cortex, and pass first into the internal capsule, where they are grouped about the knee, thence through the crusta and the pons, to form ultimately the pyramids of the medulla. They decussate in the first cervical segment of the cord and form the pyramidal columns of the cord. The fibers of the optic radiation commence in the cortex about the calcarine fissure and in the cuneate lobe, and pass forward to the pulvinar of the optic thalami. They are also associated with the external geniculate body and the anterior corpus quadrigeminus. From the pulvinar, the optic tracts pass around the crusta, then lie below and to the inner side of the internal capsules, and unite in front of the tuber cinereum to form the chiasm from which the optic nerves arise. The transverse or commissure-fibers include those of the corpus callosum and of the anterior commissure. The fibers in the corpus callosum appear to correspond closely to those regions of the brain situated nearest to them. The anterior commissure is composed of fibers uniting the temporosphenoidal lobes of the two hemispheres. The association-fibers either connect adjacent lobes (*fibræ propriæ*), or unite distant portions of the hemispheres (the long association-fibers). The most important of the latter are the superior, interior, and anterior association-bundles, the cingulum, and the fornix; the latter is a group of arching fibers connecting the hippocampal region with the corpora albicantia.

In the substance of each hemisphere are found the lateral ventricles: two long, narrow, branching cavities, joined to the third ventricle by the foramen of Monro. Each contains a choroid plexus, and is normally lined with epithelium and contains clear cerebrospinal fluid. The anterior portion of the two ventricles is separated by the septum. A small double layer of epithelial cells line and almost fill the cavity of the fifth ventricle. The basal ganglia of the brain are the lenticular nucleus, the caudate nucleus, forming together the corpus striatum, and lying on either side outside of the internal capsules, the optic thalamus, a large oval mass lying beneath the caudate nucleus. The outer portion on the lenticular nucleus is usually known as the putamen; the two inner segments are known together as the globus pallidus. To the outer side of the putamen is a band of white fibers, known as the external capsule, that

is separated from the cortex by a thin layer of pigmented cells, the claustrum.

The third ventricle communicates with the fourth by a narrow canal, the aqueduct of Sylvius, which passes through the tegmentum of the crura. It is surrounded by a zone of gray matter, in which are found the nuclei of the oculomotor nerves. Above it are the four corpora quadrigemina; two pairs of rounded eminences with a white cortex and a gray center. The superior corpora, as has been already stated, are intimately connected with the optic tract. Just anterior to these bodies is the small pineal gland, a hypoplastic median eye situated above the posterior commissure. Externally to the crusta on either side, continuous with the posterior portion of the thalamus, are the two geniculate bodies, separated by the optic tract, with which the external geniculate body is closely connected. The optic thalami lie on either side of the third ventricle, and just beneath the caudate nuclei; they are oval bodies containing numerous groups of nerve-cells, the anterior portion being called the anterior tubercle, and the posterior portion the pulvinar.

The two great channels by which fibers pass to and from the cerebrum are the crura cerebri. These are divided by a narrow layer of dark-gray material, the substantia nigra, composed of pigmented ganglion-cells, into the crusta, or inferior portion, and the tegmentum, or superior portion. A part of the crusta is formed, as has already been stated, by the pyramidal tract. Sensory nerve-fibers are found in two groups in the tegmentum toward the outer edge, comprising the inferior and superior fillets. These fibers divide into three bands: one passes into the superior portion of the tegmentum, and some of these enter the posterior portion of the interior capsule; another band passes to the anterior corpora quadrigemina and the thalamus; and a third into the posterior corpora quadrigemina, although it is not certain that all the fibers are thus distributed.

The two crura unite to form the pons, which is composed, ventrally, of bundles of motor fibers separated by the commissural fibers of the cerebellum, and dorsally, partly of the fibers of the fillet and partly of gray matter. Below the pons is found the medulla, which is really nothing but the upper portion of the spinal cord. Anteriorly we find the two well-defined bundles of motor fibers, the pyramids; just back of these the lower olives; and on the dorsal surface the nuclei of the tenth and twelfth nerves, and externally to them the nucleus gracilis and nucleus cuneatus, the terminations respectively of the columns of Goll and Burdach in the cord. The axis-cylinders of the cells that compose these nuclei pass toward the brain and form the fillets. On the outer surface of the medulla, near the dorsal surface, are the two restiform bodies, the continuations of the cerebellar peduncles.

The cerebellum is composed of two lobes and the vermiform process. Upon cross-section it is seen to be composed of a great number of narrow gyri separated by deep ramifying sulci, each convolution being lined externally by medullated fibers, beneath which is a layer of ganglion-cells enclosing a center of medullated fibers. It is united to the cerebrum by the superior peduncles, which terminate in the nucleus ruber of the tegmentum. The middle peduncles form the transverse fibers in the pons, and the inferior peduncles pass into the restiform bodies of the medulla. Certain nuclei are found in the interior of the white substance, of which the most important is the dentate nucleus, analogous structurally to the olives of the medulla.

The Neuron.—Histologically the essential element of the nervous system is the neuron. This, in the sense of Waldeyer, comprises the nerve-cell, its protoplasmic processes (which are branched), and the axis-cylinder, which may be a single fiber giving off lateral collaterals, or is extensively branched (Golgi cells). The cell-body consists of protoplasm without a dis-

tinct cell-wall, and containing or not containing chromophilic bodies. According to Nissl, two groups of cells are thus formed, the somatochromes with, and the caryochromes without, these bodies. According to zoölogists, these are respectively motor and sensory in function, but the cells of the spinal ganglia, which appear to be sensory, contain these granulations. Cells are spoken of as multipolar or bipolar, according to the number of processes that project from them. It is impossible to describe in this place all the varieties of cells and their distribution in the nerve-substance. The neurons may be divided into endogenic, wholly within the central nervous system, and exogenic, partly in the peripheral nervous system. Each axis-cylinder terminates in a tuft of fibers that surround, without touching, some other ganglion-cell, or, if it extends to the periphery, terminates in a special sensory corpuscle or a muscle-plate.

Preservation of the Brain and Cord.—After the brain has been removed from the cranial cavity it is probably best to place it at once in a 10 per cent. solution of formalin. The formalin should be changed at intervals of three or four days. If it is hardened in Müller's fluid, deep incisions should be made, preferably parallel to the upper surface of the corpus callosum, after the removal of the frontal and occipital lobes. The fluid should be changed at the end of the first hour, then at the end of twelve hours, and then every day for one or two weeks. If it is desired to examine the brain at once, it may still be preserved for microscopic investigation by making two horizontal incisions through the cerebral hemispheres, parallel to the upper surface of the corpus callosum, then cutting into the lateral ventricles. If a hemorrhage exist, it can usually be detected by the presence of blood in one of the ventricles, or by discolorations of the floor. The most important part of the brain, for the purpose of tracing secondary degeneration, consists of the stem, so called—that is, the basal ganglia, the crura, the pons, and medulla. It is usual to make serial sections through this part, which may be removed by cutting off the frontal lobes at the knee and the occipital lobes opposite the splenium, and then removing the temporal portion of the brain by sagittal section just outside of the lateral ventricles. As soon as the cord has been removed the dura mater should be cut on both sides and laid back. It is usually desirable to remove the cord first, as by this means a horizontal section can be made through one of the upper cervical segments, and the remainder of the cord then removed with the brain. In this manner the usual oblique incision, that renders the upper portion useless for microscopic study, is avoided. It is unnecessary, and for many reasons undesirable, to make transverse incisions through the cord before hardening, even if Müller's fluid be employed.

CONGENITAL ABNORMALITIES.

The deformities of the brain are numerous and complicated. They may be divided roughly into those associated with alterations in the skull and those occurring within the cranial cavity.

Acrania is a deformity characterized by absence of the skull. The membranes are usually preserved, and form a sac filled with serum, on the inner surface of which small particles of nervous tissue may occasionally be found. More frequently the brain forms only a small mass at the upper portion of the spinal canal, lying on the basilar process of the occipital bone. Sometimes it appears as if the sac had ruptured, or had never completely closed, for the membranes are collapsed, and form upon the base of the skull a mass consisting of fibrous connective tissue and blood-vessels.

Often in this case the encephalon is entirely absent, but the pons and medulla may be almost completely developed. The cranial nerves are usually present.

Hemicrania is a condition in which more or less of one of the parietal bones, or of a portion of the frontal or temporal bone, has failed to develop. The corresponding portions upon the opposite side that have developed are usually hypoplastic. Ordinarily, anencephaly, or only partial development of the brain, is associated with these changes.

Cranioschisis is the name applied to imperfect closure of the skull along the middle line. This may be associated with *rhachischisis*, when both skull and spine are cleft. The commonest situations for small fissures are in the frontal bone, in the region of the posterior fontanelle, in the median line of the posterior portion of the occipital bone, and, more rarely, in the region of the anterior fontanelle or the sagittal suture, or in the sphenoid bone.

Fissures or other small defects usually occasion hernia of the brain, which is named *encephalocele*, and according to its situation anterior or posterior, frontalis or occipitalis, superior, inferior, or lateral. If, instead of brain-substance, only the membranes protrude through the fissure, the condition is known as *meningocele*. In these cases the cavity is filled with cerebrospinal fluid. Sometimes the under surface of the membrane is lined with nervous tissue, showing that it represents a dilatation of one of the primary cavities of the brain, corresponding to the condition found in spina bifida. These congenital herniæ are probably the result of *fetal hydrocephalus*, although it is possible that the chief cause is the imperfect development of the cranium. In cases in which the fissure is in the sphenoid bone, it is not uncommon to find, as an associated condition, cleft palate. Life is, of course, incompatible with extensive encephalocele. If it is small, the neck of the sac is sometimes constricted, either spontaneously or as a result of surgical interference, and recovery ensues.

Cyclencephaly is a peculiar deformity in which there is failure of the anterior cerebral vesicle to develop. The frontal lobes remain fused, and a single rudimentary eye develops.

Abnormalities in Size.—The size of the brain is subject to considerable variation.

Macrocephaly is the condition in which the brain is excessively large—that is, more than 1500 gm. This may be of two kinds. In the first, and perhaps less common, form the brain is entirely normal in structure, the proportion between the various parts being maintained and the relation between the nervous tissue and the neuroglia not altered. In some instances the subjects possess unusual intelligence; in others this is not the case. The second form is enlargement of the brain with hyperplasia of the neurog-

liar tissue. This is not infrequently found in the so-called *hypertrophic nodular gliosis.* In this condition the brain may be considerably enlarged, and the convolutions may be increased in size, although not abnormal in arrangement. Microscopically, the changes described in the section on sclerosis are discovered. A pseudo-enlargement of the brain is produced by hydrocephalus. The weight of the brain, after the liquid has been removed from the cavities, is usually less than normal, although this is not always the case.

Hypertrophy of the brain may be limited to certain parts. These are usually individual gyri, and are nearly always sclerotic. Sometimes only a portion of a convolution is thus affected, and produces a tumor-like swelling. Hypertrophy of individual sections of the encephalon does not appear to have been observed; that is to say, simple enlargement of the cerebellum, or of one of the cerebral hemispheres.

Microcephaly is a condition in which the brain is much smaller than normal, as a result of defective growth, or else of disease, either in early life or later. In some instances the brains, aside from their smallness, appear perfectly normal, and this diminution in size, within certain limits, is not incompatible with normal intelligence. Usually, however, there are sclerosis and decrease in size of some of the gyri. There are, of course, the associated changes usually found in sclerotic conditions.

Hypoplasia of individual portions of the brain has been observed, particularly of the corpus callosum, the cerebral hemispheres, and the cerebellum.

Hypoplasia of the *cerebral hemispheres* is usually due to some pathologic change, and will be discussed under sclerosis and porencephaly.

The congenital absence, either total or partial, of the *corpus callosum* has been observed in a number of cases. It may occur in brains otherwise normal, but is usually associated with microcephaly or other profound structural changes. In the cases in which no other lesions exist the intelligence may be normal, but in the great majority of instances the patients are idiots. In all cases, however, the following associated alterations have been observed: absence of the calloso-marginal sulcus, division of the gyrus fornicatus by perpendicular fissures, the splitting of the fornix, and, in certain cases, secondary degenerations. The tapetum is usually intact. The absence of the transverse fibers in the centrum ovale renders the superior longitudinal fasciculus very distinct. The appearance of the brain is quite characteristic. As soon as it is removed the hemispheres fall widely apart, showing the third ventricle covered with a delicate layer of pia mater. The inner surfaces of both hemispheres are divided by numerous fissures, and appear atypical. When only a portion of the corpus

callosum is absent the splenium is nearly always preserved. Occasionally, in cases of marked hydrocephalus, the corpus callosum may be extremely thin, and be torn during the removal of the brain, and this may possibly be mistaken for congenital absence. A little careful examination, however, will usually reveal the true state of affairs.

Hypoplasia of the *cerebellum*, or even total absence of one or both hemispheres, has been occasionally observed. It is nearly always associated with sclerosis. A collection of cerebrospinal fluid in part supplies the place of the absent organ. The cerebellum may be of normal shape, and even microscopically show no changes other than diminution in size. More commonly, however, the changes are asymmetrical, one lobe being markedly smaller than the other, and perhaps reduced even to a small papilla. There are often sclerotic changes, with marked atrophy of the cortex and disappearance of many of the medullated fibers. In these cases the cerebellum is usually of somewhat firmer consistency. The associated changes are diminution in size of the olivary bodies; in the unilateral cases, of that upon the opposite side; the pons and medulla are usually smaller than normal, and in the former the pyramidal tracts, on account of the absence of the transverse fibers, are usually compact and distinct. Sometimes the corpora quadrigemina are also altered, but this is not invariably the case.

Other changes of unknown significance that have been described are abnormal arrangement of the convolutions. Of these the most important is the presence of *annectant gyri* across the Rolandic fissure, or the absence of annectant gyri in the parieto-occipital fissure. It does not appear, however, although the claim has been frequently made, that these changes are in any way associated with intellectual disturbances. Bundles of nerve-fibers, taking an abnormal course, have occasionally been found in the pons and medulla. These seem to be produced by premature decussation of portions of the pyramidal tract, and are of no clinical significance.

Anencephaly, or total absence of brain, is a congenital lesion usually associated with acrania. Sometimes it is associated with total absence of the spinal cord; in other cases a portion of the pons, medulla, and the cord are still present, although much smaller than normal. The cranial nerves are usually present, and the eyes, in particular, are nearly always perfectly developed. The lesion is, of course, incompatible with life, although when the medulla is present a few respirations may take place after birth. The appearance of the monsters is very characteristic. From the orbital ridge of the frontal bone the skull slopes in almost a direct line to the neck, making the face and eyes unusually prominent—the so-called frog-face. Frequently other deformities are also present.

POST-MORTEM DEGENERATIVE CONDITIONS.

It is important to be acquainted with the post-mortem alterations that may take place in the nervous system, in order to avoid the confusion of such changes with those that have occurred as the result of disease. Little attention has been paid to the macroscopic changes, and they are not characteristic. Their degree depends upon the temperature at which the body has been kept after death, the nature of the disease that preceded death, and the period that elapsed before the tissues are removed. Ordinarily no changes will be noticed under thirty-six hours if the body is kept on ice. If kept at a temperature of about 16° C. (59° F.), the brain and cord will appear normal if removed within twenty-four hours. There is first softening of the nervous tissue, that is general and not associated with pigmentation; the tissues may become so soft that it is almost impossible to remove them without injury. Later there is often a considerable extravasation of blood-pigment around the vessels; and, finally, if putrefaction is advanced, the tissues become almost diffluent and light brown in color.

Lately, Italian authors have studied methodically the microscopic changes. The nerve-cells swell, their protoplasmic processes break off, and there is a gradual loss of the staining-power of the chromatin-bodies; vacuoles appear in the protoplasm and the outline of the cell becomes irregular; and finally the chromatin-substance completely disappears. The outlines of the nucleus become indistinct, it swells, and then contracts, with irregularity of the outline. It stains homogeneously, due to diffusion of the chromatin, and may contain small granules of hyaline material. It is often placed excentrically in the cells. Later it loses its staining-power, and finally disappears completely. The nucleolus is the last structure to show alteration; it may swell slightly, become filled with vacuoles, and then break up into granular material and disappear. The protoplasmic processes do not exhibit varicosities, but apparently become more fragile, and are very apt to be broken off during staining. Changes may take place in the myelin-sheaths that, when studied by Marchi's method, are not greatly different from those seen in areas of softening—that is, small fatty granules appear along the course of the nerve-fiber. In post-mortem lesions, however, there is no perivascular round-cell infiltration; no compound granular cells can be found in the tissue; there are no signs of proliferation in the neuroglia; and the process is more general and uniform than is apt to be the case in morbid conditions.

GENERAL PATHOLOGIC ANATOMY OF THE NERVOUS SYSTEM.

The pathology of the nervous system differs from that of the other organs of the body chiefly in the fact that the special structures of which the nervous tissue is composed have no close analogies to the epithelial cells and connective tissues. It is desirable, therefore, to discuss, first, the general changes occurring in the nerve-cells, nerve-fibers, and the neuroglia.

The Nerve-cell.

Of late years, considerable progress has been made in the elucidation of the finer pathologic changes that occur in the nerve-cell. On account of their characteristic appearance and sharply differentiated structure, the cells of the anterior cornua of the spinal cord have been most carefully studied, and it is necessary, therefore, that we should give a brief description of their anatomy. The appearance depends largely upon the method of staining employed. By the Golgi method the cell appears as an irregular body, from which come a number of thick processes, that rapidly divide and subdivide, until they appear as a maze of independent delicate branches, upon either side of which can be seen minute projections, the so-called gemmules; from one portion of this cell a fine process arises that is of uniform width. At regular intervals this neuraxon gives off the so-called collaterals, delicate branches that spring from it at right angles and have a different course. By this method other ganglion-cells in the nervous system have also been carefully studied, and show numerous variations in type, the most important being the number and complexity of the protoplasmic processes, and the division or even excessive branching of the neuraxon. The morbid changes that can be observed by the application of this stain are but few, since it appears that the pathologic cells soon lose their power of impregnation. Golgi and, in this country, Berkley have made the most extensive investigations by this method. It must be said, however, that in the majority of instances their studies were made upon the pyramidal cells of the cerebral cortex, and not those of the anterior cornua of the cord.

The alterations are essentially of two kinds: first, the appearance of *varicosities* upon the protoplasmic processes in their thicker branches; second, the *disappearance of the gemmules* from the terminal filaments. Such alterations Golgi has seen in chorea, Nageotte in general paresis, and Berkley in alcoholism and other forms of poisoning. Sailer has found very marked changes of this character in the spinal cords of guinea-pigs killed with tetanus-toxin, and Steele has described a varicosity upon the axis-

cylinder in the cortical cell in an animal killed by diphtheria-toxin. Lenhossek appears to regard the varicosities of the protoplasmic processes as the result of an accumulation of the chromophilic bodies, and Kölliker states that they are merely artefacts, a view held by most zoölogists. Sailer[1] has found very characteristic changes of this type in the brain of a guinea-pig that was apparently healthy and killed for histologic purposes.

In 1885, Nissl described a method for staining the nerve-cells which, on account of its differentiation of the structures of the protoplasm, and the possibility that by it cells in any stage of degeneration may be stained, has yielded most valuable results. It consists essentially of staining tissue, hardened in alcohol, by one of the basic anilin-stains, such as thionin or methylene-blue. The cells of the anterior cornua show the irregular outline and the numerous protoplasmic processes as before. Throughout the protoplasm are small, irregular bodies, sometimes vacuolated, that take the basic stain intensely. They are arranged somewhat concentrically around the nucleus, but at the points where the protoplasmic processes come off become spindle-shaped and turn into them, and are also found in the processes as spindles. Between these bodies the cytoplasm refuses to take the stain, and is called the *achromatic substance.* Nissl and some others believe that it has a delicate fibrillar structure, but this has not been positively determined. A cup-shaped portion of the protoplasm remains clear, and is usually rather sharply delimited from the remainder of the cell. From this extends a long, faintly staining, undifferentiated neuraxon. The nucleus does not stain, but remains as a clear space near the center of the cell, containing a round, deeply staining, and usually vacuolated nucleolus, surrounded by a membrane with irregular thickenings (Fig. 348). It has been claimed (Kronthal) that these so-called chromophilic

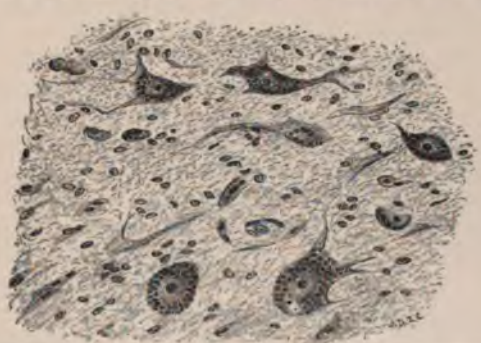

FIG. 348.—Normal and degenerated nerve-cells of the anterior cornua of the spinal cord; × 600.

[1] Verbal communication.

bodies do not exist in the living cell, but are the products of disintegration. In 1893, De Quervain laid down the following criteria by which he recognized pathologic changes: (*a*) modification of the nucleus, (*b*) vacuolization of the nucleolus, (*c*) disappearance of the nucleus, (*d*) diminished staining-capacity, (*e*) swelling of the ganglion-cells, (*f*) fragmentation of the protoplasmic processes, (*g*) shrinking of the cell, (*h*) vacuolization of the protoplasm. He does not consider enlargement of pericellular space as of pathologic significance, even when mononuclear leukocytes are found in it. It must be confessed that these criteria are not entirely adequate, nearly all of the changes described depending in part upon the length of time between death and the fixation of the tissue and upon the methods of preparation. The course of the pathologic changes appears to be somewhat as follows: The granules become first very irregular in distribution and somewhat finer, so that the concentric arrangement is no longer distinct. They may then diminish considerably in number, so that the cell as a whole appears very much paler; finally, the protoplasm may become entirely clear, a small amount of basophilic substance only remaining that is collected in irregular masses around the nucleus. This also may disappear, and the cell remain as an irregular, faintly and diffusely stained mass in the midst of the tissue. This series of changes is by no means the only one that has been described. Occasionally the chromophilic granules seem to dissolve, although their capacity for staining is unimpaired, resulting in deeply and diffusely staining cells without any apparent structure, excepting the vesicle in the situation of the nucleus (*pyknomorphous state*). Nissl regards these as artefacts, and it is true that they are frequently found in tissues supposed to be healthy. It must not be forgotten that they are always far more numerous in diseased tissues or in the neighborhood of focal lesions. I have observed some singularly beautiful examples of this change in the brain of a guinea-pig killed by anthrax, in which the micro-organisms were found in the nervous tissue. The solution, with or without loss of staining-power, corresponds very closely to the changes observed in the chromatin in karyolysis, and may be very properly described as a sort of chromolysis. In other cases chromophilic bodies may collect in diffuse, irregular masses in one or more parts of the protoplasm, a change which I have observed in the spinal cells of cases of tetanus.

Still another form is the coalescence of the chromophilic bodies, so that each individual one appears larger; their number is less, and they still maintain a rather regular arrangement in the protoplasm. These masses may then further coalesce, giving rise to the appearance just previously described, or may break up, causing a uniform granulation of the cell, or they may disappear. Berger has attempted to explain most of these phenomena by sup-

posing that the chromophilic bodies are really composed of small granules that are adherent to the sides of the spaces formed by the reticulum of the protoplasm of the cell. If these spaces dilate, the granules will be more widely separated and the appearance will be that of diffuse granulation. If they contract, as occurs in cases of general cellular contraction, the so-called inspissation of the cell, they will appear darker and the neighboring ones may seem to coalesce. The changes in the reticulum may

FIG. 349.—Degenerated nerve-cells in the neighborhood of a collection of pus; the granular appearance is due to an excess of pigment; × 600 (case of Lloyd and Sailer).

be local, and give rise to local alteration in the arrangement (Fig. 349).

Another change that frequently occurs in pathologic cells is vacuolization. It is possible that a few vacuoles of small size may be the result of the hardening processes. In some cases, however, this alteration is very extensive, the vacuoles reaching 70 μ in diameter. They appear to be filled with a liquid, possibly lymph, that may undergo slight coagulation-necrosis; at least fibrillæ, that may be fibrin, have been observed. The cells often acquire extraordinary appearances. Indeed, it looks as if the pericellular space was enormously dilated, and that bands of protoplasm extend from it to the surrounding neuroglia. The arrangement of the vacuoles is always exceedingly irregular, and if more than one is present, as is usually the case, the vacuoles vary greatly in size.

Sometimes, instead of the vacuoles, there may be found in the cells masses of some substance that differs from the protoplasm. These are usually homogeneous irregular masses that take the acid stain, and have been described as "colloid" in nature, using the word in the sense given to it by von Recklinghausen. The true nature of this change, however, is not very clearly understood. Some-

times the vacuoles appear to be replaced by clefts distributed irregularly in the protoplasm.

In nearly all degenerated cells there is accumulation of a peculiar cellular pigment. This may be fatty in nature, as it stains black with osmic acid. In some cases it seems to increase *pari passu* with the disappearance of the chromophilic bodies, so that ultimately the cell appears as an irregular mass filled with this yellowish-brown pigment. It occurs normally in old age, is found in the cells of the substantia nigra of the crura, is an almost invariable accompaniment of those diseases in which a sort of early senility appears to occur, such as general paralysis, and is rarely found in cells undergoing very acute degeneration.

The changes of the nuclei first appear in the nucleolus; this, as has been said, normally contains one or two vacuoles. In degenerative processes it begins to swell, and more vacuoles develop, so that finally it presents the appearance that has been likened by Berger to the morula stage of the ovum. Ultimately, as the degeneration progresses, it may grow fainter and disappear entirely. Clumps of chromatin are often observed at the periphery of the nucleolus, and occasionally ray-like fibers project from them into the nucleus. Two or more nucleoli have also been observed, but it is doubtful if this is a morbid change.

The nucleus itself exhibits a variety of changes. Stained with hematoxylin, it shows a delicate chromatin reticulum, and this may exhibit, in the ordinary forms of degeneration, changes that are found in other cells in the process of karyolysis; occasionally the chromatin collects in a diffuse, irregular mass about the nucleolus. In various forms of degeneration the nucleus seems to be stimulated, and shows karyokinetic figures, or may even divide completely, so that two nuclei are found in the same cell. This, however, is not necessarily a degenerative change, because similar appearances are found in embryonal and in lacerated nerve-tissue. Perhaps the most important nuclear change, and one that is most certainly pathologic in nature, is the dislocation of the nucleus. It may be found at the periphery of the cell, or even protruding from it, as if to be expelled. Wagner has even described nuclei lying outside the cells without nuclei; but Berger suggests that in these cases the cells have become excessively vacuolated, and that the nuclei lie among the vacuoles, whose situation at the periphery of the cell causes it to appear smaller than it really is. I have never seen nuclei more than slightly protruding from degenerated cells. It has been said that the nucleus can disappear from the cell when it does not present marked degenerative changes; it must be remembered, however, that the large diameter of the multipolar cell renders it possible with a good microtome to make a number of sections through a single cell, and it is very likely that these conditions are due simply to

sections beyond the plane of the nucleus. In the most advanced types of degeneration the nucleus certainly disappears completely.

Changes may also take place in the cell as a whole. In the process of degeneration its outline usually becomes irregular and angular. The cell appears to be smaller, and often the pericellular space is very obvious. In many cases, however, this is an artefact, produced by the hardening fluid, and although it may be also the result of some morbid process, it is impossible to give it any value as such. In the early stages of degeneration the protoplasmic processes may be unimpaired. Varicosities, such as shown by the silver-impregnation, are rarely observed by the Nissl method. I have, however, seen them in the nerve-cells of the cord of a guinea-pig killed by tetanus. Tortuosity of the protoplasmic processes is very common, particularly in chronic conditions, such as sclerosis. It is impossible to stain the terminal ends by the Nissl method, and the changes in the gemmules cannot therefore be recognized. Sometimes the processes become friable, break off, and disappear completely, leaving the cells with a rounded outline. Finally, dislocation in the arrangement of the pyramidal cells has been observed, particularly in cases of sclerosis of the brain, and it is probable that it occurs in all parts of the nervous system, although when the normal arrangement is irregular, it is impossible to estimate its extent. Berger has recently called attention to a very peculiar appearance which may occur in degenerated cells. Sometimes in the portion of the nucleus opposite the nucleolus there is a small projection from the wall which passes inward toward the nucleolus, but before it reaches it, branches into three or four arms that have dilated ends. These seem to encircle the nucleolus, but are not directly in contact with it. He is unable to give a satisfactory explanation of this appearance, but suggests that perhaps it represents some form of duct conveying the secretion of the nucleus to the protoplasm of the cell, ordinarily unstainable, but in degenerated conditions filled with altered fluid.

The **nerve-fibers** are of two kinds, the medullated and the non-medullated. Non-medullated nerve-fibers consist of the axis-cylinder alone. They are found in the olfactory nerve and in the sympathetic nervous system, and when they undergo degeneration exhibit swelling and varicosities, and ultimately break down into a granular detritus. Non-medullated nerve-fibers may also be provided with a sheath, the neurilemma; such fibers are found in some of the cerebrospinal nerves. Medullated nerve-fibers may consist only of the myelin-substance and the axis-cylinder—that is, the neurilemma is absent; such fibers are found in the central nervous system. Ordinarily, they consist of the neurilemma, the myelin-substance, and the axis-cylinder; such fibers are found in the central nervous system and in the peripheral nerves. These

fibers may branch, either giving off collaterals in their course, or forming more or less complex aborizations at their terminations. The axis-cylinder usually exhibits a somewhat fibrillar structure. The myelin-material resembles fat and has a high refractive index. It does not extend the whole length of the fibers, but, at rather regular intervals, is absent (nodes of Ranvier). These points are perhaps for the purpose of providing access for nutriment to the nerve-fiber. Upon the inner surface of the neurilemma are found a few oval nuclei surrounded by protoplasm. The earliest symptom of degeneration in the nerve-fibers is the appearance of granules in the myelin-sheath. These soon run together and form droplets that give all the reactions typical of fat. Such a fiber, examined microscopically in longitudinal section, exhibits these droplets arranged irregularly along its course, giving rise to a somewhat beaded appearance. (Such axis-cylinders may be stained by osmic acid (Marchi's method), or by Sudan III., providing the tissue has not been hardened in alcohol.) The next change is usually found in the axis-cylinder. This may swell and become extraordinarily varicose, so that indeed it loses all resemblance to a nerve-fiber. Instead of being fibrillar, it has an irregular granular appearance, and may contain here and there minute droplets of fat, or the fiber may shrink and become granular, and ultimately disappear, nothing remaining to indicate its previous existence excepting a mass of delicate granular detritus. These changes may be brought about, either by the destruction of the ganglion-cell from which the axis-cylinder forming the fiber arises; or by separation of the fiber from its ganglion-cell; or by injurious agencies acting locally upon the nerve-fiber. The second form of degeneration—that is, taking place in the peripheral portion of the cut nerve—is known as Wallerian. Changes in the proximal end also occur, but rarely extend further than the first node of Ranvier. When a nerve has been divided the earliest change is found on either side of the point of division, and consists in fragmentation of the myelin. About the third day fat-droplets appear in the myelin; there is some swelling of the axis-cylinder; and often proliferation of the nuclei in the neurilemma may be observed. As the myelin breaks down into a fatty detritus, it is gradually absorbed by the compound granular-cells, which appear all along the course of the nerve-fiber, and at the end of three or four months it has entirely disappeared. During this period the neuroglia is undergoing proliferation; at first there is a slight increase in the number of neuroglia-cells; later, the proliferation of the fibers preponderates, and, finally, the degenerated area is occupied by a thick mass of coarse fibers that usually undergo slight contraction. The proliferation of the cells ceases about the time that the fibers have become completely degenerated. The subsequent proliferation, if any, occurs only in the

neuroglia-fibers. The central portion of the separated fiber will, after a long interval, also degenerate; this is possibly due to functional inactivity, and appears to be more of the nature of an atrophy. Thus in amputations that have occurred in early life, the anterior roots, forming the nerves that supply the amputated limb, become smaller and contain fewer fibers, and there is ultimately some degeneration in the ganglion-cells of the anterior horns. Regeneration of nervous tissue occurs in the invertebrates and possibly among fishes and reptiles, although this is very uncertain. Regeneration of nerve-fibers in the peripheral nervous system occurs in all the higher animals, including man. After the nerve-trunk has been cut, the peripheral ends of the axis-cylinder of the central portion of the nerve become swollen and split up into very fine fibrillæ. These grow in various directions, and, if they unite with the distal portion of the nerve, will use it as a skeleton, and one of them, at least, will grow toward the periphery, ultimately forming new nerve-fibers. These changes occur in both sensory and motor fibers. (See section upon the Regeneration of the Peripheral Nerves.)

The **neuroglia** of the nervous system may proliferate or undergo softening, the former change producing various forms of sclerosis or gliosis. Sclerosis of the brain may be either diffuse or circumscribed, and the latter is again subdivided into the hypertrophic and atrophic forms.

Diffuse sclerosis of the brain never involves all parts equally. To a certain extent it is normal in old age, and is usually found to be limited to the most superficial portion of the cortex beneath the pia, or else to the layer of the gray substance adjacent to the white matter. The neuroglia-tissue in either situation appears to be composed of rather coarser fibers than common, either forming wavy bands or a coarse network. Macroscopically the brains exhibit only slight alteration. The consistency may, on account of other senile changes, be even slightly reduced; the gray matter is usually narrower than normal; the pia mater is generally firmly adherent, but not invariably. This condition sometimes occurs in connection with other diseases, as epilepsy, or may be congenital.

Disseminated sclerosis is sometimes only slight in extent. It may occur in the brains of epileptics, of criminals, of old persons, and of idiots. The small sclerotic foci are usually found at the junction of the gray and white matter, more particularly in the former than in the latter. The neuroglia-tissue forms a coarse, irregular network; as a rule, it is unusually vascular and without any or only a few true nervous elements. These areas may be detected, when large enough, by the naked eye, by the fact that they are paler than the surrounding tissue and often slightly sunken. If the process is more extensive and involves the whole thickness of one or more gyri, it gives rise either to the atrophic

or hypertrophic form, or both may coexist in the same brain. The external appearance in these cases is characteristic, and cannot be mistaken for any other process.

In the atrophic form the gyri are reduced perhaps to the thickness of a lead-pencil, they are pale, firm, slightly granular upon the surface and the pia mater may be slightly adherent; but this is not common. Section through one of these convolutions shows that the cortex is considerably thinner and has an immediate tendency to retract. The white substance is also involved, but apparently less severely. The extent of the process is very variable; only one or two convolutions may be affected, perhaps, as in several reported cases of epilepsy, only the cornua ammonis. Sometimes a number of convolutions are affected, and in the majority of these cases there is some tendency to an irregularly symmetrical distribution. Microscopically these lesions show marked hyperplasia of the neuroglia-tissue—that is, increased number of neuroglia-cells and coarseness of the neuroglia-fibers, which, however, form coarser meshes than usual. Many of the neuroglia-cells are swollen, the nuclei are enlarged, pale, and the outlines of the cells are irregular. In some cases a number of the cells show a slight projection upon one side. The nervous elements may appear to be more thickly placed and somewhat irregularly distributed, and the protoplasmic processes of the ganglion-cells are often tortuous. More frequently they are considerably diminished in number or else entirely absent. The myelinated fibers are always decreased, particularly the tangential fibers of the cortex. The vessels are more numerous than usual and often show wide perivascular spaces filled with fibrous tissue. In the most advanced areas, however, the vessels may be entirely absent. Corpora amylacea or kindred products of nerve-degeneration are sometimes found. Ordinarily the neuroglia-fibers are arranged in bands just beneath the pia. Sometimes they form distinct whorls. These changes are usually found in epilepsy and idiocy, and when the lesions occur in the motor region are always associated with motor disturbances.

In the hypertrophic nodular form, the brain, as a whole, is usually somewhat enlarged, and nodules are found in the cerebral cortex that project from the surface and are much harder than the surrounding substance. The larger ones are often slightly umbilicated. The surface of these nodules is often granular. The microscopic changes are similar to those found in atrophic sclerosis, with the exception that the excess of neuroglia-tissue is much more pronounced. In these brains there are often sclerotic areas beneath the ependyma of the ventricles, the lateral ventricles being more frequently affected than the third or fourth. These nodules are small, round, and very hard. Microscopically they are found to consist of neuroglia-fibers arranged in a somewhat

concentric manner. They may be vascular or entirely deprived of blood-vessels, and sometimes contain chalky deposits or masses of hyaloid material. As in all destructive lesions of the central nervous system, secondary degenerations may occur, but they are far less common than would be suspected from the apparent extent of the degenerative processes. These forms of congenital sclerosis probably commence after the seventh month of fetal life, because, as Kundrat has pointed out, the arrangement of the convolutions is rarely disturbed. They have been ascribed to syphilis, to inflammatory change, to congestion of the lymphatic system, and as akin to tumor-formation. The absence of round-cell infiltration, and the fact that the pia is rarely adherent, even when the sclerosis takes place in the most superficial layers of the cortex, would seem to exclude inflammatory causation. Neurogliar proliferation occurs about gumma, but there is no ground for believing that other forms are also due to syphilis. The dilatation of the perivascular spaces is favorable to the theory of congestion of the lymphatic system. This, however, is probably secondary. It is no explanation for this process to say it belongs to the tumors, but at present it appears impossible to give a more satisfactory etiology. Softening of the neuroglia is a part of all processes of softening in the brain, which are described in connection with thrombosis and embolism. A condition that is possibly the result of softening during fetal existence, but may be a congenital malformation, and consists of the formation of cavities in the brain, may be properly described here.

Porencephaly is a condition characterized by the absence of a greater or less amount of the substance of one or both of the cerebral hemispheres, leading to the formation of a cavity or cavities filled with cerebrospinal fluid.

Etiology.—The cause of porencephaly is not definitely known. As Von Kahden remarks, the similarity of the lesions in typical cases is such that it seems reasonable to accept a uniform etiology. Kundrat believed that the lesions were due to anemic infarction, as a result of the occlusion of the Sylvian arteries. Freund also accepts this as the cause in a certain number of cases. Von Kahlden, however, believes that it is the result of some disturbance in a development of the brain, and bases his opinion upon the symmetry of the lesions and their peculiar situation. Other authors have suggested an inflammatory origin of the process, because of the adhesions between the membranes. A certain number of cases certainly develop after birth; these may be due to injury, such as might be produced by instrumental delivery, or by blows upon the skull, or by embolic or inflammatory processes. It can only be said, however, that the etiology is at present unknown.

Pathologic Anatomy.—Von Kahlden has divided the cases hitherto reported into two classes: the typical and the atypical.

The former class comprises about two-thirds of all the cases, and is characterized by the presence of a funnel-like cavity in the motor region of the brain, usually bilateral, although unequal, that extends from the subarachnoid space to the cavity of the ventricle (Fig. 350). Frequently this condition is associated with imperfect development or exposure of the island of Reil. In the atypical form the lesions are exceedingly various; they may be found in any part of the cerebral hemispheres; the shape of the cavity may be either a shallow depression or a considerable loss of substance. Often—

FIG. 350.—Porencephaly (case of Dr. J. H. Lloyd).

in fact, usually—there is no communication between the cavity and the ventricle. These varieties may even be found in the cerebellum, but perhaps are most frequent in the lateral lobes at the point where they unite with the vermiform process. Cases have also been recorded with cavity-formation in the base of the brain, communicating sometimes with one of the horns of the lateral ventricles. A sort of cystic formation has been described, in which multiple cavities, not communicating with either the ventricle or subarachnoid space, have been found in the substance of the brain. The macroscopic changes observed in the typical form are as follows: ordinarily a distinct depression is noticed in the dura after the skull has been removed. When this region is more carefully examined it is found that the dura may or may not be adherent to the arachnoid which covers the cavity. The pia usually dips into and covers the wall, and may be continuous with the ependyma of the ventricle. The adjacent convolutions of the brain are arranged in a somewhat radiate manner and turn down into the cavity, although this is not invariably the case, for they sometimes may appear as if simply cut off, being otherwise normally arranged. Associated changes in the brain are microgyria; proliferation of the neuroglia-tissue, and perhaps also of the con-

nective tissue; atrophy of the nerve-cells in the cortex, particularly of the large pyramidal cells; and more or less complete destruction of the nerve-fibers in the region adjacent to the defect. Rarely there is a sort of cystic degeneration of the walls of the cavity. The spinal cord usually exhibits a secondary degeneration in the pyramidal columns; this, however, is not always the case, for sometimes it appears that one or both pyramidal columns have failed entirely to develop, giving rise to a condition of micromyelia. Other parts of the brain appear to be rarely affected in the typical form of the condition. When the lesion is situated in any other part than the central region, corresponding secondary degenerations may, of course, occur.

THE BLOOD-VESSELS.

The arteries of the brain may be divided into two groups, those nourishing the cortex and those nourishing the basal ganglia. The former are the ramifications of the terminal branches of the circle of Willis; the latter arise directly from the main vessels of the base of the brain.

Atheroma.—The changes that occur in the arteries are those ordinarily occurring in the vessels of the other parts of the body, atheroma of the arteries of the base being perhaps more frequent than of the arteries of the majority of other organs. These atheromatous changes usually lead to calcareous infiltration, and in old age often the entire circle of Willis is composed of typical pipe-stem arteries. When the process is less extensive, the calcareous infiltration is most apt to affect the two internal carotids, the middle cerebrals, and the basilar artery.

Hyaline degeneration may also occur. It is of two kinds: that which forms simply the early stage of arterial sclerosis, and another process that is apparently independent of this, and occurs as a diffuse degeneration of the intima and media. This latter form is frequently found in the brains of chronic idiots even during early life. Occasionally it is also found in senile brains, but in these cases is not so certainly independent of arterial sclerosis. Amyloid degeneration of the blood-vessels may occur as a part of general amyloid disease, but is not especially common in the brain.

Colloid Degeneration.—A rare form of degeneration has been spoken of as colloid, although the material discovered in the blood-vessels seems more akin to that of hyaline degeneration. In this process the adventitia and the media are greatly thickened as a result of their infiltration with a homogeneous translucent material, which may be deposited irregularly in masses, or else cause a diffuse thickening of the wall. The masses project into the surrounding nervous tissue, and may sometimes be detached, forming then independent clumps that are not unlike the so-called amyla-

ceous bodies, although they fail to give all the characteristic amyloid reactions. This condition is usually associated with profound disturbances of the intellect, and may give rise to clinical symptoms that resemble those of general paresis. A case of this nature has been reported by Alzheimer. This colloid or hyaloid material is soluble in boiling water and in alkaline solutions. It stains a bright-red by Van Giessen's method, and usually blue by Weigert's fibrin-method. Sometimes it stains brown with iodin, but not invariably. There is usually extensive degeneration of the nervous elements, which may be associated with secondary changes in the spinal cord.

Syphilis frequently causes *thickening of the intima* or *endarteritis*, which may be due either to the usual round-cell infiltration or to the formation of fibrous tissue. Tuberculosis may also cause endarteritis. This form is most frequently associated with tubercular meningitis, and therefore the basilar artery is the one most frequently affected.

Aneurysms may occur in any of the components of the circle of Willis. The basilar artery is the one most frequently involved, usually just at its posterior extremity. Large aneurysms of the arteries of the brain proper, or of the arteries of the vertex, are exceedingly rare. A saccular aneurysm, as large as a cherry, springing from the anterior communicating artery, was observed at the Philadelphia Hospital. *Miliary aneurysms* of the brain are, on account of their etiologic relation to cerebral hemorrhage, the most important form of vascular disease in the brain (see Fig. 182). These aneurysms may be ectatic or saccular. The ectatic forms are usually fusiform in shape, and often consist of but a single coat of the vessel-wall; that is to say, they are merely endothelium surrounded by a thin layer of fibrous tissue. The saccular aneurysms are usually somewhat larger; they appear as bulbous swellings on one side of the vessel, connecting with the lumen by narrow openings. They may consist of a single wall, as in the fusiform type, the most common variety, or of the intima or adventitia, with a considerable amount of fibrous thickening. Occasionally the fusiform aneurysms may exhibit distinct atheromatous change, but even in these instances the media is atrophic, and they are certainly exceptional. It is doubtful whether arteriosclerosis is of much importance in connection with the formation of these aneurysms, and it is certain that in the majority of cases the first change in the vessel is a fatty degeneration of the media. This leads to local weakening of the wall and to consequent distention; a change that is favored by a considerable degree of pressure, to which the arteries springing from the middle cerebral or from the beginning of the basilar artery are subjected. According to some authors, these aneurysms are to be regarded as herniæ of the intima, really the result of atrophy of the muscularis, nevertheless they are more

frequent in the old, and certainly in the majority of cases in which they are found, the arteries of the base are distinctly atheromatous. The formation of thrombi in miliary aneurysms is exceptional.

CIRCULATORY DISTURBANCES.

Circulatory disturbances in the brain differ from those in other parts of the body on account of the presence of a rigid bony capsule (the skull), which prevents any increase or decrease in the size of the contained viscus. Variations in the quantity of blood, however, do take place in adults, and are rendered possible, first, by the elasticity of the nervous substance itself, which is capable of undergoing a slight degree of compression or extension, and, second, by the free communication of the subarachnoid spaces of the brain and cord and the ventricular cavities, so that the cerebrospinal fluid may be in greater or less quantity in the cavity of the skull or in the spinal canal, and thus permit variation in the amount of blood in either region. Local congestion or anemia may occur as a result of local disturbances, but the free anastomosis of the arteries of the circle of Willis provides such facility in equallizing the amount of blood flowing to the different parts of the brain, that neither is often found in general conditions. In very young children these mechanical restrictions do not obtain, because the fibrous union between the bones of the skull permits of very considerable changes in the size of the cranial cavity.

Acute anemia of the brain may occur as a result of severe hemorrhage, or of hyperemia in other parts of the body, particularly the pulmonary and abdominal organs, and it has been supposed to exist in fainting, during hysterical crises, and in sleep. It must be admitted, however, that certain proof of its existence either as a cause or effect of the three latter conditions is lacking. Microscopically the brain is usually pale and firm. There is little or no tendency on the part of the small venules of the white substance to bleed upon cross-section, and the gray matter is distinctly paler, so that the distinction between it and the medullary substance is not so distinct as is the case in normal tissue. Sometimes in these conditions there is overfilling of the veins of the pia as a result of the shrinking of the brain.

Chronic anemia of the brain may occur in severe cachectic conditions, such as progressive pernicious anemia, lead- or malarial poisoning. It may also be the result, though less frequently, of atheroma of the cerebral arteries, with a general narrowing of their lumina. The brain is small, the consistency varies according to the duration and nature of the process, being at first hard, later, probably as a result of degenerative changes, slightly softer than normal. The ventricles are not dilated at first, but the con-

volutions are shrunken and the sulci are wider as a result of the diminution in size of the brain as a whole. The substance of the brain is pale, and often seems slightly moister than normal. Local anemia may occur as a result of thrombosis or embolism, and usually leads to softening.

Active hyperemia of the brain is nearly always associated with inflammatory or toxic conditions. It is perhaps most frequent in association with meningitis or encephalitis. It is always found after death from sunstroke, acute delirium, cholera, and hydrophobia; as well as, occasionally, after death from infectious disease. It may be local or general.

Local hyperemia is usually associated with meningitis, and may be limited to the superficial layer of the cortex beneath the meningitic areas. The affected parts are darker than normal and may even contain punctiform hemorrhages. Microscopically the blood-vessels are found to be dilated, and there is more or less degeneration of the adjacent nerve-substance, according to the duration of the process. Local hyperemia may also occur after thrombosis, and leads to red softening of the nerve-tissue.

General active hyperemia is supposed to be associated with unusual activity of the mind, particularly prolonged and intense mental effort. Certain proof of this, however, has not yet been furnished. The brain is darker and larger and its consistency is softer. The blood-vessels of the pia are injected. The gray matter is darker and, as in the local form, may contain minute hemorrhagic foci. The white matter is moist; its color is rarely altered, but as soon as the section is made it is covered with small red spots, representing hemorrhages from the veins and capillaries. These may be readily distinguished from interstitial hemorrhages by allowing a little water to flow over the surface of the section, when they will disappear. Microscopically, aside from the distention of the vessels with blood, pronounced degenerative changes are rarely found, excepting in those cases resulting from infectious diseases. In these the alterations commonly associated with severe toxemia are present, but are to be considered as complications, and not as the result of the circulatory disturbances.

Passive hyperemia may be associated with valvular heart-disease or chronic lung-disease, or it may be caused by tumors in the neck pressing upon the jugular veins, or by intracranial conditions. Of the latter, the most important are brain-tumors compressing the veins, whilst the arteries still continue to convey blood, and thus cause increase of the cranial contents. When the tumors press upon the veins of Galen passive hyperemia and distention of the ventricles are particularly common. Passive hyperemia may also be caused by thrombosis of the dural sinuses. In acute passive congestion the veins of the dura are widely distended; the subarachnoid space is moist; the brain

seems to be slightly larger, softer and moister than normal. The gray matter is of a slaty color. The white matter may have a faint bluish tinge, and its capillaries and ventricles bleed freely upon cross-section. The ventricles may not be larger, but appear to contain fluid under pressure, that wells forth when they are opened.

Edema of the brain nearly always occurs when passive hyperemia persists. This is characterized by the distention of the subarachnoid space with liquid, so that the convolutions are no longer distinct, and the surface of the brain has a clear or pearly appearance. The arachnoid is usually thicker, particularly along the sulci. The fluid is clear, or perhaps very slightly turbid; it has a higher specific gravity than the cerebrospinal liquid, coagulates upon boiling, and is usually found to contain numerous cellular elements. A microscopic examination of the brain and its membranes shows marked distention of the subarachnoid space, which is usually divided into irregular spaces by delicate fibrous bands. The endothelial cells appear to have undergone some proliferation, and in many places have desquamated and lie free in the areolar spaces. Around the blood-vessels there is occasionally slight extravasation of round cells, which are usually mononuclear and resemble lymphocytes, and indicate an inflammatory reaction to the long-continued pressure. The arachnoid is usually thicker, the thickening being almost exclusively fibrous in nature. The pia is slightly thicker, and sometimes may be seen to have coalesced with the superficial layer of the cortex. In the brain-substance the perivascular spaces are distended, the neurogliar meshwork is coarser than normal, and there may be slight evidences of degeneration in the cells.

Local edema of the brain, the so-called *apoplexia serosa,* is occasionally found in the neighborhood of areas of softening. In cases of acute hydrocephalus this serous infiltration sometimes occurs in the neighboring internal capsules, and may even lead to transient hemiplegia.

Cerebral hemorrhage occurs in two varieties: the so-called punctate form, and massive hemorrhage.

Punctate hemorrhages are due to some alteration of the vessel-walls or of the degree of blood-pressure, causing extravasation of blood into the surrounding tissues. The hemorrhages are small, often microscopic, and are by far most common in the gray matter, especially in the cortex. The principal causes are hyperemia, particularly if associated with inflammatory conditions of the brain, or convulsions. The wall of the blood-vessel may be diseased, but does not always show solution of continuity. The blood-pigment is more or less altered, according to the length of time that has elapsed between the occurrence of the hemorrhages and the examination of the tissues. The nervous tissue immedi-

ately involved is edematous, and there is usually some proliferation of the neuroglia-cells in the immediate vicinity. Such hemorrhages, of course, may heal without leaving any trace, for the secondary degenerations that may possibly be caused are too slight to be detected.

Massive hemorrhages usually occur from the branches of the middle cerebral artery—that is, from the vessels most frequently the seat of miliary aneurysms. They may also, however, occur in the centrum ovale or the pons, or, in fact, in almost any portion of the central nervous system. The blood usually collects in the form of an irregular dark-red mass that, in recent cases, rapidly becomes bright red upon exposure to the air. The size of the hemorrhagic area naturally varies with its location and the amount of blood extravasated. Its outline is exceedingly irregular, and almost always small separate hemorrhagic foci are found in the surrounding tissue. According to the density of the tissue, the blood is more or less dispersed. Thus, in the white matter the extravasation is usually more diffuse than in the gray, where hematomata are exceedingly apt to form. The substance of the brain is soon converted into an area of softening. Its structure is usually entirely lost, although it may be possible, in recent cases, to recognize the presence of altered cells and nerve-fibers. The neuroglia usually shares in this softening, but in case the hemorrhage is not extensive it may remain and form a sort of skeleton; the tissue then is not nearly so soft, and the surface of section usually is smooth. If the hemorrhage occurs in the internal capsule, as is usually the case, and is at all extensive, the blood may creep inward toward the ventricle, into which it may rupture, filling the lateral ventricle, and sometimes extending into the third ventricle and into the lateral ventricle on the other side (Fig. 351). Occasionally, in exceedingly severe cases, almost the whole of one of the hemispheres may be destroyed; this is usually associated with sudden death, and is known as the foudroyant form of apoplexy. The softened brain-substance can usually be readily washed away by a current of water, leaving the blood-vessels, which may then readily be examined with a low power for the presence of miliary aneurysms. If the patient survives his first attack, rapid alterations begin to take place in the diseased tissue. The thrombus contracts, causing edema in the surrounding tissues. A capsule of delicate fibrous tissue may even be formed about it. The small hemorrhages in the surrounding tissue are absorbed. The color of the softened region becomes dark brown, and it may either go on to complete liquefaction, with the subsequent absorption of the pigment and the formation of a cyst, or else be gradually entirely absorbed, leaving a pigmented scar. The walls of the cysts are usually discolored by pigment, and in the neighborhood pigment-granules and compound granular cells are found in

great numbers. These old hemorrhagic cysts are very difficult to distinguish from those produced by other forms of softening. Often the contents are slightly discolored, the walls are dense and somewhat sclerotic in nature, and may contain crystals of hematoidin. It is somewhat doubtful whether the walls are composed of neurogliar tissue or of true fibrous connective tissue derived from the blood-vessels. It is certain, however, that shortly after extravasation of the blood, hyperplasia of the neuroglia in the immediate vicinity takes place. This may occur very rapidly, so that in the course of a few days new neuroglia-fibers may be seen pushing their way into the hemorrhagic area from the collection of neuroglia-cells in the nearest healthy tissue. After healing has

FIG. 351.—Hemorrhage into the internal capsule and the caudate and lenticular nucleus of the right cerebral hemisphere (from Bollinger).

taken place the hemisphere is usually reduced in size. This reduction is not merely equivalent to the amount of nerve-tissue that has been destroyed, but represents also the secondary degeneration that occurs in the nerve-fibers whose course has been interrupted by the lesion. These are both ascending and descending, and frequently cause sclerosis that involves not only the brain, but extends throughout the pyramidal columns.

Secondary Degeneration after Hemorrhages.—As a result of hemorrhage into the brain-substance with destruction of tissue, secondary degenerations appear, which, of course, are systemic and follow the direction in which the nerve-fibers convey impulses. Of these the most important are the degenerations of the pyramidal tract, of the optic tract, and of the projection-fibers from the temporo-sphenoid lobes. A discussion of this subject involves

consideration of the anatomy of the brain more than of the pathology, and only the most important details can be given here. Degeneration of the *pyramidal tract* may be sharply circumscribed if the focal lesion is situated in the cortex or the centrum ovale. In this case a slender band of degenerated fibers may be traced along the pyramidal tract. This is only possible, however, if the lesion is sufficiently recent to permit the employment of Marchi's staining-method, for it is otherwise impossible to recognize a small number of degenerated fibers in the midst of a group of healthy ones. As the hemorrhage usually takes place from the lenticulo-caudate artery and involves the complete destruction of the pyramidal fibers in the internal capsule, it not unfrequently happens that the entire pyramidal column of one side undergoes secondary degeneration. Hoche, who has recently studied two cases of cerebral hemorrhage, involving complete destruction of the motor fibers on one side, by Marchi's method, has found a rather peculiar distribution of the motor fibers in the crusta. Dividing this region into five parts, he finds that the two median sections are free from degenerated fibers. The middle section is almost completely degenerated, and there is also an area of degeneration in the median part of the fourth section, extending partly into the fifth. Degenerated fibers can also be traced going to the nucleus facialis of the opposite and the same sides, and to the nucleus hypoglossus of both sides. There were also degenerated fibers in the lateral pyramids of the same side. Interruption of the fibers of the *optic radiation*, or destruction of the primary optic centers, causes secondary degeneration which does not, however, appear as promptly as in the motor fibers. There is degeneration in the external geniculate body, in the pulvinar, and in the anterior corpus quadrigeminus of the same side. Ultimately, after some years, degeneration may also occur in the optic nerves. Destruction of the second and third temporal lobes, or of the projection-fibers arising from them, causes secondary degeneration in the posterior limb of the internal capsule. The fibers appear to extend into the thalamus, and also into the crusta. Destruction of other parts of the brain-cortex causes degeneration, which seems to affect chiefly the projection-fibers. Extensive hemorrhages into the cerebellum usually cause death, as a result of pressure upon the medulla. If, however, the patient survives, and if the nucleus dentatus is particularly involved, there is degeneration of the superior cerebellar peduncle, which may be traced as far as the red nucleus in the tegmentum. Degenerations have been produced experimentally in the other peduncles. All these secondary degenerations are quite typical in character. They appear about the ninth day, the first changes being the degeneration of the myelin-sheath. This is followed by the appearance of compound granular cells and hyperplasia of the neuroglia, and later corpora

amylacea may sometimes be found. Ultimately nothing but the neuroglia remains, and this is composed of coarser fibers than are found in normal nervous tissue. Occasionally nerve-fibers without myelin-sheaths are found traversing the sclerotic tissue.

Thrombosis and **embolism** of the vessels of the brain are due to causes that produce the same processes in other parts of the body. Thrombosis may occur anywhere. It is perhaps more frequent in the basilar artery than in other situations, but this rule is by no means certainly established. The causes are, of course, chiefly atheroma of the vessels or syphilitic endarteritis. Embolism, on the other hand, usually occurs in the artery of the Sylvian fissure. Perhaps 80 per cent. of all cases occur in this situation. Less frequently, an embolus will lodge in the anterior cerebral, but it is probably extremely rare for an embolus to travel along the posterior communicating artery and lodge in the posterior cerebral. A more frequent route of embolism into the latter artery is along the vertebrals to the basilar. Embolism in the basilar artery can, of course, never occur, as its lumen is greater than that of either of the branches from which it receives blood. A saddle-embolus may occasionally lodge at its bifurcation and give rise to local thrombosis. Sometimes the two processes occur simultaneously—that is, fragments of a parietal thrombus in one of the vessels may be washed off into the blood-stream and be carried along the artery until they occlude its lumen or that of one of its branches. The results of embolism or thrombosis may be either infarction, or, if the obstruction takes place slowly, as in thrombosis, and it is possible for a collateral circulation to be established, there may be no changes, or such only as are temporary.

Infarction of the brain usually leads very rapidly to cerebral softening (*encephalomalacia*). It has been usual to describe three forms of this—red, yellow, and white softenings.

Red softening corresponds very closely to the hemorrhagic infarct. It consists of a serous infiltration of the tissue, the extravasated liquid containing numerous red corpuscles. The same theories that have been suggested for the explanation of a hemorrhagic infarct have been used to explain its occurrence.

Yellow softening is really only the red softening after more complete liquefaction has taken place and most of the pigment has been absorbed.

White softening is a term applied to two very different conditions. The first corresponds to the anemic infarct, and appears very shortly after the occlusions of the vessels. The second is a late stage of any form of softening, and is characterized by the formation of an excessive amount of fat in the softened area, producing an emulsion. The white color becomes even more pronounced after the fat has been absorbed, and the lesion is represented only by coarse neuroglia-fibers. Macroscopically the

earliest changes usually appear toward the end of the first twenty-four hours. The brain-substance in the softened area is swollen, softer, and somewhat mottled in appearance and may even exhibit small punctiform hemorrhages. The lesion is not sharply delimited, but fades gradually into the surrounding tissues.

If a large artery has been obstructed, a considerable portion of the brain may be softened and there will be a large extravasation of blood. In this case, the parts of the brain showing the greatest alteration are those nearest the periphery of the distribution of the obstructed vessel, and these changes may even occur without complete obstruction if the general circulation is impaired, as in valvular heart-disease, or as a result of profound general anemia. As the process continues, more and more blood is extravasated into the tissue, giving it a bright-red appearance. The lesion by this time becomes more circumscribed, although the surrounding tissue may be somewhat softened, and, as in the case of hemorrhage, may contain punctiform hemorrhages. As soon as the demarcation is complete, the brain-tissue becomes rapidly softer, probably as a result of the obstruction of the lymph-channels by which the nutritive fluids enter. The nerve-cells undergo almost complete degeneration; they lose their axis-cylinders and their tinctability, and may either disappear completely or be no longer recognizable. The myelin-sheaths undergo a fatty degeneration, in which the nerve-fibers soon take part. The whole tissue is filled with compound granular cells. The neuroglia-fibers may also become softened and, to a large extent, liquefied, although they persist longer than the other elements. The wall of what has now become a cyst is composed of the surrounding neurogliar tissue, newly formed capillaries, and nervous tissue in an advanced stage of degeneration. The blood-vessels, however, usually persist for some time, although they are filled with thrombi and form an irregular spongy network in the lesion.

When organization commences the blood-pigment gradually disappears, and the material changes from a brownish, turbid fluid to a lighter yellow mass, often irregularly surrounded by deeply pigmented cells. Later, complete contraction takes place, and a scar, composed chiefly of neuroglia-tissue, but also containing some fibrous connective tissue that has developed from the walls of the blood-vessels, is left. It is, of course, clear, that red softening is more frequent in the vascular parts of the brain, and white softening in those regions that are poorly supplied with blood, particularly in the white substance of the cerebrum. The areas are rarely as well circumscribed as those of red softening, and often do not lead to complete destruction of the tissue, causing only numerous adjacent minute focal lesions, the so-called *état criblé*.

A peculiar form of softening occurs in the cortex of the brain. It is usually found as lesions that have existed for some time.

The area is yellow, depressed, and somewhat circumscribed. The pia mater over and around the lesion is somewhat thickened, and often the surrounding blood-vessels show thickening of the lumen, although this latter change is probably the cause and not the result of the changes. These are the so-called *plaques jaunes* of French writers, and if extensive they lead to considerable retraction of the brain-substance and to the formation of collections of liquid in the subarachnoid space (*hydrops ex vacuo; external hydrocephalus*).

Areas of softening, probably due to capillary thrombosis, are frequently found in children suffering from tubercular meningitis. They may also occur in other forms of meningitis, and also in encephalitis, although in these latter conditions the presence of pyogenic micro-organisms in the emboli lead to somewhat different changes, which will be described in connection with encephalitis. Traumatism may also cause softening, often multiple in character, and not necessarily situated directly beneath the point of injury. As a result of the destruction of tissue, secondary degenerations occur that differ in no respect from those following hemorrhage.

INFLAMMATION.

Encephalitis, or **inflammation of the brain-substance,** is probably not essentially different from inflammation of the other tissues in the body. The nature of nervous tissue, however, and the peculiar reaction that it manifests to various injurious agencies, render this subject one of the most doubtful and difficult in the pathology of the central nervous system. The various forms may be classified, first, as acute and chronic. The important forms of acute encephalitis are the parenchymatous, the simple, the hemorrhagic, and the suppurative. Chronic encephalitis may take the form either of sclerosis or of scar-formation, which is really only a modification of the former. Acute encephalitis may be considered to be invariably disseminated or focal. No case has been recorded in which there was extensive inflammatory change in the brain, and it is inconceivable that such a condition should be compatible with life.

Acute parenchymatous encephalitis is rather a form of degeneration than a disease. Changes in the nerve-cells without associated vascular phenomena have, in the last few years, been observed and described in a number of intoxications, either the result of poisoning or infection; thus Berkeley has carefully studied the changes in the brain in alcoholic poisoning. More or less extensive changes have also been recorded as a result of poisoning by malon nitrite, arsenic, and other poisonous substances. Of the infectious diseases that have been studied, the most important are diphtheria, tetanus, leprosy, and hydrophobia. The changes differ

somewhat in nature, and, of course, in the different cases, considerably in degree. The most important and typical have been already described in the section upon degeneration of the nerve-cells. These forms of encephalitis, if the name may properly be applied to them, may lead to death, but recovery even from the advanced stages is not impossible, as has been indisputably proved by the experimental research of Goldscheider and Flatau. Neither the brain nor the cord in these cases exhibits any macroscopic changes, excepting, perhaps, passive congestion of the membranes when death was preceded by violent convulsions, as in tetanus.

Simple acute focal encephalitis is characterized by the development, in various parts of the brain, of areas of softening that may range from a millimeter to several centimeters in diameter. They are usually irregular in size, and very indistinctly separated from the surrounding tissue. The most common situations are the region of the third and fourth ventricles and the aqueduct of Sylvius. The gray matter is more often involved than the white.

Etiology.—The cause is probably in all cases the presence of infection in the body, such as influenza, typhoid fever, or septicemia. Authors, whose opinions we must respect, have, however, described encephalitis as the result of simple concussion of the brain, or of various forms of poisoning, such as lead. The difficulty in the latter group of cases is due to the close resemblance between encephalomalacia and encephalitis. Collections of round cells, with slight degenerative changes in the nervous system, have been described in chorea, and have been supposed to represent the subacute or chronic form of encephalitis. The observations are, however, at present insufficient to establish this point. References will be made again to it under the heading of Chronic Encephalitis. Some years ago, various observers reported the occurrence of acute encephalitis in new-born children, but it has since been shown that compound granular cells occur normally in the brain of the fetus and persist for some days after birth.

Pathologic Anatomy.—The two most important changes are those in the color and consistency. The former is usually slightly darker than normal, but may, if, as is not unfrequently the case, extensive hemorrhage has occurred, become a bright red, resembling, upon inspection, an area of hemorrhage, or perhaps more closely, an area of red softening. The consistency is always decreased, probably as a result of serous infiltration. Often the diseased area projects slightly from the surface of the section. Microscopically the characteristic change is the perivascular round-cell infiltration. This usually involves the majority of vessels in the lesion, and may also be found in regions of the brain in which softening has not already commenced. Usually there is the characteristic inflammatory congestion, the blood-vessels, and particularly the small capillaries, being sometimes greatly

distended and packed with red blood-cells. In some cases thrombi have formed. Hemorrhages are exceedingly frequent; these are sometimes punctiform and sometimes diffuse extravasations into the tissue. Often they appear to represent ruptured capillaries, and produce a peculiar speckled appearance on the surface of section. In the early stages the cellular exudate is chiefly composed of polynuclear leukocytes. If the process is more advanced, these may exhibit more or less degenerative changes. Later they are replaced by mononuclear cells, probably representing proliferation of the endothelial cells, and perhaps of the neuroglia-cells. The ganglion-cells in the inflammatory region undergo rapid degeneration, usually passing through various stages of chromatolysis, until they are reduced to little colorless vesicles of irregular form. The nerve-fibers also degenerate; the myelin forms fatty droplets; the axis-cylinders at first swell and then share in the granular disintegration. In the midst of the focus, the neuroglia ordinarily shares in the softening. At the periphery there is usually a noticeable proliferation of the neuroglia-cells and the formation of a coarse, thick network of neuroglia-fibers. Of course, these changes are not found about very early lesions. In the earliest stages compound granule-cells are usually absent; later they may appear in considerable numbers, but their presence is by no means sufficient to indicate the existence of an acute or chronic inflammatory process. Disappearance of the tangential fibers in the cortex, in lesions situated in this area, have also been described. Ordinarily in these forms of encephalitis, the rest of the brain exhibits no macroscopic changes, and often none can be detected by the microscope. The membranes are smooth, the vessels of normal elasticity, and not surrounded by a round-cell infiltration. Complete resolution may perhaps occur; of course, this can only be supposed from the clinical symptoms of the disease, there being no definite experimental or pathologic evidence to support it.

The focal lesions may undergo softening and lead ultimately to scar-formation; and if they are extensive, there will be considerable atrophy of the affected part of the brain. The great majority of cases, however, in all probability terminate fatally. The nature of the process is generally accepted to be primarily vascular; the secondary changes being the result of alteration in the nutrition of the surrounding part.

Suppurative encephalitis has already been in part described in connection with purulent meningitis. In that condition, the pyogenic emboli appear to enter the brain-substance along the lymphatics that dip into it from the pia. They are usually small, not circumscribed, and more apt to be found in the gray matter of the cortex, particularly near the base of the brain and in the structures adjacent to the ventricles, than in the white substance. Oc-

casionally, larger collections, forming rather ill-defined abscesses, are found.

Abscess of the brain is a condition characterized by the presence in the brain-substance of one or more cavities containing pus. The usual cause is suppurative bone-disease, particularly that resulting from otitis media. The condition may, however, occur in general pyemia as a result of metastasis from some neighboring or remote focus of suppuration. Suppuration may also occur in the course of pneumonia, or in chronic suppurative diseases of the lungs, such as fetid bronchitis. Direct infection of the brain, either experimentally or as a result of wounds penetrating the skull, has also been observed. In many of these cases the nature of the transmission is clear; thus the abscess resulting from disease of the ethmoidal sinuses or from direct inoculation is usually situated in the immediate neighborhood of the original focus. Abscess secondary to pulmonary disease is usually found at the base of the cerebral hemispheres, and is probably transmitted along the retropharyngeal lymphatics. Abscess due to injury without penetration of the skull has occasionally been recorded. Sometimes it is found in the contused area, sometimes on the opposite side of the brain. The micro-organisms that have been found in the pus are practically all the pyogenic forms. The most frequent are, perhaps, the staphylococcus, the streptococcus, and the pneumococcus. Occasionally the actinomyces, the Bacillus pyocyaneus and the Bacillus tuberculosis have been found, the latter in cases that were apparently acute abscesses of the brain, and not softened solitary tubercles.

Statistical studies of the literature show that in about two-thirds of all cases the cerebrum is the seat of the lesion. In the remaining third it is chiefly the cerebellum. Unusual seats are the pons, crura, and medulla. This distribution does not, of course, apply to the disseminated forms of purulent encephalitis. Solitary abscesses are usually the result of embolism or extension from the bones. They may be small or of considerable size, and one is on record from which 400 c.c. of pus were removed. They may be either surrounded by softened brain-substance or distinctly encapsulated. The latter condition usually occurs if they have lasted any length of time—that is, three or four weeks; although cases are on record in which a distinct wall did not develop about an abscess that had existed for several months. The wall, when it exists, varies in thickness from a half to several millimeters. The contents of the cavity are pus and detritus, and in it may frequently be found thrombosed blood-vessels. The surrounding brain-tissue is usually undergoing softening. It may be either white, or, as a result of hemorrhagic extravasation, red in color. The abscesses usually spread more or less gradually; that is to say, there is probably no tendency to heal spontaneously.

If large, they cause considerable intracranial pressure, which is indicated by the flattening of the convolutions or bulging of the brain after the skull has been trephined. Those due to punctured wounds are usually associated with meningitis. Those due to caries must also be associated with inflammatory changes in the meninges, and not unfrequently there is thrombosis of the cerebral sinuses. Microscopically, we find the ordinary characteristics of pus. The wall or periphery is usually undergoing fatty degeneration, and there is a considerable accumulation of round cells in the surrounding tissue. Multiple abscesses are usually metastatic. A group may be found either in one situation in the brain or they may be very widely distributed. Occasionally the course of the case is so chronic that secondary degeneration may occur. In such a case, examined by Sailer, with abscesses in the cerebellum, cerebrum, and particularly the pons, there was degeneration of both pyramidal tracts. This, of course, is a rare condition. In cases of severe encephalitis, more or less pronounced changes may be observed in the ganglion-cells in other parts of the central nervous system.

Primary Acute Hemorrhagic Encephalitis.—Strümpell has described under this name a form in which the dura was normal but somewhat dry; the pia injected, the centrum ovale softened, edematous, slightly pinkish or gray, and marked by fine hemorrhagic points. Microscopically there were no granular cells, but drops of myelin and some detritus. There was some hyperemia and cellular infiltration of the pia. The ganglion-cells of the cortex were normal. In the white matter the vessels were distended with blood and surrounded by a thick mass of round cells; the perivascular spaces were distended; the neurogliar tissue coarser than normal. In many situations there was bleeding from the capillaries.

General Progressive Paralysis.—There has been much diversity of opinion concerning the true nature of general progressive paralysis. The lesions hitherto described have varied in nature and situation. Nevertheless, there seems to be good reason to accept an infectious origin of the disease, and unquestionably the symptomatology and, to a certain extent, the morbid changes indicate that the brain is the organ chiefly involved. The changes found most frequently are as follows: the dura mater is adherent to the skull; it may be thickened, and often shows upon its under surface the exudate of a hemorrhagic pachymeningitis. The arachnoid is thickened and opaque, particularly along the course of the veins; and in the subarachnoid space there is often a considerable effusion of liquid. The pia mater is thickened and opaque, and may or may not be adherent to the cortex; in the latter case the subpial areolar tissue is distended with fluid. Microscopically, there is often found a round-cell infiltration about

the blood-vessels; their walls are thickened and show some hyaline degeneration. The fluid in the areolar spaces may be clear, or, as is more commonly the case, it is viscid and even colloid in nature. The gross appearance of the brain is frequently considerably altered. The convolutions are flattened; the sulci broader than normal; the consistency of the brain is slightly increased; the cortex is usually pale and greatly reduced in thickness. The white matter may appear to be slightly looser in texture, but ordinarily presents no change. Microscopically, the blood-vessels in the cortex have thickened walls, and occasionally one is found with a completely obliterated lumen. There is usually distention of the perivascular spaces, which may be filled with round cells and various products of degeneration, such as pigment-granules. The glia-cells are greatly increased in number, although it is difficult to decide whether this is absolute or relative. The neuroglia-fibers are usually slightly coarser than normal. The tangential fibers of the cortex may be reduced in number or entirely absent. The ganglion-cells exhibit a great variety of alterations. The protoplasmic processes are varicose, and when sufficiently well impregnated show the absence of the gemmules. The axis-cylinder is usually distinct, due to the degeneration of the myelin-sheath. The body of the cell may be irregular and vacuolated, and there is often extensive chromatolysis. The ventricles of the brain are usually slightly distended, probably the result of simple atrophy, and the choroid plexus is often cystic. Changes are frequently found in the spinal cord. The ganglion-cells in all parts show pronounced degenerative characteristics. This is particularly interesting in view of the fact that the motor symptoms progress so gradually. The posterior roots are often slightly degenerated, and there is systemic degeneration of the posterior columns not unlike that found in the early stages of tabes dorsalis, excepting that ordinarily it is most pronounced in the cervical region. The pia and arachnoid of the cord, particularly those portions covering the posterior columns, are thickened and more or less adherent. The dura is often markedly thickened, and may exhibit pachymeningitis. The etiology of progressive general paralysis is not clear. The great majority of cases commence in middle adult life, and have been preceded by an attack of syphilis. Certain cases, however, fail to give any syphilitic history, and present no signs of the disease.

Chronic encephalitis may take the form of sclerosis or of scar-formation, which is really but a variety of sclerosis.

Lobar sclerosis is usually an extensive but sharply circumscribed process affecting the whole or part of one or more lobes of the brain. The involved area is usually considerably diminished in size. The convolutions are smaller, the sulci broader, but, of course, not so deep; the surface is often finely granular, and the

pia is adherent. The consistency is greatly increased, the tissue being almost like cartilage. Microscopically there are the same changes found in the other forms—that is, excessive proliferation of the neuroglia, with partial or complete disappearance of the nervous elements. The cause appears to be some vascular disturbance occurring during fetal existence, as the localization nearly always corresponds to the distribution of one of the arteries supplying the brain. If the anterior cerebral artery is affected, the frontal lobe is sclerotic. If the artery of the Sylvian fissure is involved, there will be sclerosis of all the hemispheres, with the exception of a part of the occipital lobe; and if the lesion is situated on the proximal side of the lenticular striate artery, this part will also be degenerated. If the posterior cerebral artery is occluded, the lesion will be found at the tip and in the lower half of the occipital lobe. Extensive secondary degeneration always occurs in this form.

Multiple sclerosis is a condition characterized by the formation throughout the nervous system of various foci in which the neuroglia is somewhat hyperplastic, the myelin-sheaths more or less degenerated, and the axis-cylinders, as a rule, slightly, if at all, affected. The sclerotic areas are of very irregular size and distribution, and are much more frequently found in some situations than in others. When they affect the white matter of the brain and cord they appear as grayish or grayish-pink areas, which may even, if at the surface, be observed through the pia. They resemble the gray matter of the cord too closely to be clearly distinguished from it. Their edges are usually sharp. After hardening in Müller's fluid they appear of a bright-yellow color and are exceedingly distinct. The smallest may be only a millimeter in diameter, and the largest may occupy the whole transverse section of the spinal cord or even entire convolutions of the brain. Occasionally sclerotic areas may be found in the nerve-roots. The most important change that is found upon microscopic examination is a thickening of the walls of the blood-vessels. This resembles hyaline degeneration, and may be so extreme that the lumen is almost obliterated. The perivascular lymphatic space is often filled with cells containing droplets that stain black with osmic acid. Occasionally the vessels appear to be increased in number, although this is possibly due to contraction of the surrounding tissue bringing them more closely together. Immediately around the diseased vessels the neuroglia is proliferated. In the center of the foci the neuroglia-cells are not markedly increased; in the periphery, however, they seem to have undergone a distinct hyperplasia. The neuroglia-fibers throughout are somewhat thicker and more irregular, and form a large-meshed network. In the midst of the neuroglia compound granular cells and amyloid bodies are often found. If stained by Weigert's

method, it is at once evident that the myelin-sheaths have disappeared almost entirely, all the sclerotic areas appearing bright yellow. If the Marchi method be used, however, a certain number of degenerated myelin-sheaths will be found, as a rule, still present. The edge of the sclerotic area does not end as sharply as appears macroscopically, but gradually fades into the healthy tissue. The axis-cylinders, in spite of the destruction of the myelin-sheaths, are nearly always present, and apparently normal, a fact which explains the absence of secondary degeneration beyond the lesions. In those situations where the hyperplasia of the neuroglia-fibers is most pronounced, the axis-cylinders may be swollen or show partial fatty degeneration, or be entirely absent. Popoff believes that these persistent axis-cylinders are not those that originally pass through the lesion, but are regenerated nerve-fibers; a view, however, for which there is not sufficient proof. The ganglion-cells are shrunken and pigmented, and may, in rare cases, completely disappear. In advanced cases of the disease, the process resembles more closely a chronic myelitis; the axis-cylinders passing through the lesion may be totally destroyed and secondary degeneration occur. In those cases that have been studied in the early stages of the process perivascular inflammatory changes have been present, and it is about these that the sclerotic areas have formed. In some cases thrombi have been also detected in the vessels, and many of them showed the early stages of hyaline degeneration. For this reason, and because disseminated sclerosis frequently develops after an infectious disease, it is generally accepted that the process is due to infectious embolism, a view particularly supported by Marie. Certain authors, however, particularly Taylor, hold that the vessels are not the primary origin of the disease, as in many of the sclerotic foci they are perfectly healthy.

INJURIES TO THE CENTRAL NERVOUS SYSTEM.

Injuries to the central nervous system produce a great variety of lesions, according to their nature and severity.

Concussion, either from a single shock or from repeated blows, may give rise to transient or permanent changes. In the latter case autopsies have shown the existence sometimes of multiple hemorrhages, sometimes of disseminated areas of sclerosis in the white and the gray substances. Occasionally in the spinal cord, after experimental repeated concussions, changes, somewhat systemic in character and affecting chiefly the posterior columns, have been observed. The hemorrhages may be punctate or, in some cases, particularly if the injury is severe and the arteries diseased, massive.

Lacerated wounds of the brain are usually produced by fract-

ure of the skull. There is extensive interstitial hemorrhage and softening, and the surrounding tissue is edematous. If only subdural hemorrhage occurs, it may produce compression with secondary yellow softening. Any of these lesions may heal with the formation of a scar and the production of more or less extensive secondary degeneration. Extensive lacerations of the brain are sometimes the result of injury during birth, giving rise to so-called cerebral palsies of childhood. In these cases, as the central nervous system is not fully developed when the injury occurs, there is hypoplasia of the affected parts.

Punctate wounds of the brain are due to fragments of bone, to sharp instruments, or to bullets. In nearly all cases a certain amount of infection occurs, giving rise to encephalitis. The injured area usually undergoes complete necrosis, and this extends for some distance into the surrounding tissues. The necrotic area is composed of a granular detritus, in the midst of which are found altered blood-pigment and broken-down nuclei. At the periphery there is usually some granulation-tissue, proliferation of the neuroglia, and more or less round-cell infiltration, according to the intensity of the inflammatory process. Experimental lesions may be produced in various ways; the most interesting results, perhaps, being those found after the introduction of foreign bodies, or after careful aseptic laceration. In either case, shortly after the operation, necrotic changes will be found in the enlarged area. There is marked proliferation of the neuroglia-cells, even as early as the third day, and of the neuroglia-fibers. New capillaries may be seen pushing into the area, the endothelial cells of their walls exhibiting karyokinetic figures. The nervous tissue in the immediate neighborhood is in various stages of degeneration. The myelin-sheaths form balls of fat; the ganglion-cells become swollen, vacuolated, and lose their protoplasmic processes. If there has been much hemorrhage, the blood-pigment will be found in irregular homogeneous masses or in the form of hematoidin-crystals. Later, evidences of regeneration in the nervous tissue may be observed, particularly the appearance of karyokinetic figures in the nuclei of the ganglion-cells. The enlarged area is ultimately replaced by a mass of coarse neuroglia-fibers containing, usually, fewer cells than normal. That true regeneration of the central nervous system ever occurs in the human body is exceedingly doubtful; indeed, it is not certain that it occurs in any of the vertebrates, although after removal of the tail in lizards a spongy mass of neuroglia may be found in the new organ.

INFECTIOUS DISEASES.

Tuberculosis occurs in the brain in the form of *miliary tubercles* or as large masses, the so-called *solitary tubercle*, or *tyroma*.

Miliary tubercles are met with in association with tuberculous meningitis. They are most frequent at the base of the brain.

Solitary tubercles occur independently of tuberculosis of the meninges. They are more frequent in children than in adults, and usually occur in cases in which there is tuberculosis of other parts of the body, notably the lymphatic glands. The infection reaches the brain through the blood-vessels. The lesions are rounded masses of grayish or yellowish color, sometimes showing fresh gray tubercles at the periphery. The growth of the mass is caused by increase in size of the original tubercles and by conglomeration of new-formed tubercles at the periphery. Early caseation is usual. Secondary infection of the pia sometimes occurs.

Syphilis appears in the brain in the form of gummata or as a diffuse vascular disease with secondary degenerative conditions.

Gummata usually begin in the subarachnoid space, originating in the membranes and involving the brain-substance secondarily. The dura may be simultaneously involved, and the three membranes may be adherent to each other and firmly attached to the brain. Primary gumma of the brain-substance is certainly very rare. In the earlier stages the gumma is a grayish and rather translucent growth, but secondary caseation occurs so rapidly that the primary stage is rarely observed. As a rule, the lesion appears in the form of an irregular, dry, caseous area occupying the cortical portion of the brain and attached to the pia and arachnoid, and even the dura. Microscopically the substance of the growth consists of round and spindle or stellate cells in the earlier stages, and of granular material in the later stages. The cerebral substance surrounding the growth is more or less softened and degenerated. The blood-vessels in the affected area or its vicinity are the seat of endarteritis, which in some cases causes complete occlusion of the lumen. In hereditary syphilis symmetric gummata of the brain are occasionally found.

Syphilitic disease of the blood-vessels of the brain takes the form of more or less diffuse endarteritis. Secondary degenerations and softening, or sclerosis, of a diffuse or focal character, may result from the vascular disease; but neither these changes nor the vascular changes are peculiar and distinctive.

Actinomycosis of the brain is generally secondary to actinomycosis of the tissues of the neck, and results from extension upward through the base of the skull. The membranes are first involved; the brain-substance secondarily. The lesion may take the form of a chronic abscess or may be tumor-like in appearance.

TUMORS.

Tumors of the brain are important clinically on account of their situation rather than on account of their nature. The

most common is probably glioma, but almost equally as common is sarcoma. Carcinoma, excepting the form springing from the lateral ventricles, is almost never a primary growth, but secondary nodules are frequently found in the brain. Cholesteatoma, lipoma, endothelioma, and teratoid cysts also occur, but they spring from the membranes, and have been described in connection with them. Gumma and tyroma also occur very frequently in the brain, but as their etiology is infectious they are described in connection with the infectious conditions.

Glioma usually appears as an infiltrating mass, causing little alteration in the structure of the brain, somewhat harder in consistency than the brain-substance, and slightly darker. It is rarely a multiple growth, and shows no marked predilection for any particular portion of the brain, although it occurs more frequently in the cerebral hemispheres than in the basal ganglia or the cerebellum. It always springs from the neurogliar tissue of the central nervous system, and is remarkable for its extreme richness in cells, that by suitable staining-methods may be shown to possess protoplasmic processes (*astrocytes*). These protoplasmic processes, either wholly or in part, form the so-called matrix of the tumor, which appears to be composed of numerous fine, interlacing fibers, in the midst of which, by the ordinary staining-methods, the cell appears to lie. Usually the tumor is exceedingly vascular, the vessels consisting of small capillaries or larger spaces lined with endothelium, and this vascularization may be so excessive that the tumor in parts has a delicate pinkish or reddish color, giving to the cross-section a mottled appearance. Stroebe considers as one of the characteristics of this tumor the fact that it does not infiltrate the pia mater, and can invariably be shown not to spring from it. In some cases the consistency of the tumor is quite hard, and in these the cellular elements are increased in amount proportionately to the fibrous tissue. Ordinarily true nervous tissue is absent from the midst of the tumor, the mass in the center being made up of the neuroglia-tissue. This gradually diminishes toward the periphery, and ultimately fades into the true nervous tissue, that may be somewhat edematous. In some cases, however, as in ordinary sclerosis of the central nervous system, myelinated nerve-fibers may be found in the midst of the tumor, and it frequently happens that the secondary degeneration extending from a glioma is much slighter than the apparent extent of the process would lead one to expect. Occasionally, either glioma-cells, or possibly ganglion-cells, that have undergone proliferative changes in the midst of the growth, may be found. These are much larger than the ordinary cells and contain numerous branched processes, and often one or several large nuclei. This is the so-called *ganglionar neuroglioma.*

Some pathologists hold that the starting-point of glioma is always one or more ependymal cells that have been displaced in embryonal existence and have failed to assume the type of glia-cells, basing their theory in part upon the atypical shape of many of the glioma-cells.

Sarcoma of the brain is probably the next most frequent tumor. It usually occurs in middle adult life, although it is quite frequent in children. The commonest seat is the cortex, which it probably invades from a primary focus of proliferation in the membranes. The tumors are ordinarily nodular growths, usually distinctly circumscribed from the surrounding tissue, and in some cases even surrounded by a fibrous capsule, from which they can be readily removed. They are rather firmer than the brain-tissue, and sometimes slightly umbilicated if at the surface. The surface of section is pale and dry, but frequently mottled on account of the presence of hemorrhages. If primary, the sarcomata are single; if secondary, more frequently multiple, and in these cases they are very apt to be found upon the convex surface of the hemispheres, forming, if large, irregular flattened masses. Histologically, almost any type of sarcoma may be found, the most frequent, perhaps, being the round-cell, non-pigmented form. Giant-cells are very frequently found. In the midst of true sarcoma, proliferated fibrous tissue is not found, but many of the tumors are traversed by fibrous trabeculæ, and some of them contain considerable masses of fibrous tissue, giving rise to the so-called fibrosarcoma. Ordinarily the tumors are extremely vascular, and occasionally contain interstitial hemorrhages. The surrounding brain-tissue shows the symptoms of marked compression, is edematous, and may contain small interstitial hemorrhages. The true nervous substance is ordinarily degenerated, and we find extensive secondary degeneration as a result of the presence of the tumor. Sarcoma springs primarily from the brain, and nearly always grows toward the surface and infiltrates the pia mater.

Certain forms of tumors have been described, probably sarcomatous in nature, that appear to spring from the adventitia of the blood-vessels. They consist of masses of cells usually sharply circumscribed, somewhat cylindrical in shape, having in their center a small lumen in which blood-cells may sometimes be detected. The cases reported of this form of tumor, the so-called *perithelioma*, are very few and somewhat uncertain.

Many authors believe that a combination of glioma and sarcoma may occur, and gliosarcomata have been frequently described. As the neuroglia-tissue has the functions of connective tissue, and in many respects resembles it in its pathologic processes, it is natural that a glioma should be similar to a sarcoma, and this has possibly caused an error of diagnosis in some cases. As the two tumors arise from tissue of different natures, and develop in different situations, their combination is theoretically unlikely.

Fibroma occurs as a hard, circumscribed tumor, sometimes found in the hemispheres, but it is extremely rare.

Lymphangioma appears to arise from the pia.

Osteoma is usually an extension inward from the skull or membranes, but occasionally occurs as a tumor, apparently originating in the brain-substance, forming hard masses from the size of a pea to that of a cherry, and somewhat irregular in shape.

Psammoma.—This special term has been given to tumors containing calcareous granules. It has already been mentioned in connection with the choroid plexus and the membranes. Occasionally circumscribed fibrous tumors containing calcareous gran-

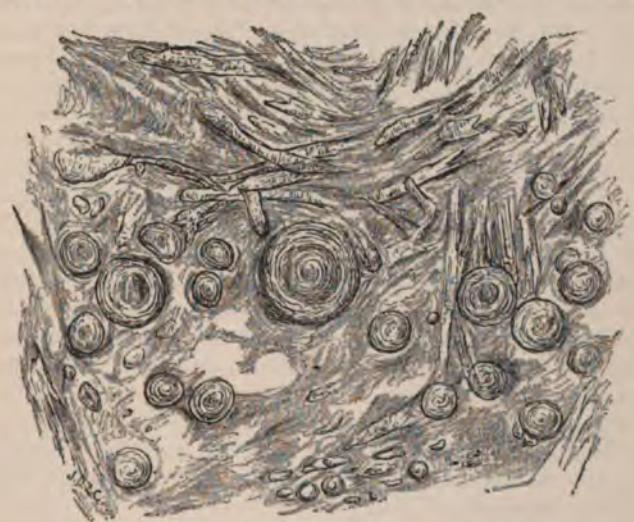

FIG. 352.—Psammoma, showing calcareous spicules and whorls.

ules are found in the brain-substance, but these are extremely rare (Fig. 352).

Carcinoma of the substance of the brain is invariably a metastatic growth. It appears either as small, round, circumscribed nodules, of firm consistency and pale color; or as larger, more or less infiltrating masses with softened interior. Histologically, the tumor may present any type of carcinoma, according to the nature of the primary growth. It usually replaces entirely the nervous tissue, either pushing it aside or destroying it, and gives rise, therefore, to more or less pronounced secondary degeneration. Multiple metastatic carcinomatous growths, however, may exist in the brain without causing clinical symptoms.

THE CHOROID PLEXUS.

The **choroid plexus,** as has been stated, consists of a plexus of vessels derived from the mesoblast, that are everywhere cov-

ered by a layer of cuboidal or columnar epithelium. Histologically, therefore, it consists of an inner layer of endothelial cells and an outer layer of epithelial cells, separated by a small amount of areolar fibrous tissue. This condition is most distinct and typical in the lower vertebrates, particularly in amphibians, in which the choroid plexus consists, in some parts, of a single vessel covered by epithelial cells. The structure of the choroid plexus, therefore, bears a very close resemblance to the structure of the glomeruli of the kidneys, and, as it is obvious that the blood-vessels of which it is composed can have no nutritive function, excepting in so far as they supply the epithelium that covers them, it has been supposed that the choroid plexus is a secretory organ, its object being to secrete the cerebrospinal fluid. This theory is sustained by the fact that the cerebrospinal fluid differs in composition from the lymph, or from the fluid poured out in serous exudations. It would naturally be supposed, therefore, that in all conditions in which the alterations in the composition of the cerebrospinal fluid have been detected, there is primarily some disease of the plexus.

Inflammation.—In inflammatory conditions, particularly meningitis, encephalomyelitis, and ependymitis, either separate or combined, and associated with the presence of an abnormal quantity of albumin in the cerebrospinal fluid, more or less inflammation of the choroid plexus is usually found. This is indicated particularly by round-cell infiltration about the vessels and beneath the epithelium. Sometimes there is a slight amount of exudation upon the epithelial surface, and occasionally small foci of suppuration can be detected.

Infectious Diseases.—Among the infectious diseases the only one of importance is tuberculosis. In this condition miliary tubercles or large cheesy foci may be found.

Chronic inflammation appears to be exceedingly rare, or, what is probably more accurate, has rarely been described, for there is every reason to believe that the choroid plexus shares in all conditions that involve the pia mater. Atheromatous conditions seem to be very infrequent, but a certain amount of thickening of the walls of the vessels may be observed in old age. A certain amount of overgrowth of connective tissue, sometimes associated with slight round-cell infiltration, is also occasionally found in old people.

Hemorrhage may take place into the choroid plexus, and is usually an agonal phenomenon.

Degenerations.—*Calcification* is the most frequent of the infiltrations. This may be recognized by the gritty sensation upon cutting into the choroid plexus. Microscopically, the calcareous nodules appear as minute dark granules that stain purplish with hematoxylin. Masses of cholesterin are by no means uncommon;

they rarely present the form of typical cholesterin-plates, but are somewhat irregular in outline, of a faint yellowish color, and shine brightly when examined by oblique light. Both conditions are common in old people.

Pigmentary infiltration probably also occurs, certainly in malaria, and perhaps in old age.

Amyloid degeneration occurs in cases of amyloid disease.

Tumors.—A great variety of tumors occur in the plexus. *Cysts* may be either retention- or extravasation-cysts, or parasitic. The retention-cysts may be lined with epithelium, and probably represent adhesions at the edges of fissures with persistence of secretory activity. More commonly they are lined with endothelium and represent dilated lymph-spaces. They may be single or multiple, and often are more numerous upon one side of the brain than on the other. They appear as small translucent sacs, filled with a clear, slightly yellowish liquid, or else a colloid-like, viscid mass. Parasitic cysts are usually due to Tænia solium. They may be either single, the Cysticercus cellulosæ, which may be attached to the plexus or lie free in the ventricular cavity, or multiple, forming the so-called Cysticercus racemosa of the brain.

Among the benign tumors, *fibromata*, possibly but organized thrombi, and *lipomata* have been described. The latter is exceedingly rare, and is usually associated with multiple lipomata in other parts of the brain. A *dermoid cyst* has been reported by Lebert. *Endotheliomata* may spring from the lymphatic space. They are small, white, infiltrating growths, of firm consistency. They possess, microscopically, the ordinary alveolar structure, the cavities being lined by endothelial cells, which have proliferated and may lie loose in or fill up the lumen. *Epitheliomata* may arise from the epithelial covering. Two varieties have been described: the *papillomatous epithelioma* is a small, often microscopic, tumor that appears as a villous outgrowth upon the surface of the plexus, and is composed of flat or polygonal epithelial cells, with distinct evidence of proliferation that may, in the lower layers, cause a breaking through of the basement-membrane. These tumors, however, are apparently non-malignant. The so-called cylindrical carcinomata also occur. These grow very rapidly and usually become attached to the wall of the ventricle, and from this situation invade the substance of the brain. They are alveolar in structure and soft in consistency. There is some doubt as to whether these tumors do not arise from the ependyma, and it has also been suggested that they are sarcomatous in nature and spring from the adventitia of the blood-vessels. They are usually single growths and do not give metastases. The choroid plexus, as a whole, may be altered, by the presence of cysts, into a mulberry-like mass, or by a general fibrous change, into a pale, solid body of cylindrical shape with a finely granular surface.

THE VENTRICLES.

The **cerebrospinal fluid** is a clear liquid with a specific gravity of about 1008, a slightly alkaline reaction, and a faint salty taste. The fluid obtained from a calf was carefully studied by Nawratzki, and it was found to contain 1.093 per cent. of solid material, of which about 0.8 per cent. was organic. The average quantity of albumin was 0.02 per cent., just sufficient to cause a slight opalescence upon boiling. The same author has also examined the cerebrospinal fluid in human beings, and finds that it is very similar in composition, with the exception of the greater proportion of albumin, which at times reaches 0.177 per cent. Fresh cerebrospinal fluid from either man or the lower animals contains a small proportion of grape-sugar, equivalent to between 0.17 and 0.27 per cent. According to Halliburton and Hammersten, the reducing substance is not sugar, but brenzcatechin. This reducing substance invariably disappears within a few hours after death.

Pathologically the fluid may show the following changes. The color may become yellowish from the admixture of blood, or turbid from the admixture of pus. Micro-organisms are frequently found in it in all forms of meningitis, but particularly in epidemic cerebrospinal meningitis. It must not be forgotten, however, that in the late stages of this and in the early stages of meningitis due to the tubercle-bacillus, the fluid may be clear. Nawratzki observed a considerable increase in the amount of albumin as the only change in a case of hemorrhagic pachymeningitis. Microscopic examination, even in normal cerebrospinal fluid, usually shows the existence of some blood-discs and leukocytes. In pathologic changes a greater or less number of pus-cells may be present, and often there is a considerable amount of fibrin.

Hydrocephalus.—Excess in quantity of the cerebrospinal fluid in the ventricles is known as hydrocephalus. This may be produced by a great variety of causes. It may be congenital, and perhaps due to a malformation, but is more often a result of disease. Congenital hydrocephalus frequently appears to be due to some defect on the part of the parent, and is particularly common in the children of drunkards.

Congenital hydrocephalus internus is characterized by a gradual accumulation of cerebrospinal fluid in the lateral and third ventricles of the brain, probably the result of excessive secretion from the choroid plexus (Fig. 353). As a general rule, the fourth ventricle is not involved. The aqueduct of Sylvius, however, is often dilated. Sometimes the fifth ventricle is distended, or the septum has atrophied and disappeared, allowing free communication between the two lateral ventricles. Less frequently, the infundibulum is distended and forms a small sac at the base of

the brain. Usually the disease is manifest at the time of birth, and the head may even at this period have attained the circumference of more than 50 cm. Externally, the head is spherical and large; the face is small, and, with the bulging forehead, gives to these patients a characteristic expression. The cranial bones are usually more or less separated; frequently the edges of the sutures are an inch or more apart. The anterior fontanelle is large and usually bulging. If the bones of such a skull be examined, it will usually be found that they are very thin, and that ossification is incomplete. The dura mater is tense, and beneath it may be found the greatly flattened convolutions. The brain-substance seems softer; often there is distinct fluctuation, although the brain collapses as soon as it is removed from the cranial cavity. The distance from the wall of the ventricle to the surface is much less than normal, this atrophy seeming to affect the white substance more than in the cortex. The total weight of the brain, however, is often normal or nearly so, and it is impossible to say that an actual atrophy has really taken place. The substance of the brain is pale, probably as a result of the pressure, and often softened, particularly in the neighborhood of the ventricles, although this is probably only an unusually rapid post-mortem change. The floor of the ventricles may be smooth or slightly roughened, and occasionally distinct nodules may be observed. In the latter case there is usually considerable proliferation of the neuroglia in the cortex, and just beneath the floor of the ventricle a sort of sclerosis of the brain-substance. The cerebrospinal fluid is usually clear, and not abnormal in consistency. Occasionally, however, it is somewhat turbid, particularly if there are any signs of old inflammatory action. The choroid plexus is often somewhat enlarged, pale, and may contain cysts. As the patients increase in age there is usually considerable increase in size of the head; nevertheless, the convolutions gradually become more rounded, and the white substance appears to undergo a sort of redevelopment, for the layer of brain-tissue between the ventricle and the surface becomes thicker. Systemic degenerations of the white fibers are uncommon. There may,

FIG. 353.—Congenital internal hydrocephalus, with marked atrophy of the white substance (from Bollinger).

however, be marked thinning of the corpus callosum and the anterior commissure. Cases have been described in which a descending degeneration along the pyramidal columns was found in the cord.

Partial hydrocephalus has been described. It is probably, in the great majority of cases, of congenital origin. It may affect only one ventricle, or even only a part of a ventricle, as, for example, the anterior or posterior horn of one of the lateral ventricles. It appears to be the result of an obliteration of one of the normal passages by which the ventricles communicate with one another.

External hydrocephalus is the accumulation of fluid that occurs in the subarachnoid space to replace brain-tissue that has undergone atrophy, or to fill the cavity of porencephaly. Occasionally symmetrical collections of liquid are found, as in a brain reported by Sailer that was removed from an idiot, in which both temporosphenoidal lobes were excavated and replaced by large cysts.

Acquired hydrocephalus may be either acute or chronic. The acute forms are usually secondary to inflammatory changes in the meninges, extending to the choroid plexus and to the ependyma, or are caused by some abnormal growth pressing upon the veins of Galen. In the atrophic brains of the aged dilated ventricles are frequently found.

Acute acquired internal hydrocephalus is usually the result of acute basilar meningitis, either inflammatory or tuberculous. The brain, in addition to the meningitic changes, presents all the characteristics of intense intracranial pressure. The convolutions are flattened and pale. The brain-tissue is usually soft, or at least softens rapidly after death, particularly the part that surrounds the distended ventricles. Upon opening the brain the fluid is usually found under considerable pressure, and often almost gelatinous in consistency. Frequently, microscopic examination of the brain-substance will show the presence of acute, disseminated, suppurative encephalitis. The ependyma of the ventricles is injected and often covered with lymph. In the tubercular form it may be roughened, as a result of the presence of numerous miliary tubercles. The choroid plexus is injected. In the acute forms it also has some lymph upon the surface, and in the tubercular form may contain miliary tubercles.

Chronic hydrocephalus is usually a late result of meningitis, particularly the epidemic form. Occasionally it is the result of gradual compression of the veins of Galen, as, for example, by a tumor of the cerebellum. Perhaps most frequently it is the result of a chronic granular ependymitis. In these cases the distention is more pronounced than in the acute form. The ependyma is thickened and opaque, and often contains small hard nodules. Occasionally bands of organized fibers may be found in the cavity of the ventricle.

Ependymitis may be chronic or acute. The acute form is always secondary to meningitis, and is characterized by proliferation of the ependymal cells and the usual inflammatory changes.

FIG. 354.—Sclerotic nodule in the floor of the lateral ventricle, with wrinkling of the ependyma; × 100 (Sailer).

Chronic ependymitis is usually associated with sclerosis of the brain. The surface is granular or even nodular. The ependyma

FIG. 355.—Sclerosis of the brain; × 300.

is thrown into folds, and there is great proliferation of the subependymal neurogliar fibers (Figs. 354, 355).

THE PITUITARY BODY, OR HYPOPHYSIS CEREBRI.

The hypophysis is a small glandular organ, situated at the base of the brain, lying upon the upper surface of the body of the

sphenoid bone, and further protected posteriorly by a wall, forming a cavity which is known as the *sella turcica*. It varies slightly in size, the average weight in the adult being from 0.59 gm. (Schönemann) to 0.48 gm. (Comte). It reaches its maximum between twenty-one and forty years of age.

The hypophysis is a double organ, developed from the central nervous system and from the alimentary canal. The nervous part originates from the middle primary cerebral vesicle as an evagination from the cavity. This forms the infundibulum and the small posterior lobe. The larger anterior lobe appears to arise from two sources, one, the primitive oral tissue in early embryonal life, and the other the anterior portion of the alimentary canal; both portions become contracted at their origins, fuse, and are ultimately separated from the alimentary canal, although this separation is not complete in some of the lower vertebrata. Histologically, the organ may be divided into three parts: the anterior portion of the anterior lobe is composed of somewhat polygonal epithelium-cells enclosed in alveoli, whose walls are made up of fibrous connective tissue. These groups of cells are very irregular, although sometimes they are arranged about the periphery of the cavity, leaving in the center a small lumen, which, more frequently than not, is filled with an oxyphilic homogeneous mass that is supposed to be colloid. The amount of connective tissue is usually relatively small, and it contains a considerable proportion of cells as compared with connective tissues of other parts of the body, and is exceedingly vascular. The cells are of two kinds, the chromophilic and the chromophobic. The former are further divided by Comte into the eosinophilic, in which the protoplasm stains deeply and homogeneously with eosin, and usually contains vacuoles; and the cyanophilic cells, in which the protoplasm colors dark blue with hematoxylin, and rarely contains vacuoles. The protoplasm of the chromophobic cells does not stain. Some authors consider that these distinctions are not morphologic, but only indicate that the different cells are in different stages of secretory activity. The posterior part of the anterior lobe usually contains, in man, a small bilobed cavity lined with cylindrical ciliated epithelium. In addition, there are also a few larger cavities lined by columnar or polygonal epithelium, and usually filled with colloid material. The posterior or nervous lobe consists of neuroglia-tissue, and, according to Berkeley, a few ganglion-cells containing an excess of pigment, and some varicose fibers may be found in it. Kölliker, however, denies that there is any nervous tissue at all in the posterior lobe, and has been able to find nothing but neuroglia.

From its analogy in structure to the thyroid gland, it has been supposed that the function of the pituitary body is to abstract some material from the blood, to alter it, and then to return it to the circulation—that is to say, it is one of the internal secretory glands. Pronounced changes following its removal or destruction cannot, however, be said to have been definitely established. If we can believe the assertions of those who have systematically examined large numbers of these bodies, a normal gland is the exception; thus, Schönemann found only 27 normal specimens in 110 cases, and Comte 33 in 108.

Hypertrophy of the hypophysis occurs in cretinism, myxedema, and acromegaly. In some of these cases the hypertrophy is due to tumor-formation; in others, particularly in those occur-

ring as a result of removal of the thyroid gland, it appears to be compensatory, or rather, as the functions of this gland and the thyroid cannot be exactly identical, at least vicarious. This enlargement, often apart from tumor-formation, may be very considerable. De Conlon records a case in which the hypophysis weighed 1.55 gm., and, aside from an apparent proliferation of the epithelium-cells, was normal in structure.

Circulatory Disturbances.—The gland, as has been mentioned, is excessively vascular. It is possible that in some cases this vascularity may increase and give rise to a true *hyperemia*, although it is difficult to be certain of this. Changes such as are found in the thyroid gland in exophthalmic goiter have certainly not been described. In case of *passive congestion* resulting from thrombosis of the cavernous sinuses intense edema may be present. *Hemorrhage* in the gland is a frequent agonal phenomenon. In these cases the blood-cells, usually normal in appearance, are found infiltrating the connective-tissue stroma. Hemorrhages during life may occasionally occur, and give rise to small, deeply pigmented areas of softening, which ultimately form scars.

Inflammation is usually secondary and suppurative. Sailer has observed a case in which the anterior lobe was infected from the parotid gland, probably as a result of ascending infection along the retropharyngeal lymphatics. In this case the capsule enclosing the gland was inflamed, and there were small collections of round cells in the substance.

Degenerations.—Infiltrations with either calcareous material or pigment have not been hitherto described. The degenerations, however, are numerous. The most important and frequent is *colloid degeneration*, the colloid material being found in the cavities of the epithelial nests, or even as small masses in the connective-tissue septa. This may be looked upon as almost physiologic. It seems to be increased in those conditions in which we have reason to suspect increased functional activity of the glands; but also is more pronounced in cases of partial atrophy. *Amyloid degeneration* occurring in the blood-vessels has been observed in cases of general amyloid disease. The walls of the blood-vessels frequently undergo hyaline degeneration in old age.

A sort of cheesy or liquefactive necrosis is also observed in the center of adenomatous formations, and is probably due to pressure-necrosis, as a result of the limited space in which the hypophysis is placed.

Infectious Diseases.—Of the infectious inflammations, the only ones of importance are *tuberculosis*, in the form of miliary tubercles, and *syphilis*, in the form of gummatous nodules. Occasionally a large single gumma has been observed.

Tumors are perhaps the most interesting and important

changes that occur, and there is still considerable difference of opinion regarding their nature.

Cysts are very common, particularly a form of cystic degeneration with distention of the follicles by colloid substance. These are almost normal in old age, the only interesting feature being the atrophy and disappearance of the epithelial cells. *Teratoid cysts* have been described, but are much less frequent than would be expected from the complicated embryology of the gland. Of this nature is the *myoneuroma* described by White.

Of the malignant tumors, the only one hitherto described is the *sarcoma*. This is usually round-cell or spindle-cell in type, and apparently springs from the capsule of the gland and replaces its substance, but rarely infiltrates the surrounding tissues or gives rise to metastasis. Cases have been reported as *lymphosarcoma* in which there were numerous collections of round cells in the alveoli of the connective tissue and some hypertrophy of the latter; apparently, however, no other lymphatic organs were involved.

Adenoma of the hypophysis causes increase in the size; the organ remains soft or may be slightly indurated, and is of normal color. The resistance of the bony structures that surround it may cause the gland to assume extraordinary shapes. Microscopically there is proliferation of the epithelium-cells, which form long tortuous and sometimes branched tubes, and often complete atrophy of the nervous lobe. These tumors have been described particularly in connection with the disease known as acromegaly.

Pathologic Physiology.—The relation of disease of the hypophysis to acromegaly is a much disputed question. In all cases that have hitherto come to autopsy the hypophysis has been found diseased and, in all but one, enlarged. In view of the analogy of structure between the hypophysis and the thyroid gland, and the certain etiologic relation of disease of the latter to myxedema and cretinism, it was at first assumed, almost without question, that acromegaly was caused by disease of the pituitary body. Many cases have been reported in which there was disease of this gland without any symptoms of acromegaly, and a certain degree of general splanchnomegaly has been observed in acromegaly. It is, of course, possible that the enlargement of the pituitary is simply a part of the latter condition. The thyroid gland, however, does not partake of this change, nor do, apparently, any of the other secretory organs, the various enlargements being usually the result of a hyperplasia of the lymphoid tissue. Neither are the changes of other organs as constant as those of the hypophysis. There is certainly no characteristic lesion in the latter organ, for nearly all forms of disease have been described—adenoma, sarcoma, cystic degeneration, and sclerotic change. In the absence of definite knowledge of the results of experimental lesions, the question must remain at present undecided.

THE PINEAL GLAND, OR EPIPHYSIS CEREBRI.

The pineal gland, or epiphysis cerebri, is an outgrowth from the roof of the posterior portion of the anterior vesicle of the brain. Its base is soon constricted, and it is finally completely separated from the primary cerebral vesicle and enclosed in a sheath of connective tissue which is surrounded by pia mater. Histologically, it is found to consist of septa of connective tissue, dividing it into numerous alveoli, in which are found epithelial cells, some of which are branched. It is very vascular, and contains a plexus of sympathetic nerve-fibers. The gland is in all probability wholly without function.

At all ages it contains small calcareous concretions (*acervulus, brain-sand*), which must therefore be looked upon as physiologic. It is sometimes enlarged in acromegaly and cretinism, or as a result of a hyperplasia of the epithelial structures, giving rise to *adenomatous* or *strumous formations*. As a result of its position it may in these conditions occlude the veins of Galen and produce hydrocephalus. Pathologically, aside from the calcareous infiltration already mentioned, *hyaline degeneration* of the blood-vessels may occur. There are usually signs of *inflammation*, more or less marked, in cases of meningitis, which may even lead to pus-formation. Of the tumors, the most important are probably *sarcomata* springing from the connective-tissue septa. *Adenomata* may also occur. *Cystic conditions*, associated with the presence of hair, cartilage, and other tissues, have been described.

CHAPTER XIII.

DISEASES OF THE SPINAL CORD AND ITS MEMBRANES.

THE DURA MATER.

Diseases External to the Dura Mater.—Among the minor processes that may occur externally to the spinal dura mater is **fatty infiltration**, sometimes associated with general obesity, but occasionally found in patients that are moderately emaciated.

Hemorrhage may occur on the external surface of the dura, the blood being found distributed in the extradural areolar tissue. The usual cause is traumatism, but it may also occur in convulsive conditions. Ordinarily the blood remains circumscribed and forms a spinal hematoma; rarely, a cyst results.

Diseases of the Dura Itself.—Most of the pathologic processes are secondary to some disease of the vertebral column. The most important is tuberculosis; this gives rise to **external tubercu-**

lous pachymeningitis, characterized by a collection of cheesy material which may have undergone either softening or necrosis, or else contains pus-cells. The dura in the affected region is usually considerably thickened, and may have upon its inner surface a slight amount of exudate. The character of the lesions is not different from that of tuberculosis in other serous membranes (Fig. 356).

Pachymeningitis cervicalis is a localized tuberculosis of the dura mater occurring in the cervical region, and characterized by con-

FIG. 356.—Tuberculous pachymeningitis secondary to spinal caries.

siderable thickening, sometimes amounting to ½ cm. or more. The dura is usually adherent to the spinal canal and to the arachnoid and pia, the latter showing more or less involvement. The serious changes consist of compression of the roots and of the spinal cord, the latter especially in the anteroposterior direction. The process may extend into the substance of the cord and produce a myelitis of the periphery, and occasionally extends deeper and causes more or less extensive secondary degenerations.

Of the acute inflammations the most important is **internal hemorrhagic pachymeningitis,** a process similar to that occurring in the dura mater of the brain. It consists of a layer of granulation-tissue in which many of the capillaries have ruptured, giving it a uniform reddish appearance; it is somewhat irregular in outline and of varied extent, and not infrequently adhesions form between the dura and the arachnoid.

Syphilis occurs either in the form of discrete gummata or as a regular and diffuse thickening of the inner membrane.

Tumors from the spinal canal frequently invade the dura. The most common of these is *sarcoma*. This occasions considerable thickening of the dura, and it is often difficult to separate the dura from the sarcomatous bone. In consequence of these conditions there may be pressure and atrophy of the spinal cord.

Tumors of the dura itself may be either benign or malignant. Of the former, *lipomata*, which also occur in the brain, are the most frequent. *Myxomata* and *fibromata* are exceedingly rare. *Sarcoma* may be of the round-cell, angiomatous or alveolar type. It is usually irregular in outline, spreading like a fungous mass over the surface of the membrane, which exhibits fibrous thickening. If small and occurring on the anterior aspect, it may pro-

duce no symptoms whatever. In this situation it is frequently secondary.

Upon the inner surface a variety of tumors have been observed. Horsley mentions myxomata, fibromata, carcinomata, and sarcomata. In rare cases echinococcus-cysts have been observed, and even the cysticercus.

THE PIA AND ARACHNOID.

CIRCULATORY DISTURBANCES.

Active hyperemia precedes inflammatory changes, and of itself is of little significance. It is rarely seen post-mortem, and in the majority of cases its existence can only be inferred.

Passive hyperemia is very common—that is to say, in many cases the veins of the pia mater are found to be tortuous and greatly distended with blood. This is usually due to post-mortem hypostasis.

DEGENERATIONS.

Calcareous infiltration sometimes occurs, appearing as small, hard plates, rarely more than 0.5 cm. in diameter, scattered along the whole length of the spinal cord. It is probably always secondary to inflammatory processes, as spinal syphilis and tuberculosis.

Pigmentary infiltration may occur, but is rare.

INFLAMMATIONS.

Acute inflammation, or **acute leptomeningitis,** is often secondary to cerebral meningitis. It may occur, however, independently as a result of local suppurative processes, particularly those of the spinal column. It may be serous or purulent in character, and in the latter an exudate is found upon the inner surface of the dura and in the subarachnoid space, often extending the entire length of the spinal cord. The microscopic changes are essentially similar to those found in the membranes of the brain. Involvement of the cord is, however, much more common. There is usually extensive round-cell infiltration in the anterior commissure and small foci of round cells scattered throughout the gray and the white matter, especially in the latter. Frequently these can be seen to surround a blood-vessel, but this is not always the case, and it is not unlikely that purulent material can enter from the lymphatics of the pia. If death does not occur, adhesions may form between the dura and arachnoid, but these are certainly exceedingly uncommon in the cord.

Chronic leptomeningitis is usually associated with scle-

rosis of the spinal cord; thus, in locomotor ataxia the pia mater over the posterior column may be opaque and slightly thickened. It may also be consecutive to some of the other inflammatory processes, and in this form adhesions may be found between the dura and arachnoid (*pachymeningitis* and *arachnitis adhesiva*).

INFECTIOUS DISEASES.

Tuberculosis may occur in the form of miliary nodules or as small cheesy masses, usually extending a slight distance from the pia mater into the substance of the cord. It is disputed whether an acute leptomeningitis without miliary or cheesy nodules may be caused by this organism alone, but this has not as yet been decisively established. Solitary tubercles may occur in any part of the spinal cord. They are rarely encapsulated. They usually consist of an aggregation of round cells with vesicular nuclei, and are often softened in the center.

Syphilis appears as a thickening of the membranes with multiple gummata, often projecting into the substance of the cord or extending to and involving the dura mater. The vascular changes are very characteristic; nearly all the blood-vessels exhibit the typical round-cell infiltration and thickening of the intima which have been described in the section on endarteritis syphilitica. There are also a perivascular round-cell infiltration and some proliferation of the adventitia. The veins may also be involved. The lumen of both sets of vessels is usually contracted, and there is a great tendency to the formation of thrombi. In these thrombi organization may take place, with the formation of new blood-vessels. The spinal cord may also exhibit various lesions, due either to pressure or to direct extension inward from the pia.

In congenital syphilis the upper part of the spinal cord appears to be more considerably involved than the lower part.

ANATOMY OF THE CORD.

The spinal cord is composed, as are the other parts of the central nervous system, of gray and white matter; the gray matter occupying the central part, and the white matter being distributed around it. It is of varying size, somewhat broader and flatter in the cervical region than elsewhere; almost circular in the dorsal region, and again thicker in the lumbar region. It communicates with the rest of the body by means of the spinal nerves, which arise anteriorly and posteriorly as roots; eight from the cervical, twelve from the dorsal, five from the lumbar, and five from the sacral region. It is surrounded by three membranes: the pia, adherent to it; the arachnoid, adherent to the pia, but not dipping into the anterior fissure, and the dura mater, which is adherent neither to the arachnoid nor to the vertebral column. The gray matter is divided into two parts by the anterior commissure and posterior septum, each part consisting of an anterior horn, a thick, roundish mass, and a posterior horn, a slenderer projection. The lateral halves are united by the gray commissure, in which is the central canal lined with cuboidal epithelium and continuous with the fourth ventricle

above. In the anterior cornua are found the large multipolar ganglion-cells, whose axis-cylinders pass out through the anterior roots and end in the muscles; commencing in the dorsal region, there is a group of cells in the inner portion of the posterior horn, near the gray commissure, which are bipolar and whose axis-cylinders pass outward to the cerebellar tract, in which they ascend to the vermiform process of the cerebellum. The posterior roots are composed of fibers that originate in the spinal ganglia and pass into the cord. These spinal ganglion-cells have a single process, which careful embryologic investigation has shown to be formed by the fusion of two polar processes, that have been brought in contact by the shrinking of one side of the cell. This process appears to divide into two fibers, one passing outward into the peripheral nerves and usually terminating in the sensory corpuscles of the skin, the other passing inward through the posterior root to the spinal cord. Lenhossek believes that the peripheral fiber represents the protoplasmic process of the cell which normally conveys impulses cellipetally. The white substance of the spinal cord is composed of bundles of nerve-fibers that have, for the most part, a common function, a common mode of origin and of termination.

Anatomically the cord may be divided into three regions: anterior, lateral, and posterior, although these do not correspond to regions embryologically distinct. According to the manner of development, it should be separated into the anterolateral and the posterior regions.

The most important bundles of fibers in the anterolateral columns are those known as the *pyramidal tracts*, for the reason that they are continuations of the pyramids of the medulla. They originate in the motor region of the cerebral cortex and, in the first cervical segment, decussate through the representatives of the anterior cornua to reach their situation in the lateral columns. This decussation does not occur in all of the fibers, many passing down in the direct pyramidal columns and some without decussation in the lateral columns. These undecussated fibers subsequently cross to the other side through the anterior or white commissure. The fibers of the pyramidal columns terminate in arborizations which surround, but are not in contact with, the ganglion-cells of the anterior cornua.

The cerebellar tract has already been described. Anterior to it and close to the periphery of the cord is the so-called *anterolateral column of Gowers*. The fibers which form this probably originate in the lateral groups or cells in the anterior cornua and in the cells in the middle portion of the spinal cord. The column increases in size upward and degenerates in the same direction. Its termination is unknown. It also contains fibers that degenerate downward, of whose origin and termination we are ignorant.

The rest of the anterolateral column is composed of short fibers, uniting different segments of the spinal cord.

The posterior columns are composed of the fibers that enter by the posterior roots. These fibers divide into two branches, one ascending and the other descending, the latter terminating in the gray matter of the posterior horn. The ascending fibers may be divided into two groups, the lateral and median bundles. The fibers of the lateral bundle are somewhat finer, and evidently belong embryologically to a different period, because they acquire their myelin-sheaths later. They pass directly into the zone of Lissauer, and thence into the substantia gelatinosa of Rolando, and some of them terminate in arborizations about the ganglion-cells in the column of Clarke. The fibers of the median bundle are coarser. They pass inward, then upward along the inner side of the posterior horns, and then become the *column of Burdach*. The median fibers from the lower part of the cord bend inward and continue their course in the column of Goll, terminating finally in the nucleus gracilis of the medulla oblongata. The fibers that enter the cord in the cervical region pass upward in Burdach's column and terminate in the nucleus cuneatus. Other fibers pass forward to the gan-

glion-cells of the anterior cornua, and have been supposed to be concerned in reflex action. Others decussate in the posterior commissure and then pass upward in the posterior columns of the opposite side. At somewhat regular intervals they give off at right angles fine collateral branches, which pass forward, and some of them, at any rate, end in arborizations about the cells of the anterior cornua of the gray matter. These are known as the reflex collaterals of Kölliker. A small portion of the posterior column just back of the gray commissure appears to be composed of fibers uniting the different segments.

[It is sometimes convenient to identify the nerve-roots in the spinal cord for the sake of locating lesions or tracing the alteration in systemic degenerations. The most satisfactory method of doing this is to cut through the dura along the anterior and posterior surfaces of the cord. The cord is then stretched out at full length and the dura pulled downward as far as the roots allow it to go. The root that pierces the dura opposite the conus terminalis is the second lumbar. The lower cervical roots are all of large size. The first dorsal is sometimes smaller, but the difference between it and the second dorsal is still more considerable, and this serves as a check upon the previous estimation. Familiarity with the appearance of the cord at the different levels also enables one to locate sections with considerable accuracy.]

CONGENITAL ABNORMALITIES.

Total absence of the cord, or **amyelia,** can only exist in association with anencephalus. It is interesting to note that the spinal ganglia are usually still present. Partial absence of the upper portion occurs in cases of anencephaly.

Abnormal smallness is known as **micromyelia.** The cord may be normal in structure, all the elements being proportionately reduced, but more commonly only certain parts are affected, particularly the pyramidal columns, as a result of fetal lesions in the motor tract.

Double cord, or **diastematomyelia,** is usually localized to one portion of the cord, particularly the lumbar region. Occasionally the cord is completely divided by a bony septum. In this case the gray matter in either half presents the normal arrangement of the gray matter in the cord.

Unusual length of the cord may also occur, the conus terminalis being in these cases elongated and extending to the end of the sacrum.

The spinal roots may be excessive or defective in number on one or both sides. This usually occurs in the dorsal region, the commonest condition being the presence of eleven roots on one side.

The cord may be asymmetrical. This usually involves only the pyramidal columns, and is due to incomplete decussation.

Heterotopia of the gray matter is not infrequent. This may consist of doubling of one of the horns; disorganization of one or both horns, or fissures extending into the substance. According to van Giessen, the majority, if not all, of these cases are the result of injury during removal, and are therefore to be regarded as artefacts. This statement is, however, too sweeping. Abnor-

mal bundles, producing heterotopiæ and due to alterations in the medulla or even higher in the central nervous system, have been found. These appearances may also be produced by tumors or other conditions causing pressure.

Dilatation of the Central Canal.—The central canal may be dilated, either locally or throughout its whole length. This condition is known as *hydromyelia*, or *hydrorrhachus*, and is akin to hydrocephalus, with which it is sometimes associated. Hemorrhage may take place into these dilated canals and gives rise to *hematomyelia* (*vide infra*).

Localized collections of liquid in the subarachnoid spaces are sometimes spoken of as *hydrorrhachus externa*.

Spina Bifida.—There may be imperfect closure of the posterior processes of the vertebræ, giving rise to clefts, which are known as *rachischisis*. If the membranes of the spinal cord protrude through the cleft in an imperfectly closed canal in the form of a sac or hernia, the condition is called spina bifida. In some cases the skin is still present, and is often covered by an abnormally thick growth of hair. In other cases the pia is the only membrane that enters into the formation of the wall. It is usually thickened, and may be covered with granulations. Sometimes the dilatation evidently takes place in the central canal, for the substance of the spinal cord may be recognized adhering to the inner layer of the pia mater. This condition is called *myelomeningocele*. Spinæ bifidæ usually appear in the sacral or lower lumbar region, and are probably due to imperfect closure of the vertebral arches.

HYDROMYELIA AND SYRINGOMYELIA.

Hydromyelia is a condition in which the central canal of the spinal cord is dilated. It frequently occurs in circumscribed portions and is apparently without clinical significance. More rarely the whole canal has a microscopic lumen throughout its entire length, particularly in cases of hydrocephalus, although in the majority of cases of this latter disease the spinal cord is not involved. A patulous canal can be distinguished from a pathologic cavity by the fact that the cavity is lined by the normal cuboidal epithelium of the ependyma. Usually there is a considerable collection of ependymal cells in the neighborhood of the central canal, and this is more apt to be the case if it is dilated or otherwise altered than if it is normal. Occasionally the central canal is doubled. This rarely happens throughout the whole length of the cord, but is more frequently found in a limited portion, especially the lumbar region. This doubling is due in some instances to the obliteration of the central part of a dilated canal with its long axis transversely placed. Sometimes a slit-like canal shows a dilatation in only one part. Sometimes the

lumen of the canal is completely obliterated, leaving nothing but a mass of cells in the gray commissure, in the midst of which capillaries may be observed. More distinct pathologic changes are the diverticula that occasionally spring from the canal. These seem to be most frequent in the cervical and dorsal regions. They usually extend downward, and are situated posteriorly to the gray commissure. It is possible that collections of epithelial cells from the ependyma under similar circumstances may form masses in the posterior column without distinct cavity-formation, although this is doubtful. These changes are particularly significant on account of their relation to the disease known as syringomyelia (Fig. 357).

FIG. 357.—Hydromyelia (partly diagrammatic).

Syringomyelia.—Pathologically this is essentially a cavity in the spinal cord that is not lined throughout with the columnar epithelium of the ependyma. This cavity may appear as a wide dilatation or as a narrow slit. It usually occupies the posterior part of the cord, is exceedingly asymmetrical, sometimes limited entirely to one side, and in these cases is ordinarily found in the posterior horn or on its inner side. The cord may be unaltered externally. The dura mater is commonly normal. The pia and arachnoid are either normal or else thickened slightly, the change being not unlike that found in senility or in cases of chronic edema of the membranes. The shape of the cord may be entirely normal. This, however, is rare. Usually there is some asymmetry, and frequently, particularly if the cavity is large, the cord upon being removed and laid upon a flat surface seems to collapse, giving rise to the so-called ribbon-appearance. Section through the cord shows the existence of a larger or smaller cavity filled with the products of liquefaction-necrosis, cerebrospinal fluid, or else more rarely with blood. Sometimes it appears to have been empty, in which case the cord probably was collapsed

in the spinal canal, and the space thus formed was filled with cerebrospinal fluid. The solid portion of the cord is usually somewhat darker in color, and the distortion of the outline corresponds to the extent of the process. The portions of spinal cord not involved by the lesion, and below it, commonly show more or less descending degeneration. In the portion above the cavity, if it does not extend as far as the medulla, some degeneration in the posterior columns is often found. In many cases, however, both the ascending and descending tracts are intact; at least they appear so to the naked eye. Microscopic examination shows that the cavity is bounded, as a rule, by a delicate reticulum of neuroglia. Sometimes this is lined with what appears to be connective tissue, and is supposed to be an inclusion of the pia mater. At other times it is lined with ependymal epithelium; occasionally, as has been previously mentioned, it may contain blood. The tissue in the neighborhood is usually hyperplastic neuroglia. The fibers are coarse; the cells are sometimes swollen, sometimes shrunken, and show various signs of commencing degeneration. They may be numerous or few. The cord in the immediate neighborhood may show curiously few changes, the ganglion-cells being perfectly normal and the fibers uninjured. If the cavity is extensive and the proliferation of the neuroglia considerable, this is not usually the case. An entire posterior root may be destroyed, or perhaps half or more of the spinal cord, and the nerve-fibers in the neighboring columns will be extensively degenerated; in these cases secondary degeneration always occurs. Not only the pyramidal tracts, but also bundles in the posterior columns degenerate downward. In a case that I have studied the coma-tract of Schultze was beautifully outlined. The nerve-roots are also usually involved, and there is descending degeneration along the anterior roots, which may be detected also in the nerves. The posterior roots may show some degeneration, but this is rare and the cells of the spinal ganglia are usually intact. Sometimes there is considerable vascular proliferation in these portions of the cords not unlike cavernous change. Atypical forms frequently occur. There may be extensive gliosis, with small or no cavity-formation; or the cavity may be extensive and the proliferation of the neuroglia slight. Occasionally the cavity may communicate with the dilated central canal, a condition that has given rise to the supposition that it is originally due to some congenital malformation.

As the great majority of all the cases of syringomyelia are associated with hyperplasia of the neurogliar tissue of the spinal cord, it is necessary, in order to understand the various theories that have been suggested to explain its origin, to briefly consider the more recent investigations in regard to this tissue. It is now established that it is ectodermal in origin, and due to a proliferation of the ependymal cells lining the central canal of the spinal cord and the ventricles of the brain. In the cord these cells elongate radially, and the nuclei show active karyokinesis, continuing

to proliferate until the neuroglia-cells are found in all parts of the spinal cord. The cells lining the central canal and, in the human cord, groups of cells in its immediate neighborhood, remain cuboidal in shape, and are spoken of as ependymal cells. Those cells forming the connective tissue of the nervous system are called *astrocytes*. It was formerly supposed that the fibrous portion of the neuroglia was due to the interlacing of the numerous radiating protoplasmic processes of the latter; although Ranvier and Chaslin had both suspected that the fibers were independent of the cells. Since the introduction of the Weigert and Mallory staining-methods, it appears certain that, in the human cord at least, the neuroglia-fibers form a network independent of the neuroglia-cells. In regard to the origin of these cells, it is not certain that they all develop directly from the ependyma; indeed, it is very likely that the astrocytes may themselves redivide, for observations have been made and reported in which they were seen to possess karyokinetic figures. Moreover, the repeated proliferation of the neuroglia in cases of injury to the central nervous system in situations far removed from the primitive ependyma would be an argument in favor of this view. Pathologically, various interesting theories have been suggested to account for this apparently idiopathic proliferation of the neuroglia. Lenhossek believes that besides the fully formed astrocytes other neuroglia-cells remain throughout life in a sort of latent condition and represent superfluous elements formed during embryonal existence. These, he believes, may, under certain circumstances, commence to proliferate and give rise to gliosis. A certain amount of neurogliar proliferation appears to be normal in the neighborhood of the central canal of the human spinal cord, and has already been described in the discussion of hydromyelia; in some cords it may reach a very extreme degree, often causing obliteration of the central canal, whose place is then taken by an irregular group of cells, in the midst of which blood-vessels may be found. Of the various theories that have been suggested, the most important is that of lymphatic or venous congestion, based upon the general dilatation of the perivascular spaces in all instances of gliosis. Cases, however, do occur in which this dilatation of the lymph-spaces does not exist. A more widely supported theory is that of congenital dislocation of some of the ependymal cells of the central canal, either in the form of diverticula, or as solid plugs, or as wholly separated cavities. In many of the cases of syringomyelia such ependymal cells are found lining the abnormal cavity, and in some cases, as has been stated, the syringomyelic cavity communicates with that of the central canal. According to this, syringomyelia is only a pronounced modification of hydromyelia. This theory is particularly supported by Hoffmann, who draws a distinction in the hyperplasia between gliosis and gliomatosis; the former representing proliferation of the ependymal cells, and the latter being a neoplastic formation, giving rise to elongated tumors with increase in the size of the spinal cord.

Schlesinger also believes that the hyperplasia commences in the ependymal cells, and that congenital anomalies play a large part in their etiology. Saxer suggests that the neuroglia-cells may have retained some of their embryologic properties and be capable of proliferating. Weigert, who disbelieves emphatically in the theory of softening of the gliosis, suggests that the gliosis, if it exists at all, is possibly secondary. Among the other theories are those of softening after traumatism or the result of angiomatous degeneration of the blood-vessels. Gerlach has reported a case in which the cavity appeared to be lined with pia mater. It is certain that in the great majority of cases there is true proliferation of the neuroglia-tissues, the cells being increased in number, and the fibers coarser and forming a wide-meshed network around the canal. A true gliomatous formation may also occur, and it is not unlikely that syringomyelia is rather a syndrome than a pathologic, or at least an etiologic, entity.

CIRCULATORY DISTURBANCES.

Diseases of the walls of the blood-vessels are similar to those occurring in the blood-vessels of the other parts of the body. Extensive atheromatous changes are relatively rare. Perhaps the most frequent disease is *hyaline degeneration.* Hyaline degeneration is exceedingly common in cases of sclerosis, and may occur in early life, even in childhood. It is almost invariably present in the cords of persons dying after middle life. Round-cell infiltration of the intima (*endarteritis*) occurs in syphilis, and also, though less frequently, in tuberculosis. Fibrous thickening of the intima and proliferation of the connective tissue of the adventitia are common senile changes.

Attention has been recently directed more particularly to these changes on account of the suggestion by Redlich that they are the anatomic basis of paralysis agitans. According to him, the characteristic changes are endarteritis and periarteritis, with extension of the latter process into the surrounding nerve-substance and the formation of perivascular insular scleroses. In addition, there is often some degeneration in the posterior columns, and occasionally in the lateral columns in the cervical and lumbar enlargements. The vascular changes, curiously enough, appear to be more severe in the posterior horns than in the other parts of the cord, and amyloid bodies are nearly always present in these regions. However, in examining the cord of a typical case of paralysis agitans Sailer failed to find these lesions; while in another case, equally characteristic clinically, they were quite pronounced. Fürstner has also reported a case of paralysis agitans without spinal lesions. Redlich's views, therefore, are probably incorrect.

Miliary aneurysms are very infrequent in the spinal cord. Aneurysms of the vertebral arteries, however, sometimes involving the commencement of the spinal branches, have been reported, but are rare.

Amyloid degeneration is found in cases of general amyloid disease.

Active hyperemia of the spinal cord is rather a clinical hypothesis than a pathologic entity. Occasionally, however, the gray matter seems to be slightly darker than normal, and there is rather free bleeding from the vessels cut transversely. In many cases of myelitis the arteries and capillaries may be found distended with blood.

Passive hyperemia is more readily detected in the veins of the membranes than in the cord itself.

Anemia is an important and easily recognized condition. Experimentally it has frequently been produced by ligation of the abdominal aorta. Cases have occasionally occurred in human

beings in which the same vessel was occluded by a thrombus, giving rise to similar changes. The cord, under these circumstances, is somewhat swollen, pale, and soft; not invariably, however, for cases have been reported in which microscopically it was entirely normal. The ganglion-cells, particularly those of the anterior cornua, are most distinctly affected. They exhibit usually the characteristic features of chromolytic degeneration. The protoplasmic processes become varicose and shortened, and the nucleus may be situated at the periphery. Similar changes may occur in other portions of the cord, but are exceedingly rare, partly on account of the free anastomosis of the blood-vessels, partly because if, as sometimes happens, thrombi are formed in the vertebral arteries, death occurs before characteristic changes have had time to develop.

Varicose Veins.—Occasionally a group of vessels in one part of the spinal cord will be dilated and varicose, forming a sort of plexiform angioma. A condition of this kind has been described by Edinger. In this case the vascular plexus had evidently developed some time after birth, for there was some degeneration of the surrounding nerve-substance, and the patient had presented distinct clinical symptoms of pressure in the upper part of the cord. Similar angiomatous formations are frequently observed in various forms of myelitis and sclerosis.

Hemorrhages may be of two kinds: *punctate* and *massive*.

Punctate hemorrhages are really nothing but pericapillary exudations of blood-cells, which can readily be distinguished from the drops of blood that form at the cross-section of blood-vessels by the fact that they cannot be washed off. It is probable that, if death does not occur at once, they are in great part absorbed, leaving perhaps a minute scar that may be readily overlooked. These minute hemorrhages are perhaps more common in the cervical region than elsewhere. They are found in the course of infectious diseases, particularly those affecting chiefly the nervous system, such as tetanus, and especially hydrophobia. Small agonal hemorrhages into the substance of the spinal cord, particularly in the region of the central canal, are not uncommon. Occasionally these may be visible to the naked eye; they are, of course, to be distinguished from ante-mortem changes by the regular form of the blood-cells and the absence of blood-pigment. They are only important on account of the possibility of their being mistaken for pathologic changes.

Massive hemorrhages may be infiltrating or circumscribed. In the former the blood is found between the nerve-fibers and in the meshes of the neuroglia. The nerve-substance is usually more or less degenerated, and the lesion corresponds anatomically to the hemorrhagic infarct. Circumscribed hemorrhages are usually

small when compared to those in the brain, a circumstance due, of course, to the restricted area in which they can occur.

The most common cause of this form of hemorrhage is traumatism, and it may sometimes occur as a result of concussion without fracture of the spinal column. Hemorrhages may also occur in persons with diseased arteries as a result of violent effort or emotional disturbance.

The clots are usually irregularly oval in outline, and are often surrounded by hyperplastic neuroglia, in the midst of which are found compound granular cells, and more or less degenerated nervous tissue.

In the later stages the formation of fibrous tissue is apparent; capillaries may also be found bending into the substance of the clot, which eventually is absorbed, leaving a scar that nearly always contains some pigment surrounded by coarse-meshed neuroglia-tissue. Rarely the pigment is absorbed and a cyst remains. Occasionally the hemorrhagic focus is restricted to the gray substance, the blood being found in cylindrical masses. This arrangement is due to the fact that in normal circumstances the gray matter is softer than the white, and offers less resistance to the extravasation of the blood. In this case the infiltrated area soon becomes filled with granular cells, the nerve-fibers degenerate, and crystals of hematoidin appear.

Hematomyelia.—If the central canal is dilated and contains blood, the condition is known as hematomyelia. This may occur as the result of traumatism or as a result of some vascular degeneration. The latter form is occasionally associated with syringomyelia, and is found most frequently in the cervical portion of the cord. If the hemorrhage occurred some time before death, the only traces that persist will be discoloration of the ependyma, and perhaps the adjacent tissue. Hemorrhage may also occur during the death-agony, in which case the central canal may either be filled with normal blood-cells, or, if it is at all dilated, there will be a thin layer of blood-cells upon the surface. The most common situation is at the point where the central canal opens into the fourth ventricle.

INFLAMMATIONS.

Myelitis, in the strict sense, is a term signifying an inflammation of the substance of the spinal cord. According to this view, it should be limited exclusively to forms of spinal disease secondary to hematogenous infection, extension from the pia, or possibly extension from the central canal, although the latter can be dismissed as an unknown variety. The name has been used, however, to signify any form of softening that may occur, whether it be produced by injury or disease of the spinal column, by

tumors, or by poisons circulating in the blood. It has also been applied to secondary changes the result of meningitis and to obscure lesions that either commence with a proliferation of the neuroglia, or as a primary degeneration or atrophy of the nerve-substance and secondary increase in the neuroglia-tissue.

According to the distribution of the lesions, myelitis is spoken of as circumscribed, transverse, or disseminated. Older writers were accustomed to distinguish between those forms which were found only in the white matter, those found only in the gray matter, and the diffuse forms. The first were known as leukomyelitis, the second as poliomyelitis, and the third as diffuse myelitis. Several varieties may be distinguished by the pathologic character of the lesions.

Hematogenous Purulent Myelitis.—As a rule, the membranes of the brain are also infected, and show the characteristic appearances of acute leptomeningitis, with subarachnoid accumulations of pus and injection of the vessels. Cross-section of the cord shows here and there small reddish or yellowish areas distributed irregularly throughout the cord; in longitudinal sections these usually appear as streaks following the course of the blood-vessels. The cord often seems to be softer and may be darker than normal. The microscopic changes consist of accumulations of pus in the pia mater and distention of the vessels, the presence of a perivascular round-cell infiltration, slight degeneration of the nervous tissue in the neighborhood of the lesions, and alteration of the neuroglia, which may show some looseness of its fibers. Unless the process is advanced, with the formation of abscesses of considerable size, or extensive vascular change, the true nervous tissue not in the immediate neighborhood of the foci is but slightly altered. Ordinarily, however, alterations may be seen in the ganglion-cells, which consist chiefly of irregularity in the arrangement of the chromophilic bodies and perhaps somewhat diffuse staining. Should, however, ganglion-cells lie in the midst of, or very close to, the purulent focus, they show a severer type of degeneration, and often have lost their protoplasmic processes. In these cases micro-organisms are not infrequently found. In some rare instances the changes in the substance may be very pronounced, whilst those in the meninges are so slight as entirely to escape macroscopic observation, and to be even readily overlooked with the microscope.

Myelitis secondary to purulent leptomeningitis is not greatly dissimilar from this, excepting that there is generally a more marked degeneration in the periphery of the cord. The neuroglia-cells are increased in this region; there are often minute hemorrhagic foci, and occasionally small peripheral accumulations of pus. These lesions have recently been observed, particularly by Councilmann, in epidemic cerebrospinal meningitis.

Transverse myelitis, without local foci, secondary to injury or infectious disease—that is, the condition generally denominated myelitis—presents three stages, the stage of red softening, of yellow softening, and of gray degeneration. In the first the membranes of the cord are usually somewhat opaque. The substance of the cord itself may be either swollen or shrunken, and is softer than normal in consistency. Upon section of the cord the surface is seen to be pink, and there may be minute hemorrhages; the tissue swells so that the surface of the cross-section is slightly convex. Microscopically the most characteristic feature is the congestion of the blood-vessels; this is more marked in the veins than in the arteries. There is usually a considerable amount of perivascular cellular exudate, the majority of these cells being polynuclear leukocytes. The myelin-sheaths show here and there degeneration; the axis-cylinders are swollen, granular, and somewhat shrunken. The neuroglia-cells are sometimes swollen; sometimes irregular in outline and increased in number. The neuroglia-fibers in the neighborhood of the vessels form a loose, irregular network. The ganglion-cells show pronounced alterations, usually similar to those already described as occurring in intoxication, such as irregularity in staining, peripheral situation of the nucleus, and varicosity or fragmentation of the protoplasmic processes. If the process has lasted any considerable time, the most characteristic feature of myelitis, namely, the accumulations of granular cells, begins to take place. It is not certain what these cells are, but in all probability they represent the wandering connective-tissue corpuscles that have absorbed the granular fatty detritus of the myelin-fibers. Occasionally hyaloid bodies are present, even in considerable numbers. These are more irregular in outline than those seen in more chronic conditions, and, according to Leyden and Goldscheider, are probably due to coagulation of an inflammatory exudate. In the next stage a pressure-anemia begins to be apparent. A cross-section through the freshly removed cord shows that it is still somewhat swollen; the color is yellow. The distinction between the gray and the white matter is preserved, but the gray matter is distinctly shrunken. Microscopically the blood-vessels are shrunken; the perivascular cellular exudate is still present, but many of the cells contain fat-droplets. Throughout the whole cord are found compound granular cells, giving to it a peculiar and characteristic appearance. The nerve-fibers are swollen, granular, or shrunken. The myelin-sheaths are filled with droplets of fat, or have partially disappeared. The neuroglia may be still looser in its texture. The neuroglia-cells are more apt to show degenerative changes. In this stage the alterations in the ganglion-cells are extreme. They may be swollen and irregular; often they form irregular, vacuolar-looking masses; some, however, are shrunken, stain dark, and exhibit no

trace of a nucleus. Others may perhaps be still recognized by the presence of a small vesicle containing the peculiar brownish pigment, and finally it is evident that some have wholly disappeared, because the number is much less than normal. In the severest grades of this condition the substance of the cord has undergone liquefaction and is reduced to a puriform mass, which it is impossible to examine, excepting upon films. It is then found to contain fat-droplets, granular cells, and detritus. In the stage of gray degeneration there is a secondary distention of the blood-vessels, giving it a somewhat redder appearance. There is proliferation of the connective tissue, which has a tendency to retract and cause concavity of the surface of the section. The granular cells are found chiefly in the neighborhood of the blood-vessels. The neuroglia-tissue is looser and appears to inclose numerous vacuoles. The nerve-fibers have in large part disappeared, although a few show degenerative changes, and the ganglion-cells are reduced to a few masses of pigment or else have disappeared entirely. After the cord has been hardened, as also occurs sometimes in various forms of sclerosis, cracks may appear in its substance from the retraction of the connective tissue. By this time secondary degenerations usually begin to appear above and below the lesion, particularly in the sections stained by Marchi's method.

Pressure-myelitis.—The alterations produced in the cord by slowly-developing pressure, such as the growth of a tumor in the membranes, or gradual bending of the spinal canal, as in Pott's disease, produce somewhat characteristic changes. The cord at first becomes anemic, due to the mechanical occlusion of blood-vessels in the affected segment. As the pressure increases and the anemia continues degenerations ensue in the white matter. These are accompanied by the appearance of a moderate number of granular cells and by slight proliferation of the neuroglia. It appears that this degeneration affects first the myelin-sheaths, and that the axis-cylinders may maintain their vitality for a considerable length of time; for regeneration has occurred after the cord has been considerably reduced in size by long-continued pressure. The gray matter appears to persist for a longer time. This does not mean that the ganglion-cells remain absolutely intact, for in the early stages of the process they exhibit various degenerative changes. As we already know, however, such degenerative changes are not necessarily fatal to the vitality of the cell. Later, they begin to shrink, usually becoming at first darker, then losing their protoplasmic processes, and ultimately undergoing change into small irregular vesicles that are frequently pigmented. The neuroglia gradually proliferates, and ultimately the cord is converted into a sclerotic mass at the point of pressure. This mass is gray in color, seems dry, and often in the process of hardening develops numerous irregular fissures. The central canal is vari-

ously affected. It may be, at different levels, obliterated, dilated, doubled, or even tripled. This appearance of doubling or tripling, however, is due to the extrusion of diverticula, which pass upward or downward more or less parallel to the axis of the cord. The epithelium lining the central canal maintains its vitality to a remarkable degree, and, even when all other nervous structures have disappeared, stains distinctly and is of normal shape. Secondary degenerations, of course, occur as soon as the axis-cylinders begin to swell, and are identical with those found in other complete transverse lesions.

Acute Anterior Poliomyelitis.—In this disease, clinically designated infantile palsy, the ganglion-cells of the anterior cornua of the spinal cord, their neuraxons passing out through the anterior roots, and the muscles over which they have trophic influence, are the principal parts involved. The disease is undoubtedly due to hematogenous intoxication or infection. It develops after exposure to cold, subsequent to some other infectious disease, such as scarlet fever or measles, and occasionally has appeared as an epidemic. Children are almost exclusively affected, usually about the period of the second dentition. The nature of the poison that causes it is unknown.

Microscopically the cord presents no characteristic external alterations. If section is made through the diseased portion, it can be seen that the tissues of the cord are somewhat redder than normal, particularly the anterior cornua of the gray matter, and minute hemorrhages may also be observed in this region. The tissue is somewhat softer than normal, and the blood-vessels are considerably distended. In old cases—that is, those with changes consecutive to the cessation of the acute process—the cord may be smaller and somewhat denser. Upon section it is readily observed that one or both of the anterior cornua are considerably reduced in size. The anterior roots from the diseased area may be considerably shrunken and fibrous. Microscopically, in the early stages the most striking appearance is that presented by the blood-vessels. These are greatly distended and surrounded by a wall of round cells. The vessels in the gray matter of the anterior cornua, in the anterior commissure, and in the anterior septum appear to be chiefly involved. The posterior half of the cord presents few, if any, alterations. The neurogliar tissue seems to be somewhat looser, and throughout all the affected tissue there is more or less cellular infiltration, the majority of the cells being mononuclear. The ganglion-cells are much altered. They may be swollen and colorless, the chromatin-granules may be arranged in irregular masses, the processes are irregular, the nucleus may stain diffusely, and the nucleolus show vacuolar degeneration. In the more advanced stages both nucleus and protoplasmic processes have disappeared, leaving nothing but the

thickened axis-cylinder springing from the cell. The perivascular spaces may be somewhat distended, and often contain round cells. Even in cases examined a few days after the onset, it is evident that some of the ganglion-cells have degenerated completely and have disappeared, as their number is markedly diminished. The fibers of the anterior roots show the ordinary forms of degeneration, the presence of globules of fat in the sheaths, and swelling or fragmentation of the axis-cylinders. The affected muscles very early exhibit fatty degeneration and atrophy of the fibers. In cases examined several months after onset considerable atrophy has usually taken place in the anterior horns. The perivascular round-cell infiltration is still very distinct, and usually compound granular cells are found in considerable numbers in the lesions. The ganglion-cells are fewer, and those that remain may be either normal or partially degenerated. Many fibers have disappeared from the anterior roots, and the trophic changes in the muscles are still more pronounced. In those cases examined very late—that is, some years after the development of the process—the anterior horns appear to be markedly diminished in size, although this alteration is exceedingly unequal, often one horn being involved whilst the other is perfectly normal or exhibits only slight alterations. Occasionally the anterior horns appear paler, but of almost normal size, apparently the result of a colloid degeneration of the neuroglia-tissues. The blood-vessels are dilated and their walls thickened, and they may contain some cellular infiltration. In those parts where the process is most severe all the ganglion-cells have disappeared. In others a few may remain, and these are usually normal. The neuroglia has undergone hyperplasia, and consists of a coarse meshwork containing many nuclei. The medullated fibers of the anterior roots are partially or completely destroyed. Degeneration of the medullated fibers of the pyramidal tract may sometimes be traced for a few segments above the affected region; as a rule, it is slight, and involves only a few of the fibers. The lesions usually attack several segments of the cord, and are most frequent in the lumbar region, although any part may be affected, even the cells of the medulla. It has been disputed whether the primary changes occur in the blood-vessels or in the ganglion-cells, but it seems now to be conclusively established that the disease is of hematogenous origin. In favor of this view are the pronounced vascular changes, and the fact that the ganglion-cells in the neighborhood of the vessels are usually more degenerated than those somewhat remote, and that definite groups of ganglion-cells are not affected, but rather those supplied by an individual vascular system.

PRIMARY DEGENERATIONS OF THE CORD.

Primary degeneration of the spinal cord is characterized by the more or less complete destruction of certain systems of fibers, affecting their whole length, without solution of continuity in any part of their course, or distinct degenerative changes in the ganglion-cells from which they arise. In other words, the distinguishing characteristic of this condition is the absence of any lesion that would serve to explain its occurrence. Certain groups of fibers appear to be more frequently affected than others; these are particularly the columns concerned in the conduction of impulses from or to the brain. They may be classified as follows: 1. The sensory neurons of the cord, which are composed of the unipolar cells of the spinal ganglia, and their neuraxons. They pass from the posterior roots into the spinal cord, and enter first the column of Burdach, subsequently bending into the column of Goll, and ending in the nuclei of Goll and Burdach in the medulla. 2. The central motor neurons, commencing in the pyramidal layer of the motor cortex, passing down through the internal capsule, the pyramids, and the pyramidal columns of the cord. 3. The peripheral motor neurons, commencing in the ganglion-cells of the anterior cornua, passing out from the anterior groups, and terminating in the muscles.

The most important primary degeneration is *tabes dorsalis*, or *posterior sclerosis;* it involves almost exclusively the sensory neuron. Involvement of the peripheral motor neuron gives rise to the disease known as *progressive spinal muscular atrophy;* degeneration of both motor neurons, to *amyotrophic lateral sclerosis.*

Posterior Sclerosis.

Degeneration of the posterior columns, when occurring independently of distinct lesions of the posterior roots or section of the spinal cord—that is, as a definite form of disease—is known as *tabes dorsalis*, and corresponds clinically to *locomotor ataxia.* There has been considerable discussion of late years as to whether this is due to systemic disease attacking primarily certain columns or tracts of fibers in the spinal cord, or to a condition secondary to disease of the posterior roots. The great majority of pathologists have now come to accept the latter view, and the evidence in its favor is so strong that it will be here adopted. The fibers of the posterior roots appear to originate in the spinal ganglia. Upon entering the cord they divide into the ascending and descending branches, both of which give off collaterals. They may be divided into two groups, the lateral and the median bundles. The lateral fibers are somewhat finer, and evidently belong embryologically to a different group, because they acquire their myelin-

sheaths later and pass directly into the zone of Lissauer, thence into the substantia gelatinosa of Rolando, and some of them terminate in arborization about the cells of the columns of Clarke. The median bundles, which consist of coarser fibers, pass inward, then upward to the inner side of the posterior roots, then bend in and form the columns of Burdach, and, finally, those from the lower regions of the cord enter the columns of Goll and terminate in the nucleus and the medulla. Experimental degeneration caused by section of the posterior roots in animals, or destruction of the posterior roots as a result of pathologic processes in human beings, causes ascending degeneration of the posterior columns that corresponds very closely in many respects to the lesions of tabes dorsalis (Fig. 358).

The macroscopic lesions of this disease are as follows: The

FIG. 358.—Sclerosis of the cord; from a specimen stained by Weigert's method.

dura shows no changes; the pia mater in the segment between the posterior roots is somewhat thickened and opaque, a change which cannot usually be observed in the lateral and anterior regions. The posterior roots may be enlarged. In the advanced cases, however, they seem to be somewhat thinner and more translucent. On section through the cord the gray matter, especially that of the septum and anterior horns, appears to be normal. The anterior and lateral regions of the white matter are similarly intact. In the most advanced cases the white matter between the posterior roots is darker than normal and seems to be shrunken. Its consistency is somewhat softer than that of the normal cord, and the fact that it becomes depressed after section shows that there is some tendency to retraction. In early cases these changes may be slight; in fact, in cords removed from patients suffering from general paresis, in which the earliest stages are usually observed, there may be no macroscopic changes found. In these

early stages sections stained by some myelin-method exhibit the following changes: In the lumbar region the columns of Goll are degenerated, excepting the anterior portion; usually there is a small oval region lying in the middle of the posterior septum; in the dorsal region there are usually two areas of degeneration in the column of Burdach; in the cervical region a portion of Goll's column is involved, and there are usually two areas on either side in the column of Burdach near the posterior horns. In nearly all cases there is usually more or less degeneration of the posterior roots. In the more advanced cases the portion of the posterior columns immediately behind the posterior commissure contains normal fibers, but all the rest of the posterior column and Lissauer's zone are degenerated. In the cervical portion the degeneration of the column of Goll is most pronounced, and there is only a small number of normal fibers anteriorly and on either side lying close to the posterior roots. The degeneration extends upward through the medulla as far as the nuclei of Goll and Burdach. It occasionally happens that one portion of the cord seems to be more severely affected than the others; as a general rule,

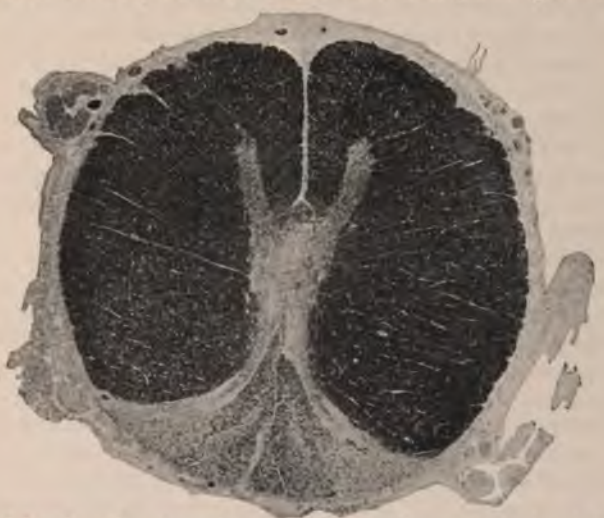

FIG. 359.—Sclerotic and contracted posterior columns in posterior sclerosis (Karg and Schmorl).

this is the lumbar region or the dorsal and lumbar regions, whilst the cervical portion shows fewer changes. Occasionally, however, the cervical portion of the cord will be particularly involved and the other regions more or less intact. In these cases the columns of Goll show only slight degeneration, whilst in the cervical portion the column of Burdach is markedly degenerated. As the fibers turn toward the center, healthy fibers from the posterior

roots of the cervical segments are usually less involved, so that the degenerated area lies near the posterior median septum, in the region usually called the middle root-zone. These degenerated areas are characterized by destruction of the myelin-sheaths and the axis-cylinders, their places being taken by proliferated neuroglia, which is characterized by the appearance of thicker and somewhat wavy fibers. In the late stages this hyperplastic neuroglia may undergo considerable contraction (Fig. 359). Proliferation of the neuroglia-cells may be observed in the earlier stages, but in the later stages this has largely disappeared. The degeneration of the fibers is in all respects similar to that of the ordinary secondary degeneration. Accumulation of the peculiar amyloid bodies is usually observed. The gray matter of the cord is little affected, the cells in particular rarely showing distinct traces of degeneration, although it is not unlikely that more careful investigation with the Nissl method will exhibit various changes in their finer structure. The fibers that normally pass through the gray matter often disappear completely. This is true especially of the fine fibers of Lissauer's zone and those that form the plexus around the cells of the column of Clarke. The reflex collaterals also frequently disappear, and this is supposed to explain the loss of the reflexes, which is a common symptom of the disease. The vessels usually exhibit some thickening of the adventitia, and occasionally an accumulation of granular cells either in the adventitia or beneath the ependyma. Hyaline degeneration is found occasionally. The pia mater, corresponding to its macroscopic appearance, shows some thickening of the fibers, although it is absent in the earlier cases.

The most interesting subject connected with this disease is the condition of the peripheral nerves, the spinal ganglia, and the posterior roots. Degeneration of the peripheral cutaneous nerves is frequently observed; but it is impossible to say, for lack of sufficient investigation, whether it occurs in every case. The changes consist of thickening of the perineurium and the connective-tissue trabeculæ, more or less degeneration of the myelin-sheaths, and occasionally swelling of the axis-cylinders.

The results of the examination of the spinal ganglia have been very contradictory, and some authors find them intact, while others describe contraction and irregularity in the outlines of the cells. In no case, however, have the changes been sufficiently pronounced to account for the extensive degeneration in the posterior columns. The posterior roots are invariably degenerated. Some of the fibers are completely destroyed, others show disappearance of the myelin-sheaths and alteration of the axis-cylinders. Nazeotte claims to have discovered a round-cell infiltration in the membranes surrounding the roots that causes a pressure-degeneration. Redlich and Obersteiner believe that the changes

are most marked after the entrance of the fibers into the cord, and explain this by supposing that there has been a slight constriction at the point where they pierce the pia mater. In this region there is certainly often considerable disappearance of the myelin-sheaths, but it cannot be said positively whether the intramedullary portion of the posterior roots is more degenerated than the extramedullary.

Friedreich's Ataxia.

In Friedreich's ataxia the most constant change is hypoplasia of the spinal cord. This hypoplasia may be regular, so that the whole cord is three-fourths or even less of its normal diameter, or it may seem irregular in the latter instance, being, perhaps, more pronounced in the cervical and upper dorsal regions. Hypoplasia of the cerebellum is a frequent associated lesion. The two conditions are, however, rarely equal, and, according as one or the other preponderates, Marie has described spinal and cerebellar forms of hereditary ataxia. The next most common lesion is degeneration in the posterior columns. This is particularly marked in the column of Goll, but, in severe cases, may also involve the column of Burdach. No degeneration at all may be found; such a case has been reported by Nonne; but in these instances the larger fibers are usually absent. Degeneration in Clarke's columns is not uncommon. The cells exhibit various forms of chronic degeneration, and the fibers either disappear completely, or at least lose their myelin-sheaths. As a result of this latter condition there is also degeneration of the ascending cerebellar column. In regard to the degenerative areas found in the lateral columns, there is much difference of opinion. The majority of authors believe that they represent degeneration of the pyramidal columns, although it is certain that none of the clinical symptoms associated with this lesion are present. The degeneration is usually most pronounced in the lower part of the cord, diminishes in intensity upward, and disappears near the normal decussation of the pyramidal columns. According to Marie, the degenerated areas usually lie to the outer side of the normal situation of the pyramidal columns. In all these degenerated areas there is considerable proliferation of the neuroglia-tissue, the fibers being especially increased, indicating the likelihood that the change is secondary. Other secondary changes are the thickening and partial adhesion of the pia mater, particularly that part in contact with the posterior columns of the spinal cord, and also the thickening of the walls of the blood-vessels, such as is usually found in sclerotic nervous tissue. Degeneration is also found in the posterior roots, which are smaller than normal. In regard to the condition of the peripheral nerves there is some difference of opinion, but it seems certain that, in some cases at

least, there is a degeneration of the sensory fibers. The disease partakes, therefore, of the nature of a combined sclerosis. Some authors hold that it is due primarily to a hypoplasia of the third primary vesicle and of the neural canal—that is to say, the medulla, cerebellum, and cord. The disease, however, appears to be slowly progressive, and it is not evident in infancy. This may be explained by assuming that the hypoplastic central nervous system is sufficient for the needs of the child, and that, as the organism develops, it becomes relatively insufficient. This, however, would not enable us to understand why such extensive secondary degenerations are sometimes present.

Amyotrophic Lateral Sclerosis.

Amyotrophic lateral sclerosis is a disease which, theoretically, should present the following pathologic changes: Degeneration in the pyramidal columns, atrophy of the ganglion-cells of the anterior cornua, degeneration of the nerve-fibers in the anterior roots and of the motor fibers in the peripheral nerves, and degenerative atrophy of the muscles. The lesions that are actually found, however, are very various. Common to almost all cases is the atrophy of the motor cells of the spinal cord and degeneration of their neuraxons, and the presence of compound granular cells, but there is no other sign of inflammatory reaction. The degeneration of the ganglion-cells is usually extensive, and the muscles exhibit the changes characteristic of progressive spinal muscular atrophy—that is, swelling of the fibers, increase of the number of the nuclei, indistinctness of the striation, and increase in the amount of connective tissue, with, in the later stages, extreme atrophy of the fibers. The degree to which the pyramidal columns are affected is not constant; at times the degeneration is pronounced and extends as far as the internal capsule. Indeed, distinct alterations have been reported in the motor cortex of the brain—that is to say, degeneration of the ganglion-cells and the presence, in more or less considerable number, of compound granular cells. In other cases the degeneration may cease at a lower point, and in at least one case was not found at all. It has been supposed that in such cases there is only a slight alteration in the nutrition of the ganglion-cells, and that the degenerative changes commence at the peripheral portion of the neuraxon and advance cellipetally. The changes found in the pyramidal columns are, of course, similar to those occurring in the other primary degenerations.

Combined sclerosis has been described in a great number of instances, and a characteristic symptomatology has been ascribed to the condition. Usually the parts affected are the posterior columns, the columns of Clarke, and, in part, the lateral pyram-

idal tracts. The lesions do not differ in appearance from those of the other forms of primary degeneration. The areas are gray, somewhat shrunken, and contain an excess of neuroglia, granular cells, and amyloid bodies. The nature of the process is still undecided. The frequency with which a certain definite combination occurs has led some neuropathologists to believe that it is a morbid entity. Others, however, contend that the parts of the cord affected are those least able, on account of their poor blood-supply, to resist noxious influences, and that, therefore, the disease is only the reaction of the weaker parts of the spinal cord to a general morbific agent.

Chronic anterior poliomyelitis, or **progressive spinal muscular atrophy,** is strictly a degeneration of the peripheral motor neuron. It is characterized by gradual atrophy of the ganglion-cells of the anterior cornua and by diminution of the size of the cornua themselves. No lesions that distinctly indicate the existence of an inflammatory process are present. The cells gradually grow smaller, become pigmented, and may ultimately disappear. There is degeneration of the fibers in the anterior roots and degenerative atrophy of the muscles. The clinical course is slowly but irregularly progressive. The condition in many respects resembles amyotrophic lateral sclerosis, and cases have been recorded in which other degenerations were found, particularly in Clarke's column and in the posterior columns. The lesions apparently commence in the cervical region, and may later extend to other parts of the cord, and even to the motor nuclei of the medulla. There is a form of chronic poliomyelitis in which distinct lesions of the vessels are present, and which is apparently only a slow form of the ordinary acute poliomyelitis.

Degenerations in the white matter of the spinal cord have been described in various forms of chronic anemia, especially pernicious anemia. Two varieties can be distinguished, those in which the areas of sclerosis are disseminated irregularly through the cord, and those in which the degeneration is systemic in nature and follows more or less closely the area of distribution of the fibers of the posterior root. In the latter case the posterior columns are affected most severely, and the lesions are most pronounced in the cervical region. Degeneration, however, may also be found in the lateral columns, either involving only a small patch of fibers, or so extensive as to give rise to the appearance of combined sclerosis. The degeneration appears to occur primarily in the nerve-fibers, with secondary proliferation of the neuroglia. Vascular changes, particularly minute hemorrhages and thickening of the vessel-cells, are also found, and when present the nerve-fibers in the immediate vicinity of the vessels are often degenerated. Lissauer's zone, the posterior

roots, the spinal ganglia, and the gray matter of the spinal cord are rarely involved. These changes are not, however, found in all cases of progressive pernicious anemia, a number of cases being now on record in which the spinal cord showed no trace of degeneration. No satisfactory explanation has hitherto been given to account for them. It has been suggested that the anemias with spinal lesions belong to a different group, but this is, of course, a mere hypothesis. The absence of degeneration in the posterior roots seems to exclude a peripheral neuritis, although it is possible that in case of slight disease of a spinal ganglia the terminations of their nerve-fibers in the medulla would exhibit the first trace of degeneration, and this, in fact, corresponds with the condition found in some of the cases.

Similar changes have also been found in other conditions, especially the chronic cachexias, such as tuberculosis, diabetes, and carcinoma. Tuczek has described changes occurring in the spinal cord in ergotism and pellagra. In the former the areas of degeneration were chiefly in the posterior columns, limited, excepting in the cervical regions, to Burdach's column, and there were lesions in the posterior roots. In the latter disease he found degeneration in Goll's column, particularly in Burdach's column, and usually in the lateral columns also. There was also partial disappearance of the cells of the anterior cornua, and small degenerative foci in the anterior columns. Marie believes that these lesions are due to degeneration of the endogenous fibers of the spinal cord. Changes limited to the posterior column have also been noted after diphtheria and leprosy. In old age small, irregular areas of degeneration, particularly in the posterior median column, and sometimes at the periphery of the spinal cord, may be observed.

SECONDARY DEGENERATIONS OF THE CORD.

Secondary degenerations of the spinal cord occur after any lesion interrupting the course of one or more of the columns of fibers, and also after any disease of the ganglion-cells that nourish these fibers. It has been divided into ascending and descending degeneration, according to the direction in which the degeneration proceeds. It will be clear, from the description already given of the course of the columns of the cord, that the chief variety of descending degeneration will be that of the pyramidal columns. This may occur as a result of injury to the motor cortex, or of interruption of the motor fibers in any part of their course from the cortex to the conus terminalis. If the lesion is unilateral and above the decussation, ordinarily only one pyramidal column is distinctly affected—that is to say, the anterior pyramidal tract of the same side and the lateral pyramidal tract of the opposite side. Careful microscopic investigations, however,

have shown that certain fibers that do not decussate, pass down the spinal cord in the lateral columns. In cases of long-standing secondary degeneration of the pyramidal columns a certain amount of simple atrophy of the ganglion-cells of the anterior cornua has

FIG. 360.—Sclerosis of the white substance of the cord.

been observed. Descending degeneration has also been observed in the posterior columns. In the upper portion of the cord it assumes the form of two small areas that project from a point slightly posterior to the gray commissure and extend backward and outward. This has been called the comma-degeneration of Schultze. In the lower part of the cord these descending fibers appear to approach the posterior commissure, and form the oval field of Flechsig. Descending degeneration for a short distance below a total transverse lesion may be found in all the columns. Ascending degeneration occurs chiefly in the posterior columns, and will be described in connection with tabes dorsalis. In case of isolated injury to one of the posterior roots, there may be traced upward a slender band of degeneration that gradually approaches the posterior septum. Ascending degeneration also occurs in the direct cerebellar tract, and may often be found to be associated with disease of the ganglion-cells in Clarke's columns. It extends as far as the restiform bodies in the medulla. Ascending degeneration also occurs in the anterolateral tract of Gowers.

After total transverse lesion secondary alterations may usually be detected in the remote portions of the cord in the course of from five to seven days. These alterations consist of a swelling of the axis-cylinders and, within a very short time, fatty degeneration of the myelin-sheaths. Granular cells appear early in the tissue. In the course of a month the degenerative changes are quite pronounced, and may readily be detected by Weigert's method. The myelin-sheaths have disappeared wholly or in part; the axis-cylinders have also vanished, although some varicose fibers may be found here and there in the lesion. Compound granular cells largely fill the field, but there is also a distinct hyperplasia of the neuroglia-tissue, giving the area, microscopically, a somewhat grayish appearance. Still later, contraction begins to occur, and the appearances seen in the primary degenerations are found.

TUMORS.

Glioma.—Of the primary tumors of the spinal cord, the most frequent and important is glioma. This is usually infiltrating in type and elongated, extending for a distance of several segments along the cord, and sometimes involving the nerve-roots, causing them to swell and become harder. It may give rise to curious distortions in shape, and an apparent hypertrophy; this latter is probably the result of the compression in a longitudinal direction of some portion of the cord, so that in a given section more ganglion-cells are found than would normally be present.

Sarcoma alone, or containing gliomatous or mucoid tissue, or of the type known as angiosarcoma, may also appear.

Carcinoma and sarcoma may also appear as metastatic growths.

Cysts are exceedingly rare, but both the echinococcus and the Cysticercus cellulosæ have been reported.

CHAPTER XIV.

DISEASES OF THE PERIPHERAL NERVOUS SYSTEM.

THE GANGLIA OF THE CRANIAL AND SPINAL NERVES.

The **ganglia of the cranial nerves** may be diseased as a result of extension of pathologic processes, usually tuberculosis, from the surrounding bony structures. It is probable that they are also subject to inflammatory changes. Spiller and Keen have reported the results of the examination of a number of Gasserian ganglia removed on account of persistent trifacial neuralgia, in

which they found degeneration—in some cases total—of the myelin-sheaths and the nerve-fibers in the ganglia. In one case the degenerated nerve-tissue was replaced by connective tissue, giving rise to marked sclerosis. Occasionally the cells in the ganglia had undergone atrophy, and in all instances the vessels were distinctly sclerotic, the lumen being sometimes completely obliterated. The authors believe that these changes are not primary, but secondary to lesions in the peripheral sensory nerves.

The **spinal ganglia** may also be diseased. Slight degenerative changes have been noted in locomotor ataxia and as a result of peripheral neuritis. In this case the walls of the ganglia show swelling and granulation of the chromatin-bodies, and are often somewhat shrunken. More frequently the ganglia are involved as a result of disease of the surrounding bones; particularly caries or sarcoma of the spine may produce pressure, resulting in atrophy, or, in the case of the former, areas of tubercular softening. The ganglia of the spinal nerves are sometimes found diseased in cases of herpes zoster, and are supposed to have an etiologic relation to that disease. Zinno has reported a case in which there appears to have been a chronic swelling of the ganglia, some of which were as large as a pigeon's egg, as a result of a hyperplasia of the neuroglia and the connective tissue. These swollen ganglia pressed upon the cord and produced secondary degenerations. Enlarged spinal ganglia have also been observed in acromegaly.

THE NERVES.

CIRCULATORY DISTURBANCES.

Hyperemia of the nerve-trunks attends acute inflammations. The vessels of the perineurium may be intensely injected.

Hemorrhages may result from acute congestion or from traumatic injuries. They take the form of punctate ecchymoses in the perineurium or endoneurium.

Edema of the nerve-trunks may occur in the nerves traversing areas of inflammation.

ATROPHY AND DEGENERATION.

Atrophy of the nerves occurs in consequence of pressure upon the nerve or as a result of disease (*neuritis*) of the nerves. It may also result from disease of the central nervous system, causing disturbance or destruction of the nuclei of origin of the peripheral nerves. Occasionally atrophy arises without definite cause in old age. The changes in the nerve are similar to those following section of the nerve, and are described under the heading Degeneration.

Degeneration.—Injury of a nerve in its course produces

various manifestations in the nerve-fibers corresponding more or less to the nature of the destructive agencies. It is obvious that, if the nerve be divided by a clean incision, the degenerative changes below the point of incision will be less extensive than if the destructive agent is severe, such as in cauterization, the crushing of the nerve-trunk with extensive disintegration, or the removal of a section of some length. Still milder changes, however, may be produced by a ligature that is not drawn tightly enough to destroy completely all the nerve-fibers. Degenerative changes are less pronounced if there is prompt coaptation of the injured ends, or if the continuity of the nerve is not entirely destroyed.

If a nerve is examined immediately after injury, there will be found only deformity of the nerve-fibers. This consists in dislocation of the myelin and perhaps fibrillation of the axis-cylinder, so that it seems to be crushed into and diffused throughout the white substance of the nerve-fiber. Within a few hours the cells in the myelin-sheath begin to exhibit signs of degeneration, the chromatin swells, stains more feebly, and may undergo fragmentation. At the end of eighteen hours the axis-cylinder is usually slightly swollen and its outline becomes irregular. These changes, however, are by no means uniform throughout the whole nerve; some parts perhaps being almost normal, and others extensively degenerated. Wieting states that the cones of Schmidt-Lantermann become evident, and are the first indication of nutritive disturbance. At the end of thirty-six hours the myelin-substance has undergone fatty degeneration, with the formation of small globules. These changes are found on both sides of the lesion; on the proximal side extending to the first node of Ranvier, and on the peripheral side extending considerably beyond this. At first the changes in both fragments are approximately equal, but those in the peripheral end rapidly progress, and soon dominate the field. The changes in the peripheral fragment, however, are more pronounced near the lesion and diminish toward the periphery. In the central end there are nearly always a few fibers that degenerate as far as the spinal cord, but these are the exception.

REGENERATION AFTER INJURY OF A NERVE.

The first sign of regeneration is proliferation of the cells of the sheaths. Their nuclei exhibit karyokinetic figures, and there appears to be an increase in their protoplasmic substance. At the same time the cells of the connective tissue also undergo multiplication and, to a certain extent, act as phagocytes, absorbing the fatty detritus. The protoplasm of the cells of the sheath gradually elongates and occupies the situation of the

myelin-substance and the old axis-cylinder. There appears to be some doubt whether these changes are more pronounced in the proximal or distal fragments; at any rate, the protoplasm of the cells of the sheaths on both sides of the lesion seem to possess phagocytic properties and to absorb some of the fat and detritus resulting from the degenerative changes. The protoplasmic mass usually closes the free ends of the nerve-fibers, and assumes a somewhat conical form, not unlike a node of Ranvier. This mass appears to be continuous with the partially degenerated end of the axis-cylinder. Toward the end of the first week the elongated protoplasmic masses in the end of the nerve-fibers become somewhat differentiated. In the interior may be seen a delicate fibrillated structure that appears to be continuous with the axis-cylinder of the nerve; outside of this is a delicate grayish membrane, but both of these structures lie within the old myelin-sheath, in as far as it is preserved. There is considerable dispute among pathologists as to whether the central fibrillated mass arises from the pre-existing axis-cylinder or from the protoplasm of the cells of the sheath. Stroebe maintains the former view, and believes that the axis-cylinder, as soon as a supporting and directing skeleton has been formed by the protoplasm of the cells, begins to grow, extending toward the lesion, outward along the protoplasmic support. It is certain, at any rate, that in the course of time the differentiation becomes so distinct that it can be seen that the fibrillated central portion is a delicate axis-cylinder continuous with the old one, and that the gray mass is becoming the myelin-sheath of the fiber. As the new nerve-fibers increase in length they gradually pass through the injured area and come in contact with the proximal area of the peripheral fragment. In this a somewhat similar, but certainly less active, process has been taking place—that is to say, the cells of the sheath have undergone proliferation and have formed protoplasmic masses at the ends of the fiber. Differentiation in this protoplasmic mass does not, however, appear to occur until the new axis-cylinder reaches it. Gradually the nerve approximates more and more closely to the normal appearance, the axis-cylinder becoming more distinct and the myelin-sheath thicker till it can be said to be re-established. In the course of the absorption of the fatty and other detritus, cells accumulate in the connective tissue of the nerve and between the fibers that are filled with fat-droplets, which are probably ordinary compound granular cells. It is questionable, however, whether they are derived from the endothelium of the lymph-spaces or from the leukocytes, or whether they represent the excess of the proliferated cells of the sheath. Somewhat later, concentric masses may be found that resemble very closely the amyloid or hyaloid bodies of the central nervous system. In the

study of these subjects, as in the study of the details of all the finer structures of the nervous system, much depends upon the freshness of the tissue, the method of fixation, and the stain employed. Stroebe used chiefly anilin-blue, which stains the axis-cylinder distinctly. Von Büngner employed saffranin. Neither method renders it absolutely certain whether the new axis-cylinder is formed by the elongation of the pre-existing axis-cylinder or from the protoplasm of the cells of the sheath. It seems, *a priori*, reasonable to conclude that if the axis-cylinder does not directly elongate and form the new axis-cylinder, at any rate it exercises some peculiar trophic influence upon the protoplasm of the cells in immediate contact with it, and is the cause of the peculiar differentiation into fibrillar substance. It is certain, moreover, that as this fibrillar mass grows downward it passes by the nuclei of the cells of the sheath, and does not appear to grow by the simple conversion of contiguous protoplasm. On the other hand, if the lesion has caused destruction of an extensive portion of the nerve, so that the new axis-cylinders do not come in contact with the peripheral fragment, they cease to grow, forming first an irregular mass of fibers with delicate myelin-sheaths, that are soon surrounded and compressed by fibrous connective tissue. It therefore seems plausible to believe that certain nutritive elements are contained in the peripheral segment, which, if they do not form the axis-cylinder directly, are at least absolutely essential to its growth and vitality.

INFLAMMATIONS.

Neuritis may be either acute or chronic. It has also been classified as parenchymatous and interstitial; the former comprising the degenerations of the nerve-fibers without involvement of the connective tissue, and the latter comprising all those forms associated with the characteristic signs of an inflammatory process in the connective tissue of the nerve.

Acute interstitial inflammation, or neuritis proper, may be caused by direct extension from an inflammatory focus in the surrounding tissue or by trauma, or as the result of some as yet unknown poison, which is generally supposed to be rheumatic in nature. It may also occur in the course of acute infectious diseases, or as an independent condition, as in beri-beri. The inflammatory changes occur in the perineurium and the endoneurium. The nerve is swollen, soft, and pinkish in color. Microscopically, both the perineurium and the trabeculæ of connective tissue are increased in size, the blood-vessels are distended, and there is extensive round-cell infiltration. In the acute forms partially degenerated fibers with fatty myelin-sheaths and swollen axis-cylinders are found very early. The primary change unquestionably occurs in

the connective tissue, and the nerve-fibers are involved secondarily, the myelin-sheaths being the parts first affected.

Chronic interstitial neuritis may follow the acute form or commence as an independent condition. The nerve is harder than

FIG. 361.—Neuritis: longitudinal section, showing degenerated nerve-fibers (black); Azoulay's method; × 300.

normal, the connective tissue is increased, the walls of the blood-vessels are thickened and their lumina may be partially obliterated. More or less round-cell infiltration is found in the hyperplastic

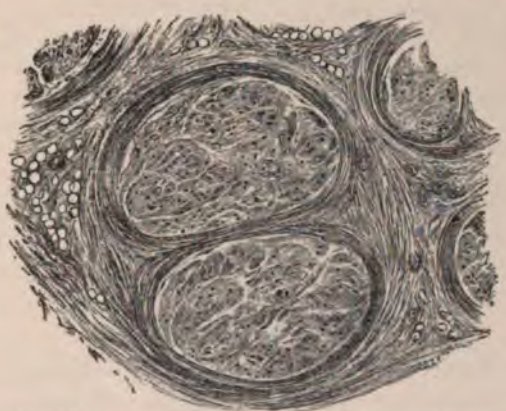

FIG. 362.—Chronic hypertrophic interstitial neuritis (case of Dejerine); × 100.

connective tissue, and the nerve-fibers show extensive degeneration, many of them having disappeared, and the few that remain presenting marked morbid changes. Often there is a distinct proliferation of the cells in the neurilemma. This form of neuritis

in particular is associated with muscular deger to give rise to the type known as the neural muscular atrophy. Associated changes are spinal cord, and consist of an ascending dege terior columns and more or less alteration o In a variety of this disease, described by Deje of *chronic hypertrophic interstitial neuritis*, the growth of the connective tissue, the nerve-tr firm cords, several times the normal thickne be felt beneath the skin. This disease is app hereditary influence; two of the three cases occurring in the same family. Microscopicall sist of an enormous proliferation of the co round-cell infiltration, partly about the scl and pronounced degeneration of the nerve-f undergo degenerative atrophy, and there are tions in the spinal cord.

Suppurative neuritis is nearly always secor in the tissue surrounding the nerve. It is presence of small foci of pus in the connective of the nerve-trunk. The nerve-fibers degene

Parenchymatous neuritis is characterized b ation of the nerve-fibers, the alterations in t being secondary. It is always due to som substance circulating in the fluids of the body. causes are lead, arsenic, alcohol, and diphtheri as a result of other poisons and infectious course of tabes dorsalis. The nerve-trunl firmer, and grayer. Inflammatory changes a while the degeneration of the nerve-fibers is p have frequently been found in the cells in the the spinal cord.

Polyneuritis does not differ from the isol that a number of nerve-trunks in various usually the limbs, are affected at the same ti quently of the parenchymatous type.

INFECTIOUS DISEASES.

Tuberculosis of the nerve-trunks is due It most commonly affects the roots of the n the course of tubercular spinal or cerebral pa connective tissue is first affected, and may c foci, in which epithelioid and giant-cells are fibers degenerate secondarily.

Syphilis also occurs, chiefly in the ner overgrowth of the connective tissue, particul

rium, with pressure upon and degeneration of the nerve-fibers. Gummata are sometimes observed upon the cranial nerves.

Leprosy is characterized by the presence, in the connective tissue of the nerve-fibers, of large epithelioid cells containing vacuoles more or less filled with lepra-bacilli. The bacilli cause a certain amount of hyperplasia of the connective tissue, which presses upon and eventually destroys the nerve-fibers. The disease affects the small cutaneous nerves almost exclusively, and causes anesthesia and trophic changes in the skin.

TUMORS.

Neuroma.—The tumors embraced by this term have been sufficiently described under the heading Neuroma, in Part I.

Sarcoma is a rare tumor of nerve-trunks. It takes its origin from the connective tissues of the nerve.

Muscle-fibers are sometimes found in intramuscular nerve-trunks. They usually exhibit proliferation of the nuclei, but the striations remain distinct. Their position has been ascribed to errors of development, but it is not certain that they are without function.

INDEX.

ABDOMINAL pregnancy, 652
Abnormal cell-division, 97
Abortion, tubal, 651
Abrin, poisoning by, 27
Abscess, 105
  actinomycotic, 249
  alveolar, 474
  of brain, 756
  of heart, 364
  of liver, 589
  of prostate, 671
  of spleen, 330
  of thyroid gland, 559
  of tonsil 478
  of vulva, 659
  perityphlitic, 508
  periurethral, 615
  retropharyngeal, 476
  submucous, of intestine, 505
Absolute immunity, 197
Accessory suprarenal bodies, 564
Acervuloma, 149
Acervulus cerebri, 775
Acetone, excess of, effects of, 40
Acetonuria, 607
Achromatic substance of nerve-cell, 733
Acid-intoxication, 33
  cryptogenic, 34
  etiology of, 34
  experimental, 34
  in man, 34
  symptoms of, 35
Acid-stain, definition, 301 (note)
Acne, pancreatic, 550
Acquired immunity, 197
Acrania, 727
Acromegaly, 687
  relation of pituitary body to, 774
Actinomyces bovis seu hominis, 247
Actinomycosis, 247
  of brain, 768
  of heart, 375
  of intestines, 516
  of lungs, 456
  of mouth, 473
  of muscles, 712
  of pericardium, 380
  of thyroid gland, 562
Actinomycotic abscesses, 249
Active hyperemia, 46
  immunity, 197
Acute yellow atrophy of liver, 527
Addison's disease, 566
Adenia, 137
Adenin, 36
Adenocarcinoma, 161
  of stomach, 497
Adenocystoma of ovaries, 640
Adenoma, 159
  alveolar, 160
  cystic, 162
  destruens, 161
  malignant, of stomach, 497
  of intestines, 516
  of kidney, 591
    congenital, 591
    papilliferous cystic, 592
  of liver, 537
    cystic, 539
  of mammary gland, 680
  of pituitary body, 774
  of suprarenal bodies, 566
  of testicle, 669
  of thyroid gland, 562
  of uterus, 634
    malignant, 634
  of vulva, 660
  racemose, 160
  tubular, 160
Adenomatous proliferation of glands of stomach, 494
Adenosarcoma, 161
  of kidney, 591
  of testicle, 669
Adhesions, formation of, 109
Aërobic bacteria, 189
Afanassiew, bacillus of, 261
Affentuberculose, 334
Agar-agar, 190
Age in the etiology of carcinoma, 164
"Ague-cake," 330
α-granules, 300
Air-embolism, 52, 54
Albuminoid degenerations, 71
Albuminous infiltration, 64. See *Cloudy swelling.*
Albuminuria, 608
Albumose, poisoning by, 28
Albumoses, formation of, 35
  in blood, effect of, 35
Albumosuria, 608
  enterogenic, 608
  from extensive burns, 20
  hematogenic, 608
  pyogenic, 608
Alcohol, poisoning by, 29
Aleukemic lymphadenoma, 138
Alexins, 198

Alimentary glycosuria, 37
Alkaloids, poisoning by, 29
Alloxin bases, 36
Alveolar abscess, 474
  adenoma, 160
  angiosarcoma, 144
  sarcoma, 143
Ameboid movements of red blood-corpuscles, 304
Amido-bodies in urine, 35
Amnion, 654
Amœba cachexica, 272
  coli, 265
    in liver, 539
  urinalis, 266
Amphistoma hominis, 296
Amphitrichous bacteria, 185
Amyelia, 780
Amyelinic neuroma, 154
Amylaceous bodies of prostate, 672
Amyloid degeneration, 71. See *Degeneration.*
    of arteries, 382
    of choroid plexus, 763
    of heart, 360
    of intestines, 502
    of kidney, 588
    of liver, 528
    of lymphatic glands, 334
    of muscles, 711
    of pancreas, 547
    of pituitary body, 773
    of spleen, 331
    of submucosa of stomach, 492
    of suprarenal bodies, 565
    of uterus, 631
  formations, local, 73
  material, composition of, 71, 73
Amyotrophic lateral sclerosis, 798
Anaërobic bacteria, 189
  cultures, 192
Anal fissure, 505
Anastomotic aneurysm, 391
Anemia, 313
  collateral, 47
  direct, 47
  local, 47
  lymphatic, 137
  of brain, 745
  of heart-muscle, 359
  of kidney, 568
  of liver, 522
  of lungs, 415
  of mucous membrane of mouth, 467
  of muscles, 707
  of pharynx, 475
  of pia, 715
  of spinal cord, 785
  of spleen, 328
  of stomach, 485
  primary, 315
  progressive pernicious, 317
  secondary, 313
  splenic, 315
Anemias, classification of, 313
Anemic infarcts, 53
Anencephaly, 730
Anesthetic leprosy, 236
Aneurysm, 388
  associated conditions in other parts with, 393
  cirsoid, 391
  cylindrical, 391
  definition of, 388
  dissecting, 390, 393
  ectatic, 390
  etiology of, 388
  false, 388, 395
  fusiform, 390
  miliary, 390
  of arteries of brain, 744
  of heart, 374
  pathologic anatomy of, 390
  saccular, 391
  spindle-shaped, 390
  spurious, 388, 395
  true, 388
  varicose, 395
Aneurysma racemosum seu cirsoideum 133
Aneurysmal varix, 395
Angina, 475
  herpetic, 475
  Ludovici, 477, 481
  Ludwig's, 477, 481
Angiolipoma, 134
Angioma, 132. See also *Hemangioma.*
  cavernosum, 133
  of bone, 698
  of liver, 536
  of penis, 663
  of spleen, 333
  telangiectaticum, 132
Angioneurotic edema, 61
Angiosarcoma, 139, 144
  alveolar, 144
  myxomatodes, 146
  of dura mater, 715
  plexiform, 144
Angiosclerosis, 384
Anguillula intestinalis, 290
  stercoralis, 290
Anhydremia, 307
Anilin, poisoning by, 28
Animal parasites, 265
    in etiology of disease, 31
Ankylosis of joints, 700
Ankylostoma duodenale, 289
  duodenalis, 520
Annectant gyri, abnormalities of, 730
Annelides, 296
Anteflexion of uterus, 620
Anteversion of uterus, 620
Anthracosis, 83
  of lungs, 439
  of lymphatic glands, 336
Anthrax, 242
  antitoxin of, 244
  bacillus of, 242
  of intestines, 515
  of muscles, 712
  of stomach, 493
Antistreptococcic serum, 205
Antitoxin, 199

Antitoxin, action of, 200
elimination of, 201
of anthrax, 244
of diphtheria, 214
of leprosy, 238
of tetanus, 247
of yellow fever, 261
Anuria, 606
Anus, fistula of, 510
Aorta, stenosis and atresia of, 347
Aphthous stomatitis, 468
Aplasia, definition of, 62
Apoplexia pulmonum vascularis, 415
serosa, 747
Appendicitis, 507
catarrhal, 507
gangrenous, 507
interstitial, 507
necrotic, 507
pathologic anatomy of, 507
recurring, 508
relapsing, 508
results of, 508
Aqueduct of Sylvius, 726
Arachnoid, cerebral, 715
cholesteatomata of, 722
edema of, 716
endothelioma of, 722
hemorrhages into, 715
inflammation of, 716
lipomata of, 723
syphilis of, 721
teratomata of, 723
tumors of, 721
spinal, 777
inflammation of, 777
syphilis of, 778
tuberculosis of, 778
Argyria, 85
Arnold on diapedesis, 49
Arsenic, poisoning by, 26
Arseniuretted hydrogen, poisoning by, 28
Arterial disorders, effect of, on circulation, 45
hemorrhage, 48
hyperemia, 45
Arteries, 381
amyloid degeneration of, 382
anatomic considerations of, 381
atrophy of, 381
calcareous infiltration of, 382
congenital defects of, 381
fatty degeneration of, 382
hyaline degeneration of, 382
hypertrophy of, 381
hypoplasia of, 381
inflammation of, 383
of brain, atheroma of, 743
colloid degeneration of, 743
hyaline degeneration of, 743
syphilis of, 744
syphilis of, 388
tuberculosis of, 388
Arteriocapillary fibrosis, 384
Arterioliths, 58
Arteriosclerosis, 384
Arteriosclerosis from nephritis, 584
Arteriosclerotic nephritis, 578
Arteritis, 383
acute, 383
productive, 383
suppurative, 383
Arthritis, 701
acute, 701
chronic, 701
dry, with ulceration, 702
purulent, 702
serous, 702
deformans, 702
gonorrheal, 616
gouty, 704
neuropathic, 703
rheumatoid, 702
senile, 702
Arthropodia, 296
Arthrospores, 184
Ascarides in liver, 540
Ascaris lumbricoides, 286, 520
maratiana, 287
mystax, 287
Ascites, 552
chyliform, 552
chylous, 552
Asphyxia, 22
Aspiration-pneumonia, 431, 434
Asporogenous races, 185
Association-fibers of brain, 725
Astrocytes, 769
Asymmetric karyokinesis, 97
Atavism, 18
Ataxia, Friedreich's, 797
Atelectasis, 423
congenital, 423
Atheroma of arteries of brain, 743
Atheromatous cyst of testicle, 671
plate, 385
ulcer, 385
Atmospheric pressure, decreased, in etiology of disease, 22
increased, in etiology of disease, 21
Atonic dilatation of stomach, 493
Atrophic cirrhosis of liver, 530
sclerosis of brain, 740
Atrophy, 62
acute yellow, of liver, 527
brown, 63
of heart, 370
definition of, 62
etiology of, 62
muscular, myopathic, 700
neuropathic, 709
progressive, 700
pseudohypertrophic, 711
simple, 711
numerical, 62
of arteries, 38
of bone, 692
of bone-marrow, 344
of gastric glands, 491
of heart, 370
of kidney, 585
of liver, 524
of lungs, 419

Atrophy of mucosa of intestines, 502
of lymphatic glands, 334
of mammary gland, 678
of muscles, 709
of nerves, 803
of pancreas, 546
of prostate, 672
of spleen, 331
of stomach, 491
of tongue and cheeks, 471
of uterus, senile, 631
puerperal, 631
of testicle, 663
pathologic anatomy of, 62
pathologic physiology of, 63
progressive spinal muscular, 799
simple, 62
Atropin, poisoning by, 29
Auricular septum of heart, defects of, 348
Auriculoventricular orifices, stenosis and atresia of, 348
Auto-intoxication, definition of, 19
Autonomous new-growths, 115
Avian tuberculosis, 235

BACILLUS, 182, 183
aërogenes capsulatus, 245
anthracis, 242
coli communis, 218
in urine, 610
in kidney, 595
œdematis maligni, 240
diphtheriæ, 211
cultivation of, 215
distribution of, 212
pathogenicity of, 212
icteroides, 260
influenzæ, 252
lepræ, 235
mallei, 239
neapolitanus, 218
of bubonic plague, 253
of Ducrey, 259
of malignant edema, 240
of syphilis, 254
of tetanus, 246
phlegmones emphysematosæ, 245
pneumoniæ of Friedländer, 210
proteus in urine, 610
pyocyaneus, 205
pyogenes fœtidus, 205, 218
tuberculosis, 223
culture of, 224
demonstration of, 225
distribution of, 226
in urine, 610
modes of infection by, 226
toxic properties of, 233
typhi abdominalis, 214
distribution of, 216
pathogenicity of, 215
cultivation of, 215
Bacteria, 181
artificial cultivation of, 190
etiology of, 188
cell-contents of, 183
Bacteria, cell-membrane of, 185
chemistry of, 186
classification of, 183
conditions of growth of, 189
definition of, 182
demonstration of, 186
diseases due to, 201
classification of, 30
embolism by, 52
entrance of, into the body, 31
functions and products of, 192
in etiology of disease, 29
in urine, 610
local effects of, 195
morphology of, 183
of kidney, 594
of suppuration, entrance of, into body, 104
in suppurative inflammation, 104
spores of, 184
staining of, 186–188
toxic products of, effects of, 196
poisoning by, 27
Bacteriaceæ, 183
Bactericidal action of bodily fluids, 198
Bacterioprotein, 104
Bacterium, 183
coli commune, 218
termo in urine, 610
Bacterinuria, 610
Balanitis, 661
Balantidium coli, 276
Ball thrombi, 57, 351
Basic stain, definition of, 301 (note)
Bednar's aphthæ, 469
Beggiatoaceæ, 183
Beri-beri, 265
Bichlorid of mercury, poisoning by, 24
Bile, pigmentations derived from, 87
Biliary cirrhosis of liver, 533
ducts, 541
dilatation of, 543
inflammation of, 541. See *Cholangitis.*
stenosis of, 542
tumors of, 544
Bilirubin-infarcts in urinary tubules, 88
in urine, 613
pigmentation by, 87
Biliverdin pigmentation, 87
Bilocular heart, 347
Biology of bacteria, 188
Black-tongue, 471
Bladder, 599
calculi of, 603
carcinoma of, 605
changes of position of, 599
circulatory disturbances of, 600
cysts of, 606
dilatation of, 599
exstrophy of, 599
fibro-adenoma of, 605
fibroma of, 605
hemorrhages of, 600
hyperemia of, 600
inflammation of, 600. See *Cystitis.*
malformations of, 599

Bladder, myoma of, 605
myxoma of, 605
papilloma of, 604
polypoid growths of, 604
rupture of, 600
syphilitic ulcers of, 602
tuberculosis of, 602
tumors of, 604
Blastomycetes as a cause of cancer, 272
"Bleeders," 50
Blood, anatomy of, 298
-casts, 582
changes in character of, effects of, on circulation, 45
in chlorosis, 316
-corpuscles, red, 298
alterations of isotonicity of, 305
ameboid movements of, 354
formation of, 303
nucleated, 304
pathogenic changes in, 303
pigmentation of, 305
shape of, 303
size of, 303
vacuolation of, 305
white, 298. See also *Leukocytes.*
-crisis, 304
-current, alterations in, a cause of thrombosis, 55
decrease of quantity of, effect of, on circulation, 45
-destruction, 95
diseases of, 298
fixation of, 325
fixed, preparations of, examination of, 325
foreign bodies in, 324
-formation, 303
fresh, examination of, 324
increase of quantity of, effect of, on circulation, 45
in leukemia, 321
in progressive pernicious anemia, 318
methods of examining, 324
parasites of, 324
-plaques, 302
-plasma, 302
pathologic changes in, 306
poisons, 28
-pressure, increased, a cause of edema, 59
increase of, hemorrhage from, 450
-serum as a culture-medium, 190
staining of, 325
-vessels, diseases of, hemorrhage from, 50
Bone, anatomy of, 682
angioma of, 798
atrophy of, 692
carcinoma of, 699
caries of, 692
cysts of, 699
development of, 683
diseases of, 682
disorders of, development of, 683
fibroma of, 698
Bone, giant growth of, 687
hemorrhage of, 688
hyperemia of, 688
hypertrophy of, 687
hypoplasia of, 692
inflammation of, 688
lepra of, 698
lipoma of, 698
-marrow, 343
atrophy of, 344
fatty infiltration of, 343
hypertrophy of, 344
inflammation of, 344
mucoid degeneration of, 343
pigmentation of, 343
myxoma of, 698
necrosis of, 693
parasites of, 699
regeneration of, 685
sarcoma of, 698
syphilis of, 697.
thrombosis of, 688
tuberculosis of, 694
tumors of, 698
Bothriocephalus cordatus, 286
cristatus, 286
latus, 285
liguloides, 286
Bouillon as a culture-medium, 190
Bow-legs, 700
β-oxybutyric acid, excessive formation of, in body, 34, 39
Brain, abscess of, 756
actinomycosis of, 768
anatomy of, 725
anemia of, 745
arteries of. See *Arteries of brain.*
carcinoma of, 771
circulatory disturbances of, 745
congenital abnormalities of, 727
degeneration of, after hemorrhage, 749
development of, 723
diseases of, 713
edema of, 747
local, 747
embolism of, 751
examination of, 727
fibroma of, 770
glioma of, 769
gummata of, 768
hyperemia of, 746
inflammation of, 753. See also *Encephalitis.*
lacerated wounds of, 760
lymphangioma of, 771
method of hardening, for examination, 727
multiple sclerosis of, 759
osteoma of, 771
post-mortem degenerative conditions of, 731
primary vesicles of, 723
punctate wounds of, 761
red softening of, 751
sand, 775
sarcoma of, 770
sclerosis of, atrophic, 740

Brain, sclerosis of, diffuse, 739
disseminated, 739
hypertrophic, 740
lobar, 758
syphilis of, 768
thrombosis of, 751
total absence of, 730
tuberculosis of, 767
tumors of, 768
white softening of, 751
yellow softening of, 751
Bread-and-butter pleurisy, 463
Breast. See *Mammary gland.*
male, abnormal development of, 676
Bright's disease, acute, 572
Bromin, poisoning by, 24
Bronchi, anatomic considerations, 409
anemia of, 409
congenital malformations of, 409
dilatation of, 412
foreign bodies in, 414
hemorrhages of, 409
hyperemia of, 409
inflammations of, 409
parasites of, 403
stenosis and obstruction of, 412
syphilis of, 413
tuberculosis of, 413
tumors of, 413
ulcers of, 412
Bronchiectasis, 412
cylindrical, 413
fusiform, 413
saccular, 413
Bronchiolitis, 433
exudativa, 412
Bronchitis, 409
acute catarrhal, 410
capillary, 433
chronic catarrhal, 410
fetid, 410
fibrinous, 411
Bronchogenic pneumonia, complications in, 450
purulent pneumonia, 440
tuberculosis of lungs, 443, 444
Bronchopneumonia, catarrhal, 430
etiology of, 430
pathogenesis of, 433
pathologic physiology of, 431
pseudolobar form of, 433
simple, 431
Bronchorrhea, 410
Brown atrophy, 63
of heart, 370
induration from hyperemia, 47
Bubo, 337
syphilitic, 255
Bubonic plague, 253
bacillus of, 253
Bullous emphysema of lungs, 421
Bursæ, inflammation of, 706
Bursitis, 796

CACHECTIC leukocytosis, 311
Cachexia strumipriva, 563
Calcareous infiltration of arteries, 382
Calcareous infiltration of spinal pia, 777
Calcicosis, 83
Calcification, 81
differentiation of, from ossification, 83
etiology of, 81
of choroid plexus, 762
of kidney, 588
of lymphatic glands, 335
of mucosa of stomach, 492
of muscles, 711
of spleen, 332
of testicle, 664
of thrombus, 58
of veins, 396
pathologic anatomy of, 81
physiology of, 83
seats of, 82
Calcium salts, poisoning by, 28
Calculi in bladder, 503
mulberry, 603
pancreatic, 550
phosphatic, 603
renal, 596
uric acid, 603
urinary, 603
Calculus in pelvis of kidney, 596
Callus, 596
intermediary, 687
myelogenous, 686
periosteal, 686
Calomel, poisoning by, 26
Canalization of a thrombus, 58
Cancer, 163. See *Carcinoma.*
cirrhotic, of liver, 537
colloid, 174
diffuse hepatic, 537
endothelial, 150
of stomach, 494
Cantharidin, poisoning by, 24
Capillary bronchitis, 433
hemorrhage, 48
Capsule of bacteria, 185
staining of, 188
Carbohydrates, disposition of, by the body, 37
value of, in nutrition, 31, 32
Carbolic acid, poisoning by, 24
Carbolized thionin, 187
Carbon-monoxid poisoning, 28
Carbonates in urine, 613
Carbonic acid in blood, effect of, 45
gas, poisoning by, 28
Carcinoma, 163
animal parasite in, 270
appearance of, 165
definition of, 163
degenerative changes in, 168
etiology of, 163
glandular, 172
medullary, 172
nature of, 169
of bladder, 605
of bone, 699
of hair, 771
of dura mater, 715
of esophagus, 484
of Fallopian tubes, 650

Carcinoma of intestines, 518
of kidney, 592
of larynx, 407
of liver, 537
of lungs, 458
of lymphatic glands, 343
of mammary gland, 680
of mouth, 473
of muscle, 713
of ovary, 643
of pancreas, 549
of penis, 662
of peritoneum, 557
of prostate, 675
of spinal cord, 802
of spleen, 333
of stomach, 494
of suprarenal bodies, 566
of testicle, 669
of thyroid gland, 562
of urethra, 618
of uterus, 634
of vagina, 654
of vulva, 661
parasites of, 270
pathologic physiology of, 170
scirrhous, 172
seats of, 166
secondary, 538
simple, 172
structure of, 166
theories as to causes of, 163
varieties of, 170
Carcinomatosis, general, 166
Carcinomatous cylindroma, 175
Cardioliths, 58
Caries of bone, 692
of teeth, 474
Carnification of lung-tissue, 424
Caseation, 93
of testicle, 664
Casts, blood-, 582
cellular, 582
crystalline, 582
fatty, 583
granular, 583
hyaline, 582
in urine in nephritis, 581
leukocytic, 582
waxy, 582
Catarrh, acute nasal, 402
mucopurulent, 105
Catarrhal appendicitis, 507
bronchopneumonia, 430. See *Bronchopneumonia.*
dysentery, 510
enteritis, 504
esophagitis, 482
jaundice, 544
pharyngitis, 475
pneumonia, 530
bacteria of, 210
stomatitis, 468
tonsillitis, 477
Caustic ammonium, poisoning by, 24
potash, poisoning by, 24
soda, poisoning by, 24
Caustics, action of, 24
Cavernoma, 133
lymphaticum, 132
Cavernous bodies of penis, inflammation of, 661
Cavities, tuberculous, 448
Cecitis, 506
Cecum, inflammation of, 506
Cell-contents of bacteria, 183
-division, abnormal, 97
-membrane of bacteria, 185
-multiplication, 110
-nuclei, degenerations of, 97
Cells, edema of, 80
Cellular and attraction theory of inflammation, 98
casts, 582
necrosis, etiology of, 97
general pathology of, 97
Central nervous system, injuries of, 760
Cephalohematoma, 688
internal, 713
Cercomonas coli hominis, 275
intestinalis, 274
Cerebellum, anatomy of, 726
hyperplasia of, 730
Cerebral arteries. See *Arteries of brain.*
hemispheres, hypoplasia of, 729
hemorrhage, 747
degeneration after, 749
massive, 748
punctate, 747
vesicles, primary, 723
Cerebrospinal fluid, 764
disease of, 764
meningitis, epidemic, 718
Cervix uteri, chronic endometritis of, 627
hypertrophy of, 631
phagedenic ulceration of, 527
sarcoma of, 634
Cestodes, 277
Chalicosis, 439
Chalmydobacteriaceæ, 183
Chancre, 255, 257
soft, 259
Chancroid, 259
of vulva, 660
Charcot-Neumann crystals of the blood, 322
Chauveau's theory of toxin immunity, 200
Cheesy pneumonia, 435
Chemical conditions,
effect of, on growth of bacteria, 189
Chemotaxis, negative, 100
positive, 100
Chilblain, 21
Chlorin, poisoning by, 24
Chloroform, poisoning by, 29
Chloroma, 149, 699
Chlorosis, 315
Cholangitis, 541
chronic, 542
results of, 542
suppurative, 532
Cholecystitis, 542

Cholelithiasis, 543
Cholera, 219, 511
bacillus of, 219. See *Spirillum choleræ Asiaticæ.*
etiology of, 219.
pathologic physiology of, 221
spirillum, 219. See *Spirillum choleræ Asiaticæ.*
Cholesteatoma, 180
of pia and arachnoid, 722
Cholesterin in fatty degeneration, 70
in fatty infiltration, 67
in urine, 613
Choluria, 607
Chondroblasts, 111
Chondrocarcinoma of testicle, 670
Chondroma, 127
appearance of, 127
definition, 127
etiology, 127
nature of, 129
of lung, 457
of mammary gland, 680
of mouth, 473
of muscles, 712
of ovary, 640
of pleura, 465
of testicle, 669
seats of, 128
structure of, 128
Chorion, 654
Choroid plexus, 761
amyloid degeneration of, 763
calcification of, 762
cysts of, 763
endotheliomata of, 763
epithelioma of, 763
fibroma of 763
hemorrhage into, 762
inflammation of, 762
pigmentation of, 763
tuberculosis of, 762
tumors of, 763
Chromogenesis, 195
Chromophilic bodies of nerve-cell, 733
Chromophoric bacteria, 195
Chronic inflammation, 105
relapsing fever, 137
Chyliform ascites, 552
Chylous ascites, 552
hydropericardium, 376
Chyluria, 132, 610
Cicatrices fistuleuse, 449
Circulation of blood, disturbances of, 43
Circulatory disturbances, 350
system, diseases of, 346
Circumscribed tumors, 118
Cirrhosis, atrophic, 530
biliary, 533
hypertrophic, 532
Laennec's, 530
of liver, 530
of pancreas, 548
Cirrhotic cancer of liver, 537
Cirsoid aneurysm, 391
Cladothrix, 183
Clap-threads, 617
Claustrum, 726
Cleft palate, 467
Cloudy swelling, 64
definition of, 64
etiology of, 764
of heart, 359
of kidney, 586
of liver, 526
pathologic anatomy of, 64
physiology of, 65
seats of, 65
Clubbing of finger-ends, 349
Coagulating ferments, 193
Coagulation-necrosis, 91
definition of, 91
etiology of, 91
morbid physiology of, 92
of muscle, 711
pathologic anatomy of, 91
Coal-dust pigmentation, 83
-tar derivatives, poisoning by, 28
Coccaceæ, 183
Coccidium oviforme, 269
perforans, 270
Coccus, 182
Coffee-ground vomit, 486
Cohnheim's theory as to origin of carcinoma, 163
of tumors, 116
Cold abscess of joints, 705
in etiology of disease, 21
Colitis, 509
mucous, 509
Collateral anemia, 47
hyperemia, 46
of lungs, 415
Colloid cancer, 174
of stomach, 497
cystomata of ovaries, 640
degeneration, 78. See *Degeneration.*
of arteries of brain, 743
of pituitary body, 773
goiter, 561
Colon, inflammation of, 509
Colpitis, 653
Combined sclerosis of spinal cord, 798
Comma-bacillus, 219
Comminuted fracture, 685
Commissural fibers of brain, 725
Compound fracture, 685
granule-cell, 584
Concentric hypertrophy of heart, 372
Concretions beneath prepuce, 663
in prostate, 672
in seminal vesicles, 676
in uriniferous tubules, 589
Concussion of dental nervous system, 760
Condensing osteitis, 691
Condyloma acuminatum of penis, 662
latum, 255, 257
Congenital cyanosis, 348
cystic hygroma, 132
rickets, 685
syphilis, 258
theory of carcinoma, 163
Congestion, hypostatic, 44
Conglutination of blood-plaques, 56

Connective tissue, fibrous, regeneration of, 111
regeneration of, 112
Contagious disease, definition of, 30
Contagium vivum, 29
Cor bovinum, 372
villosum, 377
Cord, spinal. See *Spinal cord.*
umbilical. See *Umbilical cord.*
Cornutin, 27
Coronary artery, embolism of, 351
thrombosis of, 351
Corpora quadrigemina, 726
Corpus callosum, congenital absence of, 729
fibrosum, 639
luteum, 639
Corpuscles of Hassall, 345
Corrosive chlorid of mercury, poisoning by, 26
poisons, 24
Coryza, 402
Cowper's glands, 675
Cranioschisis, 728
Craniotabes, 684
Crenothrix, 183
Cretinism, 563
Croton oil, poisoning by, 24
Croupous enteritis, 505
laryngitis, 406
pneumonia, 207, 425. See also *Pneumonia.*
Crura cerebri, 726
Crusta, 726
Cryptogenic acid-intoxication, 34
Cryptorchismus, 663
Crystalline casts, 582
Cultivation of bacteria, 190
Culture-media, 190
inoculation of, 191
Cultures, anaërobic, 192
Currant-jelly clots, 350
Curschmann's spirals, 412
Cutaneous absorption, pigmentation by, 85
Cyanogen-poisoning, 28
Cyanosis, 46
congenital, 348
Cyanotic induration of liver, 522
of lungs, 417
of the spleen, 328
Cyclencephaly, 728
Cylindrical aneurysm, 391
bronchiectasis, 413
cancer of stomach, 497
epithelioma, 171
Cylindro-adenoma, 162
Cylindroids, 584
Cylindroma, 145, 162
carcinomatous, 175
Cyst-adenoma, 162
Cystic adenoma, 162
of liver, 539
Cysticerci of tape-worm, 278
racemose, 279
Cysticercus cellulosæ, 540
Cystin in urine, 613
Cystitis, 600
mucopurulent, 601
phlegmonous, 601
pseudomembranous, 602
Cysto-adenoma of ovaries, 640
Cystocele, 624
vaginal, 652
Cystoids, 177
Cystoma of ovary, colloid, 340
glandular, 640
myxoid, 640
papillary, 641
Cystomata. Same as *Epithelial cysts*, 177
Cysts, 176
classification of, 177
dermoid, 180
due to foreign bodies, 177
epithelial, 177
of alveolar processes of jaw, 475
of bladder, 606
of bone, 699
of choroid plexus, 763
of Fallopian tubes, 650
of kidney, 592
of Kobelt, 644
of liver, 539
of lungs, 459
of mammary gland, 682
of mouth, 473
of pancreas, 549
of parovarium, 643
of penis, 662
of pituitary body, 774
of prostate, 675
of scrotum, 662
of spinal cord, 802
of spleen, 333
of testicle, 670
of urethra, 668
of uterus, 637
of vagina, 654
of vulva, 661
proliferation-, 177
retention-, 177
softening-, 177
tubo-ovarian, 650
Cytorcytes variolæ seu vaccinæ, 274

DAUGHTER-STARS, 111
Decidua, 654
hemorrhage from, 656
hyperplasia of, 657
inflammation of, 656
reflexa, 655
serotina, 655
vera, 654
Defensive proteids, 200
Degeneration, amyloid, 71
definition of, 71
etiology of, 71
local formations of, 73
of arteries, 382
of choroid plexus, 763
of heart, 360
of intestines, 502
of kidney, 588
of liver, 528

Degeneration, amyloid, of muscles, 711
of pancreas, 547
of pituitary body, 773
of spleen, 331
of submucosa of stomach, 492
of suprarenal bodies, 565
of uterus, 631
microscopic appearances of, 72
pathologic anatomy of, 71
physiology of, 73
reactions for, 73
seats of, 73
colloid, 78
definition of, 78
etiology of, 78
of arteries of brain, 743
of pituitary body, 773
pathologic anatomy of, 78
physiology of, 79
defined, 64
fatty, 68
definition of, 68
etiology of, 68
microscopic appearances of, 70
of arteries, 382
of gastric glands, 491
of heart, 362
of kidney, 587
of liver, 526
of muscles, 711
of prostate, 672
of suprarenal bodies, 565
of testicle, 664
of uterus, 631
of veins, 396
pathologic anatomy of, 69
physiology of, 70
seats of, 70
hyaline, 74
definition of, 74
etiology of, 74
of arteries, 382
of brain, 743
of heart, 360
of muscles, 711
pathologic anatomy of, 74
physiology of, 75
seats of, 75
mucoid, 76
definition of, 76
etiology of, 76
microscopic appearances of, 77
pathologic anatomy of, 77
physiology of, 78
seats of, 78
myxomatous, of mammary gland, 678
of testicle, 664
parenchymatous, 64
of heart, 360
of kidney, 586
of liver, 526
of muscles, 711
of pancreas, 547
Degenerations, 64
Deglutition-pneumonia, 431
Dendritic tumors, 118
Denecke, spirillum tyrogenicum, 222
Dental osteoma, 131
Dermatomyositis, 708
Dermoid cyst, 180
of choroid plexus, 763
of ovary, 642
of testicle, 671
Destructive adenoma, 161
Determining causes of disease, 19
Dextrinuria, 607
Dextrocardia, 347
δ-granules, 301
Diabète bronzé, 40, 88
Diabetes, 38
etiology of, 38
from puncture of medulla, 39
metabolism in, 39
pathogenesis of, 38
pathologic anatomy of, 40
phosphaticus, 41
Diacetic acid, excessive formation of, in body, 34, 39
Diaceturia, 607
Diapedesis of red blood-corpuscles, 48
in inflammation, 101
Diaphragmatic hernia, 499
Diastatic ferments, 193
Diastematomyelia, 780
Dichotomy of bacteria, 186
Diffuse nephritis, 571
acute, 573
sclerosis of brain, 739
Diffusion, escape of fluid by, 59
Dilatation of bladder, 599
of Fallopian tubes, 645
of heart, 371
of intestines, 498
of stomach, 492
atonic, 493
of ureter, 595
of uterus, 622
Diphtheria, 211
antitoxin of, 214
bacillus of, 211
-bacilli, non-pathogenic, 212
of animals, 212
of pharynx, 479
of vulva, 660
pathologic anatomy of, 213
physiology of, 213
toxin of, 213
Diphtheritic dysentery, 510
endocarditis, 354
inflammation, 103
laryngitis, 406
membrane, structure of, 103
rhinitis, 403
salpingitis, 647
Diplococcus intercellularis meningitidis in leptomeningitis, 716
pneumoniæ, 207
in diseases other than pneumonia, 209
Direct heredity, 18
Disease, causes of, 18
determining, 19
predisposing, 18
definition of, 17

Disease, etiology of, 18
Disorders of nutrition and metabolism, 31
Dissecting-aneurysm, 390, 393
Disseminated sclerosis of brain, 739
Distoma conjunctum, 296
  crassum, 296
  hæmatobium, 294, 540
    in kidney, 595
  hepaticum, 294, 540
  heterophyes, 296
  lanceolatum, 294, 540
  ophthalmobium, 296
  pulmonale, 296
  sinense, 296
Disturbances of circulation of blood, 43
Diverticula of intestines, 498
Diverticulum, Meckel's, 498
Dochmius duodenalis, 289
Dracunculus medinensis, 291
Dropsical infiltration, 80. See *Infiltration.*
    of liver, 528
Dropsy from nephritis, 585
  of gall-bladder, 543
  of joints, 701
  of peritoneum, 552
Dry gangrene, 95
  pericarditis, 376
Ducrey, bacillus of, 259
Ductus Botalli, patulous, 348
Duodenitis, 506
Duodenum, inflammation of, 506
Dura mater, 713
    angiosarcoma of, 715
    carcinoma of, 715
    fibroma of, 715
    gliosarcoma of, 715
    hemorrhages of, 713
    hyperemia of, 713
    inflammation of, 713
    syphilis of, 714
    tuberculosis of, 714
    tumors of, 715
    spinal, 775
      fatty infiltration of, 775
      fibroma of, 776
      hemorrhage into, 775
      lipoma of, 776
      myxoma of, 776
      sarcoma of, 776
      syphilis of, 776
      tuberculosis of, 775
      tumors of, 776
Dust-cells, 437
  -corpuscles, 304
  -embolism, 54
Dwarf tape-worm, 281
Dysentery, 510
  catarrhal, 510
  diphtheritic, 510
  gangrenous, 510
  ulcerative, 510
Dysmenorrhœa membranacea, 623
Dyspepsia, 488

ECCENTRIC hypertrophy of heart, 372
Ecchondromata, 127
Ecchondroses, 128
Ecchymosis, definition of, 51
Echinococcus cyst, 283
    of kidney, 595
    of larynx, 408
    of liver, 540
    of peritoneum, 558
    of testicle, 671
    of thyroid gland, 562
  endogenes, 284
  hydatidosus, 284
  multilocularis, 284
  scoliciparens, 283
Echinorrhynchus gigas, 293
Ectatic aneurysm, 390
Ectogenous teratoma, 179
Ectoplasm of bacteria, 185
Edema, angioneurotic, 61
  character of the liquid in, 61
  definition of, 59
  etiology of, 59
  from nephritis, 584
  inflammatory, 60
  malignant, 240. See *Malignant edema.*
  of brain, 747
    local, 747
  of cells, 80
  of intestines, 503
  of kidney, 569
  of larynx, 404
  of lungs, 417
  of nasal cavities, 402
  of nerves, 803
  of pharynx, 475
  of pia and arachnoid, 716
  pathologic anatomy of, 61
  results of, 61
Edematous inflammation, 103
  laryngitis, 405
ε-granules, 301
Ehrlich's classification of leukocytes, 299
  triple stain, 326
Electrical currents, effects of, on bacteria, 189
  influences in etiology of disease, 23
Elephantiasis congenita mollis, 132
  Græcorum, 235. See *Leprosy.*
  of scrotum, 662
  phlebectatic, 398
  vulvæ, 660
Emboli, 51
  sources and nature of, 51
Embolism, 51
  air-, 54
  dust-, 54
  fat-, 54
  infective, 54
  of brain, 751
  of coronary artery, 351
  of intestines, 503
  of kidney, 570
  of liver, 523
  of lungs, 419
  of muscles, 707
  of spermatic artery, 664
  of spleen, 328
  paradoxic, 52

Embolism, results of, 52
retrograde, 52
seats of, 52
Embryonic rests, 116
Emigration of leukocytes of blood, 48
-theory of inflammation, 98
Emphysema, infectious, 244
of lungs, 419
bullous, 421
interstitial, 419
senile, 422
substantial, 420
vesicular, 420
vicarious, 420
Empyema, 463
of gall-bladder, 542
Emulsifying ferments, 193
Encephalitis, 753
acute parenchymatous, 753
chronic, 758
primary acute hemorrhagic, 757
simple acute focal, 754
suppurative, 755
Encephalocele, 728
Encephalomalacia, 751
End-arteries of Cohnheim, thrombosis of, 53
Endarteritis, 383
chronica deformans, 384
obliterans, 387
of cerebral blood-vessels, 785
Endemic disease, definition of, 30
Endocarditis, 352
acute, 352
etiology of, 352
lesions in other organs in, 356
pathologic anatomy of, 353
results of, 355
changes in other organs in, 358
chronic, 356
etiology of, 356
pathologic anatomy of, 356
diphtheritic, 354
malignant, 354
micro-organisms of, 352
mural, 352
mycotic, 354
pathologic physiology of, 358
septic, 354
ulcerative, 354
verrucose, 354
Endocardium, 346
diseases of, 352
inflammation of, 352
Endogenic neurons, 727
Endogenous teratoma, 179
Endometritis, 624
acute catarrhal, 624
chronic, 625
of cervix, 627
decidualis, 656
exfoliativa, 623
glandularis, 625
interstitialis, 625
Endoplasm of bacteria, 185
Endospores, 184
Endosporium, 184
Endothelial cancer, 150
Endothelioma, 150, 400
of arachnoid and pia, 722
of choroid plexus, 763
of lungs, 457
of pleura, 465
Enteritis, 504
catarrhal, 504
chronic, 505
croupous, 505
etiology of, 504
follicular, 504
pathologic anatomy of, 504
physiology of, 506
pseudomembranous, 505
suppurative, 505
Enterocystoma, 498
Enterogenic albumosuria, 608
Enteroliths, 521
Enteromycosis, 516
Enterorrhagia, 51
Enzymes, 193
Eosinophile granules, 300
Ependymitis, 766
Epidemic cerebrospinal meningitis, 718
disease, definition of, 30
Epididymis, inflammation of, 664
tuberculosis of, 667
Epididymitis, 616, 664
acute, 665
Epiphysis cerebri, 775
Epispadias, 661
Epistaxis, 50, 402
Epithelial cysts, 177
perles, 171
Epithelioma, 171
contagiosum, animal parasites in, 272
cylindrical, 171
of choroid plexus, 763
of penis, 662
of scrotum, 662
of thymus gland, 345
squamous, 171
Epulis, 149, 474
Equatorial spores, 184
Ergot, poisoning by, 26
Erythroblasts, 303
Erythrocytes, 298
Erythrocytosis, 310
Escharotics, action of, 24
Esophagitis, catarrhal, 482
chronic catarrhal, 482
phlegmonous, 483
pseudomembranous, 482
ulcerative, 483
Esophagus, anemia of, 482
carcinoma of, 484
circulatory disturbances of, 482
congenital defects of, 482
dilatation of, 483
diverticula of, 483
inflammation of, 482
passive congestion of, 482
perforation and rupture of, 484
stenosis of, 483
syphilis of, 484
thrush of, 484

Esophagus, tuberculosis of, 484
tumors of, 484
Estivo-autumnal fever, parasite of, 268
État crible, 752
ségmentaire, 364
Ether, poisoning by, 29
Ethylendiamin, poisoning by, 29
Etiology, definition of, 17
of disease, 18
Eustrongylus gigas, 293
Exfoliative vaginitis, 653
Exogenic neurons, 727
Exosporium, 184
Exostoses, 130, 698
Experimental acid-intoxication, 34
glycosuria, 38
Exposure to general high temperature, effects of, 20
Exstrophy of bladder, 599
External hernia, 499
Extra-uterine pregnancy, 650

FACULTATIVE aërobes, 189
saprophytes and parasites, 189
Fallopian tubes, 644
anatomy of, 644
carcinoma of, 650
congenital abnormalities, 644
cysts of, 650
dilatation of, 645
displacement of, 644
fibromata of, 649
fibromyomata of, 649
hematoma of, 645
hemorrhages of, 645
hyperemia of, 645
inflammation of, 646. See *Salpingitis*.
lipoma of, 649
papillomatous elevations of, 649
sarcoma of, 650
stenosis of, 645
syncytioma malignum of, 650
syphilis of, 649
tuberculosis of, 648
tumors of, 649
False croup, 405
neuroma, 154
Fat-crystals in urine, 613
-embolism, 54
in fatty infiltration, staining of, 67
-necrosis, 94
of pancreas, 547
of body, origin of, 32
-splitting ferments, 193
Fats, value of, in nutrition, 31, 32
Fatty acids, origin of, 34
casts, 583
contracting kidney, 576
degeneration, 68. See *Degeneration*.
of arteries, 382
of gastric glands, 491
of heart, 362
of kidney, 587
of liver, 526
of muscle, 711
of prostate, 672
of suprarenal bodies, 565
Fatty degeneration of testicle, 664
of uterus, 631
of veins, 396
infiltration, 66
definition of, 66
etiology of, 66
of bone-marrow, 343
of dura mater of cord, 775
of heart, 361
of kidney, 588
of liver, 525
of mammary gland, 678
of muscles, 711
pathologic anatomy of, 66
physiology of, 67
seats of, 67
Febris undulans, 264
Femoral hernia, 499
Fermentation, 193
thrombosis, 55
Ferments, coagulating, 193
diastatic, 193
effects of, 193
emulsifying, 193
fat-splitting, 193
hydrolytic, 193
inverting, 193
oxidizing, 193
produced by bacteria, 192
proteolytic, 193
Fetal membranes, 654
Fetid bronchitis, 410
Fetus in fetu, 180
Fever, blood-changes in, 42
conservative effects of, 43
definition of, 41
effects of, on bacteria, 43
etiology of, 42
nature of, 41
pathologic results of, 42
Fibrin-ferment, poisoning by, 28
Fibrinous bronchitis, 411
inflammation, 103
pericarditis, 376
pleuritis, 462
pneumonia, 425
Fibrinuria, 609
Fibro-adenoma of bladder, 605
Fibroblasts, 111
Fibroid of uterus, 632
interstitial, 632
mural, 632
submucous, 632
subperitoneal, 632
phthisis, 449
polyps of uterus, 632
Fibroma, 120
appearance of, 121
definition of, 120
etiology of, 120
intracanalicular, 123
mammæ nodulum, 122
nature of, 123
of bladder, 605
of bone, 698
of brain, 770
of choroid plexus, 763

Fibroma of dura mater, 715
of cord, 776
of Fallopian tubes, 649
of intestines, 516
of kidney, 590
of larynx, 407
of liver, 536
of lungs, 457
of mammary gland, 679
intracanalicular, 679
of mouth, 473
of muscles, 712
of ovaries, 640
of penis, 663
of peritoneum, 557
of pleura, 465
of spleen, 333
of stomach, 493
of testicle, 669
of tooth-pulp, 474
of vagina, 654
of vulva, 660
seats of, 122
structure of, 123
Fibromyoma of Fallopian tubes, 649
of vulva, 660
Fibrosarcoma of ovary, 640
Fibrosis, general, 108
Fibrous connective tissue, regeneration of, 111
goiter, 561
pneumonia, 437
peribronchial, 439
perivascular, 439
pleurogenic, 439
secondary, 439
Filaria bronchialis, 293
diurna, 292
hominis oris, 293
immitis, 293
in peritoneum, 558
labialis, 293
lentis, 293
loa, 293
medinensis, 291
nocturna, 292
perstans, 292
sanguinis hominis, 291
in kidney, 595
Filariasis, 292
Filtration, escape of fluid by, 59
Fissure, anal, 505
Fistula in ano, 510
Fixation of blood, 325
Flagella of bacteria, 185
staining of, 188
Fleshy moles, 656
Fluke-worms, 293
Fœtus in fœtu, 643
Follicular cysts of ovary, 640
enteritis, 504
tonsillitis, 477
ulcers of intestine, 505
Food, diminished supply of, 31
increased supply of, effect of, 32
necessary constituents of, 31
Foot-and-mouth disease, 469
Foreign bodies, changes in tissues around, 108
in blood, 324
in intestine, 520
in larynx, 408
in tissues, 19
Formative cells, 111
Fowl-tuberculosis, 235
Fracture, 685
comminuted, 685
compound, 685
repair of, 685
Fragilitas ossium, 692
Friedreich's ataxia, 797
Frog-face, 730
Fuchsin bodies of cancer, 272
Fuchsinophile granules in fatty degeneration, 70
Fungiform tumors, 118
Fungoid tumors, 118
Fungus of testicle, benign, 665
syphilitic, 669
Furring of tongue, 468
Fusiform aneurysm, 390
bronchiectasis, 413

GALACTOCELE, 682
Galactorrhea, 678
Gall-bladder, 541
contraction of, 543
dilatation of, 543
dropsy of, 543
empyema of, 542
inflammation of, 542
tumors of, 544
Gall-stones, 543
Ganglia of cranial nerves, disease of, 802
Ganglion, 706
Ganglionar neuroglioma, 769
Gangrene, 95
definition of, 95
dry, 95
gaseous, 240
moist, 96
of lungs, 442
of vulva, 660
primary, 95
secondary, 95
Gangrenous appendicitis, 507
dysentery, 510
inflammation, 109
stomatitis, 469
Gaseous gangrene, 240
Gastrectasia, 492
Gastric glands, atrophy of, 491
fatty degeneration of, 491
mucosa, pigmentation of, 491
Gastritis, acute, 486
chronic, 486
hypertrophic, 487
interstitial, 488
pathologic anatomy of, 486
physiology of, 488
pseudomembranous, 486
ulcerative, 486
Gastro-intestinal tract, diseases of, 467
Gastromalacia, 492

Gastrophthisis, 488
Gastroptosis, 492
Gelatin as a culture-medium, 190
Gelatinous cancer, 174
General fibrosis, 108
  pathology, definition of, 17
Genital pore of tapeworm, 278
Genu valgum, 700
  varum, 700
Geographical tongue, 468
Germinal cells, 723
γ-granules, 301
Giant growth of bone, 687
Giant-cell sarcoma, 147
  -cells of tuberculosis, 229
  sarcoma of alveolar process of jaw, 474
Gibraltar fever, 264
Gin-drinker's liver, 530
Glanders, 239
  bacillus of, 239. See *Bacillus mallei.*
  effect on nasal cavities, 403
  of larynx, 407
  of lungs, 456
  of muscles, 712
  of pharynx, 480
Glandular carcinoma, 172
  cystomata of ovaries, 640
Glans penis, inflammation of, 661
Gleet, 617
Glioma, 151
  ganglionare, 153
  of eyeball, 153
  of hair, 769
  of spinal cord, 802
  of suprarenal bodies, 566
Gliosarcoma of dura mater, 715
Gliosis, hypertrophic nodular, 729
Globular thrombi, 351
Globulinuria, 608
Globus pallidus, 725
Glomerulonephritis, 572
Glossitis, 468, 470
  hemilateral, 471
  parenchymatous, 471
Glycemia, 37
Glycogen, formation of, 37
  staining of, 80
Glycogenic infiltration, 79. See *Infiltration.*
    of kidney, 588
Glycosuria, 37, 606
  alimentary, 37
  clinical causes of, 38
  experimental, 38
Goiter, 559
  colloid, 561
  definition of, 559
  etiology of, 560
  fibrous, 561
  mechanical effects of, 561
  parenchymatous, 560
  pathologic anatomy of, 560
  secondary changes in, 561
  vascular, 561
Golgi cells, 726
Gollasch's mixture, 325
Gonococcus of Neisser, 206
Gonorrhea, 614
  bacteriology of, 206
Gonorrheal arthritis, 616
  tenosynovitis, 616
  urethritis, 617
Gout, 36
  etiology of, 36
  pathogenesis of, 36
  pathogenic anatomy of, 36
Gouty arthritis, 704
  nephritis, 578
  tophi, 36, 704
Gram's method of staining bacteria, 187
Granular casts, 583
Granulations, 107
Granule-cell, compound, 584
Granules of the leukocytes, 300–302
Granuloma fungoides, 149
Grape-sugar in blood and urine, 37
Graves' disease, 564
Grawitz, slumbering cells of, 101
Gray hepatization of lung, 428
Guanin, 36
Gummata, 256
  of bones, 697
  of brain, 768
  of lungs, 454
  of lymphatic glands, 341
  structure of, 227
Gymnobacteria, 185

HAIRY polyp, 404
Hansen bacillus lepræ, 235
Hard papilloma, 158
Harelip, 467
Healing by first intention, 107
  by granulations, 107
  by immediate union, 106
  by second intention, 107
Heart, 346
  abnormality of position of, 347
    in size of, 347
  abscess of, 364
  actinomycosis of, 375
  amyloid degeneration of, 360
  anatomic considerations of, 346
  aneurysm of, 374
  atrophy of, 370
  bilocular, 347
  cloudy swelling of, 359
  congenital diseases and deformities of, 346
  defective development of, 347
  degenerations of, 359
  development of, 346
  dilatation of, 371
  -diseases, effect of, on circulation, 44
  fatty degeneration of, 362
    infiltration of, 361
  hyaline degeneration of, 360
  hypertrophy of, 371
  hypoplasia of, 370
  inflammation of, 364
  -muscle, anemia of, 359
    brown atrophy of, 63
    hemorrhages in, 359
    hyperemia of, 359

Heart, parasites of, 375
parenchymatous degeneration of, 359
pathologic physiology of, 348
segmentation of fibres of, 363
syphilis of, 375
thrombi in, 57
thrombosis of cavities of, 350
trilocular, 347
tuberculosis of, 375
tumors of, 375
wounds and rupture of, 374
Heat-dissipation, 41
effect of, on growth of bacteria, 189
in etiology of disease, 20
local excess of, effect of, 20
-production, 41
Hemangioma, 132
appearance and seats of, 133
definition of, 132
etiology of, 133
nature of, 135
of mouth, 473
structure of, 133
Hematemesis, 51
Hematoblast, 302
Hematocele, retro-uterine, 624
Hematochromatosis, 502
of liver, 525
of pancreas, 547
Hematochyluria, 292, 610
Hematogenic albumosuria, 608
pneumonia, 425
purulent, 441
tuberculosis, 451
Hematogenous pigmentation, 85, 87
local, 86
Hematoidin in urine, 613
pigmentation by, 85
Hematoma, definition of, 51
of Fallopian tube, 645
of vulva, 659
Hematomyelia, 787
Hematosalpinx, 648
Hematozoön malariæ, 267
Hematuria, 609
Hemicrania, 728
Hemilateral glossitis, 471
Hemispheres, cerebral, anatomy of, 725
Hemocytolysis, 309
Hemofuscin, pigmentation by, 85
Hemoglobin in urine, 613
-derivatives, pigmentation by, 85
Hemoglobinemia, 309
Hemoglobinuria, 609
from extensive burns, 20
paroxysmal, 609
Hemokoniæ, 304
Hemolysis, 95, 309
Hemopericardium, 376
Hemophilia, 50
Hemoptysis, 51
Hemorrhage, 48
arterial, 48
capillary, 48
causes of, 49, 262
cerebral, 747
massive, 748
Hemorrhage, cerebral, punctate, 747
classification of, 50
due to disease of blood-vessels, 50
from increase of blood-pressure, 50
neuropathic, 50
of bladder, 600
of bone, 688
of bronchi, 409
of choroid plexus, 762
of decidua, 656
of dura mater, 713
of cord, 775
of Fallopian tubes, 645
of heart-muscle, 359
of intestines, 503
of joints, 700
of kidney, 569
of larynx, 404
of lungs, 417
of mammary gland, 677
of mouth, 468
of muscles, 707
of nerves, 808
of ovary, 638
of pancreas, 546
of pericardium, 376
of peritoneum, 551
of pharynx, 475
of pia, 715
of pituitary body, 773
of spinal cords, 786
of spleen, 328
of stomach, 485
of suprarenal bodies, 566
of uterus, 624
of vagina, 653
parenchymatous, 48
per diabrosin, 50
per diapedesim, 48
per rhexin, 48
results of, 51
traumatic, 50
venous, 48
Hemorrhagic diathesis, 50
diseases, bacteriology of, 262
infarcts, 51, 53
of lungs, 417
inflammation, 109
myositis, 707
pachymeningitis, 713
pericarditis, 378
pleuritis, 464
vaginitis testis, 667
Hemorrhoids, 503
Hemosiderin, pigmentation by, 85
Hemothorax, 460
Hepatitis, 529
interstitial, acute, 529
chronic, 530
parenchymatous, 529
Hepatization of lung, 427
gray, 428
red, 427
Heredity as a factor in etiology of carcinoma, 165
as a predisposing factor in disease, 18
direct, 18

Heredity, immediate, 18
polymorphous, 36
remote, 18
Hernia, 499
diaphragmatic, 499
direct, 499
etiology of, 499
external, 499
femoral, 499
indirect, 499
inguinal, 499
internal, 499
irreducible, 500
pathologic anatomy of, 499
reducible, 500
retroperitoneal, 499
strangulated, 500
Herpetic angina, 475
laryngitis, 405
Heteroplastic osteoma, 131
Heterotopia of gray matter of spinal cord, 780
Hexathyridium pinguicola, 296
venarum, 296
Hippuric acid in urine, 612
Hirudo ceylonica, 296
vorax, 296
Hodgkin's disease, 137, 323
Horseshoe kidney, 567
Housemaid's knee, 706
Hutchinson's teeth, 259, 474
Hyaline cast, 582
degeneration, 74. See *Degeneration.*
of arteries, 382
of brain, 743
of heart, 360
of lymphatic glands, 335
of muscles, 711
of spleen, 332
Hydatid moles, 658
Hydatids of Morgagni, 650
Hydremia, 307
Hydrocele, 664, 666
funiculi cystica, 667
spermatici, 667
processus vaginalis, 667
spermatica, 666
Hydrocephalus, 764
acquired, 764
acute, 720
acquired internal, 766
chronic, 766
congenital, internal, 764
external, 766
partial, 766
Hydrofluoric acid, poisoning by, 24
Hydrogen-sulphid poisoning, 28
Hydrolytic ferments, 193
Hydrometra, 622
Hydronephrosis, 596
Hydrops articulorum, 702
ex vacuo, 716
omenti, 552
Hydromyelia, 781
Hydropericardium, 376
chylous, 376
Hydrophobia, bacteriology of, 262
Hydrorrhachus, 781
Hydrorrhœa gravidarum, 655
Hydrosalpinx, 648
Hydrothionuria, 607
Hydrothorax, 461
Hygroma, congenital cystic, 132
duræ matris, 714
of pia, 716
Hyperchromatosis, 97
Hyperemia, active, 46
arterial, 46
collateral, 46
local, 46
neuroparalytic, 46
neurotic, 46
of bladder, 600
of bone, 688
of brain, 746
of dura mater, 713
of Fallopian tubes, 645
of heart-muscle, 359
of joints, 700
of kidneys, 569
of liver, 522
of mammary gland, 676
of mouth, 468
of muscles, 707
of nerves, 803
of pericardium, 376
of pia, 715
and arachnoid of cord, 777
of pituitary body, 773
of pleura, 460
of spinal cord, 785
of spleen, 328
of testicle, 664
of uterus, 623
passive, 623
of vagina, 653
of vulva, 659
passive, 46
venous, 46
Hyperglycemia, 38
Hyperinosis, 306
Hyperplasia, 114
of deciduæ, 657
of mucous membrane of uterus, 631
of spleen, 331
Hyperplastic perihepatitis, 556
Hyperthyroidism, 564
Hypertonicity of the blood-serum, 306
Hypertrophic cirrhosis of liver, 532
enlargement, 114
gastritis, 487
nodular gliosis, 729
sclerosis of brain, 740
Hypertrophy, 113
definition of, 113
etiology of, 114
numerical, 114
of arteries, 381
of bone, 687
of bone-marrow, 344
of cervix uteri, 631
of heart, 371
with dilatation, 372
of kidney, 586

Hypertrophy of liver, 534
of lungs, 419
of lymphatic glands, 334
of mammary gland, 678
of muscles, 706
of pituitary body, 772
of prostate, 672
of testicle, 664
of uterus, 631
pathologic anatomy of, 114
physiology of, 114
simple, 114
true, 114
Hypinosis, 306
Hypochromatosis, 97
Hypoleukocytosis, 312
Hypophysis cerebri, 771. See also *Pituitary body.*
Hypoplasia, definition of, 62
of arteries, 381
of bone, 692
of cerebellum, 730
of cerebral hemispheres, 729
of heart, 347, 370
Hypospadias, 661
Hypostatic congestion, 44
of lungs, 416
pneumonia, 431, 434
Hypoxanthin, 36

ICTERUS, 544. See *Jaundice.*
seu febris amantium, 316
Ileitis, 506
Ileum, inflammation of, 506
Ileus, 500
Immediate heredity, 18
Immunity, 197
absolute, 197
acquired, 197
active, 197
mechanism of, 198
natural, 197
passive, 197
relative, 197
toxin-, 199
varieties of, 197
Inanition, 31
Indicanuria, 607
Indigestion, 488
Indigo in urine, 613
Indirect cell-division, 110
Indolent ulcer, 105
Infarction, 53, 684
Infarcts, anemic, 53
formation of, 53
hemorrhagic, 53
placental, 656
pulmonary, 54
subsequent changes in, 54
white, 53
Infection, 196
Infectious disease, definition of, 30
embolism, 54
emphysema, 244
bacillus of, 245
leukocytosis, 310
Infiltrating tumors, 118
Infiltration, albuminous, 64
calcareous, of arteries, 382
defined, 64
dropsical, 80
fatty, 66. See *Fatty infiltration.*
glycogenic, 79
definition of, 79
etiology of, 80
pathologic anatomy of, 80
physiology of, 80
of kidney, 588
inflammatory, 101
lymphoid, 137
medullary, of lymphoid structures of intestine, 512
uratic, 83
Inflammation, 98
as a cause of necrosis, 90
changes in the blood-vessels in, 99
chemotactic action in, 100
chronic, 105
definition of, 98
degenerative changes in tissues in, 101
diphtheritic, 103
edematous, 103
etiology of, 102
exudation in, 99
fibrinous, 103
gangrenous, 109
hemorrhagic, 109
historical views of, 98
interstitial, 106
necrotic, 109
of appendix vermiformis, 507. See *Appendicitis.*
of arachnoid, 716
spinal, 777
of arteries, 383
of biliary ducts, 547. See *Cholangitis.*
of bladder, 600. See *Cystitis.*
of bone, 688
of bone-marrow, 344
of brain, 753. See, also, *Encephalitis.*
of bronchi, 409
of bursæ, 706
of cavernous bodies of penis, 661
of cecum, 506
of colon, 509
of decidua, 656
of duodenum, 506
of dura mater, 713
of epididymis, 664
of Fallopian tubes, 646. See *Salpingitis.*
of gall-bladder, 542
of ileum, 506
of intestines, 504
of joints, 701. See *Arthritis.*
of kidney, 570. See *Nephritis.*
of larynx, 405
of liver, 529. See *Hepatitis.*
of lungs, 425
of lymphatic glands, 336
of lymphatic vessels, 399
of mammary gland, 677
of mouth, 468
of muscles, 707. See *Myositis.*
of nasal cavities, 402

Inflammation of nerve, 806. See *Neuritis.*
of ovaries, 639
of pancreas, 548
of pelvis of kidney, 596
of pericardium, 376
of peritoneum, 553. See *Peritonitis.*
of pharynx, 475
of pia, 716
of cord, 777
of pituitary body, 773
of placenta, 656
of pleura, 461
of prostate gland, 671
of pulp of teeth, 474
of rectum, 509
of salivary glands, 481
of seminal vesicles, 675
of spinal cord, 787. See *Myelitis* and *Poliomyelitis.*
of spleen, 329
of suprarenal bodies, 566
of tendon-sheaths, 706
of testicle, 664. See *Orchitis.*
of thoracic duct, 401
of thymus gland, 345
of thyroid gland, 559
of thyroid plexus, 762
of trachea, 408
of ureter, 597
of urethra, 614
of uterus, 624
of vagina, 653. See *Vaginitis.*
of vas deferens, 667
of veins, 396
of vulva, 659
parenchymatous, 106
phenomena in, 98
productive, 105
proliferative changes in, 101
resolution after, 109
round-cell, 101
serous, 103
special forms of, 102
suppurative, 104
theories of, 98
Inflammatory edema, 60
infiltration, 101
leukocytosis, 310
osteoporosis, 691
Influenza, 252
bacillus of, 252
Inguinal hernia, 499
Inhibitory action of bodily fluids, 198
Inoculation of culture-media, 191
Insects, venom of, poisonous effects of, 27
Insufficiency of heart-valves, 357
Intermediary callus, 687
Internal hernia, 499
Interstitial appendicitis, 507
emphysema of lungs, 419
gastritis, 488
hepatitis, acute, 529
chronic, 530
inflammation, 106
nephritis, 571
acute, 573
chronic, 577
Interstitial neuritis, acute, 806
chronic, 807
hypertrophic, 808
pregnancy, 650
uterine fibroids, 632
Intestinal obstruction, 500
Intestines, 497
abnormalities of, 497
absence of parts of, 497
actinomycosis of, 516
active hyperemia of, 503
adenoma of, 516
amyloid degeneration of, 502
anthrax of, 515
atrophy of mucosa of, 502
carcinoma of, 518
circulatory disturbances of, 503
congenital abnormalities of position of, 498
congenital enlargement of, 498
dilatation of, 498
distortion of, 497
diverticula of, 498
edema of, 503
embolism of, 503
fibroma of, 516
follicular ulcers of, 505
foreign bodies in, 520
hemorrhage of, 503
infectious diseases of, 510
inflammatory papilloma of, 516
internal strangulation of, 500
invagination of, 501
lipoma of, 516
myoma of, 518
myxoma of, 516
narrowing of, 497, 498
obstruction of, 500
parasites of, 519
passive hyperemia of, 503
peptic ulcer of, 505
pigmentation of, 502
rupture of, 520
sarcoma of, 516
stenosis of, 498
submucous abscess, 505
syphilis of, 515
thrombosis of, 503
tuberculosis of, 514
tumors of, 516
ulceration of, 505
Intoxication, 196
as a cause of necrosis, 90
Intracanalicular fibroma, 123
of mammary gland, 679
Intussusception, 501
Invagination of intestine, 501
Invasion diseases, definition of, 31
Inversion of uterus, 622
Inverting ferments, 193
Involution-forms of bacteria, 185
Iron-particles, pigmentation by, 83
Irreducible hernia, 500
Irregular pneumonias, 210
Ischemia, 47
Isotonicity of red blood-corpuscle, alterations of, 305

JAUNDICE, 544
catarrhal, 544
etiology of, 544
pathologic anatomy of, 545
Joints, ankylosis of, 700
cold abscess of, 705
diseases of, 700
distortion of, 700
dropsy of, 701
hemorrhage into, 700
hyperemia of, 700
inflammation of, 701. See *Arthritis.*
luxation of, 700
syphilis of, 705
tuberculosis of, 704
tumors of, 706

KARYOKINESIS, 110
abnormal, 97
asymmetric, 97
multipolar, 97
Karyokinetic figures in erythroblasts, 305
Karyomitosis, 110
Karyorrhexis, 97
Keloids, 120
Kidney, 567
adenoma of, 591
congenital, 591
papilliferous cystic, 592
amyloid degeneration of, 588
anemia of, 568
atrophy of, 585
bacteria in, 594
calcification of, 588
carcinoma of, 592
circulatory disturbances of, 568
cloudy swelling of, 586
congenital anomalies of, 567
cyanotic induration of, 569
cysts of, 592
degenerations of, 586
echinococcus-cyst of, 595
edema of, 569
embolism in, 570
fatty contracting, 576
degeneration of, 587
infiltration of, 588
fibromata of, 590
glycogenic infiltration of, 588
hemorrhages in, 569
horseshoe-, 567
hyperemia of, 569
hypertrophy of, 586
inflammation of, 570. See *Nephritis.*
large white, 575
leiomyoma of, 590
lipomata of, 590
lymphomatous infiltrations of, 592
malpositions of, 568
parasites of, 594
parenchymatous degeneration of, 586
pelvis of. See *Pelvis of kidney.*
red granular, 578
rhabdomyosarcoma of, 591
sarcoma of, 591
syphilis of, 590
Kidney, thrombosis in 570
tuberculosis of, 590
tumors of, 590
Klebs-Löffler bacillus, 211
Knock-knee, 700
Kobelt, cysts of, 644
Koch's laws for etiologic importance of bacteria, 30
stain for tubercle-bacillus, 225
tuberculin, 234

LACTIC acid, excessive formation of, in body, 34
Lactosuria, 607
Lacunar tonsillitis, 477
Laennec's cirrhosis of liver, 530
Langhan's cells, 176
Large white kidney, 575
Laryngitis, acute catarrhal, 405
chronic catarrhal, 405
croupous, 406
diphtheritic, 406
edematous, 405
herpetic, 405
Larynx, anatomic considerations of, 404
anemia of, 404
carcinoma of, 402
congenital abnormalities of, 404
echinococcus cysts of, 408
edema of, 404
fibroma of, 407
foreign bodies in, 408
glanders of, 407
hemorrhages in, 404
hyperemia of, 404
inflammation of, 405
lepra of, 407
lupus of, 406
mucous polyps of, 407
papilloma of, 407
parasites of, 408
syphilis of, 406
tuberculosis of, 406
tumors of, 407
Latent tuberculosis, 233
Lateral ventricles of brain, 725
thrombus, 56
Laveran's malarial parasite, 268
Lead, poisoning by, 26
Lecithin in fatty degeneration, 70
infiltration, 67
Leiomyoma, 154
of kidney, 590
of uterus, 632
Leontiasis leprosa, 236
ossium, 691
Lepra, 235. See also *Leprosy.*
affections of nasal cavities in, 403
-cell, 238
gangrænosa, 237
mutilans, 236
of bone, 698
of larynx, 407
of pharynx, 480
of testicle, 669
Leproma, 237
Leprosy, 235. See also *Lepra.*

Leprosy, antitoxin of, 238
anesthetic, 236
bacillus of, 235
etiology of, 235
of liver, 536
of nerves, 809
pathologic anatomy of, 236
physiology of, 238
structure of lesions of, 237
tubercular, 236
Leptomeningitis, 716
spinal, 777
Leucin in urine, 35, 613
Leukemia, 319
acute, 323
blood in, 321
lienomedullary, 322
lymphatic, 322
pathologic physiology of, 323
Leukemic lymphadenoma, 138
Leukocytes, 298
chemical composition of, 302
emigration of, in inflammation, 100
large mononuclear, 299
number of, 302
origin of, 303
pathologic changes in, 305
polynuclear, 300
proportion of different forms of, 302
small mononuclear, 299
transitional, 299
various forms of, 299
Leukocytic casts, 582
Leukocytosis, 310
cachectic, 311
infectious, 310
inflammatory, 310
medicinal, 311
Leukolysis, 312
Leukonuclein, 302
Leukopenia, 312
Leukoplakia, 468
Leydenia gemmipara, 558
Lienomedullary leukemia, 322
Light, effect of, on growth of bacteria, 189
Lipaciduria, 607
Lipemia, 308
Lipoma, 125
appearance of, 125
etiology of, 125
nature of, 126
of bone, 698
of choroid plexus, 763
of dura mater of cord, 776
of Fallopian tubes, 649
of intestines, 516
of kidney, 590
of liver, 536
of lungs, 457
of mammary gland, 679
of mouth, 473
of muscles, 712
of penis, 663
of peritoneum, 557
of pia and arachnoid, 723
of pleura, 465
Lipoma of stomach, 493
of vulva, 660
seats of, 126
structure of, 126
Lipomatosis, 125
of mammary gland, 678
Lipuria, 610
Liquefaction-necrosis, 92
definition of, 92
pathologic anatomy of, 93
Liquid blood-serum as a culture-medium, 190
Liquids of the tissues, alterations of, cause edema, 60
Lithopedion, 651
Liver, 521
abscess of, 529
acute yellow atrophy of, 527
adenoma of, 537
amyloid degeneration of, 528
anatomic considerations, 521
anemia of, 522
angioma of, 536
atrophy of, 524
localized, 525
carcinoma of, 537
secondary, 538
changes of position of, 521
circulatory disturbances of, 522
cirrhosis of, 530
atrophic, 530
biliary, 533
hypertrophic, 532
Laennec's, 530
cloudy swelling of, 526
complete absence of, 521
cyanotic induration of, 522
cysts of, 539
dropsical infiltration of, 528
embolism of, 523
fatty degeneration of, 526
infiltration of, 525
fibromata of, 536
-fluke, 294
gin-drinkers', 530
hyperemia of, 522
hypertrophy of, 534
infectious diseases of, 534
inflammations of, 529
leprosy of, 536
lipomata of, 536
lymphadenoma of, 536
malformations of, 521
myomata of, 536
nutmeg-, 522
parasites of, 539
parenchymatous degeneration of, 526
pigmentation of, 525
red atrophy of, 522
relation of, to diabetes, 39
rupture of, 534
sarcoma of, 536
syphilis of, 534
thrombosis of, 523
tuberculosis of, 534
tumors of, 536
Lobar pneumonia, 425. See *Pneumonia.*

Lobar sclerosis of brain, 758
Lobular pneumonia, 430
Local anemia, 47
  hyperemia, 46
Locomotor ataxia, 793
Löffler's blood-serum, 191
  methylene-blue, 187
Lophotrichous bacteria, 185
Ludwig's angina, 477, 481
Lungs, actinomycosis of, 456
  active hyperemia of, 415
  anatomic considerations, 414
  anemia of, 415
  atrophy of, 419
  carcinoma of, 458
  collateral hyperemia of, 415
  congenital defects of, 415
  congestion of, 415
  cyanotic induration of, 417
  cysts of, 459
  edema of, 417
  embolism of, 419
  emphysema of, 419
  gangrene of, 442
  glanders of, 456
  hemorrhage of, 417
  hemorrhagic infarcts of, 417
  hypostatic congestion of, 416
  hypertrophy of, 419
  inflammation of, 425
  parasites of, 459
  passive hyperemia of, 416
  sarcoma of, 457
  syphilis of, 454
  tuberculosis of, 443
  tumors of, 457
Lupus vulgaris, 233
Lustgarten's bacillus, 254
Luxation of joints, 700
Lymphadenia ossea, 699
  paniciosa, 320
Lymphadenitis, 336
  acute, 336
  chronic, 337
  suppurative, 336
Lymphadenoma, 135, 332, 341
  aleukemic, 138
  appearance and seats of, 135
  etiology of, 135
  leukemic, 138
  nature of, 137
  of liver, 536
  of mouth, 473
  structure of, 137
Lymphangiectasia, 399
  acquired, 400
Lymphangioma, 132
  cavernosum, 132
  of brain, 771
  of mouth, 473
  of spleen, 333
Lymphangitis, 399
  purulent, 442
Lymphatic anemia, 137
  circulation, obstruction of, a cause of edema, 61
  glands, amyloid degeneration of, 334
Lymphatic glands, anatomic considerations, 334
    anthracosis of, 336
    atrophy of, 334
    calcification of, 335
    carcinoma of, 343
    diseases of, 335
    fatty infiltration of, 334
    hyaline degeneration of, 335
    hypertrophy of, 334
    inflammation of, 336
    necrosis of, 335
    pigmentation of, 335
    sarcoma of, 343
    syphilis of, 341
    tuberculosis of, 338
    tumors of, 341
  leukemia, 322
  vessels, anatomic considerations, 399
    dilatation of, 399
    inflammation of, 399
    parasites of, 401
    syphilis of, 400
    tuberculosis of, 400
    tumors of, 400
Lymphemia, 321
Lymph-formation, causes of, 59
Lymphocytes, 299
Lymphogenic tuberculosis, 453
Lymphoid infiltration, 137
  tubercle, 229
Lymphoma, 135
  malignant, 135
Lymphomatous infiltration of kidney, 592
Lymphorrhea, 132
Lymphosarcoma, 135, 143, 332, 341
  of mouth, 473
  of pituitary body, 774
  of stomach, 493
  of thymus gland, 345

Macrocephaly, 728
Macrocheilia, 132, 400, 473
Macroglossia, 132, 400, 473
Madura-foot, 250
Malaria, hematozoön of, 267
  irregular, parasite of, 268
Malarial hematozoa, 267
  parasites, 267
    staining of, 326
Male breast, abnormal development of, 676
Malignant edema, 240
    bacillus of, 240
  endocarditis, 354
  lymphoma, 135
  pustule, 242
Mallein, 240
Malta fever, 264
    micrococcus of, 264
Malum coxæ senilis, 702
Mamma. See *Mammary gland.*
Mammary gland, 676
    adenoma of, 680
    atrophy of, 678
    carcinoma of, 680
    chondroma of, 680

Mammary gland, congenital abnormalities of, 676
cysts of, 682
fatty infiltration of, 678
fibroma of, 679
hemorrhages of, 677
hyperemia of, 676
hypertrophy of, 678
inflammation of, 677
lipoma of, 679
lipomatosis of, 678
myoma of, 680
myxoma of, 680
myxomatous degeneration of, 678
osteoma of, 680
sarcoma of, 680
supernumerary, 676
syphilis of, 678
tuberculosis of, 678
tumors of, 679
Marantic thrombi, 55
Margarin-crystals in fatty infiltration, 67
Marrow-cells, 343
Massive cerebral hemorrhage, 748
Mast-cells, 300
Mast-cell granules, 301
Mastitis, acute, 677
chronic, 677
Measles, animal parasites of, 274
bacteriology of, 261
Mechanical agents as causes of necrosis, 90
Meckel's diverticulum, 498
Medicinal leukocytosis, 311
Mediterranean fever, 264
Medullary carcinoma, 172
infiltration of lymphoid structures of intestine, 512
Megaloblasts, 304
Megalocytes, 303
Megastoma entericum, 276
Melæna neonatorum, 486
Melanemia, 308
Melanin, pigmentation by, 85
Melanosarcoma, 145
Melanuria, 608
Membranes of brain, diseases of, 713
of spinal cord, 775
Meningitis, epidemic cerebrospinal, 718
tuberculous, 719
Meningocele, 728
Menorrhagia, 51, 624
Menstruation, 623
Mercury, poisoning by, 26
Mesarteritis, 383
Mesencephalon, 724
Mesophilic bacteria, 189
Metabolic pigmentation, 88
Metabolism, disorders of, 31
in diabetes, 39
Metachromatic bodies, 184
Metaplasia, 113
Metastatic abscesses, production of, 54
Methemoglobin in urine, 613
Metritis, 624
acute, 627
chronic, 628
Metrorrhagia, 51, 624
Metschnikow's theory of phagocytosis, 198
Miasmatic disease, definition of, 30
Microblasts, 304
Microcephaly, 729
Micrococcus, 183
exanthematicus, 262
Maltensis, 264
tetragenus, 205
ureæ in urine, 610
Microcytes, 303
Micromyelia, 780
Microspira, 183
Migula's classification of bacteria, 183
Miliary aneurysm, 390
of brain, 744
of spinal cord, 785
tubercles, 227, 232
Milk as a culture-medium, 190
-spots, 378
Miner's elbow, 706
Mixed tumors, 129, 149
Moist gangrene, 96
Moles, fleshy, 656
hydatid, 658
Molluscum-bodies, 273
contagiosum, animal parasites of, 272
Mononuclear leukocytes, 299
Monostoma lentis, 296
Monotrichous bacteria, 185
Morbid anatomy, definition of, 17
Morbus cæruleus, 348
Morphin, poisoning by, 29
Mother-wreath, 111
Mouth, anemia of, 467
circulatory disturbances of, 467
congenital abnormalities of, 467
hemorrhages of, 468
hyperemia of, 467
inflammation of, 468
syphilis of, 472
tuberculosis of, 471
tumors of, 473
Movable spleen, 327
Mucin, hypersecretion of, distinguished from mucoid degeneration, 76
nature of, 76
staining of, 77
Mucoid degeneration, 76. See *Degeneration.*
of bone-marrow, 343
Mucopurulent catarrh, 105
cystitis, 601
Mucous colitis, 509
patch, 256, 257
polyps of larynx, 407
Mulberry calculi, 603
Multiple sclerosis of brain, 759
Multipolar karyokinesis, 97
Mumps, 481
bacteriology of, 261
Mural endocarditis, 352
fibroids, 632
Muscarin, poisoning by, 29
Muscles, actinomycosis of, 712
amyloid degeneration of, 711

Muscles, anemia of, 707
anthrax of, 712
atrophy and degeneration of, 709
calcification of, 711
carcinoma of, 713
chondroma of, 712
coagulation-necrosis of, 711
congenital malformations, 706
diseases of, 706
embolism of, 707
fatty degeneration of, 711
infiltration of, 711
fibromata of, 712
glanders of, 712
hemorrhages of, 707
hyaline degeneration of, 711
hyperemia of, 707
hypertrophy of, 706
inflammation of, 707. See *Myositis.*
lipomata of, 712
myxomata of, 712
osteoma of, 712
parasitic diseases of, 713
parenchymatous degeneration of, 711
rhabdomyomata of, 712
sarcoma of, 712
syphilis of, 712
thrombosis of, 707
tuberculosis of, 712
tumors of, 712
Muscular atrophy, myopathic, 710
neuropathic, 709
progressive, 710
pseudohypertrophic, 711
simple, 711
Mycetoma, 250
Mycophylaxins, 201
Mycoprotein, 186
Mycosis aspergillina, 413
fungoides, 149
Mycosozins, 201
Mycotic endocarditis, 354
Mydalein, poisoning by, 29
Mydatoxin, poisoning by, 29
Myelinic neuroma, 154
Myelitis, 787
hematogenous purulent, 788
pressure-, 790
secondary to purulent leptomeningitis, 788
transverse, secondary to injury or infectious disease, 789
Myelocytes, 300
Myelogenous callus, 686
osteosarcoma, 148
Myeloid sarcoma, 147
Myeloma, 699
Myelomeningocele, 781
Myiasis, 296, 297
Myocardite ségmentaire, 364
Myocarditis, 364
acute, 364
circumscribed, 364
diffuse, 365
chronic, 367
Myofibroma of ovary, 640
of uterus, 632
Myofibroma of vagina, 654
of vulva, 660
Myoma cavernosum, 155
cysticum, 155
lævicellulare, 154
of bladder, 605
of liver, 536
of mammary gland, 680
of stomach, 493
of uterus, 155
striocellulare, 157
Myomalacia, 374
cordis, 351
Myoneuroma of pituitary body, 774
Myopathic muscular atrophy, 710
Myositis, 707
chronic, 708
productive, 709
suppurative, 708
disseminated acute, 708
hemorrhagic, 707
localized acute, 707
ossificans progressiva, 709
ossifying, 709
serous, 707
suppurative, 708
Myxedema, 563
Myxoid cystomata of ovaries, 640
Myxoma, 124
appearance of, 124
definition of, 124
etiology, 124
nature of, 125
of bladder, 605
of bone, 698
of dura mater of cord, 776
of intestines, 516, 518
of mammary gland, 680
of mouth, 473
of muscles, 712
of testicle, 669
seats of, 124
structure of, 124
Myxomatous degeneration of mammary gland, 678
of testicle, 664

Nævus lymphaticus, 132
prominens, 133
Nasal catarrh, acute, 402
cavities, active congestion of, 402
anatomic considerations, 402
congenital abnormalities of, 402
edema of, 402
hemorrhage of, 402
inflammations of, 402
parasites of, 404
passive congestion of, 402
syphilis of, 403
tuberculosis of, 403
tumors of, 403
Natural immunity, 197
Necrobiosis, 89
Necrosis, 89
cellular, general pathology of, 97
coagulation-, 91
definition of, 89

Necrosis, etiology of, 89
fat-, 94
of pancreas, 547
liquefaction-, 92
of bone, 693
of lymphatic glands, 335
of pancreas, 547
Necrotic appendicitis, 507
inflammation, 109
Negative chemotaxis, 100
Neisser, gonococcus of, 206
Nematodes, 286
Neoplasms, 115. See *Tumors.*
Nephritis, 570, 573
acute catarrhal, 572
degenerative, 572
desquamative, 572
diffuse, 573
hemorrhagic, 573
inflammatory lesions from, 584
interstitial, 573
parenchymatous, 572
arteriosclerosis from, 584
arteriosclerotic, 578
cardiac changes from, 584
chronic, 575
hemorrhagic, 575
interstitial, 577
diffuse, 571
edema or dropsy from, 585
embolic suppurative, 574
etiology of, 571
gouty, 578
interstitial, 571
parenchymatous, 571
chronic, 575
pathologic anatomy of, 571
physiology of, 580
results of, 584
secondary interstitial, 576
suppurative, 574
tube-casts in, 581
uremia from, 585
urine in, 581
Nerve-cell, anatomy of, 732
changes in nuclei of, 736
degenerative changes in, as a whole, 737
processes of, 732
Nissl's method of staining, 733
pathologic changes in, 732
pigmentation of, 736
vacuolization of, 735
Nerve-fibers, anatomy of, 737
degeneration of, 738
Nerve-poisons, 29
Nerves, 803
atrophy of, 803
degeneration of, 804
edema of, 803
hemorrhages into, 803
hyperemia of, 803
inflammation of, 806. See also *Neuritis.*
leprosy of, 809
muscular fibers in, 809
regeneration of, 804
Nerves, sarcoma of, 809
syphilis of, 808
tuberculosis of, 808
tumors of, 809
Nervous system, central, injuries of, 760
general pathologic anatomy of, 732
influence of, in causation of edema, 61
Neurin, poisoning by, 29
Neuritis, 806
acute interstitial, 806
chronic hypertrophic interstitial, 808
chronic interstitial, 807
parenchymatous, 808
suppurative, 808
Neuroblasts, 724
Neuroglia, degeneration of, 739
Neuroglioma, ganglionar, 769
Neuroma, 154
amyelinic, 154
false, 154
myelinic, 154
of suprarenal bodies, 566
plexiform, 154
true, 154
Neuron, description of, 726
Neuroparalytic hyperemia, 46
Neuropathic arthritis, 703
hemorrhage, 50
muscular atrophy, 709
Neurotic hyperemia, 46
Neutrophiles, 300
Neutrophilic granules, 301
New-growths, 115. See *Tumors.*
Nigrities of tongue, 471
Nissl's method of staining nerve-cells, 733
Nitrate of silver, poisoning by, 24
Nitric acid, poisoning by, 24
Nitrifying ferments, 193
Nitrobenzol, poisoning by, 28
Nitroglycerin, poisoning by, 28
Nodes of Ranvier, 738
Noma, 469
Non-contagious disease, definition of, 30
Non-siderous pigments, 85
Normoblasts, 304
Nourishment, insufficient, effect of, 31
Nuclear solution, 97
Nuclei of cells, degenerations of, 97
of nerve-cells, morbid changes in, 736
Nucleo-albuminuria, 609
Numerical atrophy, 62
hypertrophy, 114
Nutmeg-liver, 522
Nutrition, disorders of, 31

OBESITAS cordis, 361
Obesity, 32
associated conditions, 33
causes of, 32
pathologic anatomy of, 33
Obligate saprophytes and parasites, 189
Obstruction, intestinal, 500
of bronchi, 412
Obstructive thrombus, 56
Odontinoids, 474

Odontoma, 131, 474
Œdema ex vacuo, 60
Oligemia, 307
Oligochromemia, 313
Oligocythemia, 313
Omentum, dropsy of, 552
Oöphoritis, 639
  chronic, 639
Optic thalami, 726
Orchitis, 664
  acute, 665
  chronic, 665
Organic poisons, 25
Ose, 191
Osmosis, escape of fluid by, 59
Ossification, 83
  differentiation of, from calcification, 83
Ossifying myositis, 709
  pachymeningitis, 714
  periostitis, 689
Osteitis, 689
  chronic, 690
  condensing, 691
Osteo-arthropathy, hypertrophic, 689
Osteoblasts, 111
Osteochondroma, 129
Osteoclasts, 691
Osteoid chondroma, 129
  sarcoma, 699
Osteoma, 130
  appearance of, 130
  definition of, 130
  dental, 131
  durum, 131
  eburneum, 131
  etiology of, 130
  heteroplastic, 131
  nature of, 132
  of brain, 771
  of lungs, 457
  of mammary gland, 680
  of muscles, 712
  of pleura, 465
  of testicle, 669
  seats of, 131
  spongiosum, 131
  structure of, 131
Osteomalacia, 693
Osteomyelitis, 344, 689
Osteophytes, 130
Osteoporosis, inflammatory, 691
Osteopsathyrosis, 692
Osteosarcoma, 147
  myeloid, 148
Osteosclerosis, 691
Ovaries, 637
  absence of, 638
  active hyperemia of, 638
  adenocystoma of, 640
  carcinomata of, 643
  chondromata of, 640
  congenital abnormalities of, 638
  congestion of, 638
  cysto-adenoma of, 640
  cystoma of papillary, 641
  cystomata of, colloid, 640
Ovaries, cystomata of, glandular, 640
    myxoid, 640
  dermoid cysts of, 642
  development and anatomic considerations, 637
  dislocation of, 638
  fibroma of, 640
  fibrosarcomata of, 640
  follicular cysts of, 640
  hemorrhages into, 638
  hypoplasia of, 638
  inflammation of, 639
  myofibromata of, 640
  passive congestion of, 638
  sarcoma of, 640
  supernumerary, 638
  tuberculosis of, 639
  tumors of, 640
Overaction of heart, effect of, on circulation, 45
Overfeeding, effect of, 32
Oviducts. See *Fallopian tubes.*
Oxalate of lime in urine, 611
Oxalic acid, poisoning by, 24
Oxaluria, 40
Oxidizing ferments, 193
Oxyphile granules, 300
Oxyuris vermicularis, 287, 520
Ozena, 403
Ozœna syphilitica, 403. See *Tuberculosa.*

PACCHIONIAN bodies, 721
Pachydermia laryngis, 405
Pachymeningitis, 713
  cervicalis, 776
  external tuberculous, of cord, 775
  hemorrhagic, 713
  internal hemorrhagic, of cord, 776
  ossifying, 714
  productive, 714
  suppurative, 714
Pancreas, 546
  amyloid degeneration of, 547
  atrophy of, 546
  carcinoma of, 549
  circulatory disturbances of, 546
  cirrhosis of, 548
  congenital abnormalities of, 546
  cysts of, 549
  fat-necrosis of, 547
  hematochromatosis of, 547
  hemorrhage in, 546
  hyperemia of, 546
  inflammation of, 548
  necrosis of, 547
  parenchymatous degeneration of, 547
  pigmentation of, 547
  relation of, to diabetes, 39
  sarcoma of, 549
  syphilis of, 549
  tuberculosis of, 549
  tumors of, 549
Pancreatic calculi, 550
  duct, 550
    dilatation of, 550
    obstruction of, 550
  veins, 550

Pancreatitis, 548
acute hemorrhagic, 548
suppurative, 548
chronic indurative, 548
necrotic, 548
Papillary cystoma of ovary, 641
tumors, 118
Papilliferous cystic adenoma of kidney, 592
cystoma of testicle, 670
cystomata, 178
Papilloma, 157
hard, 158
of bladder, 604
of Fallopian tubes, 649
of intestines, 516
of larynx, 407
of mouth, 473
of penis, 662
of vagina, 654
soft, 158
Papillomatous tumors of vulva, 660
Parachromophoric bacteria, 195
Paradoxic embolism, 52
Paralysis, general progressive, 757
Paramecium coli, 276
Parametritis, 624
Paraphimosis, 661
Parasites, 188
animal, 265
embolism by, 52
in etiology of disease, 31
of blood, 324
of bone, 699
of bronchi, 413
of heart, 375
of intestine, 519
of kidney, 594
of larynx, 408
of liver, 539
of lungs, 459
of lymphatic vessels, 401
of nasal cavities, 404
of pericardium, 380
of peritoneum, 558
of pleura, 467
of spleen, 333
of thyroid gland, 562
of ureter, 598
of uterus, 637
Parasitic disease, definition of, 31
stomatitis, 471
theory as to origin of carcinoma, 164
Parenchyma-poisons, 25
Parenchymatous encephalitis, 753
glossitis, 471
goiter, 560
degeneration, 64. See *Cloudy swelling.*
of heart, 359
of kidney, 586
of liver, 526
of muscles, 711
of pancreas, 547
hemorrhage, 48
hepatitis, 529
inflammation, 106
nephritis, 571
Parenchymatous nephritis, acute, 572
chronic, 575
neuritis, 808
tissue, regeneration of, 112
Paroöphoron, 638
Parotitis, 481
Parovarium, 638
cysts of, 643
Paroxysmal hemoglobinuria, 609
Passive hyperemia, 46
immunity, 197
Pathologic anatomy, definition of, 17
chemistry, definition of, 17
Pathology, definition of, 17
general, 17
special, 298
Patulous, ductus Botalli, 348
Pearl disease, 230
Pelvis of kidney, 595
calculus in, 596
inflammation of, 596
malformations of, 595
tuberculosis of, 597
tumors of, 598
Penis, 661
angioma of, 663
carcinoma of, 662
condyloma acuminatum, 662
congenital abnormalities of, 661
cysts of, 662
epithelioma of, 662
fibroma of, 663
inflammation of, 661
injuries of, 663
lipoma of, 663
papilloma of, 662
tuberculosis of, 662
tumors of, 662
Pentastomum denticulatum, 296, 297, 539
tænioides, 297
Peptic ulcer of intestine, 505
of stomach, 489
Peptone, formation of, 35
poisoning by, 28
solution, 190
Peptonuria, 35
Perforative peritonitis, 554
Periangiocolitis, 533
Periarteritis, 383
nodosa, 384
Peribronchial fibrous pneumonia, 439
Peribronchitis, 412
Pericarditis, 376
associated conditions of, 379
dry, 376
fibrinous, 376
hemorrhagic, 378
interna et externa, 380
purulent, 378
serofibrinous, 377
terminations of, 378
Pericardium, 346, 375, 378
actinomycosis of, 380
hemorrhages in, 376
hyperemia of, 376
inflammation of, 376

Pericardium, parasites of, 380
syphilis of, 380
tuberculosis of, 380
tumors of, 380
Perichondritis of larynx, 405
Perihepatitis, 533
hyperplastic, 556
Perilymphangitis, 442
Perimastitis, 677
Perimetritis, 624
Perinephritis, 570
Peri-orchitis, 666
prolifera, 666
Periosteal callus, 686
Periostitis, 688
ossifying, 689
purulent, 689
simple, 688
syphilitic, 697
Peripheral nervous system, 802
Periproctitis, 509
Periprostatitis, 671
Perisplenitis cartilaginea, 331
Perithelioma, 770
Peritoneum, 551
carcinoma of, 557
circulatory disturbances of, 551
congenital abnormalities of, 551
dropsy of, 552
echinococcus cysts of, 558
fibromata of, 557
hemorrhage of, 551
hyperemia of, 551
inflammation of, 553. See *Peritonitis.*
lipomata of, 557
parasites of, 558
sarcoma of, 557
tuberculosis of, 556
tumors of, 557
Peritonitis, 553
acute general, 555
localized, 554
chronic, 555
hemorrhagic, 555
idiopathic, 553
micro-organisms of, 554
perforative, 554
Peritrichous bacteria, 185
Perityphlitic abscess, 508
Perityphlitis, 508
Periurethral abscess, 615
Perivascular fibrous pneumonia, 439
Pes calcaneus, 700
equinus, 700
valgus, 700
varus, 700
Petechia, definition of, 51
Petri's dishes, 191
Phagedenic ulcer, 105
ulceration of cervix uteri, 627
Phagocytes, 198
Phagocytosis, 198
Phagolysis, 199
Pharyngitis, catarrhal, 475
chronic catarrhal, 475
phlegmonous, 476
pseudomembranous, 476
Pharyngomycosis leptothricia, 480
Pharynx, anemia of, 475
diphtheria of, 479
edema of, 475
glanders of, 480
hemorrhages of, 475
hyperemia of, 475
inflammation of, 475
lepra of, 480
pressure-necrosis of, 478
syphilis of, 480
tuberculosis of, 480
tumors of, 480
Phimosis, 661
Phlebectasia, 397
Phlebectatic elephantiasis, 398
Phlebitis, 396
acute, 396
chronic, 396
Phleboliths, 58, 396
Phlebosclerosis, 396
Phlegmonous cystitis, 601
esophagitis, 483
inflammation of vulva, 659
pharyngitis, 476
stomatitis, 469
tonsillitis, 477. 478
Phlogogenic bacterial proteins, 192
Phloridzin-glycosuria, 38
Phosphates in urine, 611
Phosphatic calculi, 603
Phosphaturia, 40
Phosphoric acid, excessive formation of, in body, 34, 39
Phosphorus, poisonous action of, 25
Photogenesis, 195
Phragmodiothrix, 183
Phthisis, fibroid, 449
Phylaxins, 201
Physometra, 622
Pia mater, cerebral, 715
anemia of, 715
cholesteatomata of, 722
edema of, 716
endothelioma of, 722
hemorrhages of, 715
hyperemia of, 715
inflammation of, 716
lipoma of, 723
syphilis of, 721
teratomata of, 723
spinal, 777
calcareous infiltration of, 777
hyperemia of, 777
inflammation of, 777
syphilis of, 778
tuberculosis of, 778
Pigment-building cells, 88
Pigment-metastases, 86
Pigmentation, 83
by cutaneous absorption, 85
by foreign bodies, 83
by hemoglobin derivatives, 85
by salts of silver, 85
from the exterior, 83
hematogenous, 85
hepatogenous, 87

Pigmentation, metabolic, 88
of bone-marrow, 343
of choroid plexus, 763
of intestines, 502
of liver, 525
of lymphatic glands, 335
of mucosa of stomach, 491
of nerve-cell, 736
of pancreas, 547
of red blood-corpuscle, 305
of spinal pia, 777
of spleen, 332
of suprarenal bodies, 565
Pigmented sarcoma, 146
Pineal gland, 726, 775
Pin-worm, 287
Pituitary body, 771
adenoma of, 774
amyloid degeneration of, 773
colloid degeneration of, 773
cysts of, 774
hemorrhage into, 773
hyperemia of, 773
hypertrophy of, 772
inflammation of, 773
lymphosarcoma of, 774
relation of, to acromegaly, 774
sarcoma of, 774
softening of, 773
syphilis of, 773
tuberculosis of, 773
tumors of, 773
Placenta, 654
abnormal development of, 655
hemorrhage into, 656
inflammation of, 656
prævia, 655
succenturiata, 655
syphilis of, 657
tuberculosis of, 657
Placental infarcts, 656
polyps, 657
Placentitis, 656
Planococcus, 183
Planosarcina, 183
Plaques jaunes, 753
Plasma of blood, 382
Plasmodia, 267
Plehn's solution, 326
Plethora, 306
apocoptica, 307
hydremica, 307
vera, 306
Pleura, 460
circulatory disturbances of, 460
inflammation of, 461
parasites of, 467
passive hyperemia of, 460
petechial hemorrhages of, 460
syphilis of, 465
tuberculosis of, 465
tumors of, 465
Pleurisy, 461. See *Pleuritis.*
bread-and-butter, 463
Pleuritis, 461
fibrinous, 462
hemorrhagic, 464
Pleuritis, purulent, 463
serofibrinous, 463
Pleurogenic fibrous pneumonia, 439
pneumonia, 425
purulent pneumonia, 442
Plexiform angiosarcoma, 144
neuroma, 154
Pneumaturia, 608
Pneumonia, 425
alba, 440, 454
aspiration-, 431, 434
catarrhal, 430
bacteria of, 210
cheesy, 435
congenital syphilitic, 440
croupous, 425. See *Pneumonia, fibrinous.*
bacteriology of, 207
deglutition-, 431
desiccans, 442
fibrinous, 425
associated lesions in, 429
etiology of, 425
pathologic anatomy of, 426
physiology of, 429
stage of congestion or engorgement, 426
stage of consolidation or hepatization, 427
stage of resolution in, 428
usual characters of, 428
usual terminations of, 429
fibrous, 437
peribronchial, 439
perivascular, 439
pleurogenic, 439
secondary, 439
hematogenic, 425
hypostatic, 431, 434
irregular, 210
lobar, 425. See *Pneumonia, fibrinous.*
lobular, 430
migrans, 426
pleurogenic, 425
productive, 437
purulent, 440
bronchogenic, 440
hematogenic, 441
pleurogenic, 442
tubercular, 210
tuberculous, 435
Pneumonic tuberculosis, 445
Pneumonokoniosis, 83, 437
Pneumonomycosis aspergillina, 460
Pneumopericardium, 380
Pneumopyopericardium, 381
Pneumothorax, 461
Poikilocytosis, 303
Poisons, action of, in general, 23
blood-, 28
classification of, 24
corrosive, 24
effect of, 23
elimination of, 24
fate of, after ingestion, 23
immunity to, 23, 24
in etiology of disease, 23

Poisons, necrosis from, 90
nerve-, 29
organic, 25
parenchyma-, 25
Polar spore, 184
field, 111
Poliomyelitis, acute anterior, 791
chronic anterior, 799
Polycholia, 545
Polychromatophilia, 305
Polycythemia, 310
Polymastia, 676
Polymorphonuclear leukocytes, 300
Polymorphous heredity, 36
Polymyositis, 708
secondary acute, 711
Polyneuritis, 808
Polynuclear leukocytes, 300
Polypoid elevations of stomach, 493
growths of bladder, 604
outgrowths from tooth-pulp, 474
tumors, 118
Polyps, nasal, 403
placental, 657
of uterus, 632
sarcomatous, 634
Polyuria, 606
Pons, anatomy of, 726
Porencephaly, 741
Portal vein, embolism and thrombosis of, 523
Port-wine stains, 133
Posterior sclerosis of spinal cord, 793
Posthitis, 661
Post-mortem lividity, 44
Potassium chlorate, poisoning by, 28
Potato-extract, 190
Predisposing causes of disease, 18
Predisposition to disease, 18
Pregnancy, abdominal, 652
extra-uterine, 650
interstitial, 650
tubal, 650
Prepuce, concretions under, 663
inflammation of, 661
Pressure, effect of, on tissues, 19
-myelitis, 790
-necrosis of pharynx, 478
Primary anemias, 315
gangrene, 95
thrombus, 56
Processes of nerve-cell, degenerative changes in, 732
Proctitis, 509
Productive inflammation, 105
myositis, chronic, 709
pachymeningitis, 714
pneumonia, 437
Proglottides of tape-worms, 278
Progressive muscular atrophy, 710
pernicious anemia, 317
spinal muscular atrophy, 799
tissue-changes, 113
Projection fibers of brain, 725
Prolapse of rectum, 502
of uterus, 620
of vaginal walls, 652
Proliferation-cysts, 177
Proliferative cystomata, 178
Prosencephalon, 724
Prostate gland, 671
abscess of, 671
atrophy of, 672
carcinoma of, 675
concretions in, 672
cysts of, 675
fatty degeneration of, 672
hypertrophy of, 672
inflammation of, 671
sarcoma of, 675
tuberculosis of, 672
Prostatitis, 671
phlegmonous, 671
simple, 671
suppurative, 671
Proteins produced by bacteria, 192
Proteolytic ferments, 193
Protozoa, 265
Psammoma, 82, 149, 771
-bodies, 81, 641
Pseudarthroses, 687
Pseudodichotomy of bacteria, 186
Pseudodiphtheria bacillus, 212
Pseudohypertrophic muscular atrophy, 711
Pseudoleukemia, 137, 323
cutis, 150
infantum, 323
Pseudomembranous cystitis, 602
enteritis, 505
esophagitis, 482
gastritis, 486
pharyngitis, 476
stomatitis, 469
vaginitis, 653
Pseudomonas, 183
Pseudomucin, 77
Pseudoplasms, 115. See *Tumors*.
Pseudotrichinosis, 708
Pseudotuberculosis, 234
Psorospermiæ, 269
in liver, 539
in pelvis of kidney, 598
Psychrophilic bacteria, 189
Ptomains, poisoning by, 29
Puerperal infections of uterus, 628
etiology of, 628
pathologic anatomy of, 629
Pulmonary artery, stenosis and atresia of, 347
infarcts, 54
Pulsion-diverticula of esophagus, 483
Punctate cerebral hemorrhage, 747
Purulent arthritis, 702
lymphangitis, 442
myelitis, hematogenous, 788
pericarditis, 378
periostitis, 689
pleuritis, 463
pneumonia, 440
vaginitis testis, 667
Pustule, malignant, 242
Putrefaction, 193
Pyelitis, 570, 596

Pyelonephritis, 597
suppurative, 574
Pyemia, 197
Pyknomorphous state, 734
Pyknosis, 97
Pylephlebitis, 524
Pyogenic albumosuria, 608
bacterial proteins, 192
membrane, 105
Pyoid marrow, 344
Pyonephrosis, 597
Pyosalpinx, 648
Pyothorax, 463
Pyramidal tract, degeneration of, 750

QUARTAN malaria, organism of, 267
Quinsy, 478

RABIES, bacteriology of, 262
Racemose adenoma, 160
cysticerci, 279
Rachitic rosary, 684
Rachitis, 683
Ranula, 473
Ranulæ, 177
Ray fungus, 248
Rectocele, 621
vaginal, 652
Rectum, inflammation of, 509
prolapse of, 502
Recurrent fibroid tumor, 141
Recurring appendicitis, 508
Red atrophy of liver, 522
blood-corpuscles, 298. See *Blood-corpuscle.*
nucleated, 304
granular kidney, 578
hepatization of lung, 427
softening of brain, 751
Reducible hernia, 500
Regeneration, 109
normal, 109, 110
of bone, 685
of connective tissues other than fibrous, 112
of fibrous connective tissues, 111
of nerves, 804
of parenchymatous tissue, 112
pathologic, 110, 111
Relapsing appendicitis, 508
fever, 251
Relative immunity, 197
Remote heredity, 18
Renal calculi, 596
"rests," 564
sand, 596
Repair of wounds, 106
Reproductive organs, diseases of, 618
Resolution after inflammation, 109
Respiratory system, diseases of, 402
Retention-cysts, 177
Retroflexion of uterus, 620
Retrograde embolism, 52
Retrogressive processes, 62
Retroperitoneal hernia, 499
Retropharyngeal abscess, 476
Retro-uterine hematocele, 624
Rhabditis stercoralis, 290
Rhabdomyoma, 157
of muscles, 712
of testicle, 669
Rhabdomyosarcoma of kidney, 591
Rhachischisis, 728
Rheumatism, bacteriology of, 263
Rheumatoid arthritis, 702
Rhinitis, acute, 402
atrophica, 403
chronic, 403
diphtheritic, 403
Rhinoliths, 404
Rhinoscleroma, 210
affections of nasal cavities in, 403
Rhopalocephalus carcinomatosus, 272
Rice-water stools of cholera, 511
Ricin, poisoning by, 27
Rickets, 683
congenital, 685
Round-cell infiltration, 101
-celled sarcoma, 142
ulcer of stomach, 489
worms, 286
Rubeola, 261. See *Measles.*
Rupture of bladder, 600
of intestines, 520
of liver, 534
of uterus, 623

SACCHAROMYCES albicans, 471
Saccular aneurysm, 391
bronchiectasis, 413
Sago spleen, 332
Salivary ducts, concretions in, 482
cystic dilatation of, 482
diseases of, 481
fistulæ, 481
glands, inflammation of, 481
tumors of, 481
Salpingitis, 646
acute, 646
chronic, 648
diphtheritic, 647
Sanarelli's bacillus, 260
Sapremia, 197
Saprophytes, 188
Sarcina, 183
Sarcinæ ventriculi, 493
Sarcolactic acid, excessive formation of, in body, 34
Sarcoma, 138
alveolar, 143
appearances of, 139
blood-vessels of, 140
giant-celled, 147
myeloid, 147
of bone, 698
of brain, 770
of cervix uteri, 634
of dura mater of cord, 776
of Fallopian tubes, 650
of intestines, 516
of kidney, 591
of liver, 536
of lungs, 457
of lymphatic glands, 343

Sarcoma of mammary gland, 680
of mouth, 473
of muscles, 712
of nerve, 809
of ovaries, 640
of pancreas, 549
of peritoneum, 557
of pituitary body, 774
of pleura, 465
of prostate, 675
of spinal cord, 802
of spleen, 333
of stomach, 493
of suprarenal bodies, 566
of testicle, 669
of thymus gland, 345
of thyroid gland, 562
of tooth-pulp, 474
of urethra, 618
of uterus, 634
of vagina, 654
of vulva, 660
osteoid, 699
pigmented, 146
round-celled, 142
seats of, 140
spindle-celled, 141
Sarcomatosis, 140
Sarcomatous cylindromata, 145
polyps of uterus, 634
Scarlatina. See *Scarlet fever*.
Scarlet fever, animal parasites of, 274
bacterium of, 261
Scirrhous carcinoma, 172
Sclerosis of brain, atrophic, 740
diffuse, 739
disseminated, 739
hypertrophic, 740
lobar, 758
multiple, 759
of spinal cord, amyotrophic lateral, 798
combined, 798
posterior, 793
Scolex of tape-worm, 278
Scrofula, 339
Scrotum, 661
cysts of, 662
elephantiasis of, 662
epithelioma of, 662
Seat-worm, 287
Secondary anemia, 313
gangrene, 95
thrombus, 56
Segmentation, indirect, 110
of fibers of heart, 363
Seminal vesicles, 675
diseases of, 676
Senile arthritis, 702
atrophy of uterus, 631
emphysema of lungs, 422
Septicemia, 197
Septic endocarditis, 354
Sequestrum, 693
Serofibrinous pericarditis, 377
pleuritis, 463
Serous arthritis, 702
Serous inflammation, 103
myositis, 707
vaginitis testis, 666
Serpents, venom of, poisoning by, 27
Serpiginous ulcer, 105
Serum-reaction of Widal, 217
Serumuria, 608
Shadow corpuscles, 305
"Shaven-beard" appearance, 513
Siderosis, 83, 439
Siderous pigments, 85
Silver-salts, pigmentation by, 85
Slumbering cells of Grawitz, 101
Soft chancre, 259
papilloma, 158
Softening-cysts, 177
Sozins, 201
Special pathology, 298
definition of, 17
Spermatocele, 670
Sphacelinic acid, 26
Sphacelus, 97
Spina bifida, 781
Spinal cord, 775
abnormal smallness of, 780
anatomy of, 778
anemia of, 785
aneurysms of, 785
blood-vessels of, degeneration of walls of, 785
carcinoma of, 802
cysts of, 802
degenerations of, secondary, 800
development of, 723
double, 780
glioma of, 802
hyperemia of, 785
inflammations of, 787
primary degenerations of, 793
sarcoma of, 802
sclerosis of, amyotrophic lateral, 798
combined, 798
posterior, 793
total absence of, 780
tumors of, 802
unusual length of, 780
varicose veins of, 786
white matter of, degeneration of, 799
ganglia, disease of, 803
Spindle-celled sarcoma, 141
-shaped aneurysm, 390
Spirillaceæ, 183
Spirillum, 183
Berolinensis, 223
choleræ Asiaticæ, 219
pathogenicity of, 221
Metschnikowi, 222
of Finkler and Prior, 222
tyrogenicum, 222
Spirochæta, 183
Obemeieri, 251
Spirosoma, 183
Splanchnoptosis, 492
Spleen, abnormal development and situation of, 327
abscess of, 330
amyloid degeneration of, 331

Spleen, anemia of, 328
atrophy of, 331
calcification of, 332
carcinoma of, 333
chronic hyperplasia of, 331
inflammation of, 331
circulatory disturbances in, 328
congestion of, 328
cysts of, 333
embolism of, 328
hemorrhages in, 328
hyaline degeneration of, 332
hyperemia of, 328
infectious diseases of, 333
inflammation of, 329
movable, 327
pathologic physiology of, 327
pigmentation of, 332
sarcoma of, 333
syphilis of, 334
thrombosis of, 329
tuberculosis of, 333
tumors of, 332
Splenemia, 321
Splenic anemia, 315
fever, 242
stones, 329
Splenitis, 329
circumscribed, 330
diffuse, 329
spodogenous, 332
Splenization of lung-tissue, 417, 424
Spodogenous splenitis, 332
Spongioblasts, 723
Spores of bacteria, 184
staining of, 188
Squamous cancer of stomach, 497
epithelioma, 171
Staining of bacteria, 186–188
of blood, 325
Staphylococcus epidermidis albus, 203
pyogenes albus, 203
aureus, 202
citreus, 203
Starvation, 31
Stasis of blood, 47
Staubzellen, 437
Stenosis of biliary ducts, 542
of esophagus, 483
of Fallopian tubes, 645
of heart-valves, 357
of intestines, 498
of uterus, 622
of vagina, 652
Stercoral typhlitis, 506
Stomach, adenocarcinoma of, 497
adenomatous proliferation of glands of, 494
alteration in position of, 492
amyloid degeneration of submucosa of, 492
anemia of, 485
anthrax of, 493
atrophy of, 491
calcification of mucosa of, 492
cancer of, 494
carcinoma of, 494
Stomach, circulatory disturbances of, 485
colloid cancer of, 497
congenital defects of, 485
cylindrical cancer of, 497
degeneration of mucous membrane of, 491
dilatation of, 492
atonic, 492
displacements of, 492
fatty degeneration of cells of, 491
hemorrhage of, 485
hyperemia of, 485
infectious diseases of, 493
inflammation of, 504
of mucosa of, 486
malignant adenoma of, 497
peptic ulcer of, 489
pigmentation of mucosa of, 491
polypoid elevations of, 493
round ulcer of, 489
softening of walls of, 492
squamous cancer of, 497
syphilitic gummata of, 493
thrush of, 493
tuberculous ulceration of, 493
tumors of, 493
Stomatitis, 468
aphthous, 468
associated conditions in, 470
catarrhal, 468
gangrenous, 469
parasitic, 471
phlegmonous, 469
pseudomembranous, 469
ulcerative, 469
Stone-particles, pigmentation by, 83
Strangulated hernia, 500
Strangulation, internal, of intestines, 500
Stratified thrombi, 56
Streptococci in kidney, 595
Streptococcus, 183
pyogenes seu erysipelatis, 203
-toxin, 205
Streptothrix, 183
Maduræ, 250
Stricture of urethra, 616
syphilitic, 515
Strongylus longevaginatus, 293
Struma, 559. See *Goiter.*
aberrata suprarenalis, 591
adenomatosa, 561
Strumitis, acute, 559
suppurative, 559
Submucous abscess of intestine, 505
fibroids, 632
Subperitoneal fibroids, 632
Substantia nigra, 726
Substantial emphysema of lungs, 420
Suffocation, 22
Suffusion, definition of, 51
Sugar in blood, 37
in urine, 37
Suggillation, definition of, 51
Sulphate of copper, poisoning by, 24
Sulphates in urine, 613
Sulphuric acid, excessive formation of, in body, 34

Sulphuric acid, poisoning by, 24
Supernumerary ovaries, 638
Suprarenal bodies, 564
accessory, 564
adenoma of, 566
amyloid degeneration of, 565
carcinoma of, 566
congenital abnormalities of, 564
fatty degeneration of, 565
general effects of diseases of, 566
glioma of, 566
hemorrhage from, 566
inflammation of, 566
neuroma of, 566
pigmentation of, 565
sarcoma of, 566
syphilis of, 565
tuberculosis of, 565
tumors of, 566
Suppurative bacterial diseases, 202
cholangitis, 542
encephalitis, 755
enteritis, 505
inflammation, 104
lymphadenitis, 336
myositis, 708
chronic, 708
nephritis, 574
neuritis, 808
pachymeningitis, 714
pyelonephritis, 574
Sympathetic nervous system, development of, 724
Syncytioma malignum, 175
Syncytium, 176, 655
Synovitis pannosa, 702
Syphilis, 254
congenital, 258
of arachnoid and pia, 721
of arteries, 388
of brain, 744
of bone, 697
of brain, 768
of bronchi, 413
of dura mater, 714
cord, 776
of esophagus, 484
of Fallopian tubes, 649
of heart, 375
of intestines, 515
of joints, 705
of kidney, 590
of larynx, 406
of liver, 534
of lungs, 454
of lymphatic glands, 341
vessels, 400
of mammary gland, 678
of mouth, 472
of muscles, 712
of nasal cavities, 403
of nerves, 808
of pancreas, 549
of pericardium, 380
of pharynx, 480
of pia and arachnoid of cord, 778
of pituitary body, 773
Syphilis of placenta, 657
of pleura, 465
of spleen, 334
of suprarenal bodies, 565
of testicle, 668
of thymus gland, 345
of thyroid gland, 562
of tongue, 472
of trachea, 409
of urethra, 618
of uterus, 631
of vagina, 654
of vulva, 660
secondary lesions of, 255
tertiary lesions of, 256
Syphilitic bubo, 255
gummata of stomach, 493
periostitis, 697
pneumonia, congenital, 440
stricture, 515
Syphilomata, 256
Syringomyelia, 782

Tabes dorsalis, 793
mesenterica, 341
Tænia Algeriana, 282
cucumerina, 282
echinococcus, 282
elliptica, 282
flovopunctata, 282
Madagascariensis, 282
nana, 281
saginata, 280
solium, 279
tenella, 282
Tape-worms, 277
dwarf, 281
Teeth, affections of, 474
Temperature, high, effect of, 20
Tendon-sheaths, inflammation of, 706
Tenosynovitis, 706
gonorrheal, 616
Teratoma, 179
of pia and arachnoid, 723
Tertian fever, parasite of, 267
Testicles, 663
adenoma of, 669
adenosarcoma of, 669
atheromatous cyst of, 671
atrophy of, 663
benign fungus of, 665
calcification of, 664
carcinoma of, 669
caseation of, 664
chondrocarcinoma of, 670
chondroma of, 669
congenital abnormalities of, 663
cysts of, 670
dermoid cysts of, 671
echinococcus cysts of, 671
fatty degeneration of, 664
fibroma of, 669
hyperemia of, 664
hypertrophy of, 664
inflammation of, 664. See *Orchitis.*
lepra of, 669
myxoma of, 669

Testicles, myxomatous degeneration of, 664
osteoma of, 669
papilliferous cystoma of, 670
rhabdomyoma of, 669
sarcoma of, 669
syphilis of, 668
syphilitic fungus of, 669
tuberculosis of, 667
tumors of, 669
Tetanin, 247
Tetanotoxin, 247
Tetanus 246
antitoxin of, 247
bacillus of, 246
Thalamencephalon, 724
Thermophilic bacteria, 189
Thiothrix, 183
Third ventricle of brain, 726
Thoracic duct, diseases of, 401
Thrombi, ball, 57
calcification of, 58
canalization of, 58
degeneration of, 57
marantic, 55
organization of, 58
purulent softening of, 58
simple softening of, 58
stratified, 56
Thrombo-arteritis, 384
Thrombophlebitis, 396
Thrombosis, 55
fermentation-, 55
of bone, 688
of brain, 751
of cavities of heart, 350
of coronary artery, 351
of intestines, 503
of kidney, 570
of liver, 523
of muscles, 707
of spleen, 329
of thoracic duct, 401
Thrombus, lateral, 56
obstructive, 56
primary, 56
secondary, 56
Thrush, 471
of esophagus, 484
of stomach, 493
Thymus gland, diseases of, 345
Thyroid disease, general results of, 562
gland, 558
abscess of, 559
actinomycosis of, 562
adenoma of, 562
anatomic considerations, 558
carcinoma of, 562
circulatory disturbances in, 559
congenital defects of, 559
general results of disease of, 562
hyperemia of, 559
inflammation of, 559
sarcoma of, 562
syphilis of, 562
tuberculosis of, 562
tumors of, 562
Tissue-changes, progressive, 113
-destruction, excessive, 33
-elasticity, decreased, a cause of edema, 60
Toadstools, poisoning by, 28
Tongue, actinomycosis of, 473
furring of, 468
geographical, 467
nigrities of, 471
syphilis of, 472
tuberculosis of, 471
Tonsil, abscess of, 478
hypertrophy of, 478
Tonsillitis, 477
catarrhal, 477
follicular, 477
lacunar, 477
phlegmonous, 477, 478
Tophi of gout, 36
Toxalbumins, 194
from plants, poisoning by, 27
Toxic products of bacteria, action of, 27
effects of, 196
Toxin-immunity, 199
of diphtheria, 213
Toxins, 194
Toxophylaxins, 201
Toxosozins, 201
Trachea, 408
circulatory disturbances of, 408
inflammations of, 408
malformations of, 408
syphilis of, 409
tuberculosis of, 409
tumors of, 409
Traction-diverticula of esophagus, 483
Transitional leukocytes, 299
Traumatic hemorrhage, 50
theory of cause of carcinoma, 164
Traumatism in etiology of disease, 19
Trematodes, 293
Trichina spiralis, 288
in larynx, 408
Trichiniasis, 289
Trichobacteria, 185
Trichocephalus dispar, 290
Trichomonas caudata, 275
elongata, 275
flagellata, 275
intestinalis, 275
vaginalis, 275
Trilocular heart, 347
True hypertrophy, 114
neuroma, 154
Tubal abortion, 651
pregnancy, 650
Tube-cast in nephritis, 581
Tubercle-bacillus, 223
lymphoid, 229
miliary, 227
structure and evolution of, 228
toxic properties of, 233
Tubercula dolorosa, 155
Tubercular leprosy, 236
pneumonia, 210
Tuberculin of Koch, 234
Tuberculosis, 223

Tuberculosis, acute pneumonic, 446
avian, 235
bacillus of, 223
bronchogenic, 444
chronic pneumonic, 447
fowl-, 235
gallivarum, 235
hematogenic, 451
latent, 233
lymphogenic, 453
miliary, 232
of arteries, 388
of bladder, 602
of bone, 694
of brain, 767
of bronchi, 413
of choroid plexus, 762
of dura mater, 714
of cord, 775
of epididymis, 667
of esophagus, 484
of Fallopian tubes, 648
of heart, 375
of intestine, 514
of joints, 704
of kidney, 590
of larynx, 406
of liver, 534
of lungs, 443
bronchogenic, 443, 444
of lymphatic glands, 338
of lymphatics, 400
of mammary gland, 678
of mouth, 471
of muscle, 712
of nasal cavities, 403
of nerves, 808
of ovary, 639
of pancreas, 549
of pelvis of kidney, 597
of penis, 662
of pericardium, 380
of peritoneum, 556
of pharynx, 480
of pia and arachnoid of cord, 778
of pituitary body, 773
of placenta, 657
of pleura, 465
of prostate, 672
of seminal vesicles, 676
of spleen, 333
of suprarenal bodies, 565
of testicle, 667
of thoracic duct, 401
of thymus gland, 345
of thyroid gland, 562
of tongue, 471
of trachea, 409
of urethra, 618
of uterus, 630
of vagina, 654
of vas deferens, 668
of veins, 399
of vulva, 660
pneumonic, 445
relations of human, to animal, 227
seats of, 232

Tuberculous meningitis, 719
pneumonia, 435
ulceration of stomach, 493
Tubo-ovarian cysts, 650
Tubular adenoma, 160
Tumor-dyscrasia, 164
Tumors, 115
benign, 119
circumscribed, 118
classification of, 120
dendritic, 118
fungiform, 118
fungoid, 118
infiltrating, 118
malignant, 119
mixed, 129
of arachnoid and pia, 721
of biliary ducts, 544
of bladder, 604
of bone, 698
of brain, 768
of bronchi, 413
of choroid plexus, 763
of dura mater, 715
of cord, 776
of esophagus, 484
of Fallopian tubes, 649
of gall-bladder, 544
of heart, 375
of intestine, 516
of joints, 705
of kidney, 590
of larynx, 407
of liver, 536
of lungs, 457
of lymphatic glands, 341
vessels, 400
of mammary gland, 679
of mouth, 473
of muscles, 712
of nasal cavities, 403
of nerves, 809
of ovaries, 640
of pancreas, 549
of pelvis of kidney, 598
of penis, 662
of pericardium, 380
of peritoneum, 557
of pharynx, 480
of pituitary body, 773
of pleura, 465
of salivary glands, 481
of seminal vesicles, 676
of spinal cord, 802
of spleen, 332
of stomach, 493
of suprarenal bodies, 566
of teeth, 474
of testicle, 669
of thoracic duct, 401
of thymus gland, 345
of thyroid gland, 562
of trachea, 409
of ureter, 598
of urethra, 618
of uterus, 632
of vagina, 654

Tumors of veins, 398
of vulva, 660
papillary, 118
polypoid, 118
verrucose, 118
Typhlitis, 506
stercoral, 506
Typhoid fever, 214, 511
bacillus of, 214
complications of, 513
Typhus fever, bacteriology of, 262
icteroides, 260
recurrens, 251
Tyroma, meningeal, 720
Tyrosin in urine, 35, 613
Tyrotoxicon, 29

ULCER, 105
indolent, 105
peptic, of intestines, 505
phagedenic, 105
serpiginous, 105
Ulceration of intestines, 505
Ulcerative dysentery, 510
endocarditis, 354
esophagitis, 483
gastritis, 486
stomatitis, 469
Ulcers of bronchi, 412
Ulcus ex digestione, 489
Umbilical cord, abnormalities of, 655
velamentous insertion, 655
Urate of sodium, deposit in tissues, 83
Urates in urine, 612
Uratic infiltration, 83
Urea, formation of, 33
Uremia from nephritis, 585
Ureter, 595
dilatation of, 595
inflammation of, 597
malformations of, 595
obstructions of, 595
parasites of, 598
tumors of, 598
Ureteritis, 597
Urethra, 614
carcinoma of, 618
congenital abnormalities of, 614
cysts of, 618
inflammation of, 614
injuries of, 617
sarcoma of, 618
stricture of, 616
tuberculosis of, 618
tumors of, 618
Urethritis, 614
anterior, 615
associated lesions of, 615
posterior, 616
Uric acid calculi, 603
crystals in urine, 611
excretion of, in gout, 37
formation of, 36
Urinary bladder. See *Bladder.*
calculi, 603
results of, 604
organs, congenital anomalies of, 567
Urine, abnormal conditions of, 606
bacteria in, 610
bilirubin in, 613
carbonates in, 613
chemic changes in, 611
cholesterin in, 613
color of, 606
cystin in, 613
fat-crystals in, 613
hippuric acid in, 612
indigo in, 613
in nephritis, 581
leucin in, 613
oxalate of urine in, 611
phosphates in, 611
quantity of, 606
reaction of, 606
sediments of, 611
specific gravity of, 606
sulphates in, 613
tyrosin in, 613
urates in, 612
uric acid crystals in, 611
xanthin in, 613
Uriniferous tubules, concretions in, 589
Urobilinuria, 607
Uschinsky's fluid, 190
Uterus, 618
adenoma of, 634
malignant, 634
amyloid degeneration of, 631
anteflexion of, 620
anteversion of, 620
bicornis, 619
carcinoma of, 634
congenital abnormalities, 619
cysts of, 637
dilatation of, 622
erosions of, 627
fatty degeneration of, 631
fibroid of, 632
polyps of, 632
fœtalis seu infantalis, 619
hemorrhages of, 624
hyperemia of, 623
hyperplasia of mucous membrane of, 631
hypertrophy of, 631
hypoplasia of, 619
inflammation of, 624
inversion of, 622
lateral displacements of, 620
leiomyoma of, 632
myofibroma of, 632
parasites of, 637
polyps of, 632
prolapse of, 620
puerperal atrophy of, 631
infections of, 628
retroflexion, 620
rupture of, 623
sarcoma of, 634
senile atrophy of, 631
septus, 619
stenosis of, 622
syphilis of, 631
tuberculosis of, 630

Uterus, tumors of, 632
unicornis, 620
upward dislocation of, 620

VACCINIA, animal parasites of, 273
Vacuolation of red blood-corpuscle, 305
Vacuolization of nerve-cell, 735
Vagina, 652
carcinoma of, 654
circulatory disturbances of, 653
cysts of, 654
fibroma of, 654
hyperemia of, 653
inflammation of, 653. See *Vaginitis.*
myofibroma of, 654
papilloma of, 654
sarcoma of, 654.
stenosis of, 652
syphilis of, 654
tuberculosis of, 654
tumors of, 654
Vaginal cystocele, 652
rectocele, 652
wall, prolapse of, 652
wounds and fistulæ of, 652
Vaginitis, 653
acute catarrhal, 653
chronic catarrhal, 653
exfoliative, 653
pseudomembranous, 653
testis, 664, 666
hemorrhagic, 667
purulent, 667
serofibrinous, 666
serous, 666
Valvular defects, 348
Varicella, micro-organism of, 274
Varicose aneurysm, 395
veins of spinal cord, 786
Varicosity, 397
Variola, animal parasites of, 273
Vas deferens, inflammation of, 667
tuberculosis of, 668
Vascular goiter, 561
theories of inflammation, 98
Vein-stones, 396
Veins, 395
calcification of, 396
dilatation of, 397
fatty degeneration of, 396
inflammation of, 396
tuberculosis of, 399
tumors of, 398
Venereal wart, 157
Venom of serpents, poisoning by, 27
Venous hemorrhage, 48
hyperemia, 46
Ventricular septum, defects of, 348
Verrucose endocarditis, 354
tumors, 118
Vesica bipartitis, 599
Vesicular emphysema of lungs, 420
Vibrio choleræ Asiaticæ, 219
Vibrion septique, 240
Vicarious emphysema of lungs, 420
Virchow's theory of inflammation, 98
classification of tumors, 120
theory of tumors, 116
Voluntary muscles, diseases of, 706
Volvulus, 501
Vulva, 659
abscess of, 659
adenoma of, 660
carcinoma of, 661
chancroids of, 660
circulatory disturbances of, 659
cysts of, 661
diphtheria of, 660
elephantiasis of, 660
fibroma of, 660
fibromyxoma of, 660
gangrene of, 660
hematoma of, 659
hyperemia of, 659
inflammation of, 659
lipoma of, 660
myofibroma of, 660
papillomatous tumors of, 660
sarcoma of, 660
syphilis of, 660
tuberculosis of, 660
tumors of, 660
wounds of, 659
Vulvitis, 659

WART, 157
venereal, 157
Waxy casts in nephritis, 582
Wens, 177
White blood-corpuscles, 298. See *Leukocytes.*
infarct, 53
matter of cord, degeneration of, 799
softening of brain, 751
Whooping-cough, bacteriology of, 261
Widal reaction, 217
Wool-sorters' disease, 242
Wounds, repair of, 106

XANTHIN, 36
diabeticorum, 126
in urine, 613
Xanthoma, 126
diabeticorum, 126
vulgare, 126

YELLOW fever, 260
antitoxin of, 261
bacillus of, 260
softening of brain, 751

ZIEHL'S solution, 187
Zuckergussleber, 534, 556

LANE MEDICAL LIBRARY

To avoid fine, this book should be returned on or before the date last stamped below.

J111 Stengel, A. 43499
S825 A text-book of path-
1899 ology... 2d ed.

NAME	DATE DUE
Bindery	